



**HAL**  
open science

## Staged gamma knife radiosurgery for large critically located benign meningiomas: evaluation of a series comprising 20 patients

Klaus Haselsberger, Thorsten Maier, Karlheinz Dominikus, Etienne Holl, Senta Kurschel, Petra Ofner-Kopeinig, Frank Unger

### ► To cite this version:

Klaus Haselsberger, Thorsten Maier, Karlheinz Dominikus, Etienne Holl, Senta Kurschel, et al.. Staged gamma knife radiosurgery for large critically located benign meningiomas: evaluation of a series comprising 20 patients. *Journal of Neurology, Neurosurgery and Psychiatry*, 2009, 80 (10), pp.1172. 10.1136/jnnp.2008.156745 . hal-00552712

**HAL Id: hal-00552712**

**<https://hal.science/hal-00552712>**

Submitted on 6 Jan 2011

**HAL** is a multi-disciplinary open access archive for the deposit and dissemination of scientific research documents, whether they are published or not. The documents may come from teaching and research institutions in France or abroad, or from public or private research centers.

L'archive ouverte pluridisciplinaire **HAL**, est destinée au dépôt et à la diffusion de documents scientifiques de niveau recherche, publiés ou non, émanant des établissements d'enseignement et de recherche français ou étrangers, des laboratoires publics ou privés.

**Staged gamma knife radiosurgery for large critically located benign meningiomas: evaluation of a series comprising 20 patients**

**Klaus Haselsberger, Thorsten Maier, Karlheinz Dominikus, Etienne Holl, Senta Kurschel, Petra Ofner-Kopeinig, Frank Unger**

**Klaus Haselsberger, Thorsten Maier, Etienne Holl, Senta Kurschel, Frank Unger**

Department of Neurosurgery, Medical University, Graz, Austria

**Karlheinz Dominikus**, Department of Therapeutic Radiology and Oncology, Medical University, Graz, Austria

**Petra Ofner-Kopeinig**, Institute for Medical Informatics, Statistics and Documentation, Medical University, Graz, Austria

Correspondence to:

Klaus Haselsberger, M.D.

Department of Neurosurgery

Medical University

Auenbruggerplatz 29

8036 Graz, Austria

Phone: +43-316-385-81935

Fax: +43-316-385-3368

Email: klaus.haselsberger@klinikum-graz.at

**Keywords:** meningioma • stereotactic radiosurgery • staged treatment • gamma knife

**The Corresponding Author has the right to grant on behalf of all authors and does grant on behalf of all authors, an exclusive licence (or non exclusive for government employees) on a worldwide basis to the BMJ Publishing Group Ltd and its Licensees to permit this article (if accepted) to be published in JNNP and any other BMJ PGL products to exploit all subsidiary rights, as set out in the licence (<http://adc.bmjournals.com/ifora/licence.dtl>).**

## **ABSTRACT**

**Objectives:** This study investigates the efficacy of staged radiosurgical treatment for intracranial meningiomas exceeding 3 cm in diameter.

**Methods:** Between April 1992 and May 2008 staged gamma knife radiosurgery (GKRS) was performed in 20 patients with large benign meningiomas. 14 patients had undergone surgery at least once. The patients' age ranged between 26 and 73 years (median 60.5 years). Tumour volumes measured between 13.6 and 79.8 cm<sup>3</sup> (median 33.3), treatment volumes between 5.4 and 42.9 cm<sup>3</sup> (median 19.0). Out of 41 treatments, the prescription dose at the tumour margin was 12 Gy for 33 treatments, 10 Gy for one, 14 Gy for four, 15 Gy for one, and 25 Gy for further two, respectively (median: 12 Gy to a marginal isodose of 45%). Median follow-up was 7.5 years.

**Results:** Tumour control was achieved in 90% of our series (25 % tumour regression, 65 % stable size). 2 patients (10%) experienced tumour progression outlying the planning target volumes treated by an additional radiosurgical procedure. Thereafter, tumour volume decreased in one patient and remained stable in the second one. Clinically, 9 patients (45%) improved within the time of follow-up, 11 (55%) remained unchanged.

**Conclusion:** Due to excellent tumour control at a low concomitant morbidity, staged SRS for meningiomas represents a safe treatment modality that can be recommended for meningiomas in critical locations either after incomplete surgery or as primary treatment for patients with significant co-morbidity.

## **INTRODUCTION**

Among so-called benign meningiomas (WHO grade 1), there are two distinct patterns of tumour growth and recurrence, corresponding to different genetic subtypes.<sup>1-3</sup>

Surgical morbidity for meningiomas in critical locations (cavernous sinus, petroclival, falcotentorial) has remained high even in modern neurosurgery.<sup>4-6</sup> Therefore, further improvements are not likely to be achieved by surgery alone. Single-staged radiosurgery usually is limited to smaller tumours. Thus, the suitability of either tumour debulking followed by staged radiosurgery or that of staged radiosurgery as primary treatment in elderly patients has to be thoroughly evaluated.

Our study presents the experience obtained in the largest series of meningioma patients treated according to this concept so far.

## **PATIENTS AND METHODS**

### **Patient population**

From April 1992 to May 2008, 1012 patients with benign intracranial meningiomas were treated at our department. Among patients harbouring large tumours, 70 underwent surgery followed by gamma knife radiosurgery (GKRS), 28 had surgery twice, 41 had surgery twice and subsequent GKRS. Among the 20 patients of this series, 13 were referred from other neurosurgical centers specifically for GKRS, seven were primarily admitted at our department. Prior to GKRS, patients were informed about all therapeutic alternatives and their complications; all gave informed consent. A staged procedure was defined as at least two consecutive radiosurgical treatments at time intervals between one and twelve months. Patient characteristics, tumour location, and treatment prior to staged GKRS see table.

Most patients (14/22, 70%) underwent staged GKRS following surgery either due to recurrent or residual tumours, one patient (1/20, 5%) had tumour embolisation. In five patients

(5/20, 25%), GKRS was the primary treatment. Patients demonstrated a number of pre-existent neurological deficits that had partially deteriorated after surgery.

### **Radiosurgical technique**

All stereotactic procedures were performed using the Leksell gamma knife (model B; Elekta Instruments AB, Stockholm, Sweden). An image-compatible stereotactic frame was applied under local anaesthesia. Before 1996, computed tomography (CT) was used for treatment planning (four patients), thereafter, magnetic resonance imaging (MRI) using axial and coronal T1 sequences with and without contrast enhancement.

In 14 cases, the diagnosis meningioma WHO grade 1 was confirmed by histopathological specification, in six patients diagnosis was assessed radiologically. The median total tumour volume was 33.8 cm<sup>3</sup> (range 13.6-79.8). Treatment isodose and margin dose were determined corresponding to tumour size, location and proximity to critical structures. Dose selection resulted by assessing tumour volume and its relationship to the integrated logistic equation for a 3% risk of permanent brain injury modified to Flickinger.<sup>7</sup> Median treatment volume was 19.0 cm<sup>3</sup> (range 5.4-42.9). Out of 41 treatments, the prescription dose at the tumour margin was 12 Gy for 33 treatments, 10 Gy for one, 14 Gy for four, 15 Gy for one, and 25 Gy for two, respectively (median: 12 Gy to a marginal isodose of 45%), see table. Multiple irradiation isocenters were required to cover irregular tumour shapes (median: 9, range 3-22). In all cases, one or more of the 201 sources were blocked to reduce radiation exposure to the eye lens. Collimator plugging patterns were used to shape the radiation volume and to protect critical areas (brainstem, optic nerves, chiasm and optic tract). The median time interval between the staged procedures was 6 months (range 1-12).

All patients were discharged the day after GKRS and routinely followed at intervals of 6 months including clinical and radiological examinations. Tumour control was defined as a

stable or decreased tumour volume assessed by volumetric calculations based on neuroimaging (MRI).

Follow-up data refer to the last GKRS of the staged radiosurgical treatment protocol. Statistical analysis was performed using SPSS software, Version 14.0 (SPSS Inc., Chicago, IL, USA).

## **RESULTS**

Regression of tumour volume was observed in five patients (5/20, 25%), whereas 13 patients (13/20, 65%) presented with a stable tumour size (see table). Two patients (pat. No. 7 and 13) experienced tumour regrowth after 84 and 74 months, respectively. In both patients, tumour regrowth originated from areas outlying the radiosurgical target volumes. Following an additional GKRS, in pat. No. 7, tumour size has remained stable ever since (follow-up after additional GKRS, 98 months), in pat. No. 13, tumour size decreased in the further follow-up (13 months so far).

Neurological evaluation showed improvements in nine patients (9/20, 45%), concerning cranial nerve deficits, seizures and hemiparesis, etc, (see table). In nine other cases (9/20, 45%), the pre-existing neurological deficit remained stable, two more patients (2/20, 10%), asymptomatic prior to GKRS, maintained their condition. Three patients died during the follow-up, all unrelated to disease and treatment.

Immediate adverse effects included transient nausea or vomiting in two patients and headache in five patients, respectively, following frame application and removal. At the first 6-month MRI control, two patients (pat. No. 5 and 14, respectively) developed a high T<sub>2</sub>-signal intensity in the surrounding brain suggestive of peritumoural oedema which resolved completely after oral administration of steroids without evidence of any new neurological deficit. All patients were able to recover their pre-radiosurgical functional level within one week.

## **Illustrative case**

A 61-year-old man presented with reduced vision, cephalgia, and complex partial seizures. MRI demonstrated a large skull base meningioma (sphenoid wing, left middle fossa, clivus) with encasement of the left carotid and basilar artery. Due to a critical cardiac co-morbidity the risk for surgery was rated as high. As alternative treatment option, the patient was allocated to GKRS. Twenty-five months earlier, he had undergone tumour embolisation elsewhere without improving his neurological deficits. The first GKRS was focused on the tumour mass compressing the optic chiasm and brainstem with 12 Gy to the 45% isodose (fig 1a). Four months later, a second GKRS was directed towards the temporal part of the tumour delivering 12 Gy to the 40% isodose (fig 1b and 1c). Follow-up MRI after 51.5 months showed a considerably decreased tumour size (fig 1d). Neurologically, the patient was seizure-free, his vision having improved.

**Table** Patient characteristics, neurological outcome, radiosurgical treatment strategies, and effects on tumour volume

No	Age (yrs), Sex	Meningioma location	Previous treatment	Pre-existent neurological deficits/symptoms	Neurological outcome	Tumour volume (cm <sup>3</sup> )	Treatment volume (cm <sup>2</sup> )	Marginal dose (Gy)	Marginal isodose (%)	No. of isocenters	Treatment interval (months)	Follow-up (months)	Tumour volume
1	61, m	SW, CS	emb.	reduced vision, seizures, cephalaea	vision improved, seizure-free	74.9	33.3/42.9	12/12	45/40	8/12	4	52	decreased
2	59, f	FT	surg. (2x), rec.	none	asymptomatic	18.1	5.4/13.2	12/12	55/40	5/5	7	95	stable
3	64, m	FT	surg. (5x), rec.	hemianopia, HP, seizures	stable	21.1	9.2/12.3	25/25	50/50	8/8	1	89(†)	stable
4	52, f	SW, CS	none	reduced vision	stable	24.5	19.9/4.6	12/12	45/53	4/10	5	43	decreased
5	71, f	PC, CS	none	vertigo, ataxia	stable	41.5	31.0/12.4	14/14	45/45	9/6	11	12	stable
6	65, m	SW, CS, PC	surg. (1x), res.	III, V, VII CN def., reduced vision, seizures	CN def., seizures, and vision improved	39.9	17.0/24.0	12/12	40/40	6/6	6	69	stable
7	53, f	PC, CS	surg. (3x), rec.	III, V, VI, VII CN def., reduced vision, HP	CN def. and HP resolved, normal vision	42.2	36.7/7.5/(1.9)*	12/15/(13)*	30/50/(45)*	3/6/(9)*	5/(84)*	182(γ)	stable
8	66, f	FT	none	visual field def., psych.	visual field def., and psych. improved	40.6	21.0/20.5	12/12	50/50	9/10	7	120	stable
9	67, f	FT	surg. (1x), res.	cephalea, ataxia, III, IV CN def.	cephalea, ataxia improved, III, IV CN def. resolved	32.1	14.5/18.7	12/12	45/45	8/7	7	105	stable
10	58, f	SW, CS, PC	none	III CN def.	stable	30.0	12.4/19.1	12/12	40/45	7/6	8	92	stable
11	26, f	SP, SW, CS	surg. (2x), res.	seizures, blindness right, visual field def. left, III CN def.	stable	33.8	15.4/19.0	12/12	45/45	7/8	8	18(†)	decreased
12	45, f	SW, PC	emb., surg. (2x), res.	cephalea, reduced vision	stable	79.8	40.4/40.8	12/12	45/40	10/9	6	99	stable
13	57, f	PC	emb., surg. (1x), res.	none	asymptomatic	38.1	15.5/24.1/(3.8)*	14/14/(12)*	50/45/(50)*	13/9/(9)*	7/(74)*	87(γ)	decreased
14	73, m	OG	surg. (1x), res.	psych.	psych. improved	19.9	7.5/12.1	12/10	30/50	9/7	6	104(†)	decreased
15	66, f	CV, PC	surg. (2x), rec.	III, VII CN def., cephalaea, blindness left, deafness left	stable	48.2	28.0/20.8	12/12	40/40	13/8	5	110	stable
16	65, f	PC	surg. (1x), rec.	ataxia, V CN def.	stable	13.6	7.2/10.8	12/12	50/55	14/14	12	46	stable
17	36, m	PC	emb., surg. (1x), res.	VII CN def.	stable	28.9	20.0/9.9	12/12	45/50	5/10	6	39	stable
18	64, f	CS	surg. (1x), res.	III, IV, V, VI CN def.	VI CN def. improved	19.7	14.6/5.8	12/12	50/60	9/7	6	91	stable
19	48, m	PS	none	hemihypaesthesia	improved	57.0	25.2/22.8/24.0	12/12/12	45/45/45	22/17/17	4/5	40	decreased
20	60, f	PC, CS	surg. (2x), rec.	III, VI CN def.	III CN def. improved, VI CN def. stable	41.9	22.0/20.7	12/12	45/45	11/9	6	120	stable

Legend: (†) patient died during follow-up, not treatment- and not disease-related, (γ) patient underwent additional GKRS because of tumour regrowth outside the previous planning target volumes, (\*) treatment characteristics of additional GKRS after tumour regrowth

Abbreviations: age, sex: yrs = years, m = male, f = female

meningioma location: CS = cavernous sinus, FT = falcotentorial, OG = olfactory groove, PC = petroclival, PS = parasagittal, SP = sphenoidal plane, SW = sphenoidal wing

previous treatment: emb. = embolisation, surg. = surgery, res. = residual tumour, rec. = recurrence

neurological deficits/symptoms: CN = cranial nerve, def. = deficit, HP = hemiparesis, psych. = psychiatric disorders



## DISCUSSION

For meningiomas in critical locations, the success of SRS – confirmed by series with excellent long-term results<sup>8-11</sup> – has led to a shift in the treatment paradigms from radical surgery to a combined surgical/radiosurgical approach or even SRS as primary therapy since attempts of achieving gross total resection are associated with a high risk of surgical morbidity: New permanent cranial nerve deficits following surgery of cavernous sinus meningiomas occur in 18% to 70%,<sup>6</sup> surgery-related morbidity for petroclival meningiomas ranging between 7% and 40%.<sup>5,12</sup> Mathiesen et al have coined the term “Simpson grade 4 gamma” for a combination of judicious (subtotal) surgery followed by stereotactic radiosurgery.<sup>5</sup>

Even in some recent publications – external beam radiation (EBRT) and SRS including Gamma Knife, linear accelerator (LINAC) technique and cyberknife are all addressed to as “radiotherapy”.<sup>13-15</sup> As there is, however, a distinct difference between EBRT and SRS concerning both their radiobiological effects and their way of application, this very difference has led to a (re)definition regarding the term “stereotactic radiosurgery” (SRS).<sup>16</sup> By definition, SRS is limited to a maximum of five fractions<sup>16</sup> which is not contradictory to Lars Leksell’s original description.<sup>17</sup>

Although DiBiase et al.<sup>18</sup> identified gross total volume (GTV) exceeding 10 cm<sup>3</sup> as the only significant parameter associated with a worse prognosis for radiosurgical treatment of meningiomas, data of this series equal results achieved by a Simpson grade 1 resection (recurrence rate 9%)<sup>19</sup> and are very close to those obtained by SRS for smaller tumours.<sup>8-11, 18,20,21</sup> By a staged procedure, the characteristic benefit of SRS in terms of its inherent steep radiation fall off can be maintained also in the treatment of larger tumours, thus protecting adjacent brain tissue from radiation-induced injury.<sup>22,23</sup> With reference to the dose plan of the previous radiosurgical procedures, the overlap of radiation can be minimized. Furthermore, this approach – unlike open surgery – can be offered also to patients with significant co-

morbidity. Based on our own experience and in compliance with the specific literature, the marginal dose of 12 Gy can be regarded as safe and efficient.<sup>8,9,11,14,21</sup>

Metellus et al.<sup>20</sup> have compared GKRS and conventional radiotherapy for cavernous sinus meningiomas. They conclude that both EBRT and GKRS are safe and efficient, but GKRS provides a better radiological response, is far more convenient and fits into most patients' lives much better than EBRT.<sup>20</sup> Moreover, in contrast to surgery, an additional GKRS can be offered readily to patients with tumour recurrence without further risks of treatment-related morbidity. Even as staged treatment, SRS proves to be associated with a low risk of complications and a short hospitalization compared to both surgery and EBRT and we think that all radiosurgical techniques (Gamma Knife, LINAC, Cyber Knife) will show as appropriate tools for the treatment of "high risk" meningiomas in the future.

## **CONCLUSIONS**

Although benign meningiomas may recur even after a long time interval and need therefore be followed adequately, the data of our series justify a clear recommendation in favour of staged SRS with or without previous surgery for large meningiomas in delicate locations compared to open surgery alone or conventional radiotherapy. By yielding excellent tumour control at a very low level of treatment-related morbidity, staged radiosurgery provides a substantial improvement regarding the treatment options for large meningiomas in critical regions.

## **ACKNOWLEDGEMENTS**

The authors thank Ms E. Meier for preparation of the manuscript.

## REFERENCES

- 1 **Pfisterer WK**, Hendricks WP, Scheck AC *et al.* Fluorescent in situ hybridization and ex vivo <sup>1</sup>H magnetic resonance spectroscopic examinations of meningioma tumor tissue: is it possible to identify a clinically-aggressive subset of benign meningiomas? *Neurosurgery* 2007;**61**:1048-61.
- 2 **Couldwell WT**, Cole CD, Al-Mefty O. Patterns of skull base meningioma progression after failed radiosurgery. *J Neurosurg* 2007;**106**:30-5.
- 3 **Ketter R**, Rahnenführer J, Henn W, *et al.* Correspondence of tumor localization with tumor recurrence and cytogenetic progression in meningiomas. *Neurosurgery* 2008;**62**:61-70.
- 4 **Bambakidis NC**, Kakarla UK, Kim LJ, *et al.* Evolution of surgical approaches in the treatment of petroclival meningiomas: a retrospective review. *Neurosurgery* 2007;**61** (Suppl 2):202-11.
- 5 **Mathiesen T**, Gerlich A, Kihlström L, *et al.* Effects of using combined transpetrosal surgical approaches to treat petroclival meningiomas. *Neurosurgery* 2007;**60**:982-92.
- 6 **Couldwell WT**, Kan P, Liu JK, *et al.* Decompression of cavernous sinus meningioma for preservation and improvement of cranial nerve function. *J Neurosurg* 2006;**105**:148-52.
- 7 **Flickinger JC**. An integrated logistic formula for prediction of complications from radiosurgery. *Int Radiat Oncol Biol Phys* 1989;**17**:879-85.
- 8 **Lee JYK**, Niranjan A, McInerney J, *et al.* Stereotactic radiosurgery providing long-term tumor control of cavernous sinus meningiomas. *J Neurosurg* 2002;**97**:65-72.
- 9 **Kollová A**, Liščák R, Novotný J Jr, *et al.* Gamma knife surgery for benign meningioma. *J Neurosurg* 2007;**107**:325-36.
- 10 **Kondziolka D**, Mathieu D, Lunsford LD, *et al.* Radiosurgery as definitive management of intracranial meningiomas. *Neurosurgery* 2008;**62**:53-60.

- 11 **Hasegawa T**, Kida Y, Yoshimoto M, *et al.* Long-term outcomes of gamma knife surgery for cavernous sinus meningioma. *J Neurosurg* 2007;**107**:745-51.
- 12 **Little KM**, Friedman AH, Sampson JH, *et al.* Surgical management of petroclival meningiomas: Defining resection goals based on risk of neurological morbidity and tumor recurrence rates in 137 patients. *Neurosurgery* 2005;**56**:546-59.
- 13 **Rockhill J**, Mrugala M, Chamberlain MC. Intracranial meningiomas: an overview of diagnosis and treatment. *Neurosurg Focus* 2007;**23**:E1.
- 14 **Rogers L**, Mehta M. Role of radiation therapy in treating intracranial meningiomas. *Neurosurg Focus* 2007;**23**:E4.
- 15 **Johnson WD**, Loredó LN, Slater JD. Surgery and radiotherapy: complementary tools in the management of benign intracranial tumors. *Neurosurg Focus* 2008;**24**:E2.
- 16 **Barnett GH**, Linskey ME, Adler JR, *et al.* Stereotactic radiosurgery – an organized neurosurgery-sanctioned definition. *J Neurosurg* 2007;**106**:1-5.
- 17 **Leksell L**. The stereotaxic method and radiosurgery of the brain. *Acta Chir Scand* 1951; **102**:3316-9.
- 18 **DiBiase SJ**, Kwok Y, Yovino S, *et al.* Factors predicting local tumor control after gamma knife stereotactic radiosurgery for benign intracranial meningiomas. *Int J Radiation Oncology Biol Phys* 2004;**60**:1515-9.
- 19 **Simpson D**. The recurrence of intracranial meningiomas after surgical treatment. *J Neurol Neurosurg Psychiatry* 1957;**20**:22-39.
- 20 **Metellus P**, Regis J, Muracciole X, *et al.* Evaluation of fractionated radiotherapy and gamma knife radiosurgery in cavernous sinus meningiomas: treatment surgery. *Neurosurgery* 2005;**57**:873-86.
- 21 **Kondziolka D**, Flickinger JC, Lunsford LD. The principles of skull base radiosurgery. *Neurosurg Focus* 2008;**24**:E11.

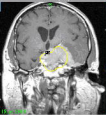
- 22 **Pendl G**, Unger F, Papaefthymiou G, *et al.* Staged radiosurgical treatment for large benign cerebral lesions. *J Neurosurg* 2000;**93** (Suppl 3):107-12.
- 23 **Iwai Y**, Yamanaka K, Nakajima H. Two-staged gamma knife radiosurgery for the treatment of large petroclival and cavernous sinus meningiomas. *Surg Neurol* 2001;**56**:308-14.

## **FIGURE LEGENDS**

**Figure 1** Illustrative case.

- a)** Coronal contrast enhanced T1-weighted MR planning image for the first GKRS – large sphenoid wing and cavernous sinus meningioma 25 months after initial embolisation (the line indicating the 45% isodose).
- b)** Axial and **c)** coronal contrast enhanced T1-weighted MRI for the second radiosurgical treatment performed four months later (12 Gy delivered to the 40% isodose line).
- d)** Axial contrast enhanced T1-weighted follow-up MRI obtained 51 months after the second GKRS demonstrating a clear regression of tumour volume.

Control (mm)



30° 15' 00" 000



