



**HAL**  
open science

## Two cases of distal extremity swelling with pitting oedema in psoriatic arthritis: the different pathological mechanisms

L. Quarta, A. Corrado, F. d'Onofrio, N. Maruotti, Francesco Paolo Cantatore

### ► To cite this version:

L. Quarta, A. Corrado, F. d'Onofrio, N. Maruotti, Francesco Paolo Cantatore. Two cases of distal extremity swelling with pitting oedema in psoriatic arthritis: the different pathological mechanisms. *Rheumatology International*, 2009, 30 (10), pp.1367-1370. 10.1007/s00296-009-1060-y . hal-00552491

**HAL Id: hal-00552491**

**<https://hal.science/hal-00552491>**

Submitted on 6 Jan 2011

**HAL** is a multi-disciplinary open access archive for the deposit and dissemination of scientific research documents, whether they are published or not. The documents may come from teaching and research institutions in France or abroad, or from public or private research centers.

L'archive ouverte pluridisciplinaire **HAL**, est destinée au dépôt et à la diffusion de documents scientifiques de niveau recherche, publiés ou non, émanant des établissements d'enseignement et de recherche français ou étrangers, des laboratoires publics ou privés.

## Two cases of distal extremity swelling with pitting oedema in psoriatic arthritis: the different pathological mechanisms

L. Quarta · A. Corrado · F. d’Onofrio · N. Maruotti ·  
Francesco Paolo Cantatore

Received: 21 May 2009 / Accepted: 28 June 2009 / Published online: 16 July 2009  
© Springer-Verlag 2009

**Abstract** In psoriatic arthritis, swelling and pitting oedema may be caused by different pathogenic mechanisms: on one hand, the involvement of tenosynovial structures; on the other hand, the involvement of lymphatic vessels, which may be rarely implicated by the inflammatory process. This different involvement is responsible for a different response to therapy and a different clinical outcome. In fact, patients with inflammation of the tenosynovial structures and normal lymphatic drainage have a more favourable clinical outcome and response to pharmacologic treatment, whilst patients affected by psoriatic arthritis with chronic lymphatic vascular damage are characterized usually by resistance of oedema to therapy. In this study, we report two cases of psoriatic arthritis with distal extremity swelling and pitting oedema. In the first patient, the swelling and pitting oedema were associated with lymphatic obstruction, as detected by lymphoscintigraphy. In the second, the predominant involvement of the tenosynovial structures, as shown by magnetic resonance, with normal lymphatic flow, may have been the cause of arthritis with oedema. These different pathogenetic mechanisms were associated with different response to therapy. Nevertheless, oedema was resistant to therapy in both patients probably because of other unknown factors, which influence therapy and clinical outcome.

**Keywords** Arthritis · Lymphoedema · Pathogenesis · Psoriasis

### Introduction

Lymphoedema is well known in rheumatoid arthritis (RA) [1], but its association with psoriatic arthritis (PsA) is rare. Until now, few cases have been described in literature [2–8]. Lymphoedema occasionally occurs in the upper limbs and the legs in RA. The swelling and oedema predominantly involve the upper limbs with asymmetric pattern in PsA. The lymphatic vessels or the tenosynovial structures may be involved in the inflammatory process. Their involvement may be revealed by lymphoscintigraphy and magnetic resonance imaging (MRI) and is responsible for a different response to therapy and a different clinical outcome. In consideration of these evidences, two different pathogenetic mechanisms have been hypothesized which may be associated with distal extremity swelling and pitting oedema in PsA [9].

In this study, we report two cases of PsA with distal extremity swelling and pitting oedema caused by involvement of different anatomical structures.

### Case reports

#### Case 1

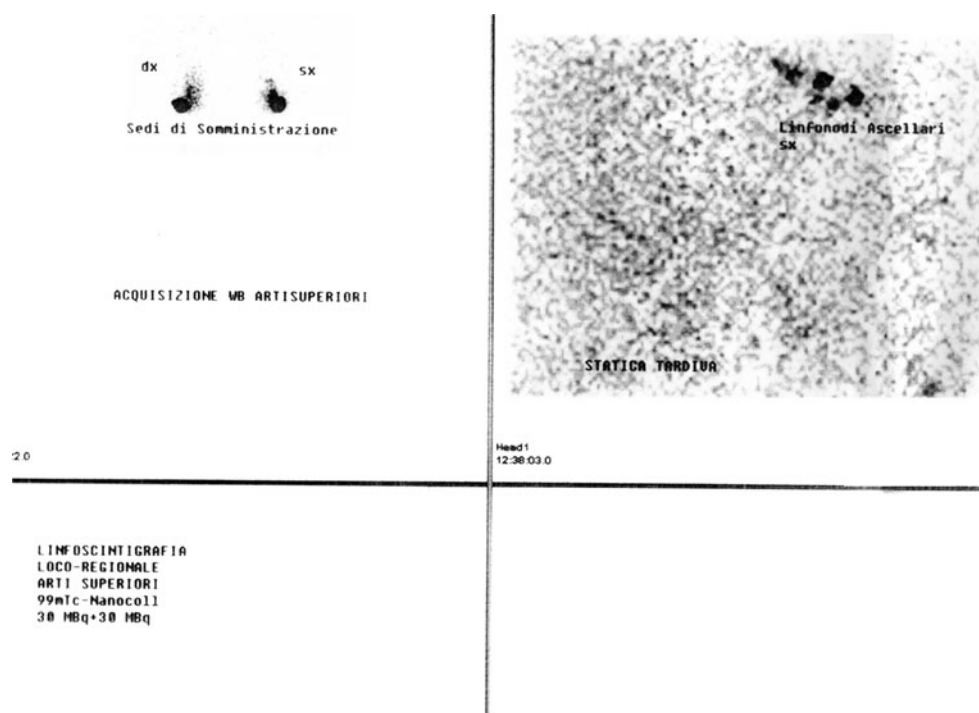
RM was a 38-year-old man affected by psoriasis. At the age of 21, he developed an erosive polyarthropathy involving the shoulder, elbow, wrist, carpal, distal interphalangeal (DIP), proximal interphalangeal (PIP) and metacarpophalangeal (MCP) joints, knee and metatarsophalangeal (MTP)

L. Quarta · A. Corrado · F. d’Onofrio · N. Maruotti · F. P. Cantatore  
Department of Rheumatology,  
University of Foggia Medical School, Foggia, Italy

F. P. Cantatore (✉)  
Rheumatology Clinic “Mario Carrozzo”,  
“D’Avanzo” Hospital, Viale degli Aviatori, 1,  
71100 Foggia, Italy  
e-mail: fp.cantatore@unifg.it

joints bilaterally. He also had a swelling and pitting oedema in the right hand and forearm. A diagnosis of PsA was made and he was treated with gold salts, methotrexate at a weekly dose of maximum 10 mg, methylprednisolone (16–4 mg/day) and anti-inflammatory non-steroid drugs (NSAIDs) without clinical improvement. At the age of 38 years, he was admitted to our clinic because of active asymmetrical arthritis and lymphoedema of the right hand and forearm. The physical examination revealed a marked swelling and pitting oedema of the right hand extending to below the elbow, tenderness of MCF, PIP and DIP joints of both hands, and swelling and tenderness of both elbows and left knee. Laboratory investigations revealed erythrocyte sedimentation rate (ESR), C-reactive protein (CRP), blood count, liver and renal function parameters within normal range. Rheumatoid factor and antinuclear antibodies were negative. X-rays of both hands showed multiple erosions of wrist, carpal, PIP and DIP joints. Quantitative lymphoscintigraphy  $^{99m}\text{Tc}$ -labelled nanocoll was performed on both arms. Colloid movement from the injection site on the dorsum of the right hand to the ipsilateral axillary nodes was absent, whilst left lymphatic drainage was normal (Fig. 1). MRI revealed a subcutaneous oedema without involvement of the synovial tendon sheaths. The patient underwent a manual lymphatic drainage and a treatment with etanercept (25 mg twice weekly), methotrexate (10 mg weekly), methylprednisolone (4 mg daily) and NSAID(s) therapy with a rapid clinical improvement of arthritis after 2–3 months of therapy, but without improvement of oedema after 12 months of treatment.

**Fig. 1** Quantitative lymphoscintigraphy  $^{99m}\text{Tc}$ -labelled nanocoll performed on both arms: absent colloid movement from the injection site on the dorsum of the right hand to the ipsilateral axillary nodes. Normal left lymphatic drainage

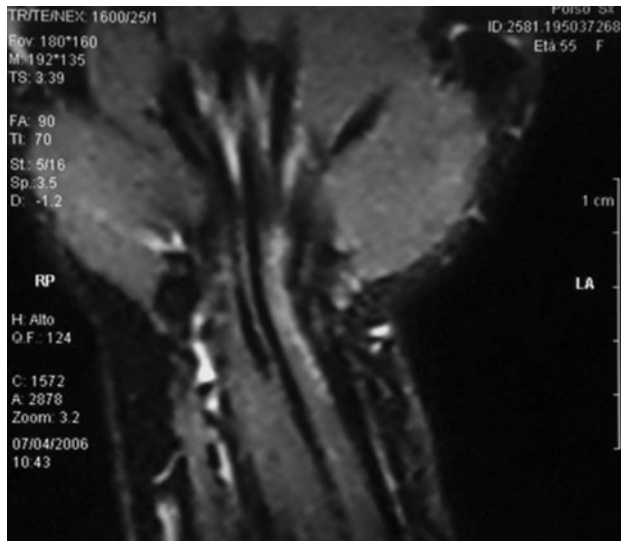


## Case 2

A 55-year-old woman was suffering from PsA since the age of 52 years. After the date of the diagnosis, her arthritis was treated with methotrexate (7.5 mg weekly) and NSAID(s) with good clinical improvement. At the age of 54 years, she was admitted to our clinic due to the development of swelling and pitting oedema of the left hand and forearm. On clinical examination, she showed a marked swelling and oedema of the left forearm and hand, and tenderness of MCP, PIP and DIP of the right hand. Psoriasis in both hands and onychodystrophy were observed. Biohumoral laboratory tests showed ESR 28 mm/h, CRP 0.094 mg/dl and normal blood count and protein electrophoresis. Rheumatoid factor and antinuclear antibodies were negative. X-rays of hands showed a subchondral microcyst at the head of the third right MCP joint. Quantitative lymphoscintigraphy  $^{99m}\text{Tc}$ -labelled nanocoll revealed normal lymphatic drainage in both arms. MRI of the left hand showed soft tissue oedema over the dorsum and extensor tenosynovitis (Fig. 2). The patient was started on etanercept (25 mg twice weekly), methotrexate (10 mg weekly), methylprednisolone (8 mg daily) and NSAID(s) therapy. After 1 year of therapy, the swelling and the pitting oedema of the left hand continued to be present.

## Discussion

Lymphoedema is an unusual extra-articular feature of RA and rarely has been described in PsA. According to our



**Fig. 2** MRI of the left hand: soft tissue oedema over the dorsum and extensor tenosynovitis

knowledge, only few patients with PsA and distal extremity swelling with pitting oedema have been reported in literature [2, 4–6]. In all cases, oedema predominantly affected the upper limbs with asymmetrical pattern and its onset was not directly connected with the severity of arthritis. Response to therapy and clinical outcome were different in relation to involved anatomical structures (lymphatic vessels or tenosynovial structures). Indeed, in some patients oedema and swelling were chronic and resistant to pharmacological therapy, whilst other patients responded to therapy with complete remission.

Similar clinical pictures were also reported in patients with RA [1, 10], even though in these patients oedema and swelling affected the upper limbs and, occasionally, the legs.

Many other clinical conditions may be associated with oedema and swelling described in patients with PsA and RA. In 1985, McCarty et al. [11] observed ten patients affected by remitting seronegative symmetrical synovitis with pitting oedema of the upper and/or lower limbs (RS3PE syndrome), which was considered to be secondary to vigorous tenosynovitis and synovitis of the underlying joints [9]. The clinical findings of RS3PE syndrome have also been observed in other rheumatic diseases such as polymyalgia rheumatica, giant cell arteritis, ankylosing spondylitis, late-onset undifferentiated spondyloarthropathies and acute sarcoidosis [9, 12–14].

Other forms of lymphoedema may be secondary to lymphatic damage or compression by mastectomy [15], tumours and infections (e.g. filariasis) [3, 9]. All these clinical pictures must be distinguished from lymphoedema associated with PsA.

In 1999, Salvarani et al. [9] described two cases of distal swelling with pitting oedema in PsA characterized by two

different lesions based on involved anatomic structures with different response to therapy and clinical outcome. In these two PsA patients, oedema and swelling were a direct consequence of involvement of the lymphatic vessels by the inflammatory process, as demonstrated by lymphoscintigraphy, which revealed an altered lymphatic drainage with an obstructed flow in the affected limb. It has been hypothesized that in these cases, the inflammatory products from the synovium are deposited in the adjacent lymphatic vessels, leading to lymphangitis and lymphatic obstruction [8]. The chronic lymphatic vascular damage can induce abnormalities of the lymphatic vessels (dilatation, lack of fenestration or dermal distal blind loops) with progressive and definitive damage and flow obstruction [3, 16, 17]. These anatomical damages could explain the usual resistance of oedema to therapy in patients with PsA.

On the contrary, cases reporting distal swelling with pitting oedema in PsA, characterized by inflammation of tenosynovial structures, confirmed by MRI, and normal lymphatic drainage, were characterized by a more favourable clinical outcome. In fact, these patients responded to psoriatic treatment with remission of the inflammatory process responsible for tenosynovitis and complete resolution of anatomical damage in the tenosynovial structures.

Our two cases support the evidence of two different lesions and pathogenetic mechanisms associated with distal swelling and pitting oedema in PsA. Whilst estimation of the involved anatomic structures by clinical examination was difficult, the type of lesion and the different pathogenetic mechanisms were clearly defined using MRI and lymphoscintigraphy.

In the first patient, the swelling and pitting oedema were associated with lymphatic obstruction, as shown by lymphoscintigraphy, and absence of tenosynovitis on MRI. In the second, the predominant involvement of the tenosynovial structures on MRI, with normal lymphatic flow on lymphoscintigraphy, may have been the cause of the arthritis with oedema. These different pathogenetic mechanisms were associated with different response to therapy.

In the first patient, oedema and swelling associated with lymphatic flow obstruction were resistant to therapy, according to the case reports of other authors. Nevertheless, in the second patient with prominent involvement of the tenosynovial structures, oedema did not respond to the anti-inflammatory and immunosuppressive therapy and to etanercept, a soluble TNF receptor fusion protein, which mediates its anti-inflammatory effects by binding to TNF $\alpha$  and preventing it from interacting with cell-surface receptors. On the contrary, in this patient, oedema and arthritis continued to be present.

Considering this abnormal response to therapy, we hypothesized that in PsA patients, pathogenesis of distal extremity swelling with pitting oedema is characterized by

other unknown factors, which influence the therapy and clinical outcome. Nevertheless, further studies are necessary to confirm this hypothesis.

## References

1. Griller B, Dequeker J (1987) Rheumatoid lymphedema. *J Rheumatol* 14:1095–1097
2. Bamji A (1991) Limb lymphoedema in rheumatoid arthritis. *Ann Rheum Dis* 50:407
3. Bohm M, Riemann B, Luger TA, Bosmann G (2000) Bilateral upper limb lymphoedema associated with psoriatic arthritis: a case report and review of the literature. *Br J Dermatol* 143:1297–1301
4. Kiely PDW, Joseph AEA, Mortimer PS, Bourke BE (1994) Upper limb lymphedema associated with polyarthritis of rheumatoid type. *J Rheumatol* 21:1043–1045
5. Mulherin DM, FitzGerald O, Bresnihan B (1993) Lymphedema of the upper limb in patients with psoriatic arthritis. *Semin Arth Rheum* 22:350–356
6. Salvarani C, Macchioni P, Veneziani M et al (1990) Upper limb lymphedema in psoriatic arthritis. *J Rheumatol* 17:273–274
7. Salvarani C (1995) Upper limb lymphedema in inflammatory arthropathy. *J Rheumatol* 22:230 (letter)
8. Yamamoto T, Nishioka K (2002) Psoriasis arthropathy and lymphedema. *J Dermatol* 29:812–814
9. Salvarani C, Cantini F, Olivieri I, Niccoli L, Senesi C, Macchioni L et al (1999) Distal extremity swelling with pitting oedema in psoriatic arthritis: evidence of 2 pathological mechanisms. *J Rheumatol* 26:1831–1834
10. Kiely PDW, Bland JM, Joseph AEA, Mortimer PS, Bourke BE (1995) Upper limb lymphatic function in inflammatory arthritis. *J Rheumatol* 22:214–217
11. McCarty DJ, O'Duffy DI, Pearson L, Hunter IB (1985) Remitting seronegative symmetrical synovitis with pitting edema. *JAMA* 254:2763–2767
12. Cantini F, Niccoli L, Olivieri I et al (1997) Remitting distal lower extremity swelling with pitting oedema in acute sarcoidosis. *Ann Rheum Dis* 56:566 (letter)
13. Olivieri I, Padula A, Pierro A, Favaro L, Oranges GS, Ferri S (1995) Late-onset undifferentiated seronegative spondyloarthropathy. *J Rheumatol* 22:899–903
14. Salvarani C, Gabriel S, Hunder GG (1996) Distal extremity swelling with pitting edema in polymyalgia rheumatica. *Arthritis Rheum* 39:73–80
15. Stanton AWB, Levick JR, Mortimer PS (1996) Current puzzles presented by postmastectomy oedema (breast cancer related lymphoedema). *Vasc Med* 1:213–225
16. Braun-Falco O, Christopher E (1974) Structural aspects of initial psoriatic lesions. *Arch Dermatol Forsch* 251:95–110
17. Braverman IM, Yen A (1974) Microcirculation in psoriatic skin. *J Invest Dermatol* 62:493–502