



HAL
open science

Novel surgical technique for insertion of pleuroperitoneal shunts for bilateral chylous effusions in ex preterm infant at term corrected age

Vimal Vasu, Chinwendu Ude, Vinit Shah, Eric Lim, Andrew Bush

► **To cite this version:**

Vimal Vasu, Chinwendu Ude, Vinit Shah, Eric Lim, Andrew Bush. Novel surgical technique for insertion of pleuroperitoneal shunts for bilateral chylous effusions in ex preterm infant at term corrected age. *Pediatric Pulmonology*, 2010, 45 (8), pp.840. 10.1002/ppul.21258 . hal-00552426

HAL Id: hal-00552426

<https://hal.science/hal-00552426>

Submitted on 6 Jan 2011

HAL is a multi-disciplinary open access archive for the deposit and dissemination of scientific research documents, whether they are published or not. The documents may come from teaching and research institutions in France or abroad, or from public or private research centers.

L'archive ouverte pluridisciplinaire **HAL**, est destinée au dépôt et à la diffusion de documents scientifiques de niveau recherche, publiés ou non, émanant des établissements d'enseignement et de recherche français ou étrangers, des laboratoires publics ou privés.



Novel surgical technique for insertion of pleuroperitoneal shunts for bilateral chylous effusions in ex preterm infant at term corrected age

Journal:	<i>Pediatric Pulmonology</i>
Manuscript ID:	PPUL-09-0389.R2
Wiley - Manuscript type:	Case Report
Date Submitted by the Author:	01-Mar-2010
Complete List of Authors:	Vasu, Vimal; William Harvey Hospital, Child Health Ude, Chinwendu; William Harvey Hospital, Child Health Shah, Vinit; William Harvey Hospital, Child Health; William Harvey Hospital, Child Health Lim, Eric; Royal Brompton Hospital, Thoracic Surgery Bush, Andrew; Royal Brompton Hospital, Paediatric Respiratory Medicine
Keywords:	chylothorax, neonatal, pleuroperitoneal, shunt



1
2
3 **Novel surgical technique for insertion of pleuroperitoneal shunts for**
4 **bilateral chylous effusions in ex preterm infant at term corrected age**
5
6
7

8
9 **Vasu V¹, Ude C¹, Shah V¹, Lim E², Bush A³**
10
11

12 **¹Department of Child Health, William Harvey Hospital, Kennington Road,**
13 **Ashford, Kent, TN24 0LZ**
14
15

16
17
18 **³Department of Thoracic Surgery, Royal Brompton Hospital, Sydney**
19 **Street, London, SW3 6NP**
20
21

22
23
24 **³Department of Paediatric Respiratory Medicine, Royal Brompton**
25 **Hospital, Sydney Street, London, SW3 6NP**
26
27
28
29
30
31
32
33
34
35
36

37 **Correspondence to: Vimal Vasu**
38
39

40
41 **Department of Child Health, William Harvey Hospital, Kennington Road,**
42 **Ashford, Kent, TN24 0LZ**
43
44
45

46
47 **Tel: 01233 633331 (ext 84224)**
48
49

50
51 **Fax: 01233 616139**
52
53

54 **Email: vimal.vasu@ekht.nhs.uk**
55
56
57
58
59
60

Summary

Neonatal chylothorax is a relatively uncommon condition. Here we describe the case of an extremely preterm infant with bilateral chylous effusions which were resistant to conventional medical management and were ultimately managed with the insertion of pleuroperitoneal shunts using a novel surgical technique. Subsequently the infant recovered and the shunts could be removed. We report this case to highlight that such shunts can be inserted even in tiny preterm infants with minimally invasive techniques, and be extremely successful in managing chylothorax, pending spontaneous recovery.

Keywords

Chylothorax, neonatal, pleuroperitoneal, shunt

Introduction

Chylothorax in the neonatal period can be congenital or acquired. It can lead to severe respiratory compromise, depletion of immune plasma proteins and lymphocytes, and contribute to a malnourished state. The aetiology of iatrogenic cases include surgical trauma to the thoracic duct and catheter related superior vena cava (SVC) obstruction¹. Medical management is often complex and prolonged and may involve some or all of the following strategies; respiratory support, external tube drainage of effusions, the use of medium chain triglyceride (MCT) feeds, parenteral nutrition support and octreotide². Conventionally, surgical intervention is reserved for complex cases or where medical management has failed. Strategies include thoracic duct ligation, mechanical pleurodesis, application of fibrin glue and insertion of bilateral pleuroperitoneal shunts³.

With informed parental consent for publication, here we describe an extremely preterm male infant who presented with respiratory distress almost completely dependent on respiratory support, and facial and upper limb oedema as a result of central venous catheter (CVC) related SVC thrombosis and resultant bilateral chylothoraces that were resistant to conventional medical management. The patient was severely ill, with an ongoing need for ventilation and multiple thoracocenteses, leading to malnutrition, an immunocompromised state, and poor somatic and brain growth. Progress was made only after insertion of pleuroperitoneal shunts.

Case Report

An 865 gram, 26⁺¹ week gestation male infant was born by emergency Caesarean section in view of fetal decelerations in the context of chorioamnionitis, and was transferred to the neonatal unit at the William Harvey Hospital on the first day of life.

He required conventional ventilation for respiratory distress syndrome for 14 days and was then extubated to nasal continuous positive pressure (CPAP). Parenteral nutrition was commenced on the first day of life via a peripheral venous line. A 2 French central venous catheter (CVC) was sited in the left basilic vein on day 3 (tip in left axillary/subclavian junction). This was removed on day 14 because of a suspected extravasation injury. Subsequently, a 1 French CVC was sited in the right saphenous vein on day 16 (tip at femoral/inferior vena cava junction) and removed on day 22. Enteral feeds were commenced on day 2 with maternal milk. Attainment of full enteral feeds was only achieved by day 22 because of probable necrotizing enterocolitis. The infant was transferred back to his local neonatal unit on day 22 for on going management. He was re-referred on day 60 (post menstrual age 34⁺⁴ weeks) because of difficulty in weaning from CPAP and head and upper body oedema. Figure 1 shows chest radiographs on the day of birth and at time of re-referral.

1
2
3 In view of the clinical suspicion of a chylous effusion, a chest drain was
4 inserted into the left hemithorax. Subsequent imaging demonstrated bilateral
5 effusions. Aspirated pleural fluid was milky in appearance with a triglyceride
6 level of 3.4mmol/L (>1.1mmol/L diagnostic of chyle). Microscopy and culture
7 revealed 1+ leucocytes and no organisms. No cell count was performed.
8
9 Echocardiogram demonstrated a structurally normal heart and thrombotic
10 SVC obstruction (Figure 2), and enoxaparin therapy was commenced.
11
12 Surgical thrombectomy was considered, but rejected as too high risk a
13 procedure. Over the following two months the effusions persisted bilaterally
14 and intercostal drain fluid losses averaged around 50ml/kg/day, despite use of
15 an MCT formula milk (Monogen), trials of Octreotide (4 micrograms/kg/dose
16 every 6 hours) and exclusive parenteral feeding. The infant required
17 numerous intercostal chest drain insertions, remained ventilator dependent
18 with high peak inspiratory pressures and oxygen requirements, developed
19 Pneumococcal septicaemia and meningitis (day 83) and became profoundly
20 malnourished. In view of failure of expectant management, at 5 weeks
21 corrected gestational age he was subsequently transferred to the Royal
22 Brompton Hospital for surgical insertion of pleuroperitoneal shunts (Figure 3).
23
24 His weight at the time of the procedure was 2.5kg. This was achieved using
25 novel procedure, a single incision thoracoscopic technique with improvised
26 paediatric laparoscopic ports in the chest and a paediatric bronchoscope as a
27 means to obtain direct visualization and breakdown of any loculations within
28 the thoracic cavity. Low tidal volume hand ventilation was used during port
29 insertion to facilitate visualization as the lung was not isolated. The shunts
30 were adult sized pleuroperitoneal shunts as no paediatric equivalents have
31
32
33
34
35
36
37
38
39
40
41
42
43
44
45
46
47
48
49
50
51
52
53
54
55
56
57
58
59
60

1
2
3 been manufactured. Each shunt is made as a complete unit, without Y-
4 connection option (for single abdominal catheter placement). The shunts were
5 placed into the abdominal cavity under direct vision through incisions in the
6 anterior abdominal wall, and sharp dissection through the peritoneum lifted via
7 mosquito forceps to reduce the risk of injury to any intra-abdominal organs.
8
9 The length of the abdominal tail (15.5 Fr) of the shunt was cut to size by visual
10 estimation of the length required to reach the pelvis. At operation multiple
11 intrapleural loculi were noted. Post operatively, the pump chamber was
12 cleared every hour (i.e. a few pumps until there was no further positive
13 pressure in the chamber). The postoperative drainage of the thoracic cavity
14 was uneventful, except for occasional leaking of chyle from the abdominal
15 incision sites. After three weeks, the chylous effusions resolved
16 spontaneously and the shunts could be removed. A tracheostomy was
17 inserted because of ongoing need for ventilation due to chronic lung disease
18 of prematurity.
19
20
21
22
23
24
25
26
27
28
29
30
31
32
33
34
35
36
37
38

39
40 The patient was discharged at a corrected age of 10 Months with night time
41 BiPAP via his tracheostomy. He has had no further chylous effusions.
42
43
44
45
46
47
48
49
50
51
52
53
54
55
56
57
58
59
60

Discussion

Optimal management of the preterm infant with acquired bilateral chylothoraces resistant to conventional medical therapy remains a huge challenge. The aetiology in our patient was presumed to be CVC related SVC thrombosis. Chylothoraces following SVC occlusion have been demonstrated in experimentally⁴. There is a single case report of an infant with thrombosis at the confluence of the left subclavian vein and internal jugular vein occluding the orifice of the thoracic duct resulting in bilateral chylothoraces⁵. Our patient developed chylothorax at about 6 weeks of life, around 4 weeks after removal of his indwelling CVC. The SVC thrombus lead to upper body venous hypertension and severe facial and neck oedema, and was presumably the cause of the bilateral chylous effusions. There is a rich lymphatic network in the pleura which drains into the thoracic duct via the right lymphatic duct. The thoracic duct drains into the SVC via the internal jugular vein. Obstruction to lymphatic drainage at the base of the neck combined with unusual communications between the thoracic and other mediastinal nodes with resultant secondary lymphangectasia and incompetence of lymphatic valves may permit chylous reflux into the lungs⁶.

Our patient was initially managed medically. His course was characterized by extreme haemodynamic and ventilator instability, malnutrition and secondary immune deficiency, which led to invasive pneumococcal infection and ongoing need for high levels of positive pressure ventilation. We were reluctant to intervene surgically in such a small immature infant, but eventually an innovative and relatively non-invasive procedure was performed, which led to

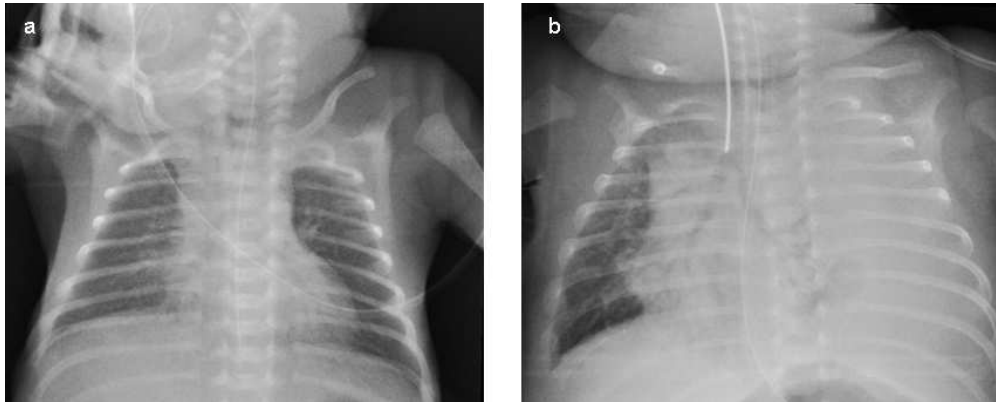
1
2
3 the child's condition becoming stabilized, allowing complete resolution of the
4
5 effusions with time. With retrospect, earlier surgical intervention may have
6
7 saved this child considerable morbidity. However, the diagnosis of neonatal
8
9 chylothorax secondary to SVC thrombus in preterm infants is rare. Therefore,
10
11 objective assessment of the efficacy of any interventions is difficult and is
12
13 currently limited to clinical experience and case series publications. A register
14
15 allowing for reporting of this rare condition may be one strategy which would
16
17 allow better definition of incidence, aetiology, effective interventions and
18
19 outcomes.
20
21
22
23
24

25
26 In summary, we report a novel surgical procedure which allowed drainage of
27
28 bilateral chylous effusions in a small sick infant, in order to encourage earlier
29
30 consideration of this procedure in future patients.
31
32
33
34
35
36
37
38
39
40
41
42
43
44
45
46
47
48
49
50
51
52
53
54
55
56
57
58
59
60

Review

References

1. Curci MR, Dibbins AW. Bilateral chylothorax in a newborn. *J Pediatr Surg*. 1980 Oct;15(5):663-5.
2. Siu SL, Lam DS. Spontaneous neonatal chylothorax treated with octreotide. *J Paediatr Child Health*. 2006 Jan-Feb;42(1-2):65-7.
3. Engum SA, Rescoria FJ, West KW, Scherer III LR, Grosfield JL. The use of pleuroperitoneal shunts in the management of persistent chylothorax in infants. *Journal of Pediatric Surgery*, Vol 34, No 2 (February), 1999: pp286-290.
4. Azizkhan RG, Canfield J, Alford BA, Rodgers BM. Pleuroperitoneal shunts in the management of neonatal chylothorax. *J Pediatr Surg* 1983 Dec; 18(6): 842-50.
5. Hinckley M. Thoracic duct thrombosis with fatal chylothorax caused by a long venous catheter. *English Journal of Medicine* 280:95, 1969
6. Maier HC. The Pulmonary and pleural lymphatics: A challenge to the thoracic explorer. *Journal of Thoracic CV Surgery*, 52 :155



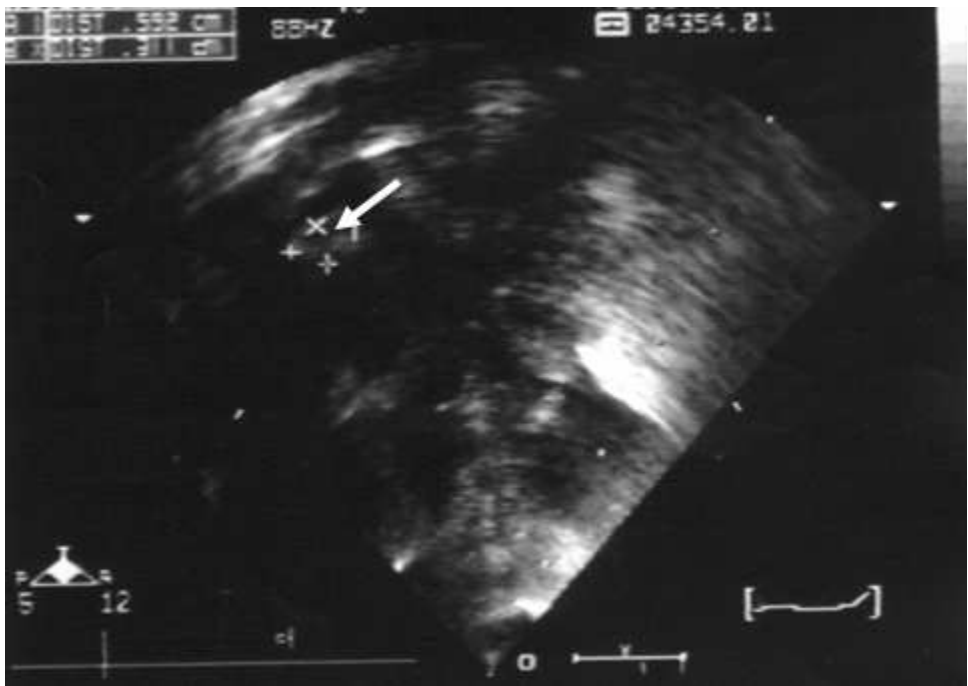Chest Radiographs a) on day of birth b) on presentation with chylous effusion at 2 months of age

225x90mm (96 x 96 DPI)

Peer Review

1
2
3
4
5
6
7
8
9
10
11
12
13
14
15
16
17
18
19
20
21
22
23
24
25
26
27
28
29
30
31
32
33
34
35
36
37
38
39
40
41
42
43
44
45
46
47
48
49
50
51
52
53
54
55
56
57
58
59
60

1
2
3
4
5
6
7
8
9
10
11
12
13
14
15
16
17
18
19
20
21
22
23
24
25
26
27
28
29
30
31
32
33
34
35
36
37
38
39
40
41
42
43
44
45
46
47
48
49
50
51
52
53
54
55
56
57
58
59
60

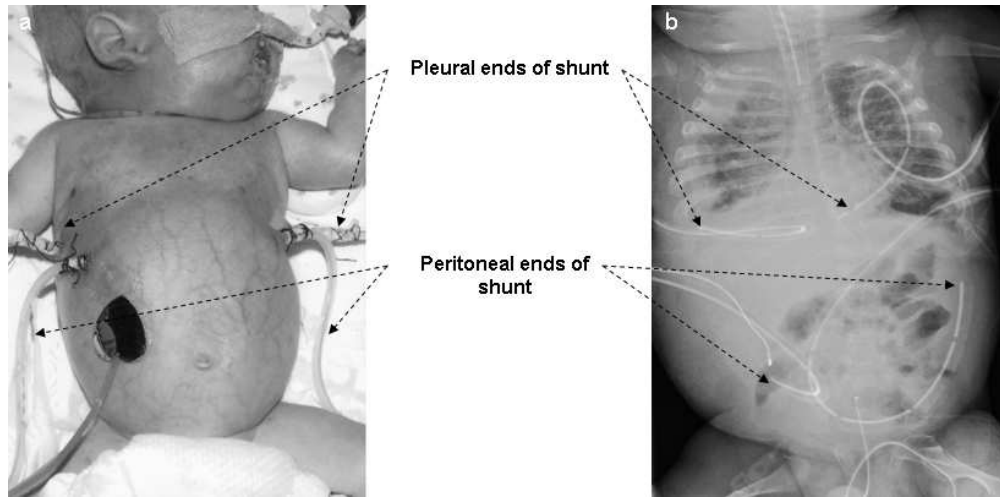


Four chamber echocardiogram view demonstrating SVC thrombus (arrow)

127x89mm (96 x 96 DPI)

Review

1
2
3
4
5
6
7
8
9
10
11
12
13
14
15
16
17
18
19
20
21
22
23
24
25
26
27
28
29
30
31
32
33
34
35
36
37
38
39
40
41
42
43
44
45
46
47
48
49
50
51
52
53
54
55
56
57
58
59
60



a) Pleuroperitoneal shunts in situ b) Chest radiograph indicating position of pleural and peritoneal ends of shunts

216x106mm (96 x 96 DPI)

er Review