



HAL
open science

BORTEZOMIB EFFECTIVENESS IN ONE PATIENT WITH ACQUIRED VON WILLEBRAND SYNDROME ASSOCIATED TO MONOCLONAL GAMMOPATHY OF UNDETERMINED SIGNIFICANCE

Mario Ojeda Uribe, Claudine Caron, Nathalie Itzhar-Baikian, Agathe Debliquis

► **To cite this version:**

Mario Ojeda Uribe, Claudine Caron, Nathalie Itzhar-Baikian, Agathe Debliquis. BORTEZOMIB EFFECTIVENESS IN ONE PATIENT WITH ACQUIRED VON WILLEBRAND SYNDROME ASSOCIATED TO MONOCLONAL GAMMOPATHY OF UNDETERMINED SIGNIFICANCE. *American Journal of Hematology*, 2010, 10.1002/ajh.21692 . hal-00552313

HAL Id: hal-00552313

<https://hal.science/hal-00552313>

Submitted on 6 Jan 2011

HAL is a multi-disciplinary open access archive for the deposit and dissemination of scientific research documents, whether they are published or not. The documents may come from teaching and research institutions in France or abroad, or from public or private research centers.

L'archive ouverte pluridisciplinaire **HAL**, est destinée au dépôt et à la diffusion de documents scientifiques de niveau recherche, publiés ou non, émanant des établissements d'enseignement et de recherche français ou étrangers, des laboratoires publics ou privés.



**BORTEZOMIB EFFECTIVENESS IN ONE PATIENT WITH
ACQUIRED VON WILLEBRAND SYNDROME ASSOCIATED TO
MONOCLONAL GAMMOPATHY OF UNDETERMINED
SIGNIFICANCE**

Journal:	<i>American Journal of Hematology</i>
Manuscript ID:	AJH-10-0072.R1
Wiley - Manuscript type:	Correspondence
Date Submitted by the Author:	08-Feb-2010
Complete List of Authors:	Ojeda Uribe, Mario; Hôpital e Muller, Hematology Caron, Claudine; Centre Hospitalier Universitaire de Lille, Pôle d'Hématologie-Hémostase Itzhar-Baikian, Nathalie; Centre Hospitalier Universitaire, Hôpital Antoine Béclère, Assistance Publique-Hopitaux de Paris, Centre de Référence sur la Maladie de Willebrand, Service d'Hématologie Biologique Debliquis, Agathe; Hôpital Emile Muller, Hématologie-Biologique
Keywords:	von Willebrand Disease, Chemotherapy, Immunology, Hemorrhagic Disorders and Therapies, Acquired coagulation disorders



1
2
3
4
5
6
7
8
9
10
11
12

BORTEZOMIB EFFECTIVENESS IN ONE PATIENT WITH ACQUIRED VON WILLEBRAND SYNDROME ASSOCIATED TO MONOCLONAL GAMMOPATHY OF UNDETERMINED SIGNIFICANCE

13 Mario Ojeda-Uribe¹, M.D., Claudine Caron², M.D., Nathalie Itzhar-Baikian³ M.D., Agathe
14 Debliquis⁴, Pharm. D.
15
16
17

18 ¹Service d'Hématologie Clinique, Hôpital E Muller, Mulhouse, France

19 ²Pôle d'Hématologie-Hémostase, Centre Hospitalier Universitaire de Lille, France

20 ³Centre de Référence sur la Maladie de Willebrand, Assistance Publique-Hopitaux de Paris, Hôpital
21 Antoine Bécère, Clamart
22
23

24 ⁴Laboratoire d'Hématologie, Hôpital E Muller, Mulhouse, France.
25
26
27
28
29

30 **Number of words:** 829

31
32 **Number of Figures:** 1
33
34
35
36

37 **Corresponding author:**

38 Dr Mario Ojeda-Uribe, M.D.

39 Service d'Hématologie Clinique - Hôpital E Muller

40 20 avenue du Dr Laënnec, 68070 Mulhouse Cedex, France
41
42
43
44
45
46

47 Phone: 33-3-8964 7755 - Fax : 33-3-8961 7747
48

49 e-mail: ojedam@evhr.net
50
51
52

53 **Running head:** Successful Bortezomib in AVWS
54

55 **Key words:** AVWS, Bortezomib, Rituximab, MGUS
56
57
58
59
60

To the Editor,

Acquired von Willebrand Syndrome (AVWS) is a rare heterogeneous bleeding condition associated with several disorders, including monoclonal gammopathy of undetermined significance (MGUS) [1-3]. Successful therapy of the underlying disorder can lead to the improvement of AVWS [1]. Regarding the association of AVWS and MGUS, no long-term successful therapy has been reported. Indeed, most of these patients are not treated on a curative goal [1]. In a few single cases anti-CD20 targeted therapy (Rituximab) has shown no efficacy [4, 5]. We describe herein the case of a patient with AVWS accompanied by MGUS who was successfully treated with the proteasome inhibitor Bortezomib after failure of Rituximab. A 60-year-old man with poliomyelitis sequelae in one of his legs was referred to our hospital with a post-traumatic gluteal hematoma. The hypothesis of AVWS was based on the following findings: the patient had no personal and no family history of constitutional hemorrhagic disease ; a prolonged activated partial thromboplastin time (aPTT): ratio 2.4 (PTTa, Stago, Asnieres, France) ; a severe decrease of VWF ristocetin cofactor activity (VWF:RCo) :<1 % (VWF reagent, Siemens, Marburg, Germany) ; a low level of VWF antigen (VWF:Ag): 6 % (LIATEST, Stago) and FVIII: 6 % (plasma deficient FVIII reagent, Stago) ; a prolonged platelet occlusion time with collagen-epinephrine and collagen-ADP (240 and 275 seconds respectively) (PFA-100, Siemens, Marburg, Germany). An inhibitor effect was observed by in vitro functional assay (PTT-LA, Stago) with a measured Rosner index of 22. This inhibitory activity was considered as unspecific because no lupus anticoagulant (STACLOT DRVV, Stago) and no specific anti-FVIII inhibitor were detected ; the lack of response to the desmopressin test ; a high VWF-propeptide (VWFpp) (171%) (measured by fluorometry on Fluoroskan, Thermo, Waltham, USA ; using the VWF reagent & propeptide assay, GTI diagnostics, Waukesha, USA) associated to a high VWFpp/VWF:Ag ratio (23.6), which was in favor of an increased clearance of mature VWF. In contrast, plasma distribution of VWF multimers assessed by 0.1% sodium dodecyl sulphate-1.5% agarose electrophoresis showed a normal profile and no specific anti-VWF auto-antibodies were detected by ELISA [6].

1
2 The diagnosis of MGUS was based on the lack of evidence of autoimmune/connective tissue
3 disorders, multiple myeloma or other lymphoproliferative diseases: presence of a monoclonal IgG-
4 *kappa* on serum immunofixation ; normal serum immunoglobulin levels (g/L: IgG 9.2 ; IgA 1.3 ;
5 *kappa* on serum immunofixation ; normal serum immunoglobulin levels (g/L: IgG 9.2 ; IgA 1.3 ;
6 IgM 0.6) ; normal serum creatinine, BUN and calcium values ; negative antinuclear antibodies ; no
7 lymph-node enlargement on physical examination ; no bone lytic lesions on skeleton X-ray ;
8 normality of CT-scan of the thorax, abdomen and pelvis ; marrow smear examination showing 8
9 percent of morphologic and immunophenotypic normal plasma cells (CD38^{pos}CD138^{pos}CD20^{neg}),
10 but with a specific clonal IgH rearrangement (VH3-JH) detected by PCR. Bone marrow aspiration
11 was performed only **once** an improvement of VWF:RCo (32 %) was achieved after high-dose
12 immunoglobulin intravenous infusion (HD-IVIG) (1g/kg of body weight (b.w.)/day during 2 days,
13 followed by 0.5g/kg b.w. for 1 day. **This improvement** was transient lasting several days. Because
14 of some efficacy observed in patients with acquired hemophilia A and other autoimmune disorders,
15 we started anti-CD20 targeted therapy by weekly Rituximab at the dose of 375 mg/m². A peripheral
16 blood deep B-cell depletion was rapidly achieved after the first Rituximab administration, but six
17 cycles after we did not observe any improvement in AVWS. A new post-traumatic knee hematoma
18 leads us to prescribe HD-VWF:VIII F concentrate (Wilstart, LFB, Cortaboef, France) without
19 efficacy. Again, HD-IVIG induced a transient higher VWF:RCo activity, which allowed the
20 evacuation of the hematoma. Afterwards, we started an every 21-day cycle 2nd-line therapy
21 including Bortezomib 1.3 mg/m²/day plus dexamethasone 40 mg/day (both on days 1,4,8,11). After
22 3 cycles a dramatic improvement in all the parameters of AVWS was observed (Figure 1),
23 including a normal value of VWFpp (116%) and VWFpp/VWF ratio (1.45). This time, the
24 mutimeric distribution of VWF showed a slight excess (16% ; normal 9 %) of high-molecular-
25 weight multimers (> 15 mers). Concerning MGUS a new marrow assessment (this time without any
26 prophylactic therapy) showed 1% of normal plasma cells. The monoclonal IgG-*kappa* and the
27 clonal IgH rearrangement were undetected (Figure 1). **At this time serum free *kappa* and *lambda***
28 **chain concentrations were respectively of 6.1 mg/L (Normal values: 3.3-19.4 mg/L) and 2.4**
29
30
31
32
33
34
35
36
37
38
39
40
41
42
43
44
45
46
47
48
49
50
51
52
53
54
55
56
57
58
59
60

1
2 **mg/L (Normal values: 5.7-26.3 mg/L) ; the k/ λ ratio was 2.5 (Normal values: 0.26 –1.65).** In
3
4 total 6 cycles of bortezomib-dexamethasone were administered. Several weeks later, a new
5
6 biological assessment confirmed the favorable results observed after the first three cycles. **Serum**
7
8 **free *kappa* and *lambda* chain concentrations were respectively of 8.1 mg/L and 6.9 mg/L ; the**
9
10 **k/ λ ratio was 1.17.** The clinical and hematologic tolerance of this treatment was good, except a
11
12 mild hypo-gammaglobulinemia (5 g/L). The follow-up is still short, but after 7 months the patient is
13
14 still considered in remission of both AVWS and MGUS. Even if this favorable outcome after
15
16 bortezomib would be interpreted with caution because it has been observed in this one case, it could
17
18 represent an interesting therapeutic alternative in this clinical setting.
19
20
21
22
23
24
25
26
27
28
29
30
31
32
33
34
35
36
37
38
39
40
41
42
43
44
45
46
47
48
49
50
51
52
53
54
55
56
57
58
59
60

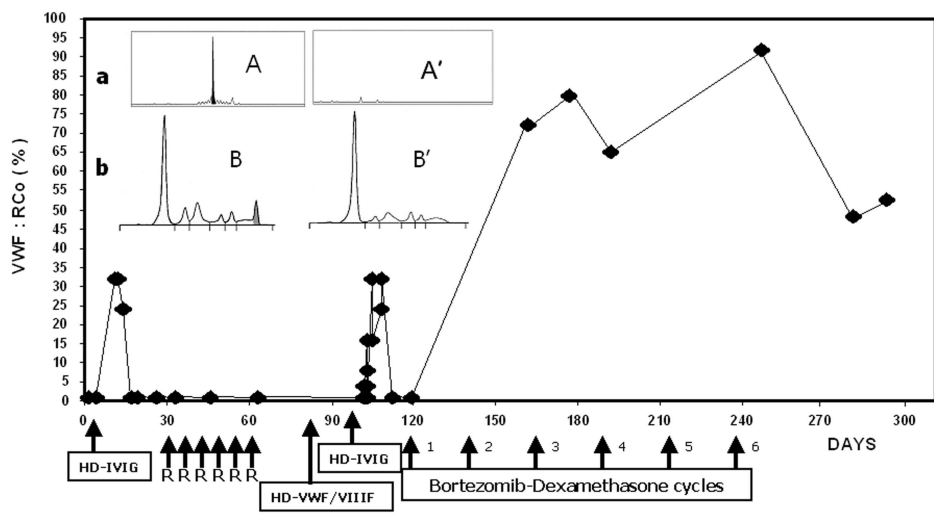
REFERENCES

1. Mohri H. Acquired von Willebrand Syndrome: Features and management. *Am J Hematol* 2006;81:616-623
2. Kumar S, Pruthi RK, Nichols W. Acquired von Willebrand Disease. *Mayo Clin Proc* 2002;77:181-187
3. Kyle RA, Themeau TM, Rajkumar SV et al. Prevalence of monoclonal gammopathy of undetermined significance. *N Engl J Med* 2006;354:1362-9
4. Grimaldi D, Bartolucci P, Gouault-Hellmann M et al. Rituximab failure in a patient with monoclonal gammopathy of undetermined significance (MGUS)-associated acquired von Willebrand syndrome. *Thromb Haemost* 2008;99:782-783
5. Mazoyer E, Fain O, Dhote R, Laurian Y. Is rituximab effective in acquired von Willebrand syndrome? *Br J Haematol* 2009;144:967-8
6. Siaka C, Rugeri L, Caron C, Goudemand J. A new ELISA assay for diagnosis of acquired von Willebrand Syndrome. *Haemophilia* 2003;9:303-308

FIGURES LEGENDS

1
2
3
4
5
6
7 **Figure 1.** ◆ VWF:RCo activity (%) following different therapies: HD-IVIG allowed a significant
8 transient improvement ; Rituximab (R) and HD-VWF/VIIIIF concentrate showed no effect ; normal
9 values were observed after 3 cycles of bortezomib-dexamethasone. Detectable and undetectable
10 clonal IgH rearrangement (**a**) and serum monoclonal IgG-*kappa* (**b**) before (A, B) and after (A', B')
11
12
13
14
15
16
17 3 cycles of bortezomib-dexamethasone, respectively.
18
19
20
21
22
23
24
25
26
27
28
29
30
31
32
33
34
35
36
37
38
39
40
41
42
43
44
45
46
47
48
49
50
51
52
53
54
55
56
57
58
59
60

1
2
3
4
5
6
7
8
9
10
11
12
13
14
15
16
17
18
19
20
21
22
23
24
25
26
27
28
29
30
31
32
33
34
35
36
37
38
39
40
41
42
43
44
45
46
47
48
49
50
51
52
53
54
55
56
57
58
59
60



254x190mm (300 x 300 DPI)

Review