



HAL
open science

Function, size and form of the gastrointestinal tract of the collared (Linnaeus 1758) and white-lipped peccary (Link 1795)

Angela Schwarm, Sylvia Ortmann, Wolfram Rietschel, Ragnar Kühne, Gudrun Wibbelt, Marcus Clauss

► To cite this version:

Angela Schwarm, Sylvia Ortmann, Wolfram Rietschel, Ragnar Kühne, Gudrun Wibbelt, et al.. Function, size and form of the gastrointestinal tract of the collared (Linnaeus 1758) and white-lipped peccary (Link 1795). *European Journal of Wildlife Research*, 2009, 56 (4), pp.569-576. 10.1007/s10344-009-0348-2 . hal-00547632

HAL Id: hal-00547632

<https://hal.science/hal-00547632>

Submitted on 17 Dec 2010

HAL is a multi-disciplinary open access archive for the deposit and dissemination of scientific research documents, whether they are published or not. The documents may come from teaching and research institutions in France or abroad, or from public or private research centers.

L'archive ouverte pluridisciplinaire **HAL**, est destinée au dépôt et à la diffusion de documents scientifiques de niveau recherche, publiés ou non, émanant des établissements d'enseignement et de recherche français ou étrangers, des laboratoires publics ou privés.

Function, size and form of the gastrointestinal tract of the collared *Pecari tajacu* (Linnaeus 1758) and white-lipped peccary *Tayassu pecari* (Link 1795)

Angela Schwarm · Sylvia Ortmann ·
Wolfram Rietschel · Ragnar Kühne · Gudrun Wibbelt ·
Marcus Clauss

Received: 26 June 2009 / Revised: 20 October 2009 / Accepted: 25 November 2009 / Published online: 17 December 2009
© Springer-Verlag 2009

Abstract The peccary digestive tract is characterised by an elaborate forestomach. In order to further characterise the digestive function of peccaries, we report body mass, digestive organ mass, content mass of the gastrointestinal tract compartments and their length and width, as well as liver, parotis and mandibular gland mass. Our data on eleven collared and four white-lipped peccaries suggest that peccaries have a small relative stomach volume compared to other

foregut fermenters, which implies a comparatively lower fermentative capacity and thus forage digestibility. The forestomach could enable peccaries to deal, in conjunction with their large parotis glands, with certain plant toxins (e.g. oxalic acid). The finding of sand being trapped in the forestomach blindsacs could indicate a disadvantage of the peccary forestomach design. The relevance of the forestomach to peccaries remains enigmatic.

Communicated by F.-J. Kaup

A. Schwarm · S. Ortmann · G. Wibbelt
Leibniz Institute for Zoo and Wildlife Research (IZW),
Alfred-Kowalke Str. 17,
10315 Berlin, Germany

A. Schwarm (✉)
Department of Nutritional Physiology “Oskar Kellner”,
Research Institute for the Biology of Farm Animals (FBN),
Wilhelm-Stahl-Allee 2,
18196 Dummerstorf, Germany
e-mail: schwarm@fbn-dummerstorf.de

A. Schwarm
Freie Universität Berlin,
14195 Berlin, Germany

W. Rietschel
Zoological and Botanical Garden of Stuttgart,
70342 Stuttgart, Germany

R. Kühne
Zoological Garden of Berlin,
10787 Berlin, Germany

M. Clauss
Clinic for Zoo Animals, Exotic Pets and Wildlife,
Vetsuisse Faculty, University of Zurich,
8057 Zurich, Switzerland
e-mail: mclauss@vetclinics.uzh.ch

Keywords Digestive anatomy · Digestive morphometry ·
Foregut fermenter · Forestomach · Tayassuidae

Introduction

Peccaries are foregut fermenters. Their digestive tract is characterised by an elaborate forestomach in which the diet, mainly fruits, leaves, stems, roots and flowers, is fermented (Barreto et al. 1997; Altrichter et al. 2001). Thus, peccaries differ in the digestive anatomy from their next relatives, the monogastric suids. The peccary stomach consists of a gastric pouch, an anterior and upper blindsac and a glandular compartment (Sowls 1978; Langer 1978). The forestomach—constituting 85% of the volume of the total stomach (Langer 1988, p 169)—is the primary site of fermentation (Lochmiller et al. 1986), and effective fibre digestibility has been demonstrated in peccaries (Gallagher et al. 1984; Comizzoli et al. 1997; Nogueira-Filho 2005). However, when comparing different species, fibre and dry matter digestibility in peccaries is not higher than in monogastric wild suids (Clauss et al. 2008). Dyson (1969), cited in Sowls (1997, p77), on the other hand, concluded that “fiber digestion in the collared peccary is higher than in most nonruminants but considerably lower

than in true ruminants". This conclusion was based on volatile fatty acid concentrations in the stomach content of hay-fed captive collared peccaries being lower than in hay-fed cattle from the literature. A direct comparison to monogastric herbivores seems to be lacking. Although collared peccaries resemble grazing ruminants regarding the total concentration of volatile fatty acids in stomach contents (reviewed by Sowls 1997, p 76–80), the acetate to propionate ratio is lower in the former (1.5–2.5 vs. 3.1–3.7 on pasture only). Carl and Brown (1983) found the concentration of protozoa to be similar in peccary and ruminants. Most of the protozoa found were of the genus *Entodinia*, primarily starch digesters, typically found in browsing ruminants (compiled by Clauss and Lechner-Doll 2001). With respect to passage time, the ability of the peccary forestomach to slow down ingesta passage is less obvious than in ruminants. Average solid ingesta passage through the peccary gut is 35 h compared to 60 h in ruminants on similar dry matter intakes (50 g/(kg^{0.75} day), Schwarm et al. 2009). In comparison to other non-ruminating foregut fermenters, particle MRT in peccaries is similar to kangaroos and shorter than in hippos (Schwarm et al. 2008, 2009). Whether food passage time through the gastrointestinal tract of peccaries is longer than in the monogastric suids has, to our knowledge, not been investigated.

The anatomy of the peccary gastro-intestinal tract as well as the type of diet found in stomach contents is well reported by (Langer 1978, 1979, 1988). However, the stomach and intestine content mass were not assessed so far, whereas Lochmiller et al. (1986) measured the mass of the emptied gut in collared peccary. In order to further

characterise the digestive function of peccaries (sensu Comizzoli et al. 1997), we report body mass, digestive organ mass, content mass of the gastrointestinal tract compartments and their length and width, as well as liver, parotis and mandibular gland mass in this study. For comparison, we report parameters of the non-ruminating foregut fermenter pygmy hippo (*Hexaprotodon liberiensis*), the monogastric hindgut-fermenter wild boar (*Sus scrofa*) and the babyrousa (*Babyrousa babyrussa*) which has been described as an intermediate form between a foregut-fermenter and a monogastric hindgut fermenter due to a pronounced stomach fornix with a prominent microbial flora (Langer 1988; MacDonald et al. 2008).

Materials and methods

Eleven collared peccaries and four white-lipped peccaries were clinically healthy but culled for population control at the zoo. Up to their death, animals had displayed a normal food intake and had been fed with a mixed diet consisting of fruits, vegetables, cooked potatoes, grass or hay supplemented three times a week with chicks, eggs, grains and concentrates. Total body mass (including blood) and net body mass (excluding blood) were measured by weighing the animals with an analogue scale. In two collared peccaries, only net body mass could be assessed. In these animals, total body mass was calculated by applying a correction factor of 5% difference, i.e. the average difference between both weights determined in the other animals. Liver mass was assessed in all animals. Parotis and mandibular total gland mass were measured

Fig. 1 Gastrointestinal tract of: **a** collared peccary (*Pecari tajacu*). The scale bar represents 5 cm. Drawing by J. Peter, Zurich. **b** wild boar (*S. scrofa*, Stevens and Hume 1995)

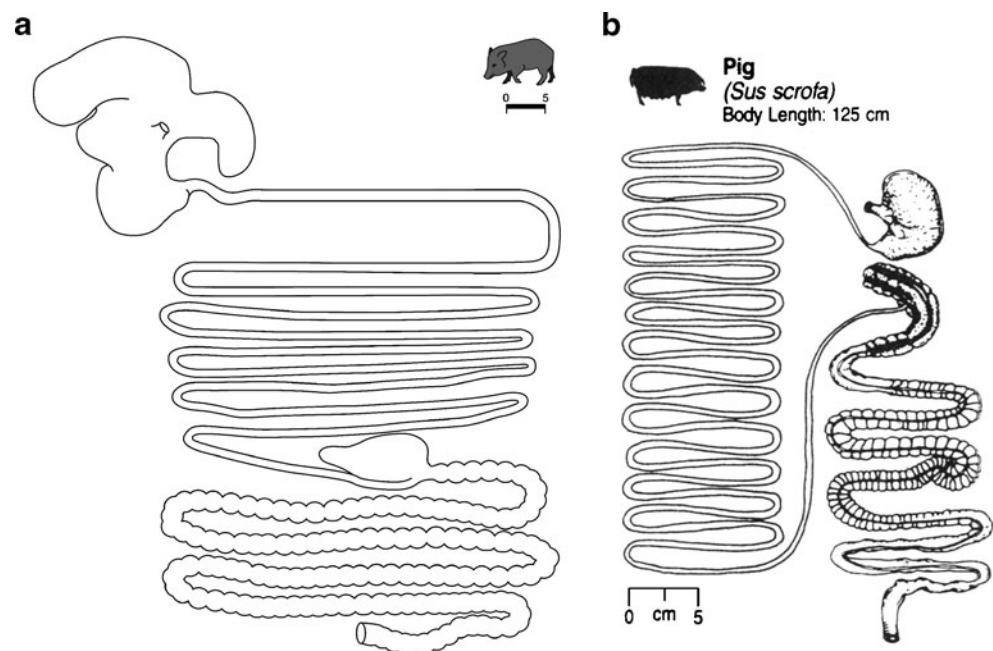


Table 1 Body mass (kg), liver mass (g), parotis and mandibular gland mass (g, bilateral), as well as content and organ mass (g) of different sections of the digestive tract of collared peccary (*Pecari tajacu*, $n=5$ –11) and white-lipped (*Tayassu pecari*, $n=0$ –4) peccary (both sexes) and the respective length and width measurements (cm)

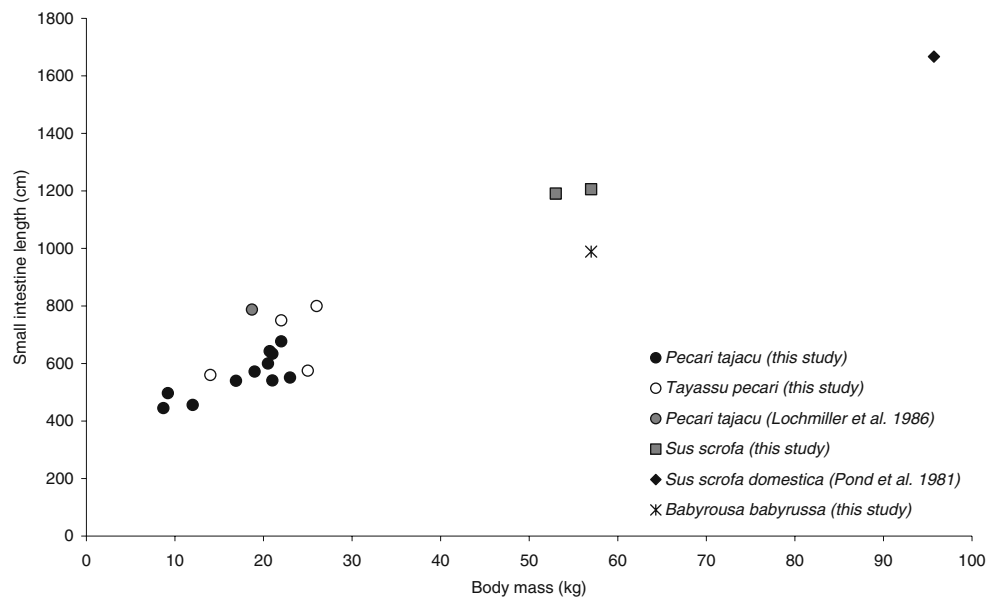
| Mean \pm SD | Collared peccary | | White-lipped peccary | | <i>P</i> (<i>U</i> test) | Pygmy hippo | Babyrousa | Wild boar |
|-----------------------------------|----------------------|-----------------|-----------------------|-----------------|---------------------------|---------------------------------|----------------------------|-------------------|
| | <i>Pecari tajacu</i> | | <i>Tayassu pecari</i> | | | | | |
| | <i>n</i> | | <i>n</i> | | | <i>Hexaprotodon liberiensis</i> | <i>Babyrousa babyrussa</i> | <i>Sus scrofa</i> |
| | | | | | | <i>n</i> =3 | <i>n</i> =1 | <i>n</i> =2 |
| Body mass (kg) | 11 | 18 \pm 5 | 4 | 22 \pm 5 | 0.105 | 220 \pm 7 | 57 | 55 \pm 3 |
| Liver mass (g) | 8 | 286 \pm 102 | 3 | 511 \pm 176 | 0.133 | n.d. | n.d. | n.d. |
| Parotis mass (g) | 5 | 97 \pm 10 | | n.d. | | n.d. | n.d. | n.d. |
| Mandibularis mass (g) | 5 | 11 \pm 2 | | n.d. | | n.d. | n.d. | n.d. |
| Content mass (g) | | | | | | | | |
| Stomach | 11 | 1,256 \pm 447 | 4 | 1,233 \pm 369 | 0.753 | 15,500 \pm 2,060 | 2,781 | 190 \pm 85 |
| Small intestine | 11 | 110 \pm 58 | 4 | 272 \pm 113 | 0.018 | 1,423 \pm 582 | 701 | 543 \pm 46 |
| Caecum | 11 | 91 \pm 47 | 4 | 84 \pm 35 | 0.971 | n.e. | 43 | n.d. |
| Large intestine | 11 | 354 \pm 124 | 4 | 728 \pm 465 | 0.177 | 1,953 \pm 941 | 722 | 2,300 \pm 304 |
| Organ mass (g) | | | | | | | | |
| Stomach | 11 | 349 \pm 85 | 4 | 339 \pm 51 | 0.753 | 6,677 \pm 1,111 | 1,419 | 363 \pm 4 |
| Small intestine | 11 | 130 \pm 36 | 4 | 299 \pm 107 | 0.003 | 2,273 \pm 211 | 715 | 635 \pm 7 |
| Caecum | 11 | 14 \pm 5 | 4 | 37 \pm 43 | 0.587 | n.e. | 41 | n.d. |
| Large intestine | 11 | 152 \pm 50 | 4 | 253 \pm 57 | 0.018 | 827 \pm 103 | 604 | 773 \pm 53 |
| Length (cm) | | | | | | | | |
| Blindsac 1 major curvature | 11 | 23 \pm 6 | 3 | 23 \pm 2 | 0.747 | n.d. | n.d. | n.e. |
| Blindsac 1 minor curvature | 8 | 14 \pm 4 | 3 | 10 \pm 4 | 0.127 | n.d. | n.d. | n.e. |
| Blindsac 1 longitudinal | | n.d. | | n.d. | | 60 (<i>n</i> =1) | 32 | n.e. |
| Blindsac 2 major curvature | 11 | 20 \pm 5 | 3 | 19 \pm 1 | 0.989 | n.d. | n.d. | n.e. |
| Blindsac 2 minor curvature | 8 | 8 \pm 2 | 2 | 8 \pm 1 | 0.133 | n.d. | n.d. | n.e. |
| Blindsac 2 longitudinal | | n.d. | | n.d. | | 55 (<i>n</i> =1) | 14 | n.e. |
| Connecting chamber | 11 | 20 \pm 4 | 3 | 18 \pm 2 | 0.409 | 69 (<i>n</i> =1) | 29 | n.e. |
| Glandular stomach major curvature | 11 | 26 \pm 4 | 4 | 32 \pm 5 | 0.050 | n.d. | n.d. | n.d. |
| Glandular stomach minor curvature | 8 | 10 \pm 2 | 3 | 12 \pm 3 | 0.255 | n.d. | n.d. | n.d. |
| Glandular stomach longitudinal | | n.d. | | n.d. | | 45 (<i>n</i> =1) | 34 | 45 \pm 7 |
| Small intestine | 11 | 560 \pm 75 | 4 | 671 \pm 122 | 0.104 | 1,892 \pm 90 | 989 | 1,199 \pm 11 |
| Caecum | 11 | 12 \pm 3 | 3 | 12 \pm 2 | 0.978 | n.e. | 12 | 21 \pm 1 |
| Large intestine | 11 | 211 \pm 45 | 4 | 339 \pm 27 | 0.001 | 288 \pm 15 | 399 | 450 \pm 60 |
| Width (cm) | | | | | | | | |
| Blindsac 1 | 8 | 6 \pm 1 | 3 | 6 \pm 1 | 0.909 | 15 (<i>n</i> =1) | 23 | n.e. |
| Blindsac 2 | 8 | 4 \pm 1 | 3 | 6 \pm 1 | 0.006 | 15 (<i>n</i> =1) | 10 | n.e. |
| Connecting chamber | 8 | 14 \pm 3 | 3 | 13 \pm 4 | 0.970 | n.d. | 17 | n.e. |
| Glandular stomach | 8 | 9 \pm 1 | 3 | 8 \pm 2 | 0.784 | n.d. | 24 | 15 \pm 1 |
| Small intestine | 5 | 1 \pm 0 | 2 | 2 \pm 1 | 0.048 | n.d. | n.d. | n.d. |
| Caecum | 10 | 6 \pm 2 | 2 | 7 \pm 1 | 0.970 | n.e. | n.d. | n.d. |
| Large intestine | 6 | 3 \pm 1 | 2 | 3 \pm 1 | 0.214 | n.d. | n.d. | n.d. |

Mean \pm SD and *P* value of the comparison between collared and white-lipped peccaries (Mann–Whitney *U* analysis). And data of pygmy hippos (*Hexaprotodon liberiensis*, $n=1$ –3), babyrousa (*Babyrousa babyrussa*, $n=1$) and wild boar (*Sus scrofa*, $n=2$) on some parameters

n.d. not determined; *n.e.* not existent

Terminology according to Langer (1988): Blindsac 1: in peccary "anterior blindsac", in babyrousa "fornix ventriculi", in hippo "visceral blindsac"; Blindsac 2: in peccary "upper blindsac", in babyrousa "diverticulum ventriculi", in hippo "parietal blindsac"; connecting chamber: in peccary "gastric pouch", in babyrousa "corpus ventriculi"

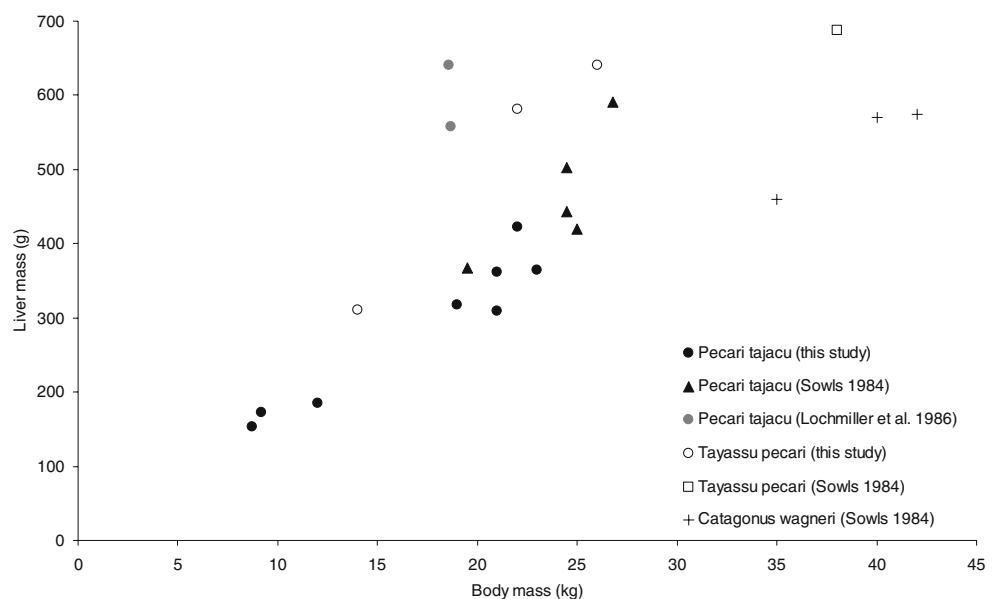
Fig. 2 Relationship between body mass (kilograms) and small intestine length (centimetres) in collared peccary (*Pecari tajacu*, this study and Lochmiller et al. 1986, mean of $n=16$), white-lipped peccary (*Tayassu pecari*, this study), wild boar (*S. scrofa*, this study), domestic pig (*S. scrofa domestica*, Pond et al. 1981, mean of $n=12$) and babiroussa (*B. babyrussa*, this study). Spearman correlation coefficients (SCC): collared peccary, $n=11$, $SCC=0.74$, $p=0.010$



in five collared peccaries. At necropsy, all adhering mesenteries were removed from the gastrointestinal tract. The stomach, small intestine, caecum and colon were weighed individually with and without content to the nearest gramme with a portable digital scale. The length of the individual segments of the gastrointestinal tract was measured without stretching to the nearest half centimetre using a linear scale. For the measurement of the gastric pouch and the intestine segments, the shortest distance was applied. For the blindsac and the glandular stomach, two measurements are specified: the major and the minor curvature. Photographs were taken to facilitate the preparation of anatomical drawings. The Mann–Whitney U test was used for comparisons between peccaries because the sample size of 4 (white-lipped peccaries) was too small to

test for normality. Three pygmy hippos (*H. liberiensis*), one babiroussa (*B. babyrussa*) and two wild boars (*S. scrofa*) were sampled opportunistically at different institutions (zoo, circus, wildlife park). These animals were either geriatric or were culled for population control. See Wings et al. (2008) for details of one pygmy hippo. Two pygmy hippos were consistently fed a diet of lucerne hay, mixed fruits and vegetables and herbivore pellets. The diet of the other pygmy hippo is not known; however, a similar feeding regime is assumed. The babiroussa was fed the same diet as the peccaries, supplemented with salad. The wild boars were fed a diet of vegetables, potatoes and a compound feed. Total body mass, gastrointestinal tract content and organ mass of the mature animals were assessed as described for peccary. The length of the

Fig. 3 Relationship between body mass (kilograms) and liver mass (grams) in collared peccary (*Pecari tajacu*, Sowls 1984; Lochmiller et al. 1986 mean of $n=2 \times 8$; this study), white-lipped peccary (*Tayassu pecari*, Sowls 1984; this study) and chacoan peccary (*Catagonus wagneri*, Sowls 1984)



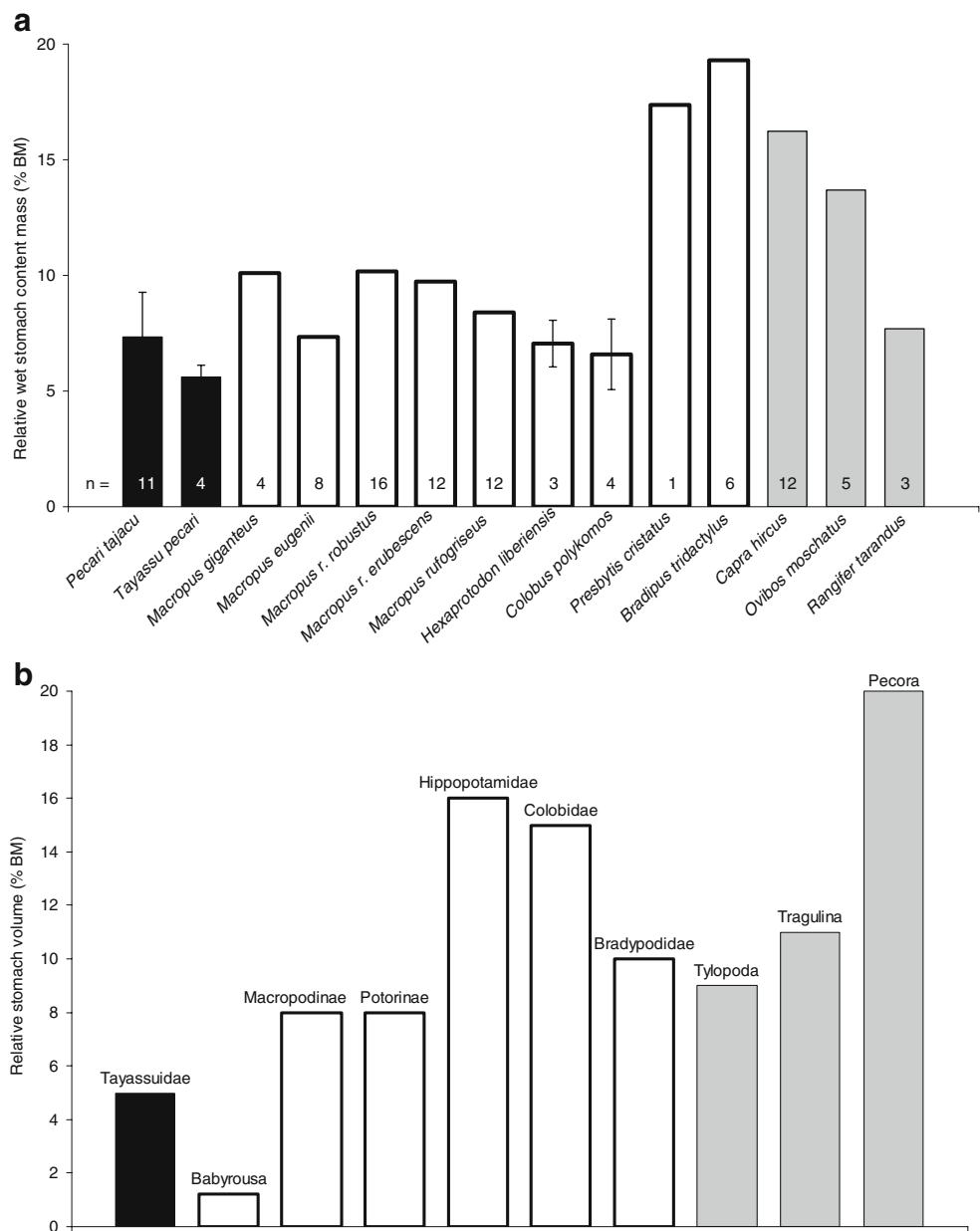
stomach compartment was measured along the central longitudinal axis.

Results

The animals were considered to be in a good body condition with no incidence of obesity (e.g. presence of mesenterial fat). The drawing of the gastrointestinal tract of a collared peccary is given in Fig. 1. The studied collared peccaries had a body mass (BM) range of 9 to 23 kg, the white-lipped peccaries of 14 to 26 kg. Body mass of collared and white-lipped peccaries did not differ significantly (Table 1); therefore, absolute parameters of the

gastro-intestinal tracts of both species could be compared. The stomach content and organ mass were of comparable size (Table 1). However, white-lipped peccaries had significantly longer large intestines than collared peccaries. And the small and large intestine organ mass was significantly higher in white-lipped than in collared peccaries. In collared peccaries, the small intestine length was related to body mass (Fig. 2). In some peccaries, a considerable amount of sand was trapped in both blindsacs of the forestomach and in the caecum (which contributes to the content mass reported in Table 1). The results for the pygmy hippos, babyrousa and wild boar are also given in Table 1. The large intestine wet content mass of the monogastric hindgut-fermenting suid, the wild boar, was

Fig. 4 a Relative full-stomach wet content mass (% body mass, BM) of different foregut fermenters. Data collection from Bauchop and Martucci (1968), *Presbytis cristatus*, leaf monkey, Pi (1973) and Kay et al. (1976), *Colobus polykomos*, Western black and white colobus monkey, Hume (1977) and Munn et al. (2009) *Macropus rufogriseus*, red-necked wallaby, Warner (1981) and Munn et al. (2006) *Macropus eugenii*, Tammar wallaby, Dellow and Hume (1982) *Macropus giganteus*, Eastern grey kangaroo, Freudenberger (1992) *Macropus robustus robustus*, Eastern wallaroo, *M. r. erubescens*, common wallaroo, *Capra hircus*, feral goat, Foley et al. (1995) *Bradipus tridactylus*, pale-throated sloth, Knott et al. (2004) *Rangifer tarandus*, reindeer, *Ovibos moschatus*, muskox, and this study (*Pecari tajacu*, collared peccary, *Tayassu pecari*, white-lipped peccary, *H. liberiensis*, pygmy hippo). **b** Relative full-stomach volume (% BM) of different foregut fermenters. Data from Langer (1988) p 403



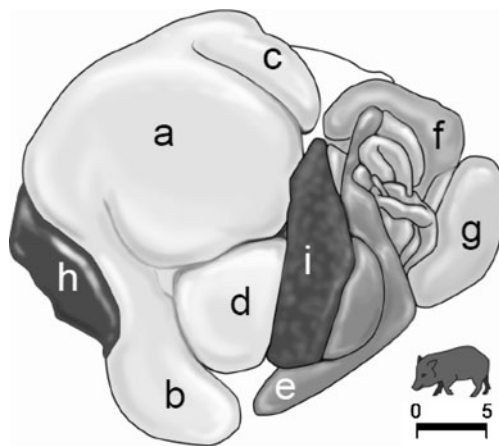


Fig. 5 In situ left lateral view of the stomach and associated visceral organs of collared peccary (*Pecari tajacu*): **a** gastric pouch, **b** anterior and **c** upper blindsac, **d** glandular stomach, **e** caecum, **f** rectum, **g** bladder, **h** liver, **i** spleen. The scale bar represents 5 cm. Note the position of the anterior and upper blindsac (“sedimentation trap”). Drawing by J. Peter, Zurich

not distinctively higher than that of the peccaries (4.2% of body mass, BM, $n=2$, vs. collared peccary $2.2\pm 0.8\%$ BM and white-lipped peccary $3.1\pm 1.5\%$ BM).

Discussion

Conclusions based on results obtained from zoo animals must be considered with caution due to differences in diet, feeding behaviour and activity between captive and free-ranging animals. Lochmiller et al. (1986) studied internal organ and gut mass and intestine length in 16 free-ranging adult collared peccaries. Although the collared peccaries of our study had a comparable average body mass (18 vs. 19 kg), we observed differences in organ mass and size. Stomach organ mass was lower in the collared peccaries of our study (349 vs. 411 g), and the small intestine was shorter (560 vs. 782 cm, Fig. 2) as well as the large intestine. Relative liver mass was also lower in the collared peccaries of our study than in the study of Lochmiller et al. (1986) (Fig. 3; on average 1.6% vs. 3.2% of total body mass). A possible explanation for the differences in relative liver mass could be a different diet: Lochmiller et al. (1986) collected the animals on the Chaparral Wildlife Management Area in Texas where they presumably fed on natural vegetation, and thus presumably on a diet with higher content of secondary plant compounds and fibre than in this zoo-based study. For browsing and grazing ruminants, it has been reported that liver size may in part reflect ability to detoxify plant secondary compounds (McArthur et al. 1991). An effect of body condition on the difference in relative liver mass is unlikely, since peccaries from both studies were lean. The peccaries in the study of Lochmiller

et al. (1986), which were shot in March in Southern Texas, showed an average absolute visceral fat depot of 110 g or about 0.6% of body mass. Although body fat was not quantified in this study, mesenteric fat was only present in one of ten collared peccaries. Indication was found that free-ranging collared peccaries ingest a diet with higher lignin content and lower digestibility than their captive counterparts (extrapolated from faecal content; Schwarm et al. 2005). A high fibre diet potentially necessitates abrasion resistance (thicker stomach walls), and it can be speculated that a longer small intestine compensates for lower digestibility. Similarly, Tyson (1683) reported the small intestine length of one individual collared peccary of unknown origin and body mass to be 822 cm and the colon length 274 cm; again, these measurements are longer than the ones from our animals.

In peccaries, the average relative wet-stomach content mass is lower compared to foregut fermenting ruminants and the majority of the kangaroos (Fig. 4a). Similarly, comparing relative stomach volumes (% BM) of different foregut fermenters collated by Langer (1988) (not explained whether stomach organ mass is included), peccaries have the smallest relative stomach of all foregut fermenters together with babyrousa (Fig. 4b). Evidently, the fermentative capacity is lower in peccaries than in other foregut fermenters. Surprisingly, the large intestine wet content mass of the monogastric, hindgut-fermenting suid, the wild boar, was not distinctively higher than that of our peccaries, suggesting that the digestive capacity of the hindgut does not vary much between these species.

The observation that a considerable amount of sand was trapped in both blindsacs of the forestomach and in the caecum of some individuals is in accord with the literature. Free-ranging peccaries have been observed to consume soil (geophagy) for postulated resources as e.g. mineral elements (Bravo et al. 2008); however, the proportion of soil to fermentable material in these animals are not known. Langer (1979) found in captive peccaries a relative increase

Table 2 Average relative parotid gland mass ($\text{g}/\text{kg}^{0.75}$) of different foregut fermenters from the literature

| Species | n | $\text{g}/\text{kg}^{0.75}$ | Source |
|------------------------------|----|-----------------------------|---------------------|
| <i>Pecari tajacu</i> | 11 | 11.3 | This study |
| <i>Alces alces</i> | 6 | 4.9 | Hofmann et al. 2008 |
| <i>Bison bison</i> | 2 | 3.5 | Hofmann et al. 2008 |
| <i>Wallabia bicolor</i> | 3 | 2.6 | Lentle et al. 2002 |
| <i>Colobus guereza</i> | 2 | 2.5 | Kay et al. 1976 |
| <i>Dama dama</i> | 7 | 2.2 | Hofmann et al. 2008 |
| <i>Petrogale penicillata</i> | 6 | 2.0 | Lentle et al. 2002 |
| <i>Macropus eugenii</i> | 44 | 1.5 | Lentle et al. 2002 |
| <i>Macropus parma</i> | 55 | 1.1 | Lentle et al. 2002 |

in sand from the gastric pouch to the pylorus and further to the caecum and rectum and stated “the increase in sand concentration relative to dry matter content is connected with a decrease in plant material, very likely because of microbial degradation of this material”. This author also observed a lot of sand in the forestomach blindsacs of peccaries in Arizona (P. Langer pers. comm.) which were wild-caught and kept in open-air enclosures some time before death. In the pygmy hippos, with access to an enclosure with natural soil, sand and gravel were also found in the forestomach blindsacs (reported in Wings et al. 2008). These findings indicate that the forestomach blindsacs of both peccaries and hippopotami will function as sedimentation traps, as suggested by Clauss et al. (2004) based on the finding that small (potentially denser) particles are sometimes—not always—retained for a longer time in the forestomach of hippos (Schwarm et al. 2008) and peccaries (Schwarm et al. 2009) than larger (potentially less dense) particles. However, such a differential excretion of particles was not observed in these species with the same consistency as, for example, the differential excretion of different-sized particles from the forestomach of ruminants (Schwarm et al. 2008; 2009), which gives rise to the suspicion that a “sedimentation trap” action might not be the primary function of the forestomach blindsacs in hippos and peccaries.

In contrast, the finding of sand being trapped in these blindsacs could, alternatively, indicate a disadvantage of the peccary (and hippopotamus) forestomach design, facilitating the accumulation of dense, indigestible material. During necropsy, we had the impression that in some animals, the sand could no longer be excreted easily because the blindsacs were stretched by the sand’s weight, causing a concomitant constriction of the blindsac opening (Fig. 5, anterior blind sac). This could be a speculative reason for the fact that this particular forestomach design is not at the base of large species radiations. Among the non-ruminant foregut fermenters, the sloth is the only other representative whose forestomach might trap dense, sedimenting material (Clauss 2004). However, due to their arboreal habits, sloths are unlikely to ingest relevant amounts of dense sand or grit, in contrast to hippos or peccaries.

The collared peccaries of this study had, with $11.3 \text{ g/kg}^{0.75}$ ($n=11$), heavier relative parotis glands than other foregut fermenters (see Table 2, e.g. in *Alces alces* $4.9 \text{ g/kg}^{0.75}$ (Hofmann et al. 2008) and in *Macropus parma* $1.1 \text{ g/kg}^{0.75}$ (Lentle et al. 2002)). Assuming that salivary gland mass, salivary flow rate and the degree of separation of the liquid and solid phase of digesta are interrelated, peccaries compared to colobine monkeys actually excrete fluids faster than particles (Schwarm et al. 2009). However, both macropods and ruminants achieve distinctively higher degrees of separation between fluid and particle passage (Schwarm et al. 2009), which suggests that, similar to the

suspicion of Hofmann et al. (2008), salivary gland size is not directly linked to saliva flow. The reason for the large size of the peccary’s parotis gland, potentially linked to the production of secondary plant compounds (e.g. oxalic acid), remains to be elucidated.

The small relative stomach and thus forestomach volume of peccaries imply a lower fermentative capacity and thus forage digestibility compared to other foregut fermenters. This, again, gives rise to the question about the relevance of a foregut to peccaries. The diet of peccaries is as diverse as the habitat they occupy—arid US southwest and dense tropical rain forests of South America. In the former habitat, peccaries consume primarily grasses and roots; in the latter habitat, they are more frugivorous (Sowls 1997). The forestomach could enable peccaries to maintain on a fibre-rich diet or deal, in conjunction with their large parotis glands, with certain plant toxins. For example, the breakdown of oxalic acid in the forestomach could be important. This toxin can be found in greater quantities in prickly pear (*Opuntia* sp.), which can constitute an “exclusive food” of peccaries in the desert areas and causes at worst renal failure (Sowls 1984, p 58 for peccaries; e.g. Allison et al. 1977, for ruminants). The relevance of the forestomach to peccaries remains enigmatic.

Acknowledgements We thank E. Zollinger, N. Brunclik, O.M. Jurado, P. Zerbe, K. Grahl, T. Dörflein, U. Fritzmann, W. Hildebrandt, Z. Mezo and their colleagues for logistical help and their aid during dissection and J. Peter from the Institute of Veterinary Anatomy of the University of Zurich for producing the illustrations of the gastrointestinal tracts. This study was supported by grants from the Freie Universität Berlin (NaFöG) to AS and the German Science Foundation (DFG) to SO (OR 86/1-1). Sincere thanks to two anonymous reviewers and J. Axtner and S. Albrecht for valuable comments.

References

- Allison MJ, Littlelidge ET, James LF (1977) Changes in ruminal oxalate degradation rates associated with adaptation to oxalate ingestion. *J Anim Sci* 45:1173–1179
- Altrichter M, Carrillo E, Sáenz J, Fuller T (2001) White-lipped peccary (*Tayassu pecari*, Artiodactyla: Tayassuidae) diet and fruit availability in a Costa Rican rain forest. *Rev Biol Trop* 49:1183–1192
- Barreto G, Hernandez O, Ojasti J (1997) Diet of peccaries (*Tayassu tajacu* and *T. pecari*) in a dry forest of Venezuela. *J Zool* 241:279–284
- Bauchop T, Martucci R (1968) Ruminant-like digestion of the langur monkey. *Science* 161:698–700
- Bravo A, Harms KE, Stevens RD, Emmons LH (2008) Collpas: Activity hotspots for frugivorous bats (Phyllostomidae) in the Peruvian Amazon. *Biotropica* 40:203–210
- Carl G, Brown R (1983) Protozoa in the forestomach of the Collared Peccary (*Tayassu tajacu*). *J Mammal* 64:709
- Clauss M (2004) A potential interplay of posture, digestive anatomy, density of ingesta and gravity in mammalian herbivores, or why sloths do not rest upside down. *Mamm Rev* 34:241–245

- Clauss M, Lechner-Doll M (2001) Differences in selective reticulo-ruminal particle retention as a key factor in ruminant diversification. *Oecologia* 129:321–327
- Clauss M, Schwarm A, Ortmann S, Alber D, Flach E, Kühne R, Hummel J, Streich WJ, Hofer H (2004) Intake, ingesta retention, particle size distribution and digestibility in the hippopotamidae. *Comp Biochem Physiol* 139:449–459
- Clauss M, Nijboer J, Loermans J, Roth T, Van der Kuilen J, Beynen A (2008) Comparative digestion studies in wild suids at Rotterdam zoo. *Zoo Biol* 27:305–319
- Comizzoli P, Peiniau J, Dutertre C, Planquette P, Aumaitre A (1997) Digestive utilization of concentrated and fibrous diets by two peccary species (*Tayassu peccari*, *Tayassu tajacu*) raised in French Guyana. *Anim Feed Sci Technol* 64:215–226
- Dellow D, Hume I (1982) Studies on the nutrition of macropodine marsupials. IV. Digestion in the stomach and the intestine of *Macropus giganteus*, *Thylogale thetis* and *Macropus eugenii*. *Aust J Zool* 30:767–777
- Foley WJ, von Engelhardt W, Charles-Dominique P (1995) The passage of digesta, particle size, and in vitro fermentation rate in the three-toed sloth. *J Zool* 236:681–696
- Freudenberger D (1992) Gut capacity, functional allocation of gut volume and size distributions of digesta particles in two macropodid marsupials (*Macropus robustus robustus* and *M. r. erubescens*) and the feral goat (*Capra hircus*). *Aust J Zool* 40:551–561
- Gallagher J, Varner L, Grant W (1984) Nutrition of the collared peccary in south texas. *J Wildl Manage* 48:749–761
- Hofmann R, Streich W, Fickel J, Hummel J, Clauss M (2008) Convergent evolution in feeding types: salivary gland mass differences in wild ruminant species. *J Morphol* 269:240–257
- Hume I (1977) Production of volatile fatty acids in two species of wallaby and in sheep. *Comp Biochem Physiol* 56:299–304
- Kay R, Hoppe P, Maloij G (1976) Fermentative digestion of food in the colobus monkey, *Colobus polykomos*. *Specialia* 32:485–487
- Knott K, Barboza PS, Bowyer R, Blake J (2004) Nutritional development of feeding strategies in arctic ruminants: digestive morphometry of reindeer, *Rangifer tarandus*, and muskoxen, *Ovibos moschatus*. *Zoology* 107:315–333
- Langer P (1978) Anatomy of the stomach of the collared peccary, *Dicotyles tajacu*. *Z Säugetierkd* 43:42–59
- Langer P (1979) Adaptational significance of the forestomach of the collared peccary, *Dicotyles tajacu*. *Mammalia* 43:235–245
- Langer P (1988) The mammalian herbivore stomach. Gustav Fischer, Stuttgart
- Lentle R, Hume I, Kennedy M, Stafford K, Potter M, Springett B, Haslett S (2002) The histology and morphometrics of the major salivary glands of four species of wallabies (Marsupialia: Macropodidae) from Kawau Island, New Zealand. *J Zool* 257:403–410
- Lochmiller R, Hellgren E, Grant W (1986) Absolute and allometric relationships between internal morphology and body mass in the adult collared peccary, *Tayassu tajacu* (Tayassuidae). *Growth* 50:296–316
- MacDonald A, Mitchell S, Signorella A, Leus K (2008) Ultrastructural characterization of the epithelium that constitutes the cardiac gland epithelial 'honeycomb' in the stomach of the babirusa (*Babyrousa babyrousa*). *Anim Biol Pathol* 331:32–41
- McArthur C, Hagerman AE, Robbins CT (1991) Physiological strategies of mammalian herbivores against plant defenses. In: Palo R, Robbins C (eds) *Plant defenses against mammalian herbivory*. CRC, Boca Raton, pp 103–114
- Munn AJ, Banks P, Hume ID (2006) Digestive plasticity of the small intestine and the fermentative hindgut in a marsupial herbivore, the tammar wallaby (*Macropus eugenii*). *Aust J Zool* 54:287–291
- Munn AJ, Clissold F, Tarszisz E, Kimpton K, Dickman CR, Hume ID (2009) hindgut plasticity in wallabies fed hay either unchopped or ground and pelleted: fiber is not the only factor. *Physiol Biochem Zool* 82:270–279
- Nogueira-Filho S (2005) The effects of increasing levels of roughage on coefficients of nutrient digestibility in the collared peccary (*Tayassu tajacu*). *Anim Feed Sci Technol* 120:151–157
- Pi JS (1973) Contribution to the ecology of *Colobus polykomos satanas* (Waterhouse, 1838) of Rio Muni, Republic of Equatorial Guinea. *Folia Primat* 19:193–207
- Pond W, Yen J, Lindvall R, Hill D (1981) Dietary alfalfa meal for genetically obese and lean growing pigs: effect on body weight gain and on carcass and gastrointestinal tract measurements and blood metabolites. *J Anim Sci* 51:367–373
- Schwarm A, Ortmann S, Kühne R, Caspers B, Kelm D, Clauss M (2005) Comparative analysis of physical and chemical characteristics of faeces from free-ranging and captive collared peccaries (*Tayassu tajacu*). *Proceedings of the 9th Congress of the European Society of Veterinary and Comparative Nutrition, Grugliasco-To (Italy)*, p 103
- Schwarm A, Ortmann S, Wolf C, Streich WJ, Clauss M (2008) Excretion patterns of fluid and different sized particle passage markers in banteng (*Bos javanicus*) and pygmy hippopotamus (*Hexaprotodon liberiensis*): two functionally different foregut fermenters. *Comp Biochem Physiol* 150:32–39
- Schwarm A, Ortmann S, Wolf C, Streich WJ, Clauss M (2009) Passage marker excretion in red kangaroo (*Macropus rufus*), collared peccary (*Pecari tajacu*) and colobine monkeys (*Colobus angolensis*, *C. polykomos*, *Trachypithecus johnii*). *J Exp Zool A* 311:647–661
- Sowls LK (1978) Collared peccary. In: Schmidt JL, Gilbert DL (eds) *Big game of North America: ecology and management*. Stackpole, Harrisburg, pp 191–205
- Sowls LK (1984) *The peccaries*. The University of Arizona Press, Tucson
- Sowls LK (1997) *Javelinas and other peccaries: their biology, management, and use*, 2nd edn. Texas A&M University Press, College Station
- Stevens CE, Hume ID (1995) *Comparative physiology of the vertebrate digestive system*, 2nd edn. Cambridge University Press, Cambridge
- Tyson E (1683) *Tajacu seu aper Mexicanus moschiferus*, or the anatomy of the Mexico musk-hog, etc. *Philos Trans* 13:359–385
- Warner A (1981) The mean retention time of digesta markers in the gut of the Tammar, *Macropus eugenii*. *Aust J Zool* 29:759–771
- Wings O, Hatt J, Schwarm A, Clauss M (2008) Gastroliths in a pygmy hippopotamus (*Hexaprotodon liberiensis* Morton 1984). *Senckenb Biol* 88:345–348