



**HAL**  
open science

## Spread bow leg syndrome in ostrich (*Struthio camelus*) chicks aged 2-12 weeks

Ross Gordon Cooper, Khalid Mahrose, Mohammed El-Shafei

► **To cite this version:**

Ross Gordon Cooper, Khalid Mahrose, Mohammed El-Shafei. Spread bow leg syndrome in ostrich (*Struthio camelus*) chicks aged 2-12 weeks. *British Poultry Science*, 2008, 49 (01), pp.1-6. 10.1080/00071660701744257 . hal-00545323


**HAL Id: hal-00545323**

**<https://hal.science/hal-00545323>**

Submitted on 10 Dec 2010

**HAL** is a multi-disciplinary open access archive for the deposit and dissemination of scientific research documents, whether they are published or not. The documents may come from teaching and research institutions in France or abroad, or from public or private research centers.

L'archive ouverte pluridisciplinaire **HAL**, est destinée au dépôt et à la diffusion de documents scientifiques de niveau recherche, publiés ou non, émanant des établissements d'enseignement et de recherche français ou étrangers, des laboratoires publics ou privés.



**Spread bow leg syndrome in ostrich (*Struthio camelus*) chicks aged 2-12 weeks**

Journal:	<i>British Poultry Science</i>
Manuscript ID:	CBPS-2007-040.R1
Manuscript Type:	Original Manuscript
Date Submitted by the Author:	26-Mar-2007
Complete List of Authors:	Cooper, Ross; UCE Birmingham, Physiology MAHROSE, Khalid; Zagazig University, Poultry EL-SHAFEI, Mohammed; Gamal`s Farm for Ostriches, none
Keywords:	Disease, Growth, Ostrich, Physiology, Welfare



1  
2  
3  
4 **Spread bow leg syndrome in ostrich (*Struthio camelus*) chicks aged 2-12 weeks**  
5  
6  
7

8  
9 R.G. COOPER, K.M.A. MAHROSE<sup>1</sup> AND M. EL-SHAFEI<sup>2</sup>  
10

11 *Division of Physiology, UCE Birmingham, Perry Barr, Birmingham, England,*

12  
13  
14 <sup>1</sup>*Department of Poultry, Faculty of Agriculture, Zagazig University, Zagazig, Sharkia and*

15  
16 <sup>2</sup>*Gamal's Farm for Ostriches, Belbeis, Sharkia, Egypt.*  
17  
18  
19

20  
21 **Running title: Bow leg syndrome in ostriches**  
22  
23  
24  
25  
26  
27

28 Correspondence to Dr Ross Cooper, Division of Physiology, UCE Birmingham, Baker

29 Building, Room 701, Franchise Street, Perry Barr, Birmingham B42 2SU, U.K.

30  
31 Phone: 00441213316227. Fax: 00441213315498. E-mail: rgcooperuk@yahoo.com  
32  
33  
34

35 **Date of acceptance 15 August 2007**  
36  
37  
38  
39  
40  
41  
42  
43  
44  
45  
46  
47  
48  
49  
50  
51  
52  
53  
54  
55  
56  
57  
58  
59  
60

1  
2  
3  
4 **Abstract.** 1. The incidence of spread bow leg syndrome and associated pathology in 15  
5 ostrich chicks aged 2, 4, 8 and 12 weeks is reported. Measurements were made of hind  
6 limbs: femur plus tibiotarsus; tarsometatarsus; phalanx I, digit III; phalanx II, digit III plus  
7 phalanx III, digit III; and phalanx IV, digit III.  
8

9  
10  
11  
12  
13  
14 2. A run was constructed (6 x 1.7 m) and subdivided into 2 m sections and the time taken  
15 to traverse it was recorded. Measurements (cm) were made of the left and right footprints;  
16 the number of footprints and average stride length in 0 - 2, 3 - 4 and 5 - 6 m. Speed was  
17 calculated using distance run (m) divided by time taken (sec).  
18

19  
20  
21  
22  
23 3. The number of steps was greater in bow leg chicks aged 4 and 8 weeks by comparison  
24 with healthy birds. Stride length, however, was smaller in all age groups with bow leg.  
25 All speeds in bow leg chicks were lower than those in healthy birds, except for that  
26 recorded at 2m in chicks aged 2 weeks which did not differ markedly.  
27

28  
29  
30  
31  
32 4. In affected birds, feathers were sparse. Icterus was present. The tarsometatarsus was  
33 twisted, with severely inflamed joints, eroded distal ends, thickening of the cartilage and  
34 the presence of fibrous material surrounding the ligaments. Muscles in the hind limb were  
35 emaciated.  
36

37  
38  
39  
40  
41 5. The syndrome compromises the ability of chicks to keep up with adults in flocks, and  
42 may compromise their ability to escape predation.  
43  
44  
45  
46  
47  
48

## 49 INTRODUCTION

50  
51  
52  
53 The ostrich has specialised hind legs that minimise inertia through loss of muscle mass  
54 (Hildebrand, 1988), while lateral digits are reduced, allowing the bird to run at high speed.  
55  
56  
57 There are a variety of skeletal diseases, however, that severely impede this movement.  
58  
59  
60

1  
2  
3  
4 Cooper (2007) studied the effect of tibiotarsal rotation on stride in 14-month old ostriches.  
5  
6 Bow leg syndrome has been previously reported in ratites (Guittin, 1986; Chang *et al.*,  
7  
8 1988) and pathology is characterized by the bowing of leg bones either inward or outward.  
9  
10 Clinical signs include abnormal posture, lameness, unable to stand, trembling and  
11  
12 depression (Chang *et al.*, 1988). Bowing of the tarsometatarsus and thinning of compact  
13  
14 bone and sparse density of cancellous bone were observed. Post-mortem revealed sandy  
15  
16 pellets in the duodenum, a thickened hock joint, softening of the bone and thinning of  
17  
18 epiphyseal lines, plus defective mineralisation of osteoid bone. The condition may result  
19  
20 from an improper diet especially excess vitamin supplementation and rapid early growth  
21  
22 rates. Bow leg may result from deficiencies of calcium, manganese and niacin. There is no  
23  
24 suitable treatment other than to improve the diet and change the feeding programme.  
25  
26 Megamin® (Healthtech Laboratories, Centurion, South Africa) has been developed and  
27  
28 balanced to prevent bow leg syndrome in fast growing ostrich chicks. Personal  
29  
30 communications with farmers in South Africa indicated that although the condition exists,  
31  
32 it is uncommon and rarely reported in that country.  
33  
34  
35  
36  
37  
38  
39  
40

41 The aim of the present study was to examine the subtle pathological consequences  
42  
43 of bow leg syndrome in ostrich chicks and its adverse effects on locomotion. The purpose  
44  
45 of the gait analysis was to detect morphological and functional changes associated with the  
46  
47 disease.  
48  
49  
50

## 51 MATERIALS AND METHODS

### 52 Case history

1  
2  
3  
4 We studied the incidence of spread bow leg syndrome (ca. 20% pa) and associated  
5 pathology in ostrich chicks aged between 2-12 weeks on an ostrich farm 30 km north-west  
6 of Cairo in the Belbeis Desert, Egypt (31°E, 13°S). The annual rainfall is variable  
7 approximating 180 mm during winter mostly during the period December to January (van  
8 Achthoven *et al.*, 2004). Water is derived principally from the Nile from irrigation  
9 channels. The average ambient temperature throughout the study was 38°C and the relative  
10 humidity 40-50%. Chicks were allowed access to food and water *ad libitum*.  
11  
12  
13  
14  
15  
16  
17  
18  
19

### 20 21 **Feed analysis**

22 Inductively-coupled plasma (ICP) optical emission spectrometry (Perkin-Elmer, Norwalk,  
23 CT), as described by Boss and Fredeen (1997), was used to measure calcium and  
24 phosphorus content in the feed. Gross energy was analysed by adiabatic bomb calorimetry  
25 (IKA® Works, Inc. Model c5000, Wilmington, NC). ELISA kits (SciMed Laboratories  
26 Inc., Edmonton, Alberta), using solid phase immobilisation of a monoclonal antibody  
27 directed against a distinct antigenic determinant on the vitamin-A molecule (retinol  
28 palmitate). A second anti-vitamin-A monoclonal antibody conjugated to horseradish  
29 peroxidase (HRP) was used as the detecting antibody in the assay mixture. The test sample  
30 was allowed to react sequentially with the two antibodies, resulting in the vitamin-A  
31 molecules being sandwiched between the solid phase and enzyme-linked antibodies. After  
32 incubation, the wells were washed with distilled water to remove all unbound labelled  
33 antibodies. A solution of TMB was added as a substrate, resulting in the development of a  
34 blue colour and the reaction was stopped by adding 0.2M H<sub>2</sub>SO<sub>4</sub>, changing the colour to  
35 yellow. Vitamin A concentration is directly proportional to the colour intensity of the test  
36 sample. Absorbency was measured spectrophotometrically at 450 nm. The Vitamin D<sub>3</sub>  
37  
38  
39  
40  
41  
42  
43  
44  
45  
46  
47  
48  
49  
50  
51  
52  
53  
54  
55  
56  
57  
58  
59  
60

1  
2  
3  
4  
5 ELISA test used was based on the principle of competitive enzyme immunoassay. The  
6  
7 assay system utilizes a fixed number of Vitamin D3 molecules immobilised on a solid  
8  
9 phase. These molecules compete with an unknown number of Vitamin D3 molecules  
10  
11 extracted from feed samples for a fixed number of binding sites on enzyme labelled  
12  
13 monoclonal antibodies directed against Vitamin D3. As the number of Vitamin D3  
14  
15 molecules in the sample increases, the number of bound labelled antibody molecules to  
16  
17 solid phase antigen decreases due to competition. The amount of enzyme-labelled  
18  
19 antibodies bound to the solid phase Vitamin D3 is inversely proportional to the  
20  
21 concentration of Vitamin D3 present in the sample. Reference values for comparison were  
22  
23 obtained from van der Vooedt-Jarvis (1994).  
24  
25  
26  
27

### 28 **Limb measurements**

29  
30 Fifteen ostriches were selected aged 2, 4, 8 and 12 weeks. They were carefully taken to a  
31  
32 shaded area in the pen to prevent heat stress. A tape measure (cm) was used to take  
33  
34 measurements of hind limbs according to anatomy (Bezuidenhout, 1999) of the femur plus  
35  
36 tibiotarsus; tarsometatarsus; phalanx I, digit III; phalanx II, digit III plus phalanx III, digit  
37  
38 III; and phalanx IV, digit III.  
39  
40  
41

### 42 **Locomotion studies**

43  
44 A run was constructed 6 x 1.7 m and subdivided into 2 m sections. The surface was raked  
45  
46 and all stones removed. The height of the run was 80 cm and was constructed of a pole  
47  
48 supported by drums. Water was sprinkled on the surface prior to each recording. As the  
49  
50 chick passed each 2 m division time was recorded (sec) using a stop watch. The chick was  
51  
52 released and following completion of its run, measurements (cm) were made of the left  
53  
54 and right footprints; the number of footprints and average stride length in 0 - 2, 3 - 4 and 5  
55  
56  
57  
58  
59  
60

1  
2  
3  
4 - 6 m. Speed was calculated using distance run (m) divisible by time taken (s). The angle  
5  
6 of twisting was measured from the inner mid-step. Only chicks aged 2, 4 and 8 weeks  
7  
8 were studied, as the farmer was concerned about stress in 12-week-old birds.  
9  
10

11 Statistical comparisons of limb measurements and locomotion studies were  
12  
13 computed using ANOVA-1 in SPSS 14.0 for Windows 2005 (SPSS Inc., Chicago, Illinois)  
14  
15 and Microsoft Excel 2002 (Windows XP, Microsoft Cooperation, London) between  
16  
17 normal chicks and those suffering from bow leg syndrome. Results were presented as  
18  
19 mean  $\pm$  s.e.m. and  $P < 0.05$  was taken as significant.  
20  
21  
22

### 23 **Post-mortem in chicks suffering from bow leg**

24  
25 A post-mortem study was performed on three chicks aged 4 weeks with bow legs. A cut  
26  
27 was made through the neck and the trunk to expose the thoraco-abdominal viscera.  
28  
29 Detailed morphological, anatomical and interior examinations of the respiratory,  
30  
31 circulatory, gastro-intestinal and uro-genital systems were made. Observations on the  
32  
33 musculature and bones of the hind limbs and joints were noted following dissection of the  
34  
35 skin. Extensive photography of bow leg limbs in ostrich chicks has been previously  
36  
37 published (Chang *et al*, 1988) and in the current study we wished to confirm that we were  
38  
39 dealing with the same pathological condition.  
40  
41  
42  
43  
44

45 All experiments were performed according to guidelines established for handling  
46  
47 and experimentation on animals in Zagazig University, Egypt. These guidelines were  
48  
49 stipulated in accordance with the Egyptian Veterinary Regulations (1966, Article 53,  
50  
51 Ministry of Agriculture).  
52  
53  
54  
55

## 56 **RESULTS**

57  
58  
59  
60



### Feed analysis

Chicks aged 2 and 4 weeks were fed a pre-starter ration consisting of 13.0 MJ ME, which was reduced in the starter ration fed to 8- and 12-week old chicks to 12.5 MJ. All feed was milled at Animal Feeds Ltd., Zagazig. By comparison with standard values prescribed by van der Vooedt-Jarvis (1994), calcium was 10.9 vs. 11.0 g/kg (pre-starter) and 9.4 vs. 9.5 (starter), respectively. Phosphorus was 5.7 vs. 5.5 g/kg (pre-starter) and 4.3 vs. 4.5 g/kg (starter), respectively. Vitamins A and D were respectively 4,003 vs. 4,000 IU and 598 vs. 600 IU, respectively.

### Limb measurements

Hind limb bone measurements (femur, tarsometatarsus and phalanges) in bow leg ostrich chicks aged 4, 8 and 12 weeks were lower ( $P<0.05$ ) than in healthy birds (Table).

### Locomotion studies

Compared with healthy controls, the number of steps was significantly greater only in bow leg chicks aged 4 and 8 weeks (Figure 1, graphs 3 and 5). Stride length, however, was smaller ( $P<0.05$ ) in all age groups with bow legs (Figure 1, graphs 1, 3 and 5). All speeds in bow leg chicks were lower ( $P<0.05$ ) than in healthy birds, except at 2m in chicks aged 2 weeks, which did not differ markedly (Figure 1, graphs 1, 3 and 5). The angle of twisting of the hind limbs was 62.8° (2 weeks), 63.6° (4 weeks), 65.1° (8 weeks) and 68.9° (12 weeks).

### Post-mortem in chicks suffering from bow legs

The farmer reported that there were between 15 – 20 % of chicks suffering from bow legs. Generally death occurred 2 – 3 d after chicks were unable to walk. Three severely sick, emaciated chicks aged 4 weeks were selected. They lay prostrate on the ground with their

1  
2  
3  
4 legs bent at the knee (Figures 2 and 3). They could not stand for more than 1 min, their  
5  
6 hind legs were weak and trembling, and they shuffled around mostly on their  
7  
8 tarsometatarsi. They did, however, call regularly. Heart rate was recorded at 60 bpm.  
9  
10 Palpitations demonstrated protruding scapulae and sternum. Feathers on the head and neck  
11  
12 were very thin with extensive bare areas. Feathers on the torso were sparse and there were  
13  
14 enlarged apteria amongst pterylae. Icterus was present in the mucosae and the buccal  
15  
16 cavity was pale pink.  
17  
18  
19

20  
21 The oesophagus, proventriculus and gizzard had pale yellow peeling mucosae. A  
22  
23 little chyme was present. Both proximal and distal small intestinal sections exhibited  
24  
25 damaged rugae with localised patches of reddish inflammation. There was no food in the  
26  
27 small intestine. In the entire length of the large intestine (proximal, mid and distal  
28  
29 sections) there were only a few small pale green whitish pellets. There was no visible  
30  
31 evidence of endoparasitic infestation. The liver was spotted with yellow discolouration on  
32  
33 the capsular and cut surfaces. The trachea, lungs and heart appeared normal.  
34  
35  
36

37  
38 Dissection of the tarsometatarsus revealed twisted, severely-inflamed joints,  
39  
40 eroded distal ends, thickening of the cartilage and the presence of fibrous material  
41  
42 surrounding the ligaments. The tibiotarsus was unusually thin and porous, with a poor  
43  
44 blood supply. The muscles in the hind limb were principally emaciated and pale pink.  
45  
46  
47  
48

## 49 DISCUSSION

50  
51  
52  
53  
54 Our study has shown that bow leg syndrome is pathological and exacerbates stress in  
55  
56 ostrich chicks. It suggests that bow leg chicks are unable to keep up with adults and in  
57  
58  
59  
60

1  
2  
3  
4 flocks, and hence a compromised ability to escape predators in the wild. The study was  
5 cost-effective and simple to set up and could be extended to observe locomotion in a wide  
6 variety of climates and geographical topographies within which ostriches are farmed.  
7  
8  
9  
10  
11  
12 Indeed, a standardisation of gait scoring in ostrich chicks would ensure a more precise  
13  
14 universal diagnosis of bow leg syndrome.

15  
16 The two-weekly growth of the metatarsal bone (phalanx I, digit III; phalanx II,  
17 digit III; and the phalanx III, digit III) demonstrated a decline of 1.83 cm between 8-12  
18 weeks, in agreement with previous studies (Mushi *et al.*, 1998; Musa *et al.*, 2005). Bow  
19 leg syndrome is clearly slowing the growth of the metatarsal bone compared with the  
20 healthy chicks which had increased rates of growth (Table). The disease is progressive  
21 over age and the entire hind limb was smaller ( $P<0.05$ ) than healthy limbs after and  
22 including the age of 4 weeks (Table). Guittin (1986) suggest this is associated with a rapid  
23 weight increase prior to tarsometatarsal growth. Pathological observations of the bones  
24 and musculature were consistent with findings of bow leg syndrome in rheas aged 2 and 8  
25 weeks (Guittin, 1986). The angles of twisting in our study were progressive with age. The  
26 value of  $70^\circ$  was much larger than the normal motion of the fibula respective to the  
27 tibiotarsus of  $35^\circ$  (Fuss, 1999). We suggest that in bow leg syndrome, flexion and inward  
28 rotation of the tibiotarsus causes exaggerated fibular supination, possibly due to erosion of  
29 the plateau of the tibiotarsus and femorofibular joint surfaces. There is also probably  
30 damage to the fibular attachment of the popliteus muscle potentiating uncoordinated and  
31 pathological outward rotation of the tibiotarsus relative to the femur. Radiographic studies  
32 in bow leg and healthy chicks using the methods of Curro *et al.* (1998) would provide  
33 strong evidence for limb development.

1  
2  
3  
4  
5  
6  
7  
8  
9  
10  
11  
12  
13  
14  
15  
16  
17  
18  
19  
20  
21  
22  
23  
24  
25  
26  
27  
28  
29  
30  
31  
32  
33  
34  
35  
36  
37  
38  
39  
40  
41  
42  
43  
44  
45  
46  
47  
48  
49  
50  
51  
52  
53  
54  
55  
56  
57  
58  
59  
60

Although we were unable to dissect other dead chicks, it would be interesting to observe the differences in rotation and twisting of the bones and the gastrocnemius tendon by age. Further studies on calcium metabolism may provide other evidence for diseased bones. Indeed, an imbalance in calcium metabolism (Guittin, 1986) and associated deficiencies of manganese and zinc during heavy calcium (Wallach, 1970; Wedekind and Baker, 1990 *a,b*) and phosphorus (Wedekind and Baker, 1990 *a,b*; Anon, 1991; Wedekind *et al.*, 1991) supplementation may predispose ostrich chicks to develop bow leg syndrome.

Locomotion in chicks suffering from bow leg is most noticeably reduced at ages 4 and 8 weeks (Figure 1, graphs 3 and 5). The syndrome reduces the number of strides and ultimately the speed. It is unlikely that inadequate nutrition is the sole cause of instability in chick hind limbs, because the incidence was 15 - 20%. We propose that pathologies establish themselves during the first week after hatching, possibly associated with inadequate provision of shade, resulting in heat stress and sedation. Indeed, stability on legs is accomplished through movement and activity, which strengthen the bones (Guittin, 1986).

The pathology observed prior to death was indicative of severe anaemia and anorexia. The nutrient composition associated with efficient skeletal and muscle function did not differ from prescribed values previously published. This suggests that the pathological changes observed rendered it difficult for the chicks to maintain an adequate nutrient intake. Amino acids (cysteine and amino nitrogen) are required for the maintenance and growth of new feather follicles, feather sheaths and epidermal blood vessels (Koutsos *et al.*, 2001). The thinness of the torso was commensurate with the loss of feather fat (Summers and Fisher, 1962). The evidence of necrotic mucosae could be

1  
2  
3  
4 indicative of bacterial infection or fibrin (exudate) which often is produced during  
5  
6 inflammation (Huchzermeyer – personal communication). However, as there was no sign  
7  
8 of either a prolapsed phallus or cloaca, we did not suspect *Cryptosporidium* infection  
9  
10 (Santos *et al.*, 2005). The presence of pellets in the large intestine in our study was also  
11  
12 observed in a previous investigation of bow leg (Chang *et al.*, 1988). We suggest that the  
13  
14 pellets were a mixture of earth and sand. It is well known that chicks through conditioning,  
15  
16 sight and calling, flock together to feed troughs when filled. We suggest the presence of  
17  
18 mild ascites and the numerous yellow foci on the surfaces of the liver were indicative of  
19  
20 *Clostridium* infection, as previously observed (Shivaprasad, 2003). Reference has been  
21  
22 made to necrosis of the mucosae and liver in psittacine beak and liver disease  
23  
24 (Shivaprasad, 2002). The gross pathology in our study was remarkably like that of copper  
25  
26 toxicosis (Kobayashi *et al.*, 1992) although soil analyses charts showed no indication of  
27  
28 this. In our study, however, we suggest a combination of opportunistic infection and  
29  
30 malnutrition contributing to the observed pathology.  
31  
32  
33  
34  
35  
36

### 37 ACKNOWLEDGEMENTS

38  
39 The owner of Gamal`s Farm and the workers are all thanked for their assistance, interest  
40  
41 and generosity.  
42  
43

### 44 REFERENCES

- 45  
46 ANON. (1991) Excess phosphorus impairs manganese utilization in chicks. *Nutrition*  
47  
48 *Reviews*, **49(4)**: 125 – 127.  
49  
50  
51 BEZUIDENHOUT, A.J. (1999) Anatomy, in *The Ostrich. Biology, Production and*  
52  
53 *Health*, edited by D.C. Deeming. Oxon: CABI Publishing: 13-49.  
54  
55  
56  
57  
58  
59  
60

1  
2  
3  
4 BOSS, B.B. & FREDEEN, K.J. (1997) Concepts, instrumentation, and techniques in  
5 inductively coupled plasma optical emission spectrometry. Norwalk: The Perkin-Elmer  
6 Corporation.  
7  
8  
9

10  
11 CHANG, P., CHANG, C., LIU, M. & WANG, K. (1988) Bow leg syndrome in young  
12 ostriches (*Struthio camelus*). *Journal of the Chinese Society of Veterinary Science*, **14(1)**:  
13 17-21.  
14  
15  
16

17  
18 COOPER, R.G. (2007) Differences in stride between healthy ostriches (*Struthio camelus*)  
19 and those affected by tibiotarsal rotation. *Journal of the South African Veterinary*  
20 *Association*, **78(1)**: 52-53.  
21  
22  
23

24  
25 CURRO, T.G., LANGENBERG, J.A. & DEAKIN, L. (1998) Radiographic analysis of the  
26 development of the pelvic limb of captive-reared cranes (*Grus spp.*). *Zoo Biology*, **15(2)**:  
27 143-157.  
28  
29  
30

31  
32 FUSS, F.K. (1999) Tibiofibular junction of the South African ostrich (*Struthio camelus*  
33 *australis*). *Journal of Morphology*, **227(2)**: 213-226.  
34  
35  
36

37  
38 GUITTIN, P. (1986) Bow leg syndrome in ratite birds. *Avicultural magazine*, **92(2)**: 70-  
39 79.  
40  
41

42  
43 HILDEBRAND, M. (1988) Form and function in vertebrate feeding and locomotion.  
44 *American Zoology*, **28**: 727-738.  
45  
46

47  
48 KOBAYASHI, Y., SHIMADA, A., UMEMURA, T. & NAGAI, T. (1992) An outbreak of  
49 copper poisoning in mute swans (*Cygnus olor*). *Journal of Veterinary Medical Science*,  
50 **54(2)**:229-233.  
51  
52

53  
54 KOUTSOS, E.A., MATSON, K.D. & KLASING, K.C. (2001) Nutrition of birds in the  
55 Order Psittaciformes: a review. *Journal of Avian Medicine and Surgery*, **15(4)**: 257 – 275.  
56  
57  
58  
59  
60

1  
2  
3  
4 MUSA, H.H., SULEIMAN, A.H., LANYASUNYA, T.P., OLOWOFESO, O. & MEKKI,  
5  
6 D.M. (2005) Feeding practices, growth rate and management of ostrich chicks in Sudan.  
7  
8  
9 *Pakistan Journal of Nutrition*, **4(3)**: 154-157.

10  
11 MUSHI, E.Z., ISA, J.F.W., CHABO, R.G. & SEGAISE, T.T. (1998) Growth rate of  
12  
13 ostrich (*Struthio camelus*) chicks under intensive management in Botswana. *Tropical*  
14  
15 *Animal Health and Production*, **30(3)**: 197-203.

16  
17  
18 SANTOS, M.M.A.B, PEIRÓ, J.R. & MEIRELES, M.V. (2005) *Cryptosporidium* infection  
19  
20 in ostriches (*Struthio camelus*) in Brazil: clinical, morphological and molecular studies.  
21  
22  
23 *Brazilian Journal of Poultry Science*, **7(2)**: 113 – 117.

24  
25  
26 SHIVAPRASAD, H.L. (2002) Pathology of birds – an overview. *Proceedings of C.L.*  
27  
28 *Davis Foundation Conference on Gross Morbid Anatomy of Animals*, AFIP, Washington  
29  
30 D.C., U.S.A., April 8 – 12: 1-48.

31  
32  
33 SHIVAPRASAD, H.L. (2003) Hepatitis associated with *Clostridium difficile* in an ostrich  
34  
35 chick. *Avian Pathology*, **32(1)**: 57-62.

36  
37  
38 SUMMERS, J.D. & FISHER, H. (1962) The nutritional requirements of the protein-  
39  
40 depleted chicken. *Zeitschrift für Ernährungswissenschaft*, **3(1-2)**: 48-56.

41  
42  
43 VAN ACHTHOVEN, T., MERABET, Z., SHALABY, K.S. & VAN STEENBERGEN, F.  
44  
45 (2004) *Balancing Productivity and Environmental Pressure in Egypt. Towards an*  
46  
47 *Interdisciplinary and Integrated Approach to Agricultural Drainage*. The International  
48  
49 Bank for Reconstruction and Development, Agriculture & Rural Development  
50  
51 Department, Washington D.C., U.S.A., pp. 69.

52  
53  
54 VAN DER VOODT-JARVIS, C. (1994) *The Dasana Ostrich Guide*. Imprimerie Barras,  
55  
56  
57 Bruxelles.

1  
2  
3  
4 WALLACH, J.D. (1970) Nutritional diseases of exotic animals. *Journal of the American*  
5  
6  
7 *Veterinary Medical Association*, **157**: 583-599.

8  
9 WEDEKIND, K.J. & BAKER, D.H. (1990a) Effect of varying calcium and phosphorus  
10  
11 level on manganese utilization. *Poultry Science*, **69(7)**: 1156 – 1164.

12  
13 WEDEKIND, K.J. & BAKER, D.H. (1990b) Manganese utilization in chicks as affected  
14  
15 by excess calcium and phosphorus ingestion. *Poultry Science*, **69(9)**: 977 – 984.

16  
17 WEDEKIND, K.J., TITGEMEYER, E.C., TWARDOCK, A.R. & BAKER, D.H. (1991)  
18  
19 Phosphorus, but not calcium, affects manganese absorption and turnover in chicks.  
20  
21  
22  
23  
24  
25  
26  
27  
28  
29  
30  
31  
32  
33  
34  
35  
36  
37  
38  
39  
40  
41  
42  
43  
44  
45  
46  
47  
48  
49  
50  
51  
52  
53  
54  
55  
56  
57  
58  
59  
60  
*Journal of Nutrition* **121(11)**: 1776 – 1786.

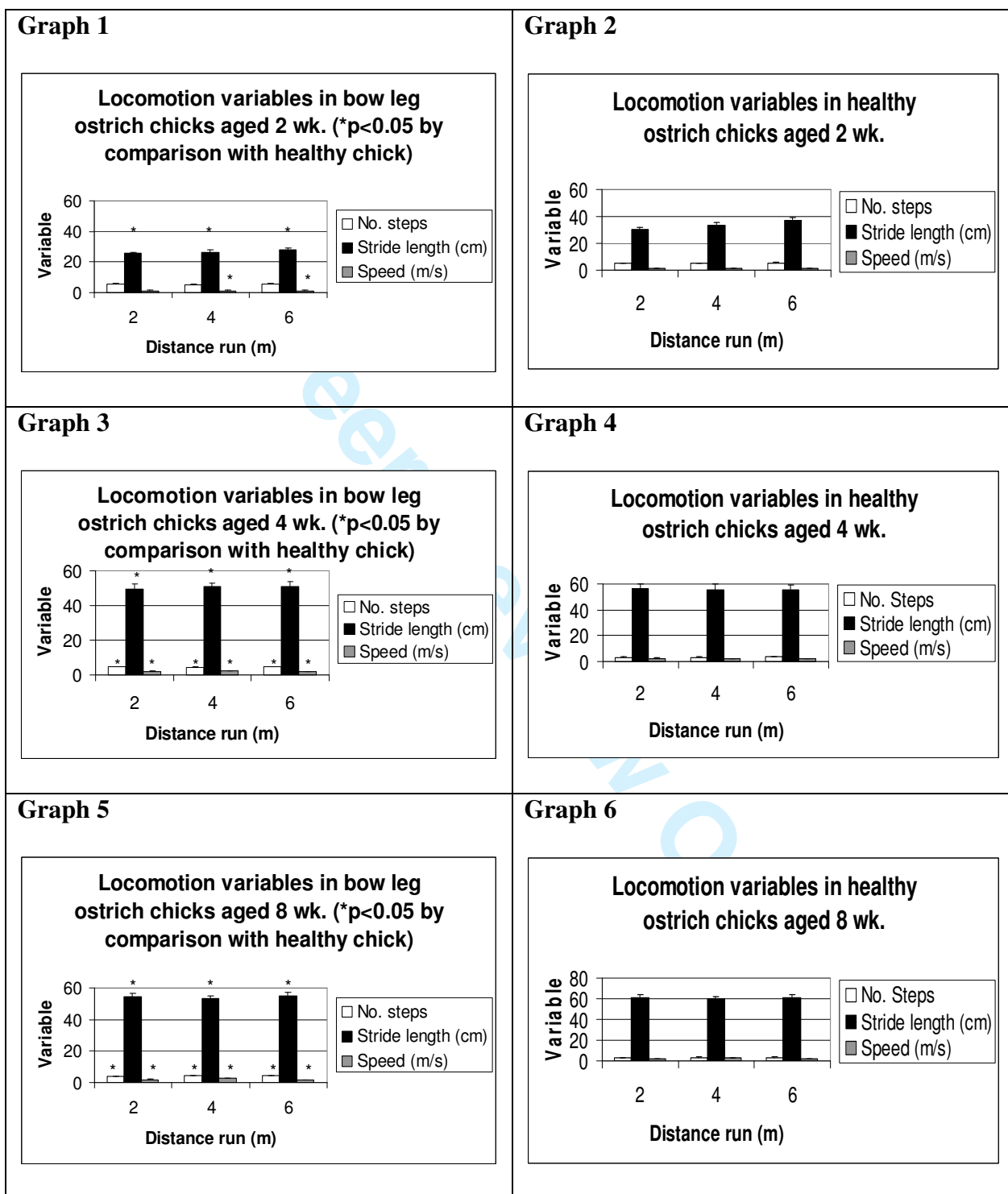


**Table.** *Hind limb measurements (cm) of healthy vs. chicks suffering from bow leg syndrome (n = 15).*

Age (wk.)	Mean hind limb measurement	Health chicks	Bow leg chicks
2	Femur plus tibiotarsus	13.67 ± 0.29	12.20 ± 0.11
	Tarsometatarsus	9.69 ± 0.24	8.60 ± 0.24
	Phalanx I, digit III	5.07 ± 0.13	4.50 ± 0.22
	Phalanx II, digit III plus phalanx III, digit III	2.59 ± 0.10	2.25 ± 0.19
	Phalanx IV, digit III	1.15 ± 0.05	1.05 ± 0.17
4	Femur plus tibiotarsus	22.89 ± 0.56	18.73* ± 0.23
	Tarsometatarsus	17.59 ± 0.46	14.01* ± 0.20
	Phalanx I, digit III	8.19 ± 0.24	7.00* ± 1.00
	Phalanx II, digit III plus phalanx III, digit III	3.84 ± 0.11	3.01* ± 0.21
	Phalanx IV, digit III	1.86 ± 0.07	1.10* ± 0.16
8	Femur plus tibiotarsus	26.61 ± 0.54	22.00* ± 0.13
	Tarsometatarsus	22.25 ± 0.51	17.03* ± 0.14
	Phalanx I, digit III	9.69 ± 0.26	8.10* ± 0.18
	Phalanx II, digit III plus phalanx III, digit III	4.88 ± 0.15	3.13* ± 0.24
	Phalanx IV, digit III	2.13 ± 0.07	1.84* ± 0.22
12	Femur plus tibiotarsus	41.55 ± 0.61	35.13* ± 0.20
	Tarsometatarsus	35.88 ± 0.42	30.12* ± 0.13
	Phalanx I, digit III	14.83 ± 0.49	11.50* ± 0.21
	Phalanx II, digit III plus phalanx III, digit III	6.75 ± 0.28	3.60* ± 0.15
	Phalanx IV, digit III	3.13 ± 0.16	2.80* ± 0.08

\*  $P < 0.05$  by comparison with healthy chicks.

**Figure 1.** Comparison of locomotion variables in bow leg vs. healthy chicks.



**Figure 2.** *Chick suffering from bow leg syndrome is isolated from the flock.*



Review Only

**Figure 3.** *Severe twisting of limbs in bow leg ostrich chick.*

