



HAL
open science

Anthropometric characterization of the child's liver

G. Pauleau, Baptiste Sandoz, L. Thollon, T. Serre, C. Brunet

► **To cite this version:**

G. Pauleau, Baptiste Sandoz, L. Thollon, T. Serre, C. Brunet. Anthropometric characterization of the child's liver. *Surgical and Radiologic Anatomy*, 2010, 25p. 10.1007/s00276-010-0675-8. hal-00543247

HAL Id: hal-00543247

<https://hal.science/hal-00543247>

Submitted on 15 Dec 2010

HAL is a multi-disciplinary open access archive for the deposit and dissemination of scientific research documents, whether they are published or not. The documents may come from teaching and research institutions in France or abroad, or from public or private research centers.

L'archive ouverte pluridisciplinaire **HAL**, est destinée au dépôt et à la diffusion de documents scientifiques de niveau recherche, publiés ou non, émanant des établissements d'enseignement et de recherche français ou étrangers, des laboratoires publics ou privés.

Editorial Manager(tm) for Surgical and Radiologic Anatomy
Manuscript Draft

Manuscript Number: SARA-D-09-00367

Title: Anthropometric characterization of the child's liver

Article Type: Original Article

Keywords: liver; child; modeling; CT; growth

Corresponding Author: Mr. Baptiste Sandoz, MSc

Corresponding Author's Institution: Laboratory of Applied Biomechanics, UMRT 24 INRETS/Université de la Méditerranée

First Author: Ghislain Pauleau, MD

Order of Authors: Ghislain Pauleau, MD; Baptiste Sandoz, MSc; Lionel Thollon, PhD; Thierry Serre, PhD; Christian Brunet, MD

Abstract: Purpose: The major purpose of this retrospective study on twenty-five CT-scanners of children liver from 2 to 13 years old was to investigate the growth, morphologic variations and modifications of the liver position as a function of the children age. The objective was to characterize the 3D geometry of the child liver, which is still unknown.

Methods: 3D reconstruction of children liver was performed using the Mimics software. Measurements of volume (total liver and right lobe), distance between anatomic reference points and angles were realized. The liver position was determined with respect to the 11th thoracic vertebra.

Results: The liver growth monitoring shows that it is harmonious as for the volume relations between the right lobe and the left lobe but disharmonious as for the distance measures situated in relation to the falciform ligament. The liver position with respect to the vertebral column in the peritoneal cavity was unchanged during the liver growth.

Conclusion: The results obtained from this preliminary work give description of the child liver during growth and are of interest for the numerical modeling.

| |
|---|
| Surgical and Radiologic Anatomy, 2010 Copyright : © Springer Verlag DOI: 10.1007/s00276-010-0675-8 http://www.springerlink.com/content/100112/ |
|---|

Anthropometric characterization of the child's liver

Ghislain Pauleau¹, Baptiste Sandoz^{2*}, Lionel Thollon², Thierry Serre², Christian Brunet²

1. Department of Digestive Surgery, Laveran Military Hospital, Blvd Laveran 13013 Marseille BP 50, France.

2. Laboratory of Applied Biomechanics, UMRT 24 INRETS/Université de la Méditerranée, Faculté de Médecine Secteur Nord, Blvd. Pierre Dramard, 13916 Marseille cedex 20, France.

*Corresponding author

Email: baptiste.sandoz@free.fr

ABSTRACT

Purpose: The major purpose of this retrospective study on twenty-five CT-scanners of children liver from 2 to 13 years old was to investigate the growth, morphologic variations and modifications of the liver position as a function of the children age. The objective was to characterize the 3D geometry of the child liver, which is still unknown.

Methods: 3D reconstruction of children liver was performed using the Mimics® software. Measurements of volume (total liver and right lobe), distance between anatomic reference points and angles were realized. The liver position was determined with respect to the 11th thoracic vertebra.

Results: The liver growth monitoring shows that it is harmonious as for the volume relations between the right lobe and the left lobe but disharmonious as for the distance measures situated in relation to the falciform ligament. The liver position with respect to the vertebral column in the peritoneal cavity was unchanged during the liver growth.

Conclusion: The results obtained from this preliminary work give description of the child liver during growth and are of interest for the numerical modeling.

Keywords: Liver, Child, Modeling, CT, Growth.

INTRODUCTION

1
2 The knowledge of liver volume is of clinical relevance when determining graft size for
3
4 transplantation and organ viability after resection. It is also important to know this volume
5
6 and its variance in different populations for the prediction of hepatic drug clearance using
7
8 physiologically based pharmacokinetic models [12]. Many models have been described to
9
10 estimate liver volume, even in children, using various parameters such as the body surface
11
12 area, size, weight, age and sexes [14]. However, the liver morphology and growth during
13
14 health childhood were not yet studied at our knowledge.
15
16
17

18
19 Various numerical models of parts or whole human bodies used to predict the kinematic
20
21 behaviour of the human body are of interest to define injury mechanisms caused by a car
22
23 crash and thereby to improve the car user safety [7]. However, these models must be adapted
24
25 for application to children since the physiological and morphological aspects between adults
26
27 and children are relatively different.
28
29
30

31
32 The current children model conception realized from adult models using a linear scale seems
33
34 to be not sufficiently accurate. Indeed, the children growth is a differential process among
35
36 organ and body segments, and each of them enlarges at a specific speed. These particular
37
38 patterns, applied to internal organs, imply that there is a possible evolution between each
39
40 other [2]. For example, the liver weight, when compared to total body weight, changes along
41
42 lifespan [6]. The liver morphology and physiology change also between foetal and neonatal
43
44 periods. The foetal liver is symmetric, i.e., the left and right hepatic lobes have nearly the
45
46 same volume. This physiologic difference between the two liver lobes is the consequence of
47
48 the blood circulation in the foetal liver, which is different from the adult circulation: the portal
49
50 branch from umbilical vein vascularises the left lobe with a high level oxygenated blood,
51
52 whereas the right hepatic lobe receives blood with low saturation level from the portal vein.
53
54
55
56
57

58
59 During the foetal period, the liver is a hematopoietic organ between 6 and 8 weeks of
60
61
62
63
64
65

1 gestation, the right liver has a hematopoietic activity higher than the left lobe [11]. This
2 anatomic difference disappears during the neo-natal period. However, to our knowledge, there
3
4 is no study dedicated to the analysis of the rhythm of liver growth, and of liver morphology
5
6 between 3 and 13 years old.
7

8
9 Cadaver data are hard to obtained for children. Liver autopsy studies have also an uncertainty
10
11 due to the blood flow increasing in vivo volume of the organ; the morphologic description
12
13 does not consider the liver in anatomic position, which is winded around the vertebral column
14
15 in right hypochondrium [5].
16
17

18
19 Few studies have been devoted to the abdominal organ modeling and biometric evolution in
20
21 children. Nevertheless, based on a previous validated study on child spleen [9], CT-scan data
22
23 could be used in order to characterize the geometry of child liver.
24
25

26
27 The objective of the present work is to evaluate the geometrical evolution of the liver and its
28
29 position in the abdomen during the child growth. The intrinsic morphology like right lobe and
30
31 left lobe relationship was investigated. Moreover, this study allows comparing liver
32
33 measurements validated in adults with measurements in children.
34
35
36
37

38 **MATERIALS AND METHODS**

39 **Sample**

40
41
42 Twenty-five CT scans of maximum 1-mm-thick liver slices have been obtained from children
43
44 belonging to the paediatric traumatic intensive care unit of the Northern Hospital of Marseille.
45
46 These data were collected using a helicoidally recording X-ray scanner, SOMATOM
47
48 Sensation 64 equipment (Siemens Medical®). CT-scans were performed only for clinical
49
50 purpose but neither in an investigative setting with normal subjects; they were only collected
51
52 and anonymized, in accordance with the ethical recommendations. Scans of liver slices either
53
54 thicker than 1 mm or not sufficiently injected with iodized contrast agent were found to be not
55
56
57
58
59
60
61
62
63
64
65

1 discriminating and were rejected. The injection time was varied from one patient to another
2 one. The following exclusion criteria were: patients less than 2 years old, more than 13 years
3 old, and patients exhibiting an acute or chronic pathology affecting the liver growth such as
4 tumour, intrahepatic hematoma, expansion of bile duct.
5
6
7

8
9 The patients were distributed in three different groups which have the same age interval (4
10 years) and containing a similar number of children. The A group was composed of the
11 youngest children from 2 to 5 years old. The two other groups, B and C, contained children of
12 6 to 9 years old (median age) and 10 to 13 years old (oldest patients), respectively.
13
14
15
16
17
18
19
20

21 **Modeling**

22 The 3D reconstruction of the liver was performed using the Mimics® software (Materialise
23 Software, Brussels) with a semi-automatic recording allowing acceptable reproducibility. The
24 operator chose a specific area of the hepatic parenchyma and the Mimics software selected
25 automatically in vicinity of this specific area pixels having Hounsfield Unit (HU) density of
26 +/- 20 to 30 HU depending on the quality of CT scans. The connectivity index was set on 4
27 and the selection was accomplished slice by slice. The contour of the selected area was
28 determined manually by the operator mostly around intercostals muscles, pancreas head,
29 inferior cave vein and myocardium at the dome level with similar HU densities very often in
30 direct contact. Then, a 3D model of livers was elaborated by the Mimic® Software from these
31 selected liver regions slice by slice. The calculation parameters from this modeling were of
32 optimal quality. To maintain the reproducibility of measurements the liver pedicle, in
33 particular the portal vein was not included in the calculation of the liver volume. The mask
34 limit chosen for the modeling of the hepatic hilum level corresponded to the separation
35 between the right and left branches of the portal vein. The major objective was to reduce the
36 discrepancy from one operator to another one.
37
38
39
40
41
42
43
44
45
46
47
48
49
50
51
52
53
54
55
56
57
58
59
60
61
62
63
64
65

Measurements

Liver size

First, fourteen anatomical points have been defined on the liver in order to characterize its geometry. The position of these points on liver is indicated in Figs.1 and 2. Eleven anatomical points over 14 points were clearly identified on CT liver scans. The localization of 3 anatomical points (M104, M105 and M110) was rather difficult on CT scans since the triangular ligaments and Arantius ligament cannot be visualized clearly.

The center of the superior plateau of the vertebral body of the 11th thoracic vertebra (T11) was adopted as anatomical point on the body skeleton. This vertebra was chosen since there is a narrow relationship between the 11th costal bone and liver. In addition, the interest of this anatomical point was demonstrated in a previous study dealing with the determination of the spleen position in abdominal cavity [9].

Then, geometrical dimensions of the liver have been determined with respect to these anatomical points. The value of nine distances was deduced (Table 2). A local hepatic reference point (corresponding to the anatomical point M000) was used as origin of a frame for these measurements. These nine distances were selected since they are very representative of the external morphology of liver (Figs. 3 and 4).

Furthermore, the values of two angles A-T11 and A-M111 were deduced from the position of the anatomical points. The top of angle A-T11 was on the centre of the superior plateau of the 11th thoracic vertebra. This angle was defined by two linear segments joining the centre of the superior plateau with the superior point of the right rim of the right liver lobe and the left end of the left liver lobe. This angle was selected for the evaluation of the liver, which is winded around the vertebral column. The top of the second angle A-M111 was located on the hepatic dome and the angle was defined by two linear segments connecting the hepatic dome to the superior point of the right rim of the right lobe and the left end of the left lobe. The angle A-

1 M111 provided information on the overall morphology of the superior part of liver. The more
2 the angle A-M111 is acute the more the hepatic dome enters the thoracic cavity with a
3
4 longilineal morphology, the more this angle is obtuse the more the liver morphology is closed
5
6 to a brevilineal type morphology. With brevilineal type morphology, the thoraco-abdominal
7
8 region is large, the heights of diaphragmatic domes are high and the deepnesses of
9
10 hypochondrium are elevated. The liver exhibits a ventro-petal and frontal position. With the
11
12 longilineal type morphology, the thoraco-abdominal region is narrow, the heights of
13
14 diaphragmatic domes are small and the deepnesses of hypochondrium are weak. The liver has
15
16 a dorso-petal and sagittal position [4].
17
18
19
20
21
22
23

24 ***Anatomical correlations***

25
26 The liver position was determined with respect to a skeleton reference point. The height of the
27
28 liver into the skeletal system was expressed by the distance between the height of the superior
29
30 plateau of T11 (corresponding to the coordinate y in the frontal plane) and the height of three
31
32 anatomical points: M000 (superior point of the junction between the falciform ligament, the
33
34 right triangular ligament and the right lobe), M001 (right superior extremity of the right lobe),
35
36 and M101 (left extremity of the left lobe). The reference used for this measurement is the
37
38 level of the slice on the CT-scan (coordinate “y” of point M and coordinate “y” of T11).
39
40
41
42
43
44
45

46 ***Volume measurements***

47
48 Two volume values, the total volume of liver and volume of the right lobe, were deduced
49
50 from the 3D model given by the Mimics® Software. In addition, the volume ratio defined as
51
52 the right lobe volume divided by the total liver volume, was also calculated.
53
54
55
56
57
58
59
60
61
62
63
64
65

Statistical Analysis

1
2 The intra-operator reproducibility was investigated to evaluate the uncertainty caused by
3 operator for the organ reconstruction from the tomodensitometric slices. This study was
4 achieved from 5 livers reconstructed twice by one operator over two weeks. The sample was
5 composed of 3 boys and 2 girls of 2 to 11 years old. The values of the total liver volume,
6 distances and angles were then compared]. The inter-operator reproducibility was determined
7 for two previous studies on kidney and spleen [9]. Therefore, this reproducibility was not yet
8 evaluated for the liver.
9

10
11
12 The Kruskal-Wallis test was used to determine whether there were significant differences
13 between the female and the male groups, and between the age groups for the calculated
14 parameters (p-value below 5%).
15

16
17 Box plots were used to represent maximum, minimal, medium and quartile values for each
18 children groups (A to C).
19
20
21
22
23
24
25
26
27
28
29
30
31
32
33

RESULTS

34
35
36 Twenty-five CT scans have been investigated with creation of masks for 3D modeling; 825
37 coordinates of 275 anatomical points have been determined for the calculation of 225
38 distances, 50 angles and 75 heights. In addition, 50 values of liver total volume and right lobe
39 volume were obtained using the Mimics® software.
40
41
42
43
44
45
46
47
48
49
50

Reproducibility of measurements and modeling

51 The results obtained from the intra-operator repeatability investigation validated the modeling
52 approach. The systematic uncertainty of two tested measurements, namely liver volume and
53 distance was negligible (Table 3). Therefore, the reproducibility was found to be very high for
54 volume and distance values (p=0,938).
55
56
57
58
59
60
61
62
63
64
65

Gender influence

Twenty five children have been selected for this study, i.e., 17 boys and 6 girls. No significant difference between boy and girl groups was detected for the distance, volume and angle values ($p > 0,061$).

Volume versus children age

The total volume of liver increased progressively from group A to C, i.e., with increasing children age (Fig.5). The average liver volume values for children belonging to group A to C are given in Table 4.

The ratio between the volume of the right lobe and the total liver volume was rather stable and equal to : (i) 0.777 for children from group A (minimum : 0.727, maximum : 0.853, standard deviation : 0.043), (ii) 0.764 for children from group B (minimum : 0.639, maximum : 0.832, standard deviation : 0.056), and (iii) 0.809 for children from group C (minimum : 0.729, maximum : 0.848, standard deviation : 0.032) (Fig.5).

Distance versus children age

The anatomical points were defined a wireframe model to determine the distance values. Seven distance values, D03 to D06, D08, D09 and D17 increased with increasing children age (Fig.5). Two distance values D07 and D10 (Left height of the right lobe and right height of the left lobe) were found to be stable (Fig.5).

Angle and liver height with respect to T11 versus children age

The value of angle between T11 and two ends (right and left extremities) of liver was stable. The values of this angle A-T11 for children from group A to C are given in table 5.

1 The value of the angle A-M111 between the dome and two liver extremities was observed to
2 be stable during the growth of children. The values of this angle for children belonging to
3
4 group A to C are given in table 5.
5
6

7 The height of liver with respect to the position of T11 did not vary significantly as a function
8
9 of the children age. In addition, the position of liver with respect to vertebral column did not
10
11 change during the children growth.
12
13

14 **DISCUSSION**

15
16 The scannographic investigation of soft organs, like spleen in children was previously
17
18 evaluated in terms of repeatability and intra-operator reproducibility [9]. The results obtained
19
20 from the present study of children livers contributed to validate the method based on the
21
22 determination of masks by Mimics® software and coordinates of anatomical points used as
23
24 reference points.
25
26

27
28 The liver volume was found to increase linearly as a function of the children age. A number
29
30 of formulae for calculation of liver volume as a function of various parameters such as body
31
32 surface area, sex and age have been proposed in previous works [8]. The approach more often
33
34 recommended for calculation of liver volume in children of less than 18 years old implied the
35
36 body surface area [14]. The growth of children liver appeared to be proportional to the
37
38 statur-weight growth of patients.
39
40

41
42 The average liver volume in adults is known to be approximately 1500 cm³. Therefore, one
43
44 can conclude that the liver continues to grow in children beyond the age of 13 years. The liver
45
46 volume determined by echography was also found to increase linearly with increasing
47
48 children height and various diagrams were proposed to evaluate the liver size as a function of
49
50 the children height [10]. Our results are in accordance with these previous studies: they show
51
52 tendencies of a linear growth.
53
54
55
56
57
58
59
60
61
62
63
64
65

1 The ratio between the volume of the right lobe and the total liver volume determined in the
2 present work was stable. The volume of the right lobe was equal to 80 % of the total liver
3 volume for the three groups of children investigated. Furthermore, the foetal liver appears to
4 be symmetric, i.e., the volumes of the left and right lobes are similar. The data on the liver
5 growth of foetus have been collected by autopsy studies and foetal in vivo magnetic
6 resonance image (MRI) investigation [3]. The morphology of liver in adults exhibits a volume
7 of the right lobe higher than the left lobe. So, ours results tends to show that this ratio is
8 obtained earlier for children older than about 2 years old. Nevertheless, additional
9 investigations in children of less than 2 years old would be of interest for the analysis of the
10 differential growth of right and left lobes.
11
12
13
14
15
16
17
18
19
20
21
22
23

24 The distance measurements performed in the present work have demonstrated that 7 distances
25 increased with the age while two distances, namely the left height of the right lobe (D07) and
26 right height of the left lobe (D10) are constant or stable. These stable distances correspond to
27 the insertion zone of the falciform ligament composed of two peritoneal layers originating
28 from the reflection of the hepatic visceral peritoneum over the diaphragmatic peritoneum.
29 Close to the anterior edge of liver, the falciform ligament contains the round ligament,
30 remaining of the umbilical vein. This area is in front of the anteroposterior left sulcus of the
31 inferior side of liver. This sulcus contains in the anterior part, the round ligament, then the
32 anterior part of the left portal branch and in the posterior part, the Arantius ligament. In
33 foetus, the Arantius vein channel is a connection between the umbilicus vein (venus return
34 placentaire) through the anterior part of the left portal branch and the right posterior cardinal
35 vein, which is the future inferior cave vein.
36
37
38
39
40
41
42
43
44
45
46
47
48
49
50
51
52

53 The umbilical vein and venus channel of Arantius become blocked for the first days of life by
54 a thrombosis caused by the disappearance of the umbilical circulation. Only the part of the left
55
56
57
58
59
60
61
62
63
64
65

portal branch remains permeable. The umbilical vein is converted into round ligament and Arantius channel into Arantius ligament [5].

According to the present work, the liver growth is more limited in front of the falciform ligament. This result can be due to the presence of fibrous embryonic remaining (round ligament and Arantius ligament), which limits the expansion of the hepatic parenchyma in this zone. The growth of liver appears to be progressive and harmonious with respect the right lobe and left lobe volume ratios. By contrast, the liver growth is disharmonious in terms of distances from the falciform ligament.

The liver height at the falciform ligament appears to increase less rapidly with respect to other distances such as right height of the right lobe, horizontal length of liver, diagonal length of liver, horizontal length of the left lobe and thickness of liver.

In a previous study on the anatomy of liver in adults, the liver diameter in the sagittal plane at the falciform ligament was found to be much lower than the diameter at the middle of the right lobe and left lobe in the sagittal plane. This result may validate the hypothesis of a weaker growth of the hepatic parenchyma in this zone [13]. Nevertheless, the results obtained in children can be not totally valid since the number of children investigated was relatively low.

The two angles measured on 25 scanners were very similar for the three groups of children investigated. The angle T11 with the summit on the superior plateau of T11 was not modified during the growth. The right lobe is winded around the vertebral column and filled out almost completely the right hypochondrium. The position of the left end of the left lobe is not changed during the growth and remains in front of the stomach.

The angle A-M111 remains also stable. So, the overall morphology of the liver seems to be not modified during the growth. Nevertheless, an uncertainty in the determination of this angle may arise from the displacement of liver caused by respiratory movements. The position of

1 liver with respect to T11 is stable during the growth. The liver possesses several fixation
2 elements; the principal element is the inferior vena cava through short sus-hepatic veins. In
3
4 addition, peritoneal ligaments contribute to the liver fixation, namely the falciform, the
5
6 coronary ligament containing one anterosuperior layer and an inferior layer corresponding to
7
8 lateral ends of the coronary ligament.
9
10

11 12 13 14 **CONCLUSION**

15
16 The anatomic modeling of liver in children from CT scans using the Mimics® software was
17
18 validated by results obtained from the present work. These measurements were of interest for
19
20 the analysis of liver growth, which appears to be harmonious with respect to the ratio between
21
22 the volumes of right and left lobes and disharmonious in terms of distances situated in relation
23
24 to the falciform ligament. The position of liver in the peritoneal cavity with respect to the
25
26 vertebral column was not modified during the growth of children. These results would be
27
28 improved by a prospective investigation of a large group of children of less than 2 years old.
29
30 The major objective of this study would be the complete numerical modeling of virtual
31
32 children in the framework of a French project “SECUR-ENFANT” which aims to simulate
33
34 the biomechanical behaviour of the children during a road accident.
35
36
37
38
39
40

41 **ACKNOWLEDGEMENTS**

42
43 This work was partly funded by the French National Research Agency (ANR) in
44
45 the framework of the “SECUR_ENFANT” project.
46
47
48
49
50

51 **ETHICAL STANDARDS**

52
53 The experiments comply with the current laws of the country in which they were performed.
54
55

56 **CONFLICT OF INTEREST**

57
58 The authors declare that they have no conflict of interest.
59
60
61
62
63
64
65

1
2
3
4
5
6
7
8
9
10
11
12
13
14
15
16
17
18
19
20
21
22
23
24
25
26
27
28
29
30
31
32
33
34
35
36
37
38
39
40
41
42
43
44
45
46
47
48
49
50
51
52
53
54
55
56
57
58
59
60
61
62
63
64
65

REFERENCES

- 1 Behr, M., Arnoux, P.J., Serre, T., Bidal, S., Kang, H.S., Thollon, L., Cavallero, C., Kayvantash, K., & Brunet, C. (2003). *A human model for road safety : from geometrical acquisition to model validation with radios*. Computer Methods on Biomechanics and Biomedical Engineering 6(4):263-273.
- 2 Beusenbergh, M.C., Happee, R., Twisk, D., & Janssen, E.G. (1993). *Status of injury biomechanics for the development of child dummies*. Paper presented at the Child Occupant Protection Symposium. San Antonio, Texas, USA.
- 3 Brugger, P.C., Prayer, D. (2006). *Imagerie par résonance magnétique de l'abdomen fœtal*. EMC (Elsevier Masson SAS, Paris), Radiodiagnostic – Appareil digestif, 33-000-A-20.
- 4 Caix, M., Outrequin, G., & Cubertafond, P. (1970). *Contribution à l'étude des variations morphologiques du foie en fonction de l'ontogénèse*. Bull Association Anatomy 149 :692-712.
- 5 Castaing, D., Veilhan, L.A. (2006). *Anatomie du foie et des voies biliaires*. EMC (Elsevier SAS, Paris), Techniques chirurgicales – Appareil digestif. 40-760.
- 6 Champetier, J. (1994). *Le foie*. In : Chevrel JP. Anatomie Clinique (2) Le tronc. 389-405.
- 7 Cheynel, N., Serre, T., Arnoux, P.J., Braque, P., Benoit L., Berdah, S.V., Brunet, C. (2006). *Biomechanic study of the human liver during a frontal deceleration*. Journal of Traumatology. 61, 855-861.
- 8 Chouker, A., et al. (2004) *Estimation of liver size for liver transplantation : the impact of age and gender*. Liver Transplantation. 10, 678-685.

9 Coquet, B., Sandoz, B., Savoie, P.H., Serre, T., Thollon, L., Brunet, C.

1
2 *Anthropometric Characterization Of Spleen In Children.* Surgical and Radiologic Anatomy.

3
4
5 In press. DOI 10.1007/s00276-009-0535-6.

6
7 10 Dittrich, M., Milde, S., Dinkel, E., Baumann, W., Weitzel, D. (1983). *Sonographic*
8
9 *biometry of liver and spleen size in childhood.* *Pediatric Radiology*, 13, 206-211.

10
11 11 Emery, J.L. (1963). *Functional asymmetry of the liver.* *Ann N Y Academic Sciences*,
12
13 111, 37-44.

14
15
16 12 Johnson, T., Tucker, G., Tanner, M. (2005). *Changes in liver volume from birth to*
17
18 *adulthood: a meta-analysis.* *Liver Transplantation*. 11, 1481-1493.

19
20
21 13 Rosset, E., Brunet, C. (1995). *Anatomic basis of the liver for the development of a*
22
23 *perihaptic prosthesis.* *Surgical Radiologic Anatomy*.17 (1):1-5.

24
25
26 14 Vauthey, J., Abdalla, E., Doherty, D., Gertsch, P., Fenstermacher, M., Loyer, E.,
27
28 Lerut, J., Materne, R., Wang, X., Encarnation, A., Herron, D., Mathey, C., Ferrari, G.,
29
30 Charnsangave, C. (2002). *Body surface area and body weight predict total liver volume in*
31
32 *Western adults.* *Liver Transplantation*. 8, 233-240.
33
34
35
36
37
38
39
40
41
42
43
44
45
46
47
48
49
50
51
52
53
54
55
56
57
58
59
60
61
62
63
64
65

Figure2

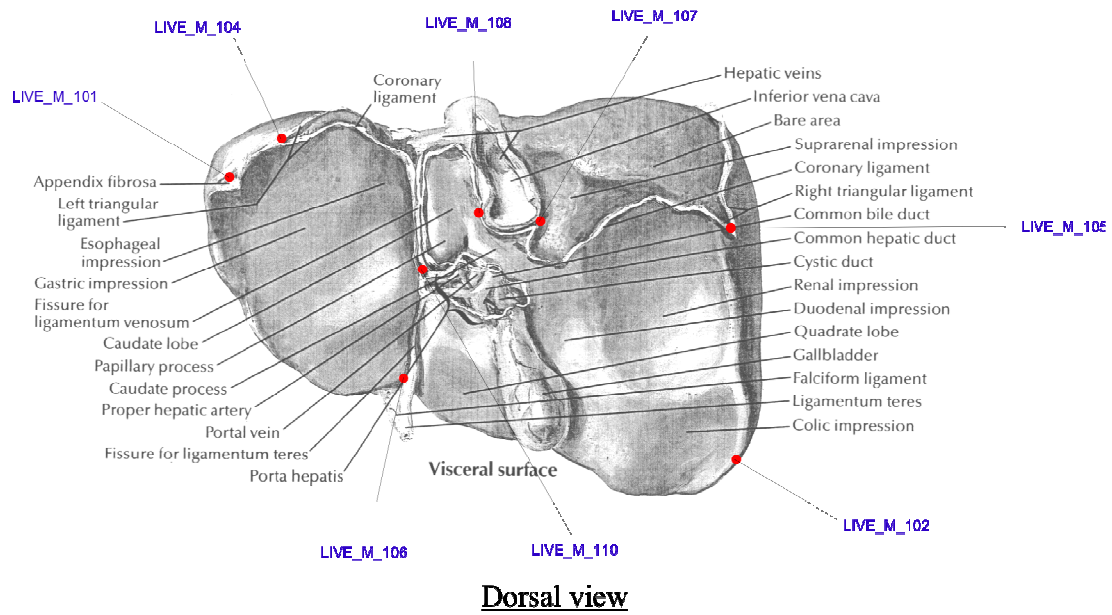


Figure 2: Reference points HUMOS on the dorsal view of the liver (modified according to Netter)




Figure 3: 4 years old liver 3D model (ventral view) and distances D04, D05, D06, D07, D08, D09, D10.

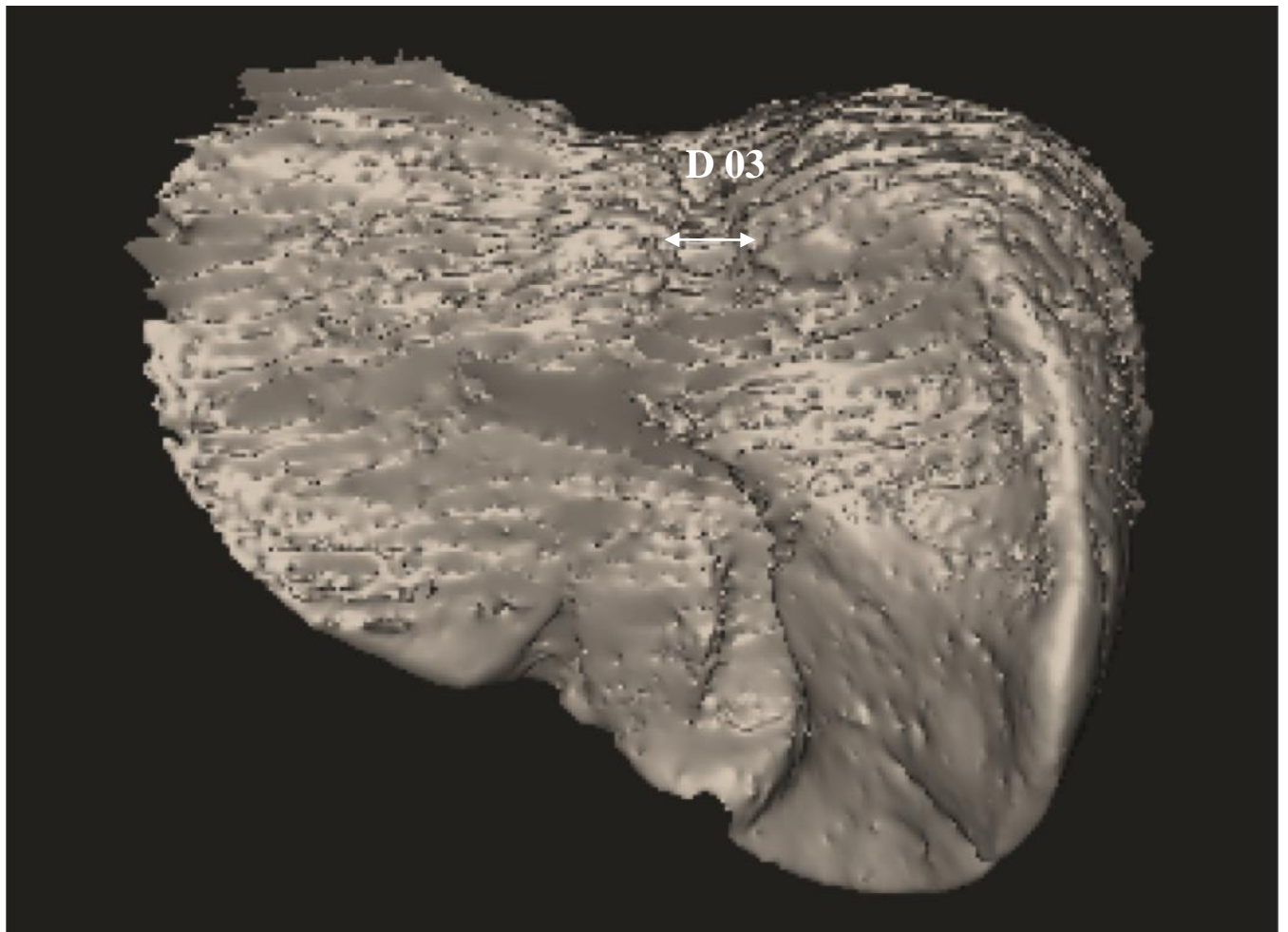


Figure 4: 4 years old children liver 3D model (dorsal view) and distance D03.

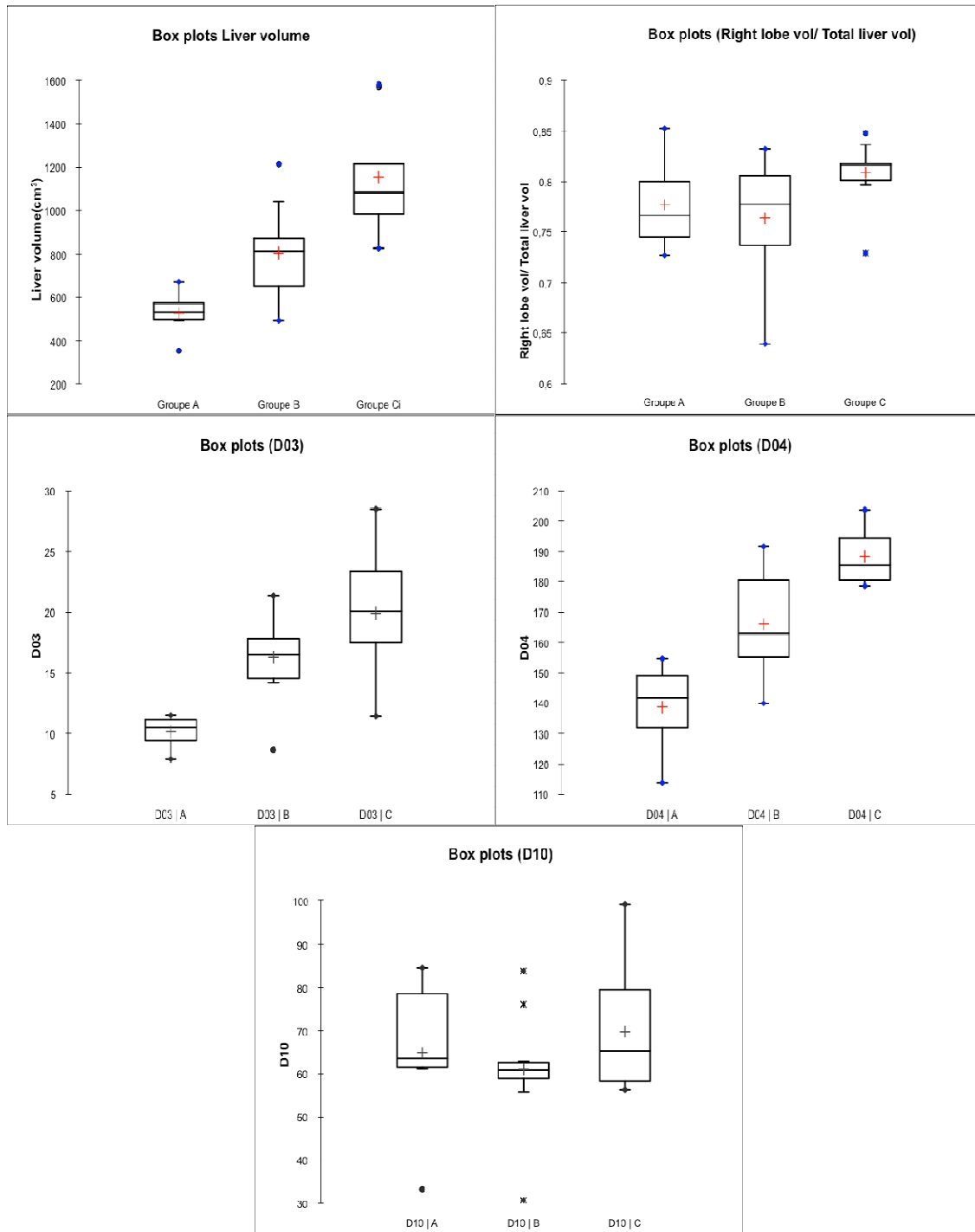


Figure 5: Anthropometric parameters according to the age group (Liver volume, Right lobe volume / Total liver volume, Distances D03, D04 and D10).

Table 1: Anatomic reference points HUMOS.

| CODE | Definition |
|-------------------|---|
| LIVE_M_000 | Superior point of the junction between the falciform ligament, the right triangular ligament and the right lobe |
| LIVE_M_001 | Right Superior extremity of the right lobe |
| LIVE_M_002 | Right inferior point of the junction between the falciform ligament and the right lobe |
| LIVE_M_101 | Left extremity of the left lobe (appendix fibrosa) |
| LIVE_M_102 | Right inferior extremity of the right lobe |
| LIVE_M_103 | Most inferior point of the enghdder impression |
| LIVE_M_104 | Left extremity of the left triangular ligament |
| LIVE_M_105 | Right extremity of the right triangular ligament |
| LIVE_M_106 | Inferior point of the junction between the round ligament and the left lobe |
| LIVE_M_107 | Right point of the inferior junction between the inferior vena cava (IVC) and the right lobe |
| LIVE_M_108 | Left point of the inferior junction between the inferior vena cava (IVC) and the right lobe |
| LIVE_M_109 | Superior point of the junction between the falciform ligament, the left triangular ligament and the left lobe |
| LIVE_M_110 | Inferior point of the fissure for ligamenum venosum |
| LIVE_M_111 | Hepatic dome |

Table 2: HUMOS measurements.

| CODE | Definition | Code of control points needed |
|------------------|--|--------------------------------------|
| LIVE_D_03 | Diameter of the inferior vena cava (IVC) | LIVE_M_107, LIVE_M_108 |
| LIVE_D_04 | Horizontal length of the liver | LIVE_M_101, LIVE_M_001 |
| LIVE_D_05 | Oblique length of the liver | LIVE_M_101, LIVE_M_102 |
| LIVE_D_06 | Horizontal length of the right lobe | LIVE_M_001, LIVE_M_000 |
| LIVE_D_07 | Left height of the right lobe | LIVE_M_002, LIVE_M_000 |
| LIVE_D_08 | Right height of the right lobe | LIVE_M_001, LIVE_M_102 |
| LIVE_D_09 | Horizontal length of the left lobe | LIVE_M_101, LIVE_M_109 |
| LIVE_D_10 | Right height of the left lobe | LIVE_M_106, LIVE_M_109 |
| LIVE_D_17 | Thickness of liver | LIVE_M_000, LIVE_M_108 |

Table 3: Intra-operator repeatability.

| Differences | Volumes (cm3) | Distances (mm) | Angles (°) |
|--------------------|----------------------|-----------------------|-------------------|
| Mean | 2.95 | 6.3 | 6.4 |
| SD | 3.7 | 5.6 | 7.5 |

Table 4: Liver volume for each group.

| | Group A | Group B | Group C |
|---|----------------|----------------|----------------|
| Children age (years) | 2 - 5 | 6 - 9 | 10 - 13 |
| Mean liver volume (cm³) | 527 | 804 | 1156 |
| Minimum (cm³) | 352 | 492 | 825 |
| Maximum (cm³) | 673 | 1215 | 1539 |
| Standard deviation | 97 | 211 | 251 |

Table 5: Angle data for each group.

| | Group A | Group B | Group C |
|--------------------------------|----------------|----------------|----------------|
| Children age (years) | 2 - 5 | 6 - 9 | 10 - 13 |
| Mean angle T11 | 95° | 84° | 90° |
| Minimum angle T11 | 80° | 63 | 76° |
| Maximum angle T11 | 116° | 101° | 112° |
| Standard déviation T11 | 12.3 | 11.6 | 10.9 |
| Mean angle M111 | 140° | 139° | 138° |
| Minimum angle M111 | 119° | 125° | 133° |
| Maximum angle M111 | 150° | 150° | 149° |
| Standard déviation M111 | 11.0 | 7.3 | 4.9 |