



HAL
open science

Prolonged hyperthermia from furosemide infusion-a case report

Lotte Ebdrup, Charles Marinus Pedersen, Mads Holmen Andersen, Merete Storgaard

► To cite this version:

Lotte Ebdrup, Charles Marinus Pedersen, Mads Holmen Andersen, Merete Storgaard. Prolonged hyperthermia from furosemide infusion-a case report. *European Journal of Clinical Pharmacology*, 2009, 66 (2), pp.215-216. 10.1007/s00228-009-0761-1 . hal-00542218

HAL Id: hal-00542218

<https://hal.science/hal-00542218>

Submitted on 2 Dec 2010

HAL is a multi-disciplinary open access archive for the deposit and dissemination of scientific research documents, whether they are published or not. The documents may come from teaching and research institutions in France or abroad, or from public or private research centers.

L'archive ouverte pluridisciplinaire **HAL**, est destinée au dépôt et à la diffusion de documents scientifiques de niveau recherche, publiés ou non, émanant des établissements d'enseignement et de recherche français ou étrangers, des laboratoires publics ou privés.

Prolonged hyperthermia from furosemide infusion—a case report

Lotte Ebdrup · Charles Marinus Pedersen ·
Mads Holmen Andersen · Merete Storgaard

Received: 30 October 2009 / Accepted: 9 November 2009 / Published online: 2 December 2009
© Springer-Verlag 2009

Keywords Furosemide · Hyperthermia · Fever ·
Side effect

Case study

Drug-induced side effects may complicate the picture in severely sick patients in the intensive care unit (ICU) treated with multiple drugs and with several affected organ systems. Presented here is a case where prolonged hyperthermia was suspected to be induced by intravenously administered furosemide.

An 18-year-old girl suffered from verified severe *Mycoplasma pneumoniae* infection with complicating pulmonary hypertension, pronounced cryoglobulinaemia and rhabdomyolysis. The patient was mechanically ventilated, sedated and required haemodialysis for several weeks at the ICU.

At the age of 2 weeks the patient had had surgical treatment of congenital aortic coarctation. She had an asymptomatic mitral stenosis and received no medication.

The *Mycoplasma* infection was treated successfully with intravenous clarithromycin supplemented with meropenem. By day 19, the temperature and C-reactive protein (CRP) (Fig. 1) had normalised, and the cryoglobulins had disappeared by day 27.

At day 24 the patient developed a second episode of hyperthermia (Fig. 1), without a concurrent increase in CRP. Simultaneously, the patient developed dermal blisters, histologically described as oedema with modest lymphocytic inflammation without eosinophilia. The patient was persistently hyperthermic and exhaustive investigation failed to detect ongoing infection.

During this hyperthermia period, the patient was continuously infused with furosemide, remifentanyl and actrapid. Moreover, treatment consisted of meropenem and methylprednisolone (iv), esomeprazole and paracetamol, and dalteparin (Fig. 1). To exclude drug-induced side effects, furosemide, dalteparin and esomeprazole were discontinued on day 29. Within 2 days the temperature and heart rate declined, and the skin manifestations vanished.

The patient was rechallenged with two doses of furosemide 5 mg iv on day 32, which triggered an almost simultaneous increase in heart rate and temperature (Fig. 1 inset) and caused the blisters to reappear. After discontinuation of furosemide, all three symptoms quickly faded.

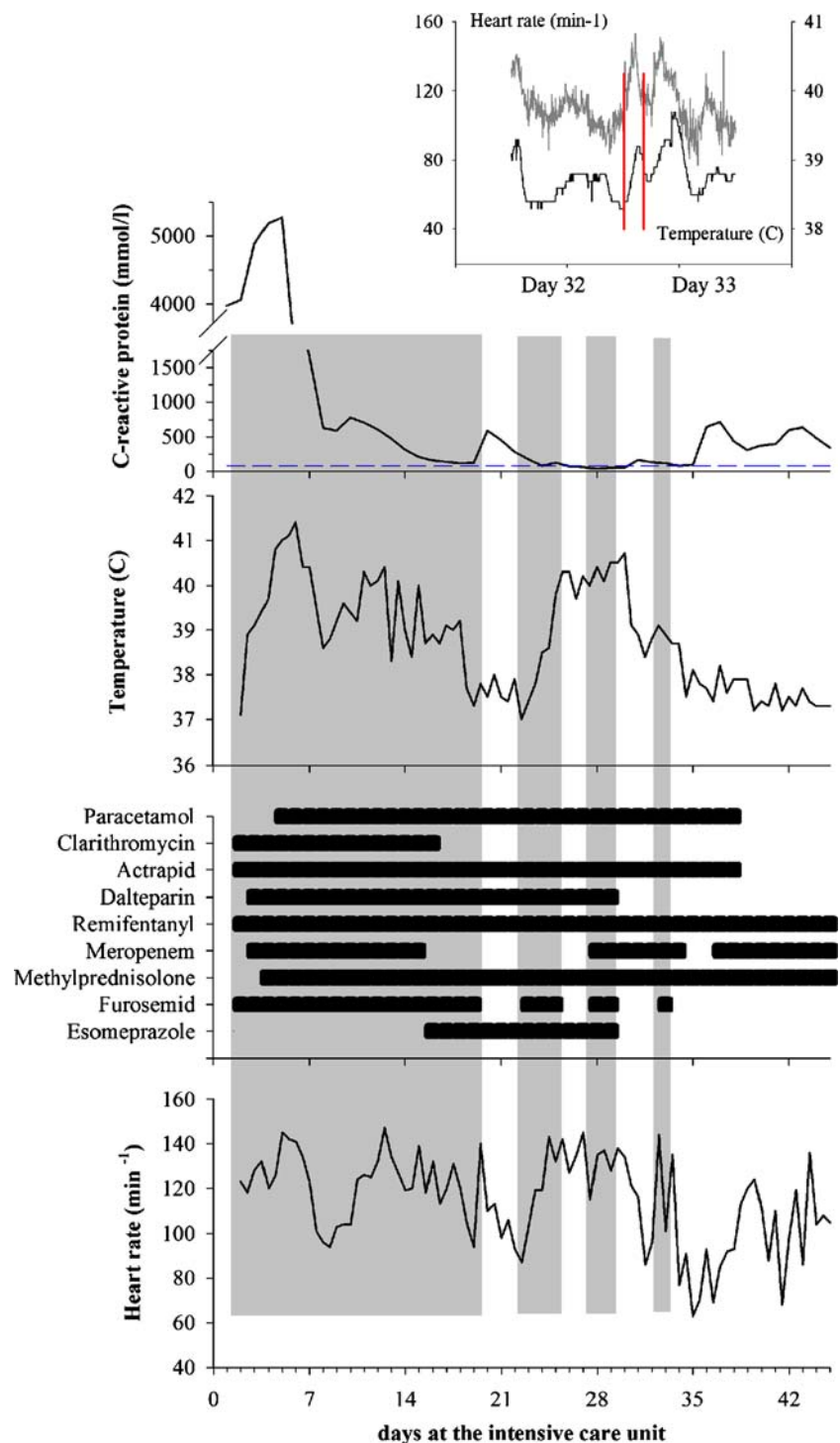
Meropenem, esomeprazole and dalteparin were reintroduced later and were all well-tolerated.

The authors declare that they have no conflicts of interest.

L. Ebdrup (✉) · M. Storgaard
Department of Infectious Diseases, Aarhus University Hospital,
Skejby Sygehus,
8200 Aarhus, Denmark
e-mail: lotteebdrup@dadlnet.dk

C. M. Pedersen · M. H. Andersen
Department of Anaesthesiology and Intensive Care Medicine,
Aarhus University Hospital,
Skejby Sygehus,
Aarhus, Denmark

Fig. 1 C-reactive protein (CRP), temperature, medication and heart rate during ICU admittance. Plasma CRP was measured daily. Temperature (intravasal) and heart rate were registered automatically every 5 min (Scoop Siemens SC 9000XL). Furosemid (Nycomed), remifentanyl and actrapid were continuously infused. Meropenem, methylparacetamol (1 g \times 4) and esomeprazole were administered daily via the nasogastric tube



In conclusion, furosemide is suspected of causing hyperthermia. Neither the European (EMA) nor the Danish Medicines Agency has issued any reports of furosemide-induced hyperthermia in adolescents, and the literature is sparse [1–3]. Drug-induced fever is a serious morbidity that may prompt exhaustive evaluation and cause prolonged hospitalisation.

References

1. Clegg HW, Riopel DA (1995) Furosemide-associated fever. *J Pediatr* 126(5 Pt 1):817–818
2. Amir J, Varsano I (1996) Furosemide-associated fever. *J Pediatr* 128(1):163–164
3. Prandota J (2001) Clinical pharmacology of furosemide in children: a supplement. *Am J Ther* 8(4):275–289