



HAL
open science

Anatomic distribution of avian Borna virus in parrots, its occurrence in clinically healthy birds and ABV- antibody detection

Michael Lierz, Hafez Mohamed Hafez, Kirsi Honkavuori, Achim D. Gruber,
Philipp Olias, Elsayed M Abdelwhab, Andrea Kohls, Ian W Lipkin, Thomas
Briese, Ruediger Hauck

► To cite this version:

Michael Lierz, Hafez Mohamed Hafez, Kirsi Honkavuori, Achim D. Gruber, Philipp Olias, et al..
Anatomic distribution of avian Borna virus in parrots, its occurrence in clinically healthy birds and
ABV- antibody detection. *Avian Pathology*, 2009, 38 (06), pp.491-496. 10.1080/03079450903349238 .
hal-00540170

HAL Id: hal-00540170

<https://hal.science/hal-00540170>

Submitted on 26 Nov 2010

HAL is a multi-disciplinary open access archive for the deposit and dissemination of scientific research documents, whether they are published or not. The documents may come from teaching and research institutions in France or abroad, or from public or private research centers.

L'archive ouverte pluridisciplinaire **HAL**, est destinée au dépôt et à la diffusion de documents scientifiques de niveau recherche, publiés ou non, émanant des établissements d'enseignement et de recherche français ou étrangers, des laboratoires publics ou privés.



Anatomic distribution of avian Borna virus in parrots, its occurrence in clinically healthy birds and ABV- antibody detection

Journal:	<i>Avian Pathology</i>
Manuscript ID:	CAVP-2009-0090.R1
Manuscript Type:	Original Research Paper
Date Submitted by the Author:	03-Sep-2009
Complete List of Authors:	Lierz, Michael; Justus-Liebig-University of Giessen, Clinic for Birds, Reptiles, Amphibians and Fish Hafez, Hafez; Faculty of Veterinary Medicine- Free University Berlin, Institute of Poultry Diseases Honkavuori, Kirsi; Columbia University, Center for Infection and Immunity Gruber, Achim; Freie Universitaet Berlin, Institute for Veterinary pathology Olias, Philipp; Free University of Berlin, Department of Veterinary Pathology Abdelwhab, Elsayed; Faculty of Veterinary Medicine- Free University Berlin, Institute of Poultry Diseases Kohls, Andrea; Free University of Berlin, Institute for Poultry Diseases Lipkin, Ian; Columbia University, Center for Infection and Immunity Briese, Thomas; Columbia University, Center for Infection and Immunity Hauck, Ruediger; Faculty of Veterinary Medicine- Free University Berlin, Institute of Poultry Diseases
Keywords:	lymphoplasmatic ganglioneuritis, proventricular dilatation disease, laser-capture microdissection, psittacines

SCHOLARONE™
Manuscripts

For Peer Review Only

Cavp-2009-0090.R1

Anatomic distribution of avian Borna virus in parrots, its occurrence in clinically healthy birds and ABV- antibody detection

Michael Lierz^{1,4*}, Hafez M. Hafez¹, Kirsi S Honkavuori², Achim D. Gruber³, Philipp Olias³, Elsayed M. Abdelwhab¹, Andrea Kohls¹, W. Ian Lipkin², Thomas Briese², Ruediger Hauck¹

¹Institute for Poultry Diseases, Freie Universitaet Berlin, Germany ²Center for Infection and Immunity, Mailman School of Public Health, Columbia University, New York, USA

³ Institute for Veterinary Pathology, Freie Universitaet Berlin, Germany ⁴Currently: Clinic for Birds, Reptiles, Amphibians and Fish, Justus-Liebig-Universitaet Giessen, Germany

Short title: Avian Borna virus in Psittacines

* Corresponding author: Clinic for Birds, Reptiles, Amphibians and Fish, Justus-Liebig-Universitaet Giessen, Frankfurter Str. 91-93, 35392 Giessen, Germany e-mail: lierz.michael@vetmed.uni-giessen.de; Tel: +49-641-9938430; Fax: +49-641-9938439

Received: 10 June 2009

Abstract

Proventricular dilatation disease (PDD) is a fatal infectious disease of birds that primarily affects psittacine birds. Although a causative agent has not been formally demonstrated, the leading candidate is a novel avian Borna virus (ABV) detected in post-mortem tissue samples of psittacids with PDD from the USA, Israel and recently Germany. Here we describe the presence of ABV in a parrot with PDD as well as in clinically normal birds exposed to birds with PDD. In two ABV positive post-mortem cases the tissue distribution of ABV was investigated by quantitative real time reverse transcription polymerase chain reaction. Viremia was observed in a PDD affected bird whereas a restriction of ABV to nerve tissue was found in the not PDD affected bird. Healthy birds from the same aviary as the affected birds were also found to harbour the virus; 19/59 (32.2%) tested positive for ABV RNA in cloacal swabs, providing the first evidence of ABV in clinically healthy birds. In contrast, 39 birds from the same geographic area, but from two different aviaries without PDD cases in recent years, had negative cloacal swabs. ABV RNA-positive, clinically healthy birds demonstrated the same serological response as the animal with confirmed PDD. These results indicate that ABV infection may occur without clinical evidence of PDD and suggest that cloacal swabs can enable the non-invasive detection of ABV infection.

Introduction

Proventricular dilatation disease (PDD) is a fatal disorder of birds and a major threat to endangered parrot populations (Lublin *et al.*, 2006; Doneley *et al.*, 2007), including one of the world's most endangered bird species, the Spix's macaw (*Cyanopsitta spixii*). It is characterized by dilatation of the proventriculus, digestive malfunction, and cachexia. Definitive diagnosis depends on histologic demonstration of lymphocytic infiltrates in the brain, spinal cord, peripheral nerves and myenteric ganglia (Lutz and Wilson, 1991; Vice, 1992; Gregory, 1995; Sullivan *et al.*, 1997; Gregory *et al.*, 1998; Berhane *et al.*, 2001; Lierz, 2005; Lublin *et al.*, 2006; Perpignan *et al.*, 2007). A viral aetiology of PDD has been presumed (Gough *et al.*, 1996; Gregory *et al.*, 1998) and several viruses were proposed, including adenovirus, coronavirus, herpesvirus, polyomavirus, eastern equine encephalitis virus and western equine encephalitis virus (Mannl *et al.*, 1987; Sullivan *et al.*, 1997; Vice, 1992; Gregory, 1995; Gregory *et al.*, 1998; Grund *et al.*, 2002; Gough *et al.*, 2006; Lublin *et al.*, 2006; Orosz & Dahlhausen, 2007), however, none was confirmed and most recently avian paramyxovirus 1 was ruled out (Deb *et al.*, 2008). A leading candidate only emerged when two independent research groups recently identified a novel avian Borna virus (ABV) in PDD-affected birds (Honkavuori *et al.*, 2008; Kistler *et al.*, 2008). In one study of US parrots, 3/3 (100%) animals with PDD, and 0/4 (0%) without PDD, had ABV in brain, proventriculus and adrenal gland (Honkavuori *et al.*, 2008). In the other study, ABV was detected in 5/8 (62.5%) PDD-birds from the US and 5/7 (71%) such birds from Israel, but not in non-diseased controls (n=5 and 14, respectively) (Kistler *et al.*, 2008). Both studies showed less than 70% nucleotide conservation of the avian sequences to those of the mammalian Borna disease virus (BDV), and indicated that these viruses represent a novel species with multiple divergent genotypes, possibly forming a separate genus (Honkavuori *et al.*, 2008, Kistler *et*

al., 2008). In a subsequent report ABV was described in six parrots in Europe with clinical PDD symptoms, in which ABV was not restricted to cells of the nervous system and the presence of ABV in the feces led the authors to posit a possible fecal-oral transmission route (Rinder *et al.*, 2009). In the same study seven birds with clinical signs of PDD were tested negative. Borna virus infection has been previously proposed for an outbreak of neurologic disease in ostriches based on serologic data (Malkinson *et al.*, 1993). Borna virus sequences have also been detected by PCR in mallard (*Anas platyrhynchos*) and jackdaw (*Corvus monedula*) droppings (Berg *et al.*, 2001), however, in these instances viral sequences were closely related to those of mammalian BDV and distinct from the recently identified ABV. A reservoir for ABV, its geographic distribution, modes of transmission, and causative relationship to PDD remain to be determined.

Materials and Methods

Animals and samples. In a parrot collection from a private breeder in Germany, consisting of 61 birds, two male salmon-crested cockatoos (*Cacatua moluccensis*) were euthanized (Z178/08) or died with PDD-like symptoms (Z1/09) within a period of 2 months. Z178/08 demonstrated wasting symptoms and shedding of undigested seeds in feces before it was euthanized. From this bird a crop biopsy free of lymphoplasmatic ganglioneuritis, taken two weeks prior to death was also available for investigation. Z1/09, kept in the neighbouring cage of Z178/08, died of ulcerative enteritis but no evidence of nutritional compromise. Tissue samples, blood and cloacal swabs from both birds were collected for histological and molecular biological investigations (see Table 1). For molecular biological analysis tissues

were placed immediately after sampling into RNA*later* (Qiagen, Hilden, Germany) and stored within 2 hours after sampling at -80°C until processing.

Other samples included cloacal swabs of the remaining 59 unaffected, clinically healthy birds in the same collection, and from 39 healthy birds in two different collections in the same geographic area of Germany that had not experienced any PDD-cases in the past 6 years (control group). Swabs were processed within 3 hours after sampling as described below. In several cases serum samples were obtained and stored frozen at -20°C until investigated.

Laser-capture microdissection. Samples of nerves, nerve ganglia, stroma and glandular structures of the proventriculus and adrenal gland of Z1/09 were isolated by laser-capture microdissection (LCM), using 8 µm thick frozen sections mounted on glass slides covered with polyethylene naphthalate membrane (PALM Microlaser Technologies, Bernried, Germany) (Klopfleisch & Gruber, 2009). The size of the excised tissue sections ranged from 1.4×10^4 to $3.0 \times 10^4 \mu\text{m}^2$. The isolated tissue pieces were laser pressure catapulted into caps of 0.5-ml reaction tubes containing 40 µl of lysis buffer (Nucleo Spin RNA XS; Macherey & Nagel, Düren, Germany) and stored at -80°C.

Quantitative real time RT-PCR (RT-qPCR). RNA was extracted from tissue samples using the RNeasy kit (Qiagen), and from cloacal swabs dissolved in PBS using the QIAamp Viral RNA kit (Qiagen). Extraction of LCM samples was performed using the NucleoSpin kit (Macherey-Nagel). ABV-specific RNA was detected by quantitative real time reverse transcription polymerase chain reaction (RT-qPCR) with primer-probe sets 1367 or 1034/1322 that match different ABV strains (Honkavuori *et al.*, 2008). Tissue samples from Z178/08 were investigated using both primer sets; for all other samples primer set 1034/1322

was used. All PCRs were carried out with the QuantiTect Probe RT-PCR kit (Qiagen). Threshold cycle (Ct) values > 36 were scored negative as determined using serial cloned standard dilutions (Honkavuori *et al.*, 2008).

Sequence determination and analysis. Phylogenetic sequence analysis was performed using a 724 bp fragment spanning the C-terminal end of the N, and the N-terminal part of the P gene (GenBank Acc. No. FJ770253, FJ932550, and FJ932551). Selected PCR products were size-fractionated on agarose gels, purified (QIAquick PCR purification kit; Qiagen), and directly dideoxy-sequenced in both directions with ABI PRISM Big Dye Terminator Cycle Sequencing kits on ABI PRISM DNA Analyzers (Applied Biosystems, Foster City, CA, USA). Sequences were assembled and analyzed using programs of the Wisconsin GCG Package (Accelrys, San Diego, CA, USA). Phylogenetic analysis was performed using www.phylogeny.fr (Dereeper *et al.*, 2008), applying T-coffee for alignment (Notredame *et al.*, 2003), Gblocks 0.91 b for curation (Castresana, 2000), and PhyML 3.0 for phylogenetic reconstruction (Guindon & Gascuel, 2003); all with standard settings.

Western blot analysis. ABV proteins P (strain 1322, Genbank Acc. No. FJ169441; 30 kDa, including tag and vector sequence) and N (strain 1367, Genbank Acc. No. FJ169440; 49 kDa, including tag and vector sequence) were expressed in prokaryotic systems (pDest17 Gateway vector; Invitrogen, Carlsbad, CA, USA) and purified by affinity chromatography using Ni-NTA-Agarose (Qiagen). In addition, P (24 kDa) and N (40 kDa) of mammalian BDV were analyzed in comparison (Briese *et al.*, 1995). Protein concentrations were estimated by Bradford assay (Bio-Rad, Hercules, CA, USA), and 100 ng of each protein in Laemmli buffer were boiled for 5 min and size-fractionated by discontinuous 4-15% gradient sodium dodecyl sulfate-polyacrylamide gel electrophoresis (Laemmli & Favre, 1973). Proteins were

transferred to nitrocellulose membranes (Bio-Rad) and blocked with 2% nonfat dry-milk in 20 mM Tris-HCl, pH 7.6, 137 mM NaCl, 0.1% Tween 20 (TTBS) overnight at room temperature (Towbin *et al.*, 1979). Membranes were incubated with bird sera (1:1000 in TTBS) for 1 h at room temperature; washed three times with TTBS, and then incubated with peroxidase-conjugated goat anti-bird immunoglobulin (1:2000 in TTBS; Bethyl Laboratories, Montgomery, TX, USA) for 1 h at room temperature. After three washes with TTBS, the membranes were developed using the ECL Western blot detection system (Amersham Biosciences, Arlington Heights, IL, USA) and scanned for chemiluminescence using a Storm 840 imager (Molecular Dynamics, Sunnyvale, CA, USA).

Results

Clinically affected birds. Post-mortem tissue samples as well as plasma and a cloacal swab from each of two birds, Z178/08 and Z1/09, were collected and analyzed by RT-qPCR. The euthanized bird Z178/08 was emaciated and had an enlarged thin-walled proventriculus filled with feed. Histological examination revealed lymphocytic infiltrates in the epicardial ganglia, the Purkinje fibres, ventriculus, proventriculus (indicating PDD), crop, ischiatic nerve and less pronounced in brain. No abnormalities were found in the adrenals, cloaca, or intestine. All tissues, including those where no histologic abnormalities were found, as well as the plasma and cloacal swab were positive for ABV RNA (Table 1) suggesting a viremia. A crop biopsy taken 2 weeks prior to death that showed no histologic abnormality, was also positive (Ct 24.7, primer set 1034/1322). Bird Z1/09 had an enlarged proventriculus filled with feed and adhesions consistent with slight peritonitis. Histopathological examination revealed a lymphocytic encephalitis and adrenalitis. Nerve tissue from the heart, proventriculus,

intestine, crop, liver and spleen was not affected demonstrating that the bird did not suffer from PDD. The intestine showed severe ulcerative enteritis in conjunction with acute purulent peritonitis as the cause of death. Viral burden was lower than in Z178/08 and measured in the two tissues with lymphocytic infiltrates, cerebrum and adrenal gland, and also in proventriculus, ventriculus and duodenum, but was absent in crop, liver, pancreas, cloacal swab and blood (Table 1).

Two sets of nerve ganglia tissue obtained by LCM from the proventriculus of bird Z1/09 yielded positive PCR signal (Ct: 35.24/ 34.93), whereas two sets each of stroma and glandular tissue were negative. LCM-samples of the adrenal gland revealed positive signal from two sets of nerve ganglia tissue (Ct: 33.94/ 31.93); six samples of interrenal and chromafin portions with diffuse infiltrations by lymphocytes and plasmacells were negative.

Clinical healthy birds Nineteen of 59 parrots (32.2%) from the same aviary as the two dead birds had ABV-RNA in their cloacal swabs (Table 2). The presence of ABV was not correlated with age, sex or cage location, including cases with positive and negative birds in the same cage. Positive birds were distributed across all age groups (juvenile - 20years old). No ABV-positive cloacal swabs were detected in any of 39 birds from two PDD-free independent aviaries located in the same geographic area (Table 2).

PCR detection of ABV RNA in healthy contacts was corroborated by Western blot analysis. A healthy Hispaniolan amazon (*A. ventralis*, Z14/09-13; Ct=19.7, Table 2) and a healthy Lesser sulphur crested cockatoo (*C. sulphurea parvula*, Z14/09-05; Ct=24.9, Table 2) showed both a similar antibody response when compared to PDD-affected bird Z178/08 (Figure 1). A strong reaction to ABV N with limited cross-reactivity to BDV N was noted; reaction to the P antigen appeared to be weaker and more variable.

Phylogenetic analysis Samples obtained from crop, cerebellum, and proventriculus of bird Z178/08 revealed no sequence variation (GenBank Acc. No. FJ770253). The same was true for sequence obtained from brain and gizzard of bird Z1/09 (GenBank Acc. No. FJ932550). Comparison to four mammalian BDV isolates from horses in Germany and 3 ABV, for which sequence in the respective genome region is available, grouped strain Z178/08 and Z1/09 sequences (100% sequence identity) in the ABV clade and clearly separate from German horse BDV (Figure 2). Strain Z178/08 and Z1/09 from Germany were phylogenetically more similar to strain 1034/1322 from the USA, than were strains 1034/1322 and bil from the USA to one another. Almost identical sequences were also obtained from cloacal swabs of healthy PCR-positive contacts, bird Z14/09-13 (100% identical to Z178/08 and Z1/09) and Z14/09-28 (97% identical to Z178/08 and Z1/09, GenBank Acc. No. FJ932551; Figure 2).

Discussion

Borna disease, a neurological syndrome of ungulates due to infection with BDV, has been endemic in Germany for more than a century (Ludwig *et al.*, 1988; Lipkin & Briese, 2007). Although cross-species transfer between ungulate and bird has been achieved experimentally (Ludwig *et al.*, 1988), its occurrence in nature is unclear. Furthermore, Borna disease of ungulates is not recorded in the USA or Israel despite the presence of a novel Borna virus in PDD-affected birds in both countries (Honkavuori *et al.*, 2008, Kistler *et al.*, 2008). These observations together with the phylogenetic distance between ABV and mammalian BDV strains suggest that, if it occurs, cross species infection appears to be an uncommon event.

Although ABV represents a plausible aetiologic candidate for PDD (Kistler *et al.*, 2008; Honkavuori *et al.*, 2008; Rinder *et al.*, 2009), much of its biology remains to be

characterized. In this study we confirmed the presence of ABV in two birds from the same collection in Germany. Whereas bird Z178/08 had classical symptoms, gross lesions and histological alterations of PDD, bird Z1/09 did not have a clinical presentation consistent with PDD. Despite having a characteristic proventricular enlargement, Z1/09 lacked typical lymphocytic infiltrates in nerve ganglia of the digestive tract. Similarly, whereas ABV-RNA was demonstrated in all organs and even in plasma of the PDD-affected bird Z178/08, ABV RNA was restricted to nerve tissue in non-PDD bird Z1/09, consistent with the pattern of BDV infection found in immunocompetent mammals (Ludwig *et al.*, 1988; Briese *et al.*, 1999). However, it remains obscure why the lymphoplasmatic ganglioneuritis was not detectable in all organs positive for ABV in bird Z178/08 and also missing in the proventriculus of bird Z1/09 despite the fact that ABV was detected in the nerve ganglia of this organ.

Rinder *et al.* (2009) also found ABV extension beyond neural tissues. It is conceivable that early infection or carrier status is characterized by confinement to nerve tissue and that wider distribution only occurs in the late stages of PDD. The presence in healthy birds of ABV RNA in cloacal swabs in association with ABV-specific serum antibodies, which was demonstrated in the present study for the first time, indicates either that ABV is not causally related to PDD or that disease is multifactorial. Differentiating these possibilities awaits formal testing of Koch's postulates. Although shedding of infectious virus remains to be demonstrated, this finding is consistent with a possible transmission mode by sub-clinical individuals, especially as birds of collections not facing PDD were tested ABV negative.

Taken together our results support previous concerns regarding the reliability of histological examination of crop biopsies (Gregory *et al.*, 1996; Berhane *et al.*, 2001) as the recommended method for PDD screening (Sullivan *et al.*, 1997); bird Z178/08 tested negative

by crop biopsy two weeks prior euthanasia due to clinical PDD. The applied RT-qPCR presents an adequate diagnostic addition, although an individual diagnosis based on cloacal swab alone may fail as indicated by bird Z1/09; despite the presence of ABV in brain and adrenal gland, the cloacal swab tested negative. Nonetheless, a cloacal-oral route of transmission is plausible. Furthermore, the observation that ABV sequences can be detected in cloacal swabs by PCR offers the prospect for efficient noninvasive surveillance and diagnosis. Until larger data sets become available, collection of biopsy and cloacal swab for histologic as well as RT-qPCR analyses is recommendable for PDD/ABV diagnosis in psittacine birds. Furthermore, ABV-antibody detection by Western blot analysis may prove useful in diagnosis as well as a screening tool, especially when screening flocks in conjunction with ABV-RNA detection in cloacal swabs.

Acknowledgements

This study was supported by funds provided by the Association for the Conservation of Threatened Parrots (ACTP), Berlin, Germany, by Google.org, and National Institutes of Health awards AI051292 and AI57158 (Northeast Biodefense Center - Lipkin).

References

- Berg, M., Johansson, M., Montell, H. & Berg, A.S.L. (2001). Wild birds as a possible natural reservoir of Borna Diseases Virus. *Epidemiology and Infection*, 127, 173-178.
- Berhane, Y., Smith, D.A., Newman, S., Taylor, M., Nagy, E., Binnington, B. & Hunter, B. (2001). Peripheral neuritis in psittacine birds with proventricular dilatation disease. *Avian Pathology*, 30, 563-570.
- Briese, T., Hatalski, C.G., Kliche, S., Park, Y.S. & Lipkin, W.I. (1995). Enzyme-linked immunosorbent assay for detecting antibodies to Borna disease virus-specific proteins. *Journal of Clinical Microbiology*, 33, 348-351.
- Briese, T., Hornig, M. & Lipkin, W.I. (1999). Bornavirus immunopathogenesis in rodents: models for human neurological diseases. *Journal for Neurovirology*, 5, 604-612.
- Castresana, J. (2000). Selection of conserved blocks from multiple alignments for their use in phylogenetic analysis. *Molecular Biology and Evolution*, 17, 540-552.
- Deb, A., Borjal, R.J., Bürkle, M., Watson, R. & Hammer, S. (2008). Evaluation of Avian Paramyxovirus- 1 serology and crop biopsy for the diagnosis of proventricular dilatation disease in captive Spix's Macaws (*Cyanopsitta spixii*). In: Proceedings of the 7th scientific meeting of the European Association of Zoo and Wildlife Veterinarians (EAZWW), Leipzig Germany, 239-242.
- Dereeper, A., Guignon, V., Blanc, G., Audic, S., Buffet, S., Chevenet, F., Dufayard, J.F., Guindon, S., Lefort, V., Lescot, M., Claverie, J.M. & Gascuel, O. (2008) Phylogeny.fr: robust phylogenetic analysis for the non-specialist. *Nucleic Acids Research*, 36(WSI), W465-W469

- Doneley, R.J.T., Miller, R.I. & Fanning, T.E. (2007). Proventricular Dilatation Disease: An emerging exotic disease of Parrots in Australia. *Australian Veterinary Journal*, 85, 119-123.
- Gough, R.E., Drury, S.E., Harcourt-Brown, N.A. & Higging, R.J. (1996). Virus like particles associated with Macaw Wasting Disease. *Veterinary Record*, 139, 24.
- Gough, R.E., Drury, S.E., Culver, F., Britton, P. & Cavanagh, D. (2006). Isolation of a coronavirus from a green-cheeked Amazon parrot (*Amazon viridigenalis cassin*). *Avian Pathology*, 35, 122-126
- Gregory, C.R. (1995). Proventricular Dilatation Disease. In: Ritchie , B.W. Avian Viruses, Function and Control. Wingers Publishing Inc, Lake Worth, Florida; 439-448.
- Gregory, C.R., Latimer, K., Campagnoli, R. & Ritchie, B. (1996). Histologic evaluation of the crop for diagnosis of proventricular dilatation syndrome in psittacine birds. *Journal of Veterinary Diagnostic Investigation*, 8, 76-80.
- Gregory, C.R., Ritchie, B.W., Latimer, K.S., Steffens, W.L., Campagnoli, R.P., Pesti, D. & Lukert, P.D. (1998). Experimental Transmission of Psittacine Proventricluar Dilatation Disease (PDD) and Preliminary Characterization of a Virus Recovered from Birds with Naturally Occurring and Experimentally Induced PDD. University of Georgia. [cited 2009 Feb 23] Available from http://www.toolady.com/library/avian/bird_health/bird_disease/pdd/experiment.htm.
- Grund, C.H., Werner, O., Gelderbrom, H.R., Grimm, F. & Kösters, J. (2002). Avian Paramyxovirus serotype 1 isolates from the spinal cord of parrots display a very low virulence. *Journal of Veterinary Medicine, Series B*, 49, 445-451.
- Guindon, S. & Gascuel, O. (2003). A simple fast and accurate algorithm to estimate large phylogenies by maximum likelihood. *Systems Biology*, 52, 696-694

- Honkavuori, K.S., Schivaprasad, H.L., Williams, B.L., Quan, P.L., Hornig, M., Street, C., Palacios, G., Hutchison, S.K., Franca, M., Egholm, M., Briese, T. & Lipkin, W.I. (2008). Novel Borna Virus in psittacine birds with Proventricular Dilatation Disease. *Emerging Infectious Diseases*, 14, 1883-1886.
- Kistler, A.L., Gancz, A., Clubb, S., Skewes-Cox, P., Fischer, K., Sorber, K., Chiu, C.Y., Lublin, A., Mechani, S., Farnoushi, Y., Greninger, A., Wen, C.C., Karlene, S.B., Ganem, D. & Derisi, J.L. (2008). Recovery of divergent avian bornaviruses from cases of proventricular dilatation disease: identification of a candidate etiologic agent. *Virology Journal*, 5, 88.
- Klopfleisch, R. & Gruber, A.D. (2009). Differential expression of cell cycle regulators p21, p27 and p53 in metastasizing canine mammary adenocarcinomas versus normal mammary glands. *Research Veterinary Science*, 87, 91-96.
- Laemmli, U.K. & Favre, M. (1973). Maturation of the head of bacteriophage T4. I. DNA packaging events. *Journal of Molecular Biology*, 80, 575-599.
- Lierz, M. (2005). Proventricular Dilatation Disease. In: Harcourt- Brown, N. & Chitty, J. (editors). *BSAVA Manual of Psittacine Birds*. 2nd ed. Replika Press Pvt. Ltd., India; 161-162.
- Lipkin, W.I. & Briese, T. (2007). Bornaviridae. In: Knipe, D.M. & Howley, R.D. (editors). *Virology*. 5th ed. Philadelphia:Lippincott, Williams & Wilkins, 1829-1851.
- Lublin, A., Mechani, S., Farnoushi, I., Perl, S. & Bendheim, U. (2006). An outbreak of proventricular dilatation disease in a psittacine breeding farm in Israel. *Israel Journal of Veterinary Medicine*, 61, 16-19.
- Ludwig, H., Bode, L. & Gosztonyi, G. (1988). Borna disease: a persistent virus infection of the central nervous system. *Progress in Medical Virology*, 35, 107-151.
- Lutz, M.E. & Wilson, R.B. (1991). Psittacine proventricular dilatation syndrome in an Umbrella cockatoo. *Journal of the American Veterinary Medical Association*, 198, 1962-1964.

- Malkinson, M., Weisman, Y., Ashash, E., Bode, L. & Ludwig, H. (1993). Borna disease in ostriches. *Veterinary Record*, 133, 304.
- Mannl, A., Gerlach, H. & Leipold, R. (1987). Neuropathic Gastric Dilatation in Psittaciformes. *Avian Diseases*, 31, 214-221.
- Notredame, C., Higgins, D.G. & Heringa, J. (2003). T-Coffee: A novel method for fast and accurate multiple sequence alignment. *Journal of Molecular Biology*, 302, 205-217.
- Orosz, S.E. & Dahlhausen, R.D. (2007). Proventricular Dilatation Syndrome in an Amazon Parrot: Possible Role of PCR Diagnosis of Paramyxovirus-1 for Presumptive Diagnosis. Proceedings of the 9th European AAV Conference- 7th Scientific Meeting, Zürich, 27-28.
- Perpiñan, D., Fernández- Bellon, H., López, C. & Ramis, A. (2007). Lymphoplasmacytic myenteric, subepicardial, and pulmonary ganglioneuritis in four nonsittacine birds. *Journal of Avian Medicine and Surgery*, 21, 210-214.
- Rinder, M., Ackermann, A., Kempf, H., Kaspers, B., Korbel, R. & Staeheli, P. (2009). Broad tissue and cell tropism of avian borna virus in parrots with proventricular dilatation disease. *Journal of Virology*, 83, 5401-5407.
- Sullivan, N.D., Mackie, J.T., Miller, R.I. & Giles, A. (1997). First case of psittacine proventricular dilatation syndrome (macaw wasting disease) in Australia. *Australian Veterinary Journal*, 75, 674.
- Towbin, H., Staehelin, T. & Gordon, J. (1979). Electrophoretic transfer of proteins from polyacrylamide gels to nitrocellulose sheets: procedure and some applications. *Proceedings of the National Academy of Science*, 76, 4350-4354.
- Vice, C.A. (1992). Myocarditis as a Component of Psittacine Proventricular Dilatation syndrome in a Patagonian Conure. *Avian Diseases*, 36, 1117-1119.

Table 1: Detection of ABV RNA by RT-qPCR, and observed histological alterations in different tissues of two Salmon-crested cockatoos (*C. moluccensis*). Bird Z179/08 was euthanized due to PDD, bird Z1/09 died from ulcerative enteritis. Samples of Z178/08 were analyzed in parallel with primer/probe sets CT 1367 and CT 1034/1322, samples of Z1/09 with primer/probe set CT1034/1322 (Honkavuori et al., 2008). Ct-values > 36 are scored as negative.

Tissue	Histology	Z178/08		Z1/09	
		CT1367	CT1034/1322	Histology	CT1034/1322
Crop	L.g.	22.4	17.5	w. p. a.	Neg.
Ventriculus	L. g.	23.8	16.7	n.d.	27.1
Proventriculus	L.g.	21.5	17.1	w. p. a.	26.9
Duodenum	w. p. a.	24.3	17.2	U. e.	34.1
Pancreas		25.8	18.1	w. p. a.	Neg.
Heart	L.g.	24.6	19.6	w. p. a.	n.d.
Chest-muscle	w. p. a.	27.4	22.1	n.d.	n.d.
Cerebrum	L.e.	21.2	15.9	L.e	n.d.
Cerebellum	L.e.	22.8	16.7	L.e	25.6
Lung	slight anthracosis	23.8	17.6	w. p. a.	n.d.
Spleen	hyperplasia	24	17.1	w. p. a.	n.d.
N. ischiadicus	L.n.	23	18.4	n.d.	n.d.
Adrenal gland	w. p. a.	22.6	16.6	L.a.	30.8
Liver	slight hepatitis	24.2	17.7	w. p. a.	Neg.
Kidney	slight nephritis	22.2	15.1	w. p. a.	n.d.
Plasma	n.d.	30.4	28.5	n.d.	Neg. ^a
Cloacal swab	n.d.	23.7	17	n.d.	Neg.

L.a.: lymphocytic adrenalitis

L.e.: lymphocytic encephalitis

L. g.: lymphoplasmatic ganglioneuritis

L. n.: lymphocytic neuritis

n.d.: not done

Neg.: negative

U.e.: ulcerative enteritis

w. p. a. : without pathological alteration

^a: Clotted heart blood as sample

Table 2: Species distribution of examined parrots from Germany and their RT-qPCR results from cloacal swabs. Ct-values > 36 are scored as negative.

Species	Total	Negative	Positive	Ct 1034/1322
PDD affected parrot collection (n=59)				
Lilac-crowned amazon (<i>A. finschi</i>)	1	0	1	28.5
Hispaniolan amazon (<i>A. ventralis</i>)	4	2	2	19.7/ 21.5
Turquoise-fronted amazon (<i>A. aestiva</i>)	1	1	0	---
Yellow-headed amazon (<i>A. oratrix</i>)	2	2	0	---
Yellow-naped amazon (<i>A. auropalliata</i>)	6	4	2	28.7/ 35.5
Red-lored amazon (<i>A. autumnalis</i>)	2	1	1	35.3
Red-browed amazon (<i>A. rhodocorytha</i>)	11	3	8	24.2/ 25/ 23/ 22.8/ 21.3/ 21/ 23/ 21.5
Cuban amazon (<i>A. leucocephala</i>)	5	3	2	27.1/ 29.5
Red-spectacled amazon (<i>A. pretrei</i>)	2	2	0	---
Vinaceous amazon (<i>A. vinacea</i>)	7	6	1	22.7
Orange-winged amazon (<i>A. amazonica</i>)	2	2	0	---
Scarlet macaw (<i>Ara macao</i>)	3	3	0	---
Grey parrot (<i>Psittacus erithacus</i>)	2	2	0	---
Major Mitchel's Cockatoo (<i>C. leadbeateri</i>)	2	1	1	25.2
Lesser sulphur-crested cockatoo (<i>C. sulphurea parvula</i>)	2	1	1	24.9
Citron-crested cockatoo (<i>C. sulphurea citrinocristata</i>)	2	2	0	---
Salmon-crested cockatoo (<i>C. moluccensis</i>)	5	5	0	---
Total number of birds	59	40/ 67.8%	19/ 32.2%	
Control parrot collections (n=39)				
Yellow-headed amazon (<i>A. oratrix</i>)	4	4	0	---
Orange-winged amazon (<i>A. amazonica</i>)	2	2	0	---
Yellow-naped amazon (<i>A. auropalliata</i>)	4	4	0	---
Haycynth macaw	4	4	0	---

<i>(Anodorhynchus hyacinthinus)</i>				
Blue-winged macaw	1	1	0	---
<i>(Ara maracana)</i>				
Blue-and-yellow macaw	8	8	0	---
<i>(Ara ararauna)</i>				
Spix's macaw	2	2	0	---
<i>(Cyanopsitta spixii)</i>				
Maroon-fronted parrot	6	6	0	---
<i>(Rhynchopsitta terrisi)</i>				
Thick-billed parrot	8	8	0	---
<i>(Rhynchopsitta pachyrhynchus)</i>				
Total number of birds	39	39/ 100%	0	---

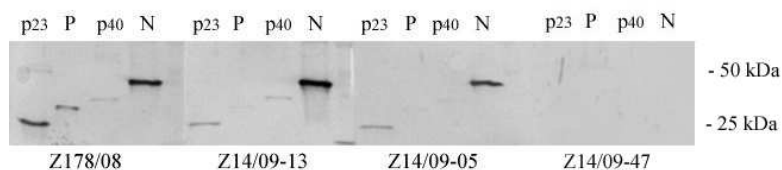
A.: Amazona

C.: Cacatua

Figure Legends

Fig. 1: Sera from PDD-affected bird Z178/08, asymptomatic ABV PCR-positive birds Z14/09-13 and Z14/09-05 and a healthy PCR-negative bird Z14/09-47, were evaluated by Western blot analysis using recombinant ABV P and N, as well as BDV P and N (p23, p40), demonstrating a strong reaction to ABV N with limited cross-reactivity to BDV N.

Fig. 2: Maximum likelihood tree based on nucleotide sequences of five ABV (strain Z178/08, Acc. No. FJ770253, identical to strain Z1/09, Acc.No. FJ932550; strain Z14/09/28 Acc.No. FJ932551; strain 1367, Acc. No. FJ169440.1; strain 1034_1322, Acc. No. FJ169441.1; strain bil, Acc. No. EU781967.1) and four Borna disease virus strains from mammals (strain No/98, Acc. No. AJ311524.1; strain V, Acc. No. U04608.1; strain He80, Acc. No. L27077.2; strain He/80/FR, Acc. No. AJ311522.1). Numbers near the nodes indicate the branch support. The unit of the scale bar is substitutions per site.



Sera from PDD-affected bird Z178/08, asymptomatic ABV PCR-positive birds Z14/09-13 and Z14/09-05 and a healthy PCR-negative bird Z14/09-47, were evaluated by Western blot analysis using recombinant ABV P and N, as well as BDV P and N (p23, p40), demonstrating a strong reaction to ABV N with limited cross-reactivity to BDV N.
222x138mm (96 x 96 DPI)

View Only

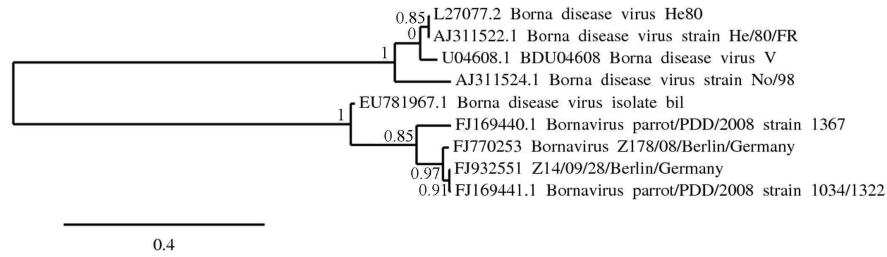


Fig. 2: Maximum likelihood tree based on nucleotide sequences of five ABV (strain Z178/08, Acc. No. FJ770253, identical to strain Z1/09, Acc.No. FJ932550; strain Z14/09/28 Acc.No. FJ932551; strain 1367, Acc. No. FJ169440.1; strain 1034_1322, Acc. No. FJ169441.1; strain bil, Acc. No. EU781967.1) and four Borna disease virus strains from mammals (strain No/98, Acc. No. AJ311524.1; strain V, Acc. No. U04608.1; strain He80, Acc. No. L27077.2; strain He/80/FR, Acc. No. AJ311522.1). Numbers near the nodes indicate the branch support. The unit of the scale bar is substitutions per site.

624x158mm (96 x 96 DPI)