



**HAL**  
open science

## Comparison of the pathogenicity of QX-like, M41 and 793/B IBV strains from different pathological conditions.

Zsofia Benyeda

► **To cite this version:**

Zsofia Benyeda. Comparison of the pathogenicity of QX-like, M41 and 793/B IBV strains from different pathological conditions.. Avian Pathology, 2009, 38 (06), pp.449-456. 10.1080/03079450903349196 . hal-00540166

**HAL Id: hal-00540166**

**<https://hal.science/hal-00540166>**

Submitted on 26 Nov 2010

**HAL** is a multi-disciplinary open access archive for the deposit and dissemination of scientific research documents, whether they are published or not. The documents may come from teaching and research institutions in France or abroad, or from public or private research centers.

L'archive ouverte pluridisciplinaire **HAL**, est destinée au dépôt et à la diffusion de documents scientifiques de niveau recherche, publiés ou non, émanant des établissements d'enseignement et de recherche français ou étrangers, des laboratoires publics ou privés.



**Comparison of the pathogenicity of QX-like, M41 and 793/B IBV strains from different pathological conditions.**

Journal:	<i>Avian Pathology</i>
Manuscript ID:	CAVP-2009-0068.R2
Manuscript Type:	Original Research Paper
Date Submitted by the Author:	11-Aug-2009
Complete List of Authors:	Benyeda, Zsofia; Szent István University, Pathology & Forensic Veterinary Medicine
Keywords:	QX IBV, false layer, nephropathogen, PCR

SCHOLARONE™  
Manuscripts

Only

Cavp-2009-0068.R2

Comparison of the pathogenicity of QX-like, M41 and 793/B Infectious Bronchitis strains from different pathological conditions

Zsófia Benyeda<sup>1\*</sup>, Tamás Mató<sup>2</sup>, Tibor Süveges<sup>2</sup>, Éva Szabó<sup>4</sup>, Veronika Kardi<sup>2</sup>, Zsolt Abonyi-Tóth<sup>3</sup>, Miklós Rusvai<sup>1</sup> and Vilmos Palya<sup>2</sup>

<sup>1</sup>*Department of Pathology and Forensic Veterinary Medicine, Faculty of Veterinary Science, Szent István University, István u. 2., 1078 Budapest, Hungary;* <sup>2</sup>*CEVA-Phylaxia Co. Ltd., Szállás u. 5., 1107 Budapest, Hungary;* <sup>3</sup>*Department of Biomathematics and Informatics, Szent István University, István u. 2., 1078 Budapest, Hungary;* <sup>4</sup>*Prpophyl Ltd., Dózsa Gy. u. 18., 7700 Mohács, Hungary*

Running head title: Pathogenicity of different IBV strains.

\*To whom correspondence should be addressed: Tel.:+ 36 1 478-4178; Fax: + 36 1 478-4284

E-mail: [Benyeda.Zsofia@aotk.szie.hu](mailto:Benyeda.Zsofia@aotk.szie.hu)

*Received: 4 May 2009*

**PLEASE NOTE:**

**FIGURE 1 NOT INCLUDED WITH THIS MANUSCRIPT.**

## Abstract

Five QX-like infectious bronchitis virus (IBV) strains, isolated from different field outbreaks and two reference IBV strains of known serotypes (M41 and 793/B) were used in this study to investigate and compare their pathogenicity for one-day-old SPF chickens. The ability of the strains to inhibit trachea epithelium ciliary activity, to induce immune response, to replicate and to cause histopathological lesions in designated organs was followed by repeated samplings during a period of 42 days post-infection.

Clear differences in pathogenicity and in organ distribution of the three serotypes were found. 793/B had the least capacity to invade the investigated organs, while it produced a good humoral response as measured by ELISA. The QX-like strains generally replicated to higher titres, although differences were found among the five strains in their pathogenicity and affinity for different organs. The Chinese isolate of QX-like virus caused the more severe lesions and induced the highest antibody titres. Severe kidney damage and dilation of the oviduct were the prominent lesions which could be related to the QX-like IBV strains, although neither marked virus replication nor histopathological lesions were not detected in the oviduct.

## Introduction

Infectious Bronchitis Virus (IBV), a coronavirus of chickens, is one of the major causes of economic losses in the poultry industry. The name of the disease refers to its most frequent clinical manifestation, although it can infect many other epithelial cells, including kidney, genital organs and many part of the alimentary tract (Cavanagh & Naqi, 2003). Pathogenicity for the reproductive tract depends on the age of the birds at the time of infection. Infection at an early age may result in false layer syndrome in the case of certain IBV strains (Crinion & Hofstad, 1971), while infection of laying birds produces a range of effects varying from eggshell pigment changes to production drops (Jones & Jordan, 1971).

Since IBV was first described several serotypes in addition to the originally identified Massachusetts (Mass.) type of IBV were found (reviewed by Fabricant, 1998). The majority of the previously unknown serotypes or variants, identified in the past two decades around the world, have either disappeared or become endemic in certain geographical areas (Bochkov *et al.*, 2006), while some of them have become widespread and predominant in the majority of the countries with a significant poultry industry over a period of time (Terregino *et al.*, 2008).

In September 1996, an outbreak of disease, characterized mainly by swelling of the stomach, occurred in chicken flocks in Qingdao, China. The disease was diagnosed as infectious bronchitis and the associated virus was designated QX IBV (YuDong *et al.*, 1998). Not much later further diseases associated with either proventriculitis or severe kidney damage occurred in IBV vaccinated flocks in many Chinese provinces (Yu *et al.*, 2001; Liu & Kong, 2004). Egg production problems were also observed in some cases in the period between 1995 and 2004 (Liu & Kong,

2004). Following a survey of various poultry flocks in the Far Eastern and European region of Russia, genetically similar strains were reported between 1998 and 2002 (Bochkov *et al.*, 2006).

More recently, different surveys and observations in both commercial and backyard chicken flocks conducted in the Netherlands (Landman *et al.*, 2005), Northern Italy (Beato *et al.*, 2005; Zanella *et al.*, 2006), France, Germany and Belgium (Worthington *et al.*, 2008) confirmed the emergence of new variant IBV strains which were genetically related to the Chinese QX IBV isolates. Since then, the prevalence of the so-called QX-like strains has been reported in Poland (Domanska-Blicharz *et al.*, 2006), the United Kingdom (Gough *et al.*, 2008) and Hungary (Benyeda *et al.*, 2008). After this variant reached the European continent, it tended to spread fast among susceptible flocks and reached high prevalence within a few years (Worthington *et al.*, 2008).

However, although all QX-like strains isolated until now are genetically closely related, clinical signs and pathological changes in connection with QX outbreaks have shown considerable variation. Mortality and morbidity also varied among the infected flocks, irrespective of previous IB vaccination.

To investigate the pathogenicity and tissue tropism of QX-like strains, a comprehensive experiment, covering the possible sites of virus replication, was conducted in SPF chickens. Five QX-like strains, isolated from outbreaks in different countries, were selected to represent the main characteristics of this genotype, while a Mass. and a 793/B strain were included to demonstrate the difference between the previously known and the recently emerged serotypes.

## Materials and methods

**Chicken.** One-day-old Spafas, Line 22, specific pathogen free (SPF) chickens were randomly divided into 8 groups. The birds were kept in confined, segregated animal houses, situated a distance apart and were supplied with feed and water *ad libitum*. Each group was cared for by a different individual. Observation of the birds always started with the control group, using new protective clothing for each group to prevent cross-contamination. During the *post mortem* and tissue samplings the same order was always followed and new sterile forceps and scissors were used for each group. During subsequent procedures, all precautions were taken to keep the samples free of any contamination. Finally, from each group the identity of the virus detected was confirmed by sequencing part of the S1 gene. No cross-contamination was detected in any group.

**Viruses.** Five different QX-like strains (Chinese, French, Slovakian, Greek and Hungarian) isolated from different pathological conditions and from different countries (Table 1), along with the M41 and 793/B reference IBV strains were used. The QX-like strains were identified by RT-PCR (Cavanagh *et al.*, 1999) and the amplified products were sequenced as described by Keeler *et al.* (1998). Genotype identification was done by comparison with sequences in the NCBI GenBank database. The five strains showed the closest relation to the Chinese QX isolate (Liu & Kong, 2004) in the amplified fragment of the S1 gene. Accession numbers of the strains are shown in Table 1. The reference Mass. (M41) and 793/B strains were received from the Veterinary Laboratories Agency, Avian Virology Department (Weybridge). The M41 strain was in the 3<sup>rd</sup>, while the 793/B strain in the 2<sup>nd</sup> passage

when received. Both strains were then given one more passage before use in this experiment. Each virus was propagated by inoculating 9-11 day-old embryonated SPF eggs *via* the allantoic cavity.

**Experimental design.** Four groups (A, B, C, D), each of 50 chickens, were inoculated with one of the four QX-like IBV strains (Chinese, French, Slovakian, and Greek respectively). Three groups (E, F, G), each of 50 chickens and 50 cockerels, were inoculated with the Hungarian QX-like, M41 or 793/B IBV strains respectively. In each case the inoculation was done by intranasal and intraocular routes with 40µl containing  $1 \times 10^5$  median embryo infective doses (EID<sub>50</sub>) of the relevant strain. 20 chickens and 10 cockerels were retained as non-inoculated controls. The birds were monitored daily by visual observation for clinical signs following gentle moving. Between the 4<sup>th</sup> and 42<sup>nd</sup> days post infection (DPI), each group were sampled eight times (4, 7, 11, 14, 21, 28, 35 and 42 DPI) to measure the ciliary activity in the trachea and to determine the lesions and the level of virus RNA in selected organs by histology and real-time RT-PCR. Five birds from groups A, B, C, D; five hens and five cockerels from groups E, F, G and two hens and one cockerel from the control group were randomly selected and killed humanly at each sampling date. Blood was also taken before killing the birds for antibody detection.

**Ciliary activity inhibition.** The whole trachea was removed with sterile forceps and scissors immediately after killing chickens at 4, 7, 11 and 14 DPI. From the upper, middle and the lower part of the trachea, 3, 4, 3 rings, respectively were cut and placed into MEM-H medium in a 96-well plate. The rings were then examined under low power magnification and score for ciliostasis on a scale from 0 (100% activity) to



4 (no activity) according Cook *et al.* (1999). The mean scores of the different strains were then compared to represent differences between the respiratory pathogenicity of the strains.

**Antibody responses.** An indirect ELISA was used to measure the humoral response in chickens. Sera collected at 4, 14, 21 and 42 DPI were examined for the presence of IBV antibodies. The M41 strain, prepared from allantoic fluid of IBV-inoculated embryonated SPF eggs, was used as antigen for the reaction. The protein concentration of the antigen was 0.48 mg/ml, after purification and rehydration. Purified IBV antigen diluted 200-fold in 100µl 0.05M carbonate buffer (pH 9,6) was added to the wells of low-binding microtitre plates (Tomtec) and incubated for 1h at 37°C, then overnight at 4°C. After washing, the plates were treated with PBS containing 0.5% milk powder and incubated for 1h at 37°C. After washing, 100µl of 100-fold dilution of test serum samples were added and incubated for 1h at 37°C. After washing again, the wells were covered with 100µl of anti-chicken IgG-HRP (Phylabs) in 2000-fold dilution and incubated for 1h at 37°C. The serum and the conjugate were diluted in PBS containing 0.05% Tween 20 and 0.5 M NaCl. Serial two-fold dilutions of a reference serum with known titre (VN titre  $\log_2$  9.3) for calibration and one negative serum were added to each plate at the same (100-fold) dilution. The plates were read using a Microtitre plate reader. The titres of the sera were calculated using the calibration curve, which was depicted in log dilution – OD form. Hyperimmune serum used for the calibration was previously titrated by VN test, therefore the OD values of the sera were transformed to the corresponding VN titre. A serum was considered positive with a VN titre  $\geq 3 \log_2$ .

**Real-Time RT-PCR (RT RT-PCR).** Tissue samples from the following organs were taken with sterile forceps and scissors for use in the PCR: trachea, lung, glandular stomach, ileum, caecal tonsil, kidney, ovary, oviduct and testis (the testis only in the case of groups E, F, G and the Control)s. Samples from the first four or five samplings were processed, except those samples which were collected from groups that had negative results at the previous sampling. The same organ samples from the five chicks of an experimental group at each sampling date were then homogenized and pooled. RNA was extracted by Tri-Reagent (Sigma) according to the manufacturer's instruction. The purified RNA was used as template for the reverse transcription using MMLV-reverse transcriptase (Promega) and random hexamer primers (Promega) according to the manufacturer's description. For the detection of IBV-specific nucleic acid Taqman-probe based group-specific real-time PCR assay was used as previously described (Callison *et al.*, 2006).

Forward primer IBV5\_GU391, located at nucleotide positions 391-408 of the IBV M41 strain genome; reverse primer IBV5\_GL533 located at nucleotide positions 533-512 of the IBV M41 strain genome, and Taqman® dual-labeled probe IBV5\_G located at nucleotide positions 494-473 of the IBV M41 strain genome were used to amplify and detect a 143-bp fragment of the 5'-untranslated region (UTR gene). The mixture for each tube consisted of 10µl of TaqMan® Master Mix, 0.2µl of 2pM IBV probe, 1µl of 10pM forward primer, 1µl of 10pM reverse primer, 5.8µl of distilled water, to produce a total volume of 18µl. 2µl of cDNA extract was added to 18µl of master mix, and negative controls containing nuclease-free water instead of cDNA were included in each run. The thermal profile for the RT RT-PCR was 95°C

for 10 min, followed by 50 cycles of 95°C for 15sec, 60°C for 1sec and 72°C for 1 sec. PCR amplification was performed by using ABI Prism 7500 Real-Time PCR System. Amplifications were performed with serial dilutions ( $10^{-1}$  to  $10^{-7}$ ) of a reference 4/91 IBV strain with known titre ( $10^{7.26}$  EID<sub>50</sub>/0.2 ml) to assess the quantification assay. The software generated a standard curve by plotting the cycle threshold (CT) values against each standard dilution of reference strain.

Results were analyzed in terms of CT values. A CT value below 40 cycles was regarded as a positive result, and a negative result was represented by a CT value equal to, or more than 40. The titre of the strains, calculated by the software, were transformed to log<sub>10</sub> titre values and represented in diagrams to show the distribution of virus RNA in different organs.

**Histology.** At *post mortem* examination, samples of tissue from the following organs were taken for histological examination: trachea, lung, glandular stomach, ileum, kidney, ovary, oviduct and, only in the case of the Hungarian strain, M41, 793/B and the control group, testis also. At the early sampling dates, when the ovary was too small to divide in two parts, three out of the five ovaries of a given group were taken for histology, while the rest remained for the RT RT-PCR. They were fixed in 8% buffered formaldehyde solution for one day and processed by standard histological procedure, embedded in paraffin wax and cut in 4µm sections (Stevens, 2007). All the sections were stained with haematoxylin and eosin and examined by light microscopy for lesions due to IBV infection.

**Statistical analysis.** Collected data were analysed using one-way analysis of variance (ANOVA) to see if there were any significant difference between the effects of the

different IBV strains. Groups were compared to controls and to each other. In the case of the ciliary activity inhibition test, mean scores of a group on a given day were generated to provide normal distribution. Results from the 4<sup>th</sup>, 7<sup>th</sup> and 11<sup>th</sup> sampling dates only were analysed, since at 14 DPI no more adverse affect was observed. The ELISA results from the 14<sup>th</sup> and succeeding samplings were used. In the case of RT-PCR, results of groups, which had a standard deviation close to zero compared to others, were excluded. Where titres at different days did not show normal distribution, weighing with DPI or its reciprocal was applied. All statistical analyses were conducted using R Development Core Team (2008).

## Results

**Clinical findings.** At 3 DPI, birds appeared depressed with ruffled feathers and respiratory distress in groups A, E and F. The respiratory signs could also be detect in groups C and D after gently moving the chickens. At 4 DPI respiratory signs became obvious and lasted until the 7<sup>th</sup> DPI in all groups. By the time of the 3<sup>rd</sup> sampling (11 DPI) only group A showed slight respiratory signs and watery diarrhoea. No bird died during the experiment and no clinical sign could be observed in the control group.

**Gross pathological findings.** Slight hyperaemia with catarrhal exudate was seen at 4 DPI in the trachea in all infected groups. Air-sac lesions were present from 11 DPI, except in group D. In the air sacs, fine to marked thickening of the air sac wall, accompanied by exudate accumulation was found until 21 DPI.

Nephroso-nephritis with varying severity developed from 11 DPI and was observed occasionally during the whole experiment in all groups except groups F and G.

The characteristic dilatation of the oviduct developed in all groups infected with the QX-like strains (Figure 1), but no change were observed in groups infected with M41 or 793/B. The dilatation and serous fluid accumulation was obvious from 14 DPI and was detected sporadically during the whole experiment. It developed in group A most often and was seen only once in group B (Table 2.).

**Inhibition of ciliary activity.** Inhibition of ciliary activity was measured at 4, 7, 11 and 14 DPI in the trachea. When comparing the mean scores resulting from infection with different strains (Figure 2), the highest inhibitory activity could be seen either at 4 or 7 DPI, while ciliary activity became completely normal by 14 DPI. The severity of the ciliostasis caused by the Greek QX-like and 793/B strains proved to be the mildest, while the effect of the rest of the strains were significantly more severe ( $p < 0.05$ ) compared to these strains and to the control group.

**Antibody response.** Antibody response was measured at 4, 14, 21 and 42 DPI. Analysing the mean titres induced by infection with the different strains (Figure 3), the cut-off level of the ELISA titre was reached by the Greek strain at 14 DPI, by the Chinese, 793/B and M41 strains at 21 DPI, while by the Hungarian and French not until 42 DPI. The mean titre induced by Slovakian strain remained under the level of positivity. The highest values developed in groups A, G and F. Statistical analyses showed that the rise in ELISA antibody titre was significant following infection with all strains ( $p < 0.05$ ), except the French and Slovakian isolates. The difference in the

titre induced by the Chinese and French strains was also found to be significant ( $p=0.0347$ ).

**Real-Time RT-PCR.** Amplifications were performed with serial dilutions ( $10^{-1}$  to  $10^{-7}$ ) of a reference 4/91 IBV strain with known titre ( $10^{7.26}$  EID<sub>50</sub>/0.2 ml) to assess the quantification assay. The software generated a standard curve by plotting the cycle threshold (CT) values against each standard dilution of reference strain. The result showed that a detectable signal above the threshold occurred at 22.16 cycles. Log titres measured in different groups and organs were compared to present the main differences between strains.

Analysing the values of QX-like strains together, it was found that the highest titres could be measured at 4 DPI in the trachea, lung, ovary and kidney, while values peaked at 7 DPI in the ileum, caecal tonsil and testis. The values dropped to zero by 28 DPI, while virus in the caecal tonsil was detectable until 35 DPI and persisted until the last day of the experiment in the kidney. No significant amount of virus RNA could be detected in the glandular stomach and in the oviduct in any of the groups. In the group infected with M41, the highest titre could be measured at 4 DPI in the trachea and caecal tonsil. In the testis, lung, kidney and ovary the titres peaked at 7, 11, 11, 14 DPI respectively and had dropped to zero by the following sampling date. In the ileum virus RNA barely reached the detection level. The amount of the 793/B strain was low in almost all the investigated organs except the ovary, where titres were highest at 4 DPI and then dropped suddenly. Almost no RNA was found in the lung and the kidney. The titre in the ovary peaked at 7 and 21 DPI with considerable values. Mean titres of the QX-like strains were considerably higher than those reached by 793/B and higher in most cases than the ones reached by M41.

By analysing the 7 strains separately, remarkable variation was found in the titres reached by the different QX-like strains in the different organs. In the *trachea*, the Chinese, French, Slovakian and Greek strains replicated at higher titres than M41 and their levels dropped to zero only by 21 or 28 DPI (Figure 4a). The level of replication of the Hungarian strain was close to 793/B, but its duration was longer. The presence of RNA of all QX-like strains in the *lung* was higher than that of M41 and 793/B on the 4<sup>th</sup> day (Figure 4b). The values dropped during the following sampling dates and reached zero by 21 or 28 DPI.

In the *ileum* considerable amounts of virus RNA were found only in the groups infected with the QX-like strains (Figure 4c). The titre of the Greek strain was the highest and peaked at 14 DPI.

The amount of RNA detected in the *caecal tonsils* and its duration were considerably higher and longer in the case of QX-like strains than of M41 and 793/B (Figure 4d). The presence of the viral genome of the QX-like strains was detected from the 4<sup>th</sup> day and dropped under detection level between 28 and 42 DPI, except for the Hungarian strain which fell to zero by 14 DPI.

In the *kidney* a similar trend to that seen in caecal tonsils was found, except for the longer persistence of viral RNA and for a short but remarkable presence in the case of the M41 strain (Figure 4e). In groups infected with the Chinese, French, Hungarian and Slovakian isolates, titres were the highest on the first or second sampling dates. Virus RNA persisted during the whole experiment and could be detected even on the last sampling day in groups A and C. All QX-like strains, except for the Greek one, showed significant levels ( $p < 0.05$ ) of virus replication in this organ.

In the *ovary*, all strains except M41, were present at detectable levels until 28 DPI, but in low titres. Only the Slovakian strain reached high values (Figure 4f). *Testis* samples were collected only from groups infected with the Hungarian, M41 and 793/B strains. The group infected with 793/B was positive only at 4 DPI (Figure 4g), while the viral genome of M41 strain could be detected on the 7<sup>th</sup> day, when it reached higher titres than 793/B. The Hungarian QX-like strain was detectable on 4 consecutive sampling dates.

**Histology.** In the *tracheas* severe lesions were found from 4 DPI, but the mucosal epithelium had completely recovered by 21DPI. Histopathological changes could be divided in three stages: (i) in the acute (degenerative) phase, degeneration and desquamation of ciliated epithelial and mucus secreting cells were the most prominent findings; (ii) in hyperplastic stage, which started 4 DPI, but became explicit at 7 DPI, slight mononuclear and lympho-histiocytic cellular infiltration, proliferation of mucus glands and newly formed epithelial cells were the more characteristic lesions; (iii) in the recovery phase the mucus membrane was complete, although epithelial metaplasia and a few inflammatory cells were still present. Each strain had an obvious respiratory effect, although lesions induced by the Greek QX-like and 793/B strains were less severe.

The relatively mild lesions in the *lungs* were mainly confined to the primary and secondary bronchi and occasionally to the parenchyma. The changes and their evolution in bronchi were similar to those observed in the trachea, but less severe. In the parenchyma, nodular or diffuse mononuclear cell infiltration was observed during the whole observation period. These lesions were more pronounced in the groups infected with the Greek and French QX-like strains.



The tunica propria of the *glandular stomach* was well populated with lymphocytes in most of the samples of each group. Although the severity of infiltration was variable and some samples exhibited very pronounced lesions, we regarded them as aspecific findings because of the physiological histological structure of this organ and the negligible replication measured by RT RT-PCR.

In the *ileum* histopathological changes were poor and sporadic. Mild mononuclear cell infiltration, restricted to the mucus membrane was observed in a few samples.

Histopathological lesions developed in all parts of the *kidney*. Lesions were seen as early as 4 DPI and lasted during the whole experiment. The most abundant lesion was the nodular or diffuse lympho-histiocytic infiltration between the tubules, especially adjacent to the distal tubules and collecting ducts. The mucus membrane of the collecting ducts was also well populated with inflammatory cells. Necrosis and desquamation were detected, but usually restricted to single epithelial cells. Although lesions were found even at the last sampling date, pronounced fibrosis, tubular degeneration and uric acid deposition was only occasionally observed. The described changes were found in all infected groups but the severity varied among them. All chickens receiving QX-like strains produced more severe kidney lesions than those infected with either M41 or 793/B.

Lesions in the *ovary* developed rarely. The most prominent alterations were observed in groups infected with the Slovakian strain. In this group calcium deposition in the primer oocytes was observed, beside the mononuclear cell infiltration.

Characteristic dilation and serum-like fluid accumulation in the *oviduct* was observed in all groups infected with QX-like strains, although very few alterations

could be seen microscopically in this organ. In the case of dilated oviducts, the flattening of the developing folds and the thinning of the wall could be seen. Focal mononuclear cell infiltration beneath the epithelial layer or the serosal lining was observed in a few cases. In the groups infected with QX-like strains, alteration could be detected microscopically only in a proportion of the animals (1 or 2 birds) per sampling. Most often chickens in the groups infected with the Chinese, Slovakian or Hungarian strains developed these lesions.

Histopathological findings in the *testis* were mild and sporadic. Slight lymphohistiocytic cell infiltration was found in the interstitium or in the epididymis. No remarkable difference in the appearance or in the severity among the three investigated IB virus strains was seen.

## **Discussion.**

Since the respiratory form of IB was first reported in the 1930s (reviewed by Fabricant, 1998), nephropathogenic (Albassam *et al.*, 1986; Cavanagh & Naqi, 2003) and enterotropic (Ambali & Jones, 1990) IBV strains, some with affinity for the reproductive tract (Cavanagh & Naqi, 2003) have been reported. In 2003 a new serotype of IBV emerged in Europe causing severe kidney damage, high morbidity and occasionally false layer syndrome in IB vaccinated flocks. The isolated IBV strains differed completely from the serotypes reported prior to 2004 in Europe. These serotypes seemed to be in close relationship (96-99%) with the Chinese QX strains (Liu & Kong, 2004), based on the S1 fragment of the spike protein (Worthington *et al.*, 2008). The strains included in this study showed also close genetic relationship to

the Chinese QX strain and to each other (data not shown, personal communication V. Palya).

Clinical signs and pathological changes induced by QX-like strains differ in some aspects from those which have been reported following infection by the IBV strains prevalent in Europe during the last few decades. Therefore, a comprehensive experiment was performed to investigate the exact effect and pathogenicity of the emerging QX-like strains and to compare them to each other and to the well known IBV serotypes (M41 and 793/B). The results presented in this paper indicate clear differences in the tissue tropism and pathogenicity of the three serotypes.

The majority of QX-like isolates caused similar respiratory effects to M41. However, unlike to previous studies where either severe kidney damage (Butcher *et al.*, 1990, Chen *et al.*, 1996), or alterations to the reproductive tract (Crinion & Hofstad, 1971) was reported following M41 infection, in our study no remarkable lesions or presence of viral RNA was detected in the other organs. This discrepancy might be caused by different passage levels, experimental conditions and design, breed or age of the birds, or by the use of different strains of M41. Relatively mild clinical and pathological signs and limited virus replication was found in the birds infected with the 793/B strain. Respiratory signs were most characteristic, which somehow was not confirmed by the ciliary activity test or by the RT RT-PCR. The histological lesions also indicated very low pathogenicity of this isolate. Interestingly this virus strain was able to induce high humoral antibody response following infection. As the passage level of this strain was similar to the others and all groups of chicks received the same amount of virus, the serological results obtained remain obscure.

As we expected, the QX-like strains showed broader tissue tropism and higher pathogenicity than the tested reference IBV strains in this experiment. Besides the pronounced respiratory lesions, nephroso-nephritis and oviduct dilation developed and slight histopathological lesions were found in some of the ileum samples. However, variation in pathogenicity and affinity for the investigated organs was found among the strains. The mildest lesions in the kidney and respiratory tract were caused by the Greek isolate, although it seemed that this strain has higher affinity for the alimentary tract. This is partly in accordance with the field observation, where no kidney lesion was reported, and the virus was isolated from the intestine. The higher passage number needed for isolation of this strain might also reflect its weaker pathogenicity.

In this study, all the QX-like strains tested were able to cause dilation and fluid accumulation in the oviduct as well as kidney damage, while proventriculitis, which was reported in the case of the original QX isolate (YuDong *et al.*, 1998), did not develop. Beside these lesions, most QX-like isolates had also strong affinity for the respiratory tract, causing pronounced clinical signs. The absence of obvious histological changes and measurable replication in the oviduct, point to the presumption that the dilated lumen and the accumulation of serous fluid in the oviduct is not the direct effect of the virus. It is likely that infection during the first week of life may affect the last step of the post embryo development of the oviduct, which enables the Müllerian duct (developing oviduct) to open into the lumen of the cloaca. An inflammation and the subsequent stricture of the wall of the cloaca or of the entry of the oviduct might led to the obstruction of the posterior part of the oviduct resulting in fluid accumulation and dilatation, which has been observed in field cases and reproduced in our experimental infection with QX-like IBV strains.

The possible adverse effect of IBV strains on the testis were reported recently due to repeated use of attenuated vaccine or wild virus infection. Epididymal stone formation or inflammation was observed after infection with IBV, which could be a possible reason for the development of a later infertility (Boltz *et al.*, 2004; Villarreal *et al.*, 2007). Cockerels were included in the groups inoculated with the Hungarian QX-like, 793/B and M41 strains and in the control group to investigate this possible impact. Presence of the virus genome was proven by RT RT-PCR, but no obvious histopathological lesions, apart from an occasional, mild inflammation, were found. However our results do not exclude the detrimental effect of the strains, because investigation of the epididymis beside the testis was in most cases not possible, as the size of this organ at a young age made it very difficult to obtain a proper section, and this might have caused false negative results.

The Chinese QX isolate, the only one originating from the Far East, where this genotype emerged, caused the most severe lesions, along with the highest levels of virus detection in the majority of the investigated organs. The reason for its stronger effect might be explained by the possible closer relationship with the original QX isolate. As there is no evidence until now, as to how QX-like strains reached the European continent, transport by migratory birds may be the most likely explanation (Bochkov *et al.*, 2006). Irrespective of the ability of IBV to replicate in these species, the genome of the numerous transported IBV strains could undergo mutation and recombination, which might also continue in the susceptible poultry flocks and eventually might result in strains with altered pathogenicity. Therefore further, detailed investigation of the genome is needed to clarify how closely these strains are related genetically and whether there is any connection between the pathogenicity and the molecular properties of these strains.

**References.**

- Albassam, M.A., Winterfield, R.W. & Thacker, H.L. (1986). Comparison of the nephropathogenicity of four strains of infectious bronchitis virus. *Avian Diseases*, 30, 468-476.
- Ambali, A.G. & Jones, R.C. (1990). Early pathogenesis in chicks of infection with an enterotropic strain of infectious bronchitis virus. *Avian Diseases*, 34, 809-817.
- Beato, M.S., De Battisti, C., Terregino, C., Drago, A., Capua, I. & Ortali, G. (2005). Evidence of circulation of a Chinese strain of infectious bronchitis virus (QXIBV) in Italy. *Veterinary Record*, 156, 720.
- Benyeda, Zs., Mató, T., Süveges, T. & Palya, V. (2008). Comparison of the pathogenicity of QX-like IBV strains from different pathological conditions. Proceedings of the XXIII<sup>rd</sup> World's Poultry Congress. Brisbane, Australia.
- Bochkov, Y.A., Batchenko, G.V., Shcherbakova, L.O., Borisov, A.V. & Drygin, V.V. (2006). Molecular epizootiology of avian infectious bronchitis virus in Russia. *Avian Pathology*, 35, 379-393.
- Boltz, D.A., Nakai, M. & Bahr, J.M. (2004). Avian Infectious Bronchitis Virus: A Possible Cause of Reduced Fertility in the Rooster. *Avian Diseases*, 48, 909-915.
- Butcher, G.D., Winterfield, R.W. & Shapiro, D.P. (1990). Pathogenesis of H13 nephropathogenic infectious bronchitis virus. *Avian Diseases*, 34, 916-921.
- Callison, S.A., Hilt, D.A., Boynton, T.O., Sample, B.F., Robison, R., Swayne, D.E. & Jackwood, M.W. (2006). Development and evaluation of a real-time Taqman RT-PCR assay for the detection of infectious bronchitis virus from infected chickens. *Journal of Virological Methods*, 138, 60-65.
- Cavanagh, D., Mawditt, K., Britton, P. and Naylor, C. J. (1999). Longitudinal field studies of infectious bronchitis virus and avian pneumovirus in broilers using type-specific polymerase chain reactions, *Avian Pathology* 28, 593-605.

- Cavanagh, D. & Naqi, S.A. (2003). Infectious bronchitis. In Y.M. Saif, H.J. Barnes, J.R. Glisson, A.M. Fadly, L.R. McDougald & D.E. Swayne, (2003). *Diseases of Poultry* 11<sup>th</sup> edn (pp.101-119). Ames: Iowa State Press.
- Chen, B.Y., Hosi, S., Nunoya, T. & Itkura, C. (1996). Histopathology and immunohistochemistry of renal lesions due to infectious bronchitis virus in chicks. *Avian Pathology*, 25, 269-283.
- Cook, J. K. A., Orbell, S. J., Woods, M. A., & Huggins, M. B. (1999). Breadth of protection of the respiratory tract provided by different live-attenuated infectious bronchitis vaccines against challenge with infectious bronchitis viruses of heterologous serotypes. *Avian Pathology*, 28, 477-485.
- Crinion, R.A.P. & Hofstad, M.S. (1971). Pathogenicity of four serotypes of avian infectious bronchitis virus for the oviduct of young chickens of various ages. *Avian Diseases*, 16, 351-363.
- Domanska-Blicharz, K., Minta, Z. & Smietanka, K. (2006). Molecular studies on infectious bronchitis virus isolated in Poland. Proceedings of the V<sup>th</sup> *International Symposium on Avian Corona- and Pneumoviruses*. (pp. 147-153). Rauschholzhausen, Germany.
- Fabricant, J. (1998). The early history of infectious bronchitis. *Avian diseases*, 42, 648-650.
- Gough, R.E., Cox, W.J., Welchman, D. de B., Worthington, K.J. & Jones R.C. (2008). Chinese QX strains of infectious bronchitis virus isolated in the UK. *Veterinary Record*, 162, 99.
- Jones, R.C. & Jordan, F.T.W. (1971). The site of replication of infectious bronchitis virus in the oviducts of experimentally infected hens. *Veterinary Record*, 89, 317-318.
- Keeler, C.L., Reed, K.L., Nix, W.A. & Gelb, J. (1998). Serotype identification of avian infectious bronchitis virus by RT-PCR of the peplomer (S-1) gene. *Avian Diseases*, 42, 275-284.
- Landman, W.J.M., Dwars, R.M. & de Wit, J.J. (2005). High incidence of false layers in (re)production hens supposedly attributed to a juvenile infectious bronchitis virus infection. Proceedings of the XIV<sup>th</sup> *International Congress of the World Veterinary Poultry Association*. (p. 369). Istanbul, Turkey.

- Liu, S. & Kong, X. (2004). A new genotype of nephropathogenic infectious bronchitis virus circulating in vaccinated and non-vaccinated flocks in China. *Avian Pathology*, 33, 321-327.
- R Development Core Team (2008). R: A language and environment for statistical computing. R Foundation for Statistical Computing, Vienna, Austria. ISBN 3-900051-07-0, URL <http://www.R-project.org>.
- Stevens, A. (2007). The haematoxylin. In: J.D. Bancroft & A. Stevens, (2007). *Theory and Practice of Histological Techniques*, 6th edn (pp. 107-118). Edinburgh, Churchill Livingstone.
- Terregino, C., Toffan, A., Beato, M.S., De Nardi, R., Vascellari, M., Meini, A., Ortali, G., Mancin, M. & Capua, I. (2008). Pathogenicity of a QX strain of infectious bronchitis virus in specific pathogen free and commercial broiler chickens, and evaluation of protection induced by a vaccination programme based on the Ma5 and 4/91 serotypes. *Avian Pathology*, 37, 487-493.
- Villarreal, L.Y., Brandão, P.E., Chacón, J.L., Assayag, M.S., Maiorka, P.C., Raffi, P., Saldenber, A.B., Jones, R.C. & Ferreira A.J. (2007). Orchitis in roosters with reduced fertility associated with avian infectious bronchitis virus and avian metapneumovirus infections. *Avian Diseases*, 51, 900-904.
- Yu, L., Jian, Y., Low, S., Wang, Z., Nam, S. J., Liu, W. & Kwang, J. (2001). Characterisation of three infectious bronchitis virus isolates from China associated with proventriculitis in vaccinated chickens. *Avian Diseases*. 45, 416-424.
- YuDong, W., YongLin, W., ZiChun, Z., GenChe, F., YiHai, J., XiangE, L., Jiang, D. & ShuShuang, W. (1998). Isolation and identification of glandular stomach type IBV (QX IBV) in chickens. *Chinese Journal of Animal Quarantine*. 15, 1-3.
- Worthington, K. J, Currie, R.J.W. & Jones, R.C. (2008). A reverse transcriptase-polymerase chain reaction survey of infectious bronchitis virus genotypes in Western Europe from 2002 to 2006. *Avian Pathology* 37, 247-257.
- Zanella, A., Barbieri, I., Gavazzi, L. & Tosi, G. (2006). Avian infectious bronchitis: isolation of an umpteenth new serotype of virus in Italy.



Proceedings of the Vth *International Symposium on Avian Corona- and Pneumoviruses*. (pp. 161-168). Rauschholzhausen, Germany.

For Peer Review Only

**Table 1.** *Origin and history of the QX-like IBV strains used.*

	Origin of QX-like strains used in this study				
	Chinese	French	Slovakian	Greek	Hungarian
Reference code	D532/9	D535/4	D722	D591/2	D683
Year of isolation	2005	2005	2006	2005	2006
Type of chicken	Broiler	Layer	Broiler	Broiler	Broiler
Age of birds at submission	3-4 weeks	10 days	2 weeks	5 weeks	4-5 weeks
Clinical signs/pathological lesions	Kidney lesions	Respiratory signs	Respiratory signs, kidney lesions	Respiratory signs	Respiratory signs, kidney lesions
Organ used for virus isolation	Caecal tonsils	Trachea <sup>a</sup>	Kidney	Intestine	Intestine
Passage number used for infection	2	1	2	3	2
GenBank Accession number	GQ403795	GQ403796	GQ403797	GQ403798	GQ403799

<sup>a</sup> Sample was provided by R.C. Jones (University of Liverpool, UK)

**Table 2.** *Occurrence of oviduct dilation and serum-like fluid accumulation in the oviduct following inoculation with different IB strains*

IB isolate	Day post inoculation							
	4	7	11	14	21	28	35	42
Chinese	0 <sup>a</sup>	0	0	2	0	2	0	1
French	0	0	0	0	1	0	0	0
Slovakian	0	0	0	1	1	1	0	0
Greek	0	0	0	1	1	0	0	0
Hungarian	0	0	0	0	0	1	1	0
M41	0	0	0	0	0	0	0	0
793/B	0	0	0	0	0	0	0	0
Control	0 <sup>b</sup>	0	0	0	0	0	0	0

<sup>a</sup> number of birds with lesion/3 birds sampled.

<sup>b</sup> Two birds sampled in control group.

**Figure 1.** *Characteristic dilatation of the oviduct induced by the Chinese QX-like isolate.*

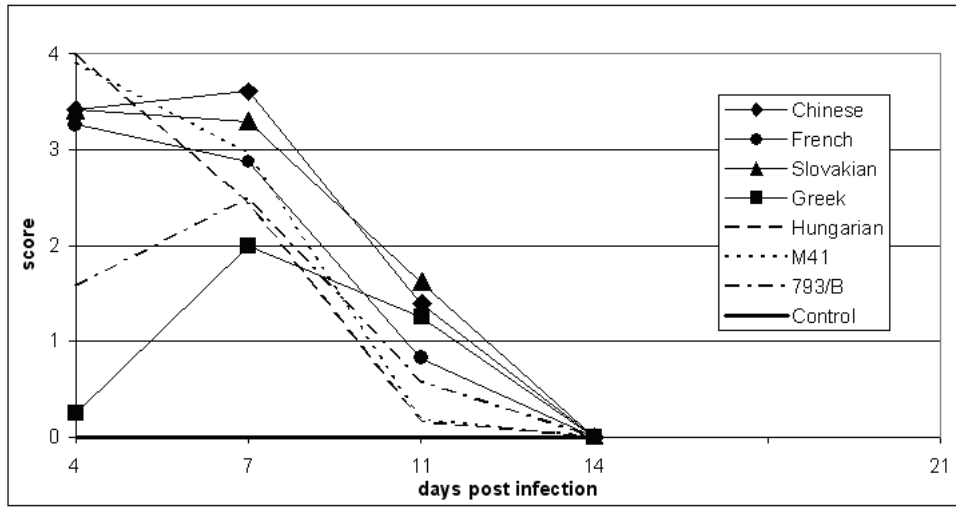
**Figure 2.** *Mean scores of the different IBV strains in ciliary activity test.*

**Figure 3.** *Antibody response induced by different IBV strains.*

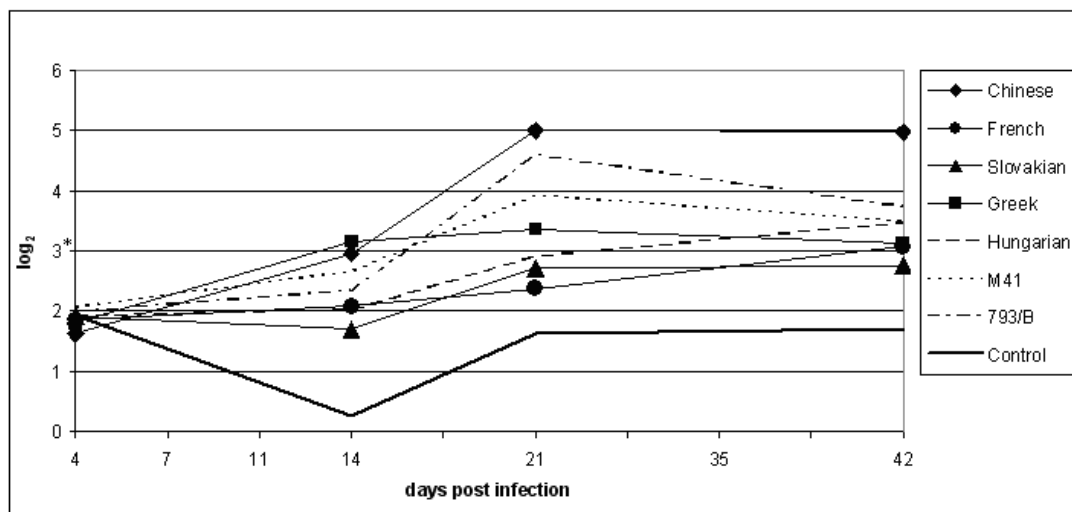
**Figure 4.** *Detection of viral RNA by real time RT-PCR in the trachea (a), lung (b), ileum (c), caecal tonsil (d), kidney (e), ovary (f) and testis (g).*

For Peer Review Only

**Figure 2.** Mean scores of the different IBV strains in ciliary activity test.

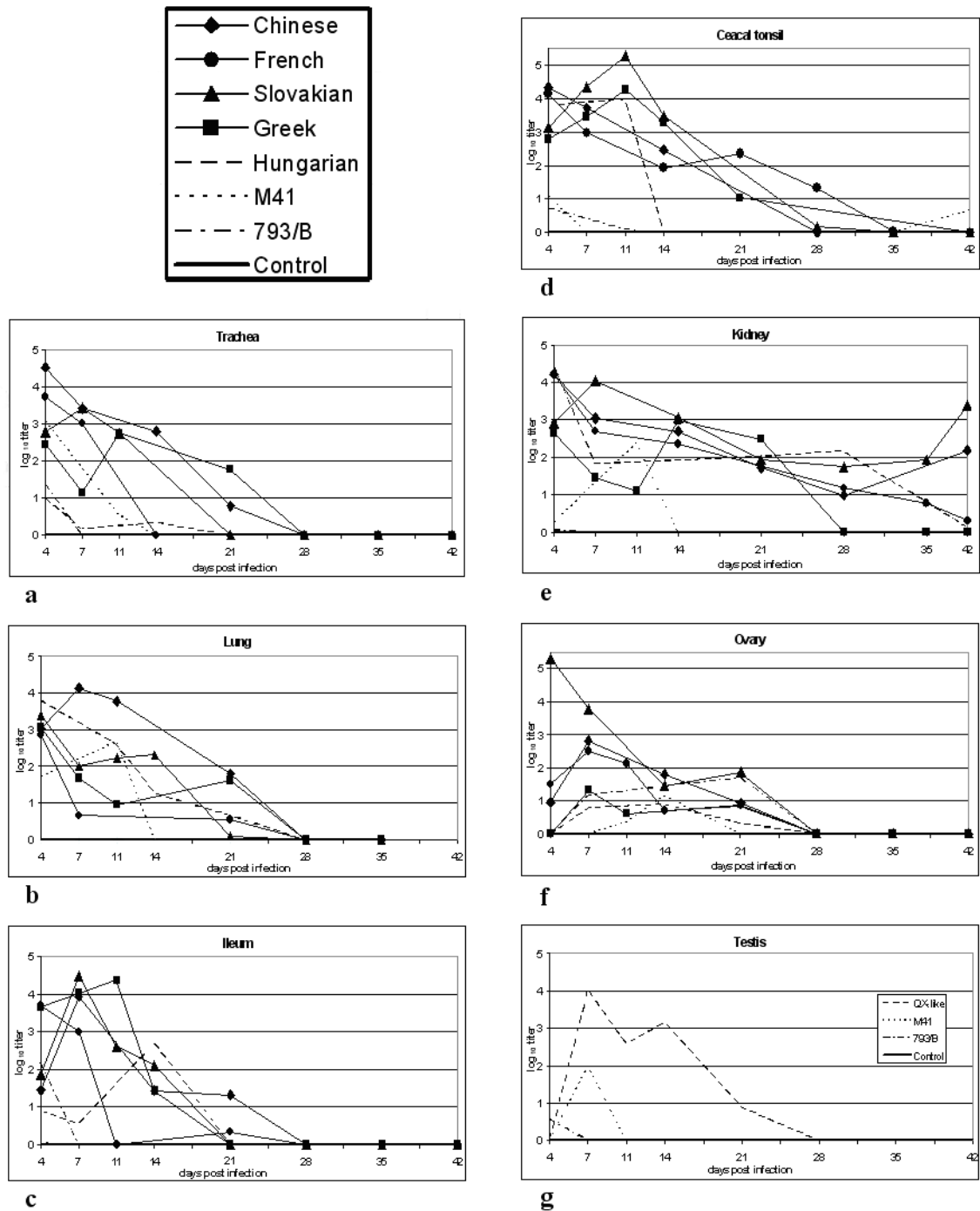


Peer Review Only

**Figure 3.** Antibody response induced by different IBV strains.

\*A serum was considered positive with a titre  $\geq 3 \log_2$ .

**Figure 4.** Detection of viral RNA by real time RT-PCR in the trachea (a), lung (b), ileum (c), caecal tonsil (d), kidney (e), ovary (f) and testis (g).



**Figure 1.:** Characteristic dilatation of the oviduct induced by the Chinese QX-like isolate.

