



**HAL**  
open science

# Pathogenesis of Highly Pathogenic Avian Influenza (HPAI) A/turkey/Turkey/1/2005 H5N1 in Pekin ducks (*Anas platyrhynchos*) infected experimentally

Brandon Z. Löndt, Alejandro Nunez, Jill Banks, Hassan Nili, Linda K  
Johnson, Dennis Alexander

► **To cite this version:**

Brandon Z. Löndt, Alejandro Nunez, Jill Banks, Hassan Nili, Linda K Johnson, et al.. Pathogenesis of Highly Pathogenic Avian Influenza (HPAI) A/turkey/Turkey/1/2005 H5N1 in Pekin ducks (*Anas platyrhynchos*) infected experimentally. *Avian Pathology*, 2008, 37 (06), pp.619-627. 10.1080/03079450802499126 . hal-00540137

**HAL Id: hal-00540137**

**<https://hal.science/hal-00540137>**

Submitted on 26 Nov 2010

**HAL** is a multi-disciplinary open access archive for the deposit and dissemination of scientific research documents, whether they are published or not. The documents may come from teaching and research institutions in France or abroad, or from public or private research centers.

L'archive ouverte pluridisciplinaire **HAL**, est destinée au dépôt et à la diffusion de documents scientifiques de niveau recherche, publiés ou non, émanant des établissements d'enseignement et de recherche français ou étrangers, des laboratoires publics ou privés.



**Pathogenesis of Highly Pathogenic Avian Influenza (HPAI)  
A/turkey/Turkey/1/2005 H5N1 in Pekin ducks (*Anas  
platyrhynchos*) infected experimentally**

Journal:	<i>Avian Pathology</i>
Manuscript ID:	CAVP-2008-0107.R1
Manuscript Type:	Original Research Paper
Date Submitted by the Author:	01-Sep-2008
Complete List of Authors:	Löndt, Brandon; Veterinary Laboratories Agency (VLA), Virology Nunez, Alejandro; Veterinary Laboratories Agency (VLA), Pathology Banks, Jill; Veterinary Laboratories Agency, Virology Nili, hassan; Poultry Research Centre Johnson, Linda; Veterinary Laboratories Agency (VLA), Pathology Alexander, Dennis; VLA Weybridge
Keywords:	HPAI , H5N1 , ducks, pathogenesis

SCHOLARONE™  
Manuscripts

Cavp-2008-107.R1

Pathogenesis of Highly Pathogenic Avian Influenza (HPAI)  
A/turkey/Turkey/1/2005 H5N1 in Pekin ducks (*Anas platyrhynchos*)  
infected experimentally.

**Brandon Z. Löndt<sup>1</sup>, Alejandro Nunez<sup>1</sup>, Jill Banks<sup>1</sup>, Hassan Nili<sup>1,2</sup>, Linda K Johnson<sup>1</sup>, & Dennis J. Alexander<sup>1</sup>**

<sup>1</sup>Veterinary Laboratories Agency, Woodham Lane, Addlestone, Surrey, KT15 3NB, United Kingdom <sup>2</sup>Poultry Research Center, School of Veterinary Medicine, 71345, PO Box 1731, Shiraz University, Shiraz, Iran

Short Title: HAPI H5N1 in Pekin ducks

**FIG 1 TO BE IN COLOUR ON ONE PAGE**

Corresponding author: Brandon Z. Löndt [b.londt@vla.defra.gsi.gov.uk](mailto:b.londt@vla.defra.gsi.gov.uk)

*Received: 3 July 2008*

## Abstract

Asian H5N1 (hereafter referred to as panzootic H5N1) highly pathogenic avian influenza (HPAI) virus has caused large numbers of deaths in both poultry and wild bird populations. Recent isolates of this virus have been reported to cause disease and death in commercial ducks, which has not been seen with other HPAI viruses. However, little is known about either the dissemination of this H5N1 within the organs or the cause of death in infected ducks. Nineteen 4-week-old Pekin ducks were infected with  $10^{6.7}$  median egg infectious doses of HPAI A/turkey/Turkey/1/05 (H5N1, clade 2.2) in 0.1ml via the intranasal and intraocular routes. Cloacal and oropharyngeal swabs were taken daily before three animals were selected randomly and killed humanely for *post-mortem* examination, when samples of tissues were taken for real-time RT-PCR, histopathological examination and immunohistochemistry (IHC). Clinical signs were first observed 4 days post infection (dpi) and included depression, reluctance to feed, in-coordination and torticollis resulting in the death of all the birds remaining on 5dpi. Higher levels of virus shedding were detected from oropharyngeal swabs than from cloacal swabs. Real-time RT-PCR and IHC identified peak levels of virus at 2dpi in several organs. In spleen, lung, kidney, caecal tonsils, breast muscle and thigh muscle the levels were greatly reduced at 3dpi. However, the highest viral loads were detected in the heart and brain from 3dpi and coincided with the appearance of clinical signs and death. Our experimental results demonstrate the systemic spread of this HPAI H5N1 virus in Pekin ducks, and the localisation of virus in brain and heart tissue preceding death.

## Introduction

Avian influenza (AI), is caused by segmented, negative-strand RNA viruses of the *Influenzavirus A* genus of the *Orthomyxoviridae* family. Certain forms of AI, termed highly pathogenic (HPAI), can cause economically devastating disease in poultry. It is thought that, classically wild birds, especially waterfowl, act as reservoirs for AI viruses (Hinshaw *et al.*, 1980b; Kawaoka *et al.*, 1988; Webster *et al.*, 1992), harbouring low pathogenicity AI (LPAI) viruses. LPAI viruses, appear to replicate preferentially in the gastrointestinal tract of wild ducks and other wild birds, resulting in the high-level excretion in faeces and the spread of infection via the faecal-oral route (Webster *et al.*, 1978; Hinshaw *et al.*, 1980a). These viruses may be transmitted to poultry populations where in some cases mutation to highly pathogenic AI (HPAI) viruses occurs (Rohm *et al.*, 1995; Banks *et al.*, 2000). Of the 16 identified haemagglutinin subtypes (H1-H16), HPAI viruses have been confined to subtypes H5 and H7.

The panzootic HPAI H5N1 virus was first detected in geese in Guangdong Province, China in 1996 (Xu *et al.*, 1999) and spread to and evolved in predominantly poultry populations in several South East countries from 1997 (de Jong *et al.*, 1997; Claas *et al.*, 1998; Shortridge *et al.*, 1998; Subbarao *et al.*, 1998; Guan *et al.*, 2002) to 2003/2004 (Stieneke *et al.*, 1992; Imai *et al.*, 2006; Horimoto *et al.*, 2004; Li *et al.*, 2004; Tiensin *et al.*, 2005; Feare & Yasue, 2006). The presence and spread of H5N1 in SE Asia appears to be the result of the virus becoming endemic in domestic ducks (Pekin ducks - *Anas platyrhynchos*), with their rearing in open-range paddy fields as a possible contributing factor (Hulse-Post *et al.*, 2005; Sims *et al.*, 2005; Sturm-Ramirez *et al.*, 2005).

Until recently the only documented infection of significant numbers of wild birds with HPAI virus occurred in common terns in South Africa in 1961, with virus A/tern/South Africa/1961 (H5N3) (Becker, 1966). However, the panzootic HPAI H5N1 virus was reported in wild birds on several occasions and most particularly a variant virus showing lethality for

wild birds was detected in populations of bar headed geese on Lake Qinghai, China in 2005 (Chen *et al.*, 2005; Liu *et al.*, 2005; Zhou *et al.*, 2006). This virus has also been reported to cause severe disease in commercial ducks (Sturm-Ramirez *et al.*, 2005), which is unusual for HPAI viruses (Alexander *et al.*, 1978; 1986). This later virus has also been responsible for deaths in wild geese, ducks and swans (Ellis *et al.*, 2004; Bui *et al.*, 2007; Lee *et al.*, 2005; Mase *et al.*, 2005; Isoda *et al.*, 2006; Nguyen *et al.*, 2005; Zhou *et al.*, 2006). After its emergence this HPAI H5N1 variant (currently termed clade 2.2) spread rapidly through Asia and into Europe and Africa.

Pekin ducks are an important meat source in South-East Asia and as a result are reared extensively in most countries in the area. The panzootic HPAI H5N1 virus is a significant threat to the commercial duck industry and because of their close genetic relationship with mallard ducks (*Anas platyrhynchos*), Pekin ducks may serve as a valuable model for AI infection and spread in wild ducks. Knowledge of the dissemination of these H5N1 viruses within this host, may provide some insight into the mechanism that resulted in increased virulence for ducks and wild birds. This information could also be vital for the efficient screening of wild-bird as well as domestic and commercial poultry populations and is thus important for disease control and future pandemic prevention.

## Material and Methods

**Infection of Pekin ducks with A/turkey/Turkey/1/05.** Commercial high-health status Pekin ducks were acquired from Cherry Valley Farms Ltd, UK. Before experimental infections were performed, oropharyngeal and cloacal swabs and blood samples were taken to test for current infection with AI virus and previous exposure to H5 by matrix gene real-time RT-PCR (see below) and haemagglutination inhibition (HI) tests, respectively, using standard methods (CEC 2006; Alexander, 2005). All duck experiments were performed in Biosafety Level 3+ (BSL-3+) facilities at the Veterinary Laboratories Agency, Weybridge. The H5N1

isolate A/turkey/Turkey/1/05 (clade 2.2) was selected, due to its status as the first of the current panzootic H5N1 viruses to be isolated in Europe, and grown in 9-day-old embryonated specific pathogen free hen's eggs. A standard intravenous pathogenicity index test (Alexander, 2005) on this virus gave the maximum value, 3.0.

Seventeen 4-week-old Pekin ducks were each infected with a total volume of 0.1ml infective allantoic fluid containing  $10^{6.7}$  median egg infectious doses (EID<sub>50</sub>) /0.1ml A/turkey/Turkey/1/05, divided equally between the intranasal and intraocular routes. Clinical signs were recorded twice daily. Where individual ducks were deemed moribund, such that they were unable to eat or drink, they were killed humanely and recorded as mortality for that day. Each day, for a period of five days, cloacal and oropharyngeal swabs were taken, before 3 animals were selected randomly and killed humanely for *post-mortem* examination. Samples of tissues (brain, heart, spleen, lung, liver, kidney, intestine, caecal tonsil, trachea, breast muscle, thigh muscle and feathers) were collected for real-time RT-PCR, histopathology and immunohistochemistry (IHC) examination. Tissues for real-time RT-PCR were collected in 15% w/v Brain-Heart-Infusion (BHI) media with antibiotics (penicillin G 10000U/ml; amphotericin B 20µl/ml; gentamycin 1000µg/ml). Tissue samples for histology were fixed in 10% v/v buffered formalin for a minimum period of 48h. All tissue samples for real-time RT-PCR and histopathology examination were collected within 1h of the death of the animal.

**Viral RNA isolation.** A 10% w/v suspension was made from each tissue in 1ml BHI media with antibiotics. Tissue was homogenised using the QIAGEN Tissuelyser using 3mm Tungsten-Carbide beads (QIAGEN, UK). To improve the viscosity for RNA isolation, the tissue homogenate was centrifuged at 16,110 g for 3min, the supernatant added to QIA Shredders (QIAGEN, UK) and centrifuged at 16,110 g for 1min to remove any additional cellular debris. Viral RNA was isolated from 140µl using the QIAquick RNA extraction kit (QIAGEN, UK).

The oropharyngeal and cloacal swabs were transferred into 1ml of BHI with antibiotics and briefly vortexed before 140µl was loaded into 420µl of AVL Buffer (QIAGEN, UK) in a QIAGEN S-block for automated viral RNA extraction by the Universal Biorobot system (QIAGEN, UK).

**Real-time reverse transcriptase polymerase chain reaction (RRT-PCR).** The Matrix gene RRT-PCR (Spackman *et al.*, 2002) was performed using one-step RT-PCR kits (QIAGEN, UK) with 0.4µM PCR primers Sep1 (5'-AGATGAGTCTTCTAACCGAGGTCG-3') and Sep2 (5'-TGCAAAAACATCTTCAAGTCTCTG-3') with 0.3µM of hydrolysis probe SePRO: ([FAM]-TCAGGCCCCCTCAAAGCCGA-[TAMRA]) (Sigma, UK); 3.1mM MgCl<sub>2</sub> (Promega, UK); 0.75µM passive reference dye ROX (Stratagene, UK) and 0.4U/µl RNase inhibitor, RNasin (Promega, UK). One-step RRT-PCR was performed using Stratagene MX3000 thermocyclers with the RT step cycler conditions as 50°C for 30 min and 95°C for 15 min, and the PCR step (40 cycles) as 95°C for 10s, 60°C for 20s. The fluorescence data was collected during the 60°C annealing step using the ROX and FAM filters.

For the H5 gene RRT-PCR, a modified protocol of Spackman *et al.* (2002) was used, where PCR primers and hydrolysis probes were altered for the detection of H5 isolates of the Eurasian lineage (Slomka *et al.*, 2007). This involved using one-step RT-PCR kits (QIAGEN, UK) with 0.4µM PCR primers H5LH1 (5'-ACA TAT GAC TAC CCA CAR TAT TCAG-3') and H5RH1 (5'-AGA CCA GCT AYC ATG ATT GC -3') with 0.3µM of hydrolysis probe H5PRO ([FAM]-TCW ACA GTG GCG AGT TCC CTA GCA-[TAMRA]) (Sigma, UK). One-step RRT-PCR was performed using Stratagene MX3000 thermocyclers with the RT step cycler conditions as 50°C for 30 min and 95°C for 15 min; and the PCR step conditions (x40 cycles): 95°C for 10s; 54°C for 30s; 72°C for 10s. The fluorescence data was collected during the 54°C annealing step using the ROX and FAM filters.

For both M gene and H5 RRT-PCR, a positive extraction control of A/chicken/Scotland/59 (H5N1) RNA of known copy number from inactivated freeze-dried



egg-grown material was included. Quantitative standards of five 10-fold dilutions of extracted RNA from  $10^6$  EID<sub>50</sub> of A/turkey/Turkey/1/05 were also included.

**Histopathology and Immunohistochemistry.** Samples for histology were routinely processed through graded alcohols and chloroform and embedded in paraffin wax (routine standard process). Sections 4  $\mu$ m thick, cut on a rotary microtome, were stained with haematoxylin and eosin or used for immunohistochemical detection of Influenza A nucleoprotein. Briefly, sections for immunohistochemistry were dewaxed in xylene, and passed through graded alcohols to Tris Buffered Saline solution (TBS) (0.005M Tris, pH7.6, 0.85% w/v NaCl). Endogenous peroxidase activity was quenched with a methanol/hydrogen peroxide block (BDH) for 15 min and treated with Protease XXIV for 10 min at room temperature. Slides were assembled into Shandon coverplates to facilitate IHC using the Shandon Sequenza system (Shandon, USA). Primary antibody cross-reactivity with tissue constituents was prevented using a normal immune serum block. Samples were subsequently incubated with an anti-Influenza A nucleoprotein primary antibody (Statens Serum Institute, Denmark) for 1h and Dako ENVISION™ polymer for 30 min at room temperature. Sections were washed three times with TBS between incubations. The immunohistochemical signal was visualised using 3,3 diaminobenzidine (Sigma-Aldrich). Sections were counterstained in Mayer's haematoxylin (Surgipath, UK), dehydrated in absolute alcohol, cleared in xylene and mounted using DPX and glass coverslips. Specificity of the immunolabelling was evaluated in both negative and positive control animals and test sections by replacing the primary antibody with isotype matching IgG or TBSt (TBS with tween). Unspecific cross-linking was not observed in any of the negative control animals or in positive and infected animals in the IgG and "omit" controls.

The number of immunolabelled cells was assessed semiquantitatively in each individual organ and scored on a scale ranging from 0 to 5 (0: negative; 1: occasional presence of immunolabelled cells; 2: small number of cells; 3: moderate; 4: numerous; 5: widespread

immunolabelling). The average score and standard error for the three animals of each time point were calculated for each individual tissue.

## Results

**Clinical Observations and Gross Pathology.** Although three of the H5N1-infected Pekin ducks were killed humanely and sampled daily, none showed clinical signs until 4dpi, when one of the remaining five ducks displayed depression, reluctance to feed, in-coordination and torticollis. However, at 5dpi the condition of the remaining five ducks deteriorated rapidly, they appeared severely sick and were thought unlikely to survive the infection. All five remaining ducks were therefore killed humanely, with three selected randomly for *post-mortem* examination and tissue collection.

No significant gross pathological changes were observed in the animals killed at 1 and 2 dpi. Airsacculitis was observed in sampled birds from day 3 onwards and lesions in the heart, in the form of multifocal linear pale discoloration of the myocardium, were observed at days 4 and 5dpi.

**Histopathology.** The most significant lesions were observed in the brain, heart and skeletal muscles. In the brain, non-suppurative encephalitis with neuronal degeneration and necrosis and lymphoplasmacytic perivascular cuffs was observed focally in one animal at 2dpi, and multifocally to focally extensive in all animals from 3dpi, with the most severe observed on the later days of the study. In the heart, mild multifocal hyalinization and necrosis of cardiomyocytes was observed in one animal at 3dpi, with more extended and severe lesions observed in all ducks killed thereafter, usually accompanied by a moderate heterophilic and mononuclear inflammatory infiltrate. Skeletal muscle from breast and thigh presented multifocal degeneration and necrosis of individual myofibers or small bundles in one animal

at 2 and 3dpi, and all of the remaining animals at 4 and 5dpi. Mucocellular exudate, mild degenerative changes and detachment of the tracheal epithelial cells were observed at 3 and 4dpi. A mild to moderate lymphoid depletion was observed in the spleen from 3 dpi. No significant lesions were observed in the remaining tissues collected.

**Immunohistochemistry (IHC).** Immunohistochemical results for the detection of AI nucleoprotein showed a good correlation between demonstration of viral antigen and presence of histological lesions, although the viral antigen was detected earlier than the appearance of histological lesions and was more widely distributed throughout tissues. Immunolabelling was usually both intracytoplasmic and intranuclear, and occasionally intranuclear only. All animals inoculated showed immunolabelling from 1 dpi. The only organ that showed immunolabelling in all cases was the lung, with individual variation throughout the experiment. In the later stages of the infection the tissues with the highest number of immunolabelled cells were the heart and brain (Figure 1), followed by skeletal muscle. Individual tissue analysis (Figure 2) showed detection of virus in the brain in 2 out of 3 animals at 2 and 3dpi and all animals at 4 and 5dpi, which was localised in neurons and glial cells. Brain tissue examined included areas of the brain cortex, midbrain, cerebellum and medulla. There did not seem to be a predilection for the location of the immunolabelling against the virus and positive neuron/glial cells were found in all regions examined.

Virus was first detected at 1dpi, and in scattered cells of the lung, in all animals. Breast muscle and thigh muscle showed similar infection patterns in which infection was first detected by IHC at 2dpi in 2 out of 3 ducks, with detection observed in all animals by 4-5dpi in myocytes. Virus was detected in heart cardiomyocytes in 2 of 3 birds at 2dpi and in all animals from 3dpi onwards. No detection was observed in kidney parenchymal cells. Liver Kupffer cells displayed limited detection at 2dpi, but this became numerous for 1 of 3 birds at 3dpi. Caecal tonsil infection was only detected at 1dpi in a macrophage and in only one animal. No immunolabelling of enterocytes was observed in the samples collected, but immunolabelling of neurons in the myenteric plexus was observed in some animal at day 3

(1/3) and 5 (2/3). A very limited amount of immunolabelling was observed in tracheal cells and only in epithelial cells in one animal at 3 dpi and in 2 animals at 4dpi. However, smooth muscle cells associated with the trachea and airsacs showed immunolabelling. Mild lymphoid depletion from 3 dpi was observed in the spleen. No immunolabelling of endothelial cells was detected. Detection of AI nucleoprotein in feathers (pulp/epithelium) was observed in main flight feathers and also in filoplumes from 2dpi onwards.

**Real-time RT- PCR of viral RNA extracted from swabs and tissues.** Viral RNA presence in tissues was detected by RRT-PCR and measured as relative equivalent units (REU) of RNA against a 10-fold dilution series of RNA purified from infective allantoic fluid containing  $10^6$  EID<sub>50</sub>/0.1ml A/turkey/Turkey/1/2005 (H5N1). Although these units measured the amount of viral RNA present and not infectivity, it may be inferred from the linear relationship with the dilution series that they are proportionate to the amount of infectious virus present. Matrix gene RRT-PCRs showed a good correlation with the results obtained from IHC. On the whole, oropharyngeal and cloacal shedding of virus peaked at 4dpi with significantly higher levels observed from oropharyngeal specimens (equivalent to approximately  $10^2$  REU) (Figure 3). A lower prevalence of cloacal shedding was observed, with virus positive cloacal swabs detected in only eight ducks and at very low levels until 4 or 5 dpi. The limited amount of shedding observed at this location confirmed the results seen for IHC where virus replication was not detected in intestinal epithelial cells. Virus shedding via the buccal route was detected on all 5 days. However, virus was not detected by this route on every day post infection for every duck.

Although a good correlation was obtained between real-time RT-PCR and immunohistochemistry, detection of virus by real-time RT-PCR was generally more sensitive. Infection was detected earliest (1dpi) from lung tissue and gave the most consistent detection of infection with all animals testing positive (Figure 4) confirming the results seen for IHC. However, viral load peaked at 2 dpi and only low levels of virus were detected by 5dpi. In contrast, high viral loads were observed in the heart and brain of animals from 2dpi ( $\sim 10^3$

REU RNA) and continued to increase over the course of infection ( $\sim 10^4$  REU RNA).

Interestingly, in some cases virus was detected in muscle tissue as early as 1 dpi.

Some variation, as much as  $10^2$  REU of viral RNA in some instances, was also seen between viral loads in certain organs between different ducks examined on the same day. This observation was particularly significant in the first 2 to 3 dpi and may be an indicator of differences in host-virus interactions leading to later dissemination of virus and onset of disease in certain individuals. Interestingly, a decrease in viral load occurred in several organs (spleen, lung, kidney, caecal tonsil, breast muscle and thigh muscle) at 3dpi, possibly indicating the action of the host immune response (Figure 4). However, viral loads began to increase at 4 and 5dpi in other organs, with a marked increase observed in the brain and heart, coinciding with the appearance of clinical signs in the remaining ducks (Figure 5).

## Discussion

Historically, ducks have been considered to be clinically resistant to HPAI viruses and in experiments such viruses have not caused clinical disease or mortality (Alexander *et al.*, 1978; 1986), even though virus has been shown to spread systemically in experimentally infected ducks (Wood *et al.*, 1995). However, several recent experimental studies and environmental observations have reported the increased pathogenesis and mortality of the currently circulating Asian-like H5N1 HPAI virus in both domestic ducks and wild birds (Perkins & Swayne, 2003; Brown *et al.*, 2006b; Hulse-Post *et al.*, 2007; Swayne, 2007; Pantin-Jackwood & Swayne, 2007; Vascellari *et al.*, 2007; Yamamoto *et al.*, 2007). In the present study, massive systemic spread of A/turkey/Turkey/1/05 (H5N1) was observed in experimentally infected 4-week-old Pekin ducks, resulting in 100% mortality. This is in contrast to previous experiments with viruses from South East Asia, isolated at an earlier stage in the H5N1 outbreak (between approximately 1997 and 2001) where viruses were only

isolated in certain organs and no morbidity, mortality or gross lesions were observed (Perkins & Swayne, 2002; 2003; Tumpey *et al.*, 2002;). This suggests that some mutation to virulence for ducks occurred prior to, or at the time of, the emergence of the Lake Qinghai (clade 2.2) isolates in 2005.

Recently Keawcharoen *et al.* (2008) reported results of experimental infection of six species of wild duck, including mallards, with A/turkey/Turkey/1/2005 (H5N1), their results were somewhat different to those obtained in the present study. In particular the mallards, which would be expected to behave similarly to Pekin ducks, as they are the same species, showed “abundant virus excretion without clinical or pathologic evidence of debilitating disease”. There were several differences in these experiments that may account for this discrepancy. Although belonging to the same species, commercial Pekin ducks have phenotypic and genetic differences from wild mallards. The dose and routes of inoculation used in the present study,  $10^{6.7}$  EID<sub>50</sub>/0.1ml A/turkey/Turkey/1/05 divided equally between the intranasal and intraocular routes, compared to  $1 \times 10^4$ TCID<sub>50</sub> divided equally between the tracheal and oesophageal routes in the Keawcharoen *et al.* (2008) study. But possibly the most significant difference was age, 4-week-old Pekin ducks compared to 8- to 11-month-old mallards.

Infection of 4-week-old Pekin ducks with A/turkey/Turkey/1/05 (H5N1) resulted in the observation of temporal dissemination in certain organs resulting in clinical disease and death. Although peaks in the presence of virus were detected during early infection in several organs including the spleen, lung, kidney, caecal tonsil, breast muscle and thigh muscle, the rapid decrease in viral load suggests an immune control of viral replication in these organs. However, high viral loads detected in the heart and brain from 3dpi, which coincided with the appearance of clinical signs and death at 5dpi, does implicate the failure of proper functioning of these two organs as the primary cause of death. The detection of virus within muscle tissue, as early as 1dpi in some cases, confirms the finding of high levels of virus in muscle tissue, especially breast muscle, in previous studies (Tumpey *et al.*, 2002; Mase *et al.*, 2005; Swayne

& Beck, 2005). The levels of variation seen at several time points within each organ indicates the possibility of individual variation in virus dissemination and disease progression.

Viral load levels were very low in cloacal swabs and intestinal tissue. Significantly higher levels of viral shedding were detected in oropharyngeal swabs than in cloacal swabs, an observation reported previously for the current H5N1 HPAI virus in several species of wild bird (Hulse-Post *et al.*, 2005; Sturm-Ramirez *et al.*, 2005; Brown *et al.*, 2006a), which further confirms a possible shift from the conventional faecal-oral mechanism of AI transmission to an, at present, unknown route. However, this information has implications for the control of AI. The selection of tissue type during an AI screening program may depend on the sampling stage in the time course of disease within an infected flock. The significantly lower levels of virus detected by swabbing also indicates that the use of swabs as a lone sampling method may not be prudent; a “belt and braces” approach of pooling selected organs may be required.

### **Acknowledgements**

The authors thank Christine Russell, Julie Gough and Philip Heath for their technical assistance. This work was funded by the United Kingdom Department for Environment, Food and Rural Affairs (DEFRA). This work was performed in part for submission towards a higher degree at the University of Reading, United Kingdom.

## References

- Alexander, D.J., Allan, W.H., Parsons, D.G. & Parsons, G. (1978). The pathogenicity of four avian influenza viruses for fowls, turkeys and ducks. *Research in Veterinary Science*, 24, 242-247.
- Alexander, D. J., Parsons, G. & Manvell, R. J. (1986). Experimental assessment of the pathogenicity of eight avian influenza A viruses of H5 subtype for chickens, turkeys, ducks and quail. *Avian Pathology*, 15, 647-662.
- Alexander, D.J. (2005). Avian influenza. Chapter 2.07.12. Manual for Diagnostic Tests and Vaccines for Terrestrial Animals. 5<sup>th</sup> Edition OIE : Paris.
- [http://mc.manuscriptcentral.com/LongRequest/cavp?TAG\\_ACTION=DOWNLOAD\\_FILE\\_BY\\_NAME&DOCUMENT\\_ID=4591729&FILE\\_TO\\_DOWNLOAD=http://www.oie.int/eng/normes/MANUAL/A\\_00037.htm-withlinks.htm&FILE\\_KEY=-44353588&FILE\\_NAME\\_KEY=-2068713916&DOWNLOAD=TRUE%20](http://mc.manuscriptcentral.com/LongRequest/cavp?TAG_ACTION=DOWNLOAD_FILE_BY_NAME&DOCUMENT_ID=4591729&FILE_TO_DOWNLOAD=http://www.oie.int/eng/normes/MANUAL/A_00037.htm-withlinks.htm&FILE_KEY=-44353588&FILE_NAME_KEY=-2068713916&DOWNLOAD=TRUE%20)
- Banks, J., Speidel, E. C., McCauley, J. W. & Alexander, D. J. (2000). Phylogenetic analysis of H7 haemagglutinin subtype influenza A viruses. *Archives of Virology*, 145, 1047-1058.
- Becker, W.B. (1966). The isolation and classification of tern virus: Influenza virus A/tern/South Africa/1961. *Journal of Hygiene*, 64, 309-320.
- Brown, J.D., Stallknecht, D.E., Beck, J.R., Suarez, D.L. & Swayne, D.E. (2006). Susceptibility of North American Ducks and Gulls to H5N1 Highly Pathogenic Avian Influenza Viruses. *Emerging Infectious Diseases*, 12, 1663-1670.
- Brown, J.D., Stallknecht, D.E. & Swayne, D.E. (2008). Experimental infection of swans and geese with highly pathogenic avian influenza virus (H5N1) of Asian lineage. *Emerging Infectious Diseases*, 14, January 2008.
- [http://mc.manuscriptcentral.com/LongRequest/cavp?TAG\\_ACTION=DOWNLOAD\\_FILE\\_BY\\_NAME&DOCUMENT\\_ID=4591729&FILE\\_TO\\_DOWNLOAD=http://www.cdc.gov/EID/content/14/1/136.htm-withlinks.htm&FILE\\_KEY=-44353588&FILE\\_NAME\\_KEY=934524087&DOWNLOAD=TRUE&FILE\\_TY%20](http://mc.manuscriptcentral.com/LongRequest/cavp?TAG_ACTION=DOWNLOAD_FILE_BY_NAME&DOCUMENT_ID=4591729&FILE_TO_DOWNLOAD=http://www.cdc.gov/EID/content/14/1/136.htm-withlinks.htm&FILE_KEY=-44353588&FILE_NAME_KEY=934524087&DOWNLOAD=TRUE&FILE_TY%20)
- Bui, H.H., Peters, B., Assarsson, E., Mbawuike, I. & Sette, A. (2007). Ab and T cell epitopes of



- influenza A virus, knowledge and opportunities. *Proceedings of the National Academy of Science USA*, 104, 246-51.
- CEC. (2006). Commission Decision 2006/437/EC approving a diagnostic manual for avian influenza as provided for in Council Directive 2005/94/EC. *Official Journal of European Commission*, L237, 1-27. <http://eur-lex.europa.eu/LexUriServ/LexUriServ.do?uri=CELEX:32006D0437:EN:NOT>
- Chen, H., Smith, G.J.D., Zhang, S.Y., Qin, K., Wang, J., Li, K.S., Webster, R.G., Peiris, J.S.M. & Guan, Y. (2005). H5N1 virus outbreak in migratory waterfowl. *Nature*, 436, 191-192.
- Claas, E.C.J., Osterhaus, A.D.M.E., vanBeek, R., de Jong, J.C., Rimmelzwaan, G.F., Senne, D.A., Krauss, S., Shortridge, K.F. & Webster, R.G. (1998). Human influenza A H5N1 virus related to a highly pathogenic avian influenza virus. *Lancet*, 351, 472-477.
- de Jong, J.C., Claas, E.C.J., Osterhaus, A.D.M.E., Webster, R.G. & Lim, W.L. (1997). A pandemic warning? *Nature*, 389, 554.
- Ellis, T.M., Bousfield, R.B., Bissett, L.A., Dyrting, K.C., Luk, G.S.M., Tsim, S.T., Sturm-Ramirez, K., Webster, R.G., Guan, Y. & Peiris, J.S.M. (2004). Investigation of Outbreaks of Highly Pathogenic H5N1 Avian Influenza in Waterfowl and Wild Birds in Hong Kong in Late 2002. *Avian Pathology*, 33, 492-505.
- Feare, C. J. & Yasue, M.A.I. (2006). Asymptomatic infection with highly pathogenic avian influenza H5N1 in wild birds: How sound is the evidence? *Journal of Virology*, 3, 96.
- Guan, Y., Peiris, J. S. M., Lipatov, A. S., Ellis, T. M., Dyrting, K. C., Krauss, S., Zhang, L. J., Webster, R. G. & Shortridge, K. F. (2002). Emergence of multiple genotypes of H5N1 avian influenza viruses in Hong Kong SAR. *Proceedings of the National Academy of Science USA*, 99, 8950-8955.
- Hinshaw, V. S., Bean, W. J., Webster, R. G. & Sriram, G. (1980a). Genetic reassortment of influenza A viruses in the intestinal tract of ducks. *Virology*, 102, 412-419.
- Hinshaw, V. S., Webster, R. G. & Turner, B. (1980b). The perpetuation of orthomyxoviruses and paramyxoviruses in Canadian waterfowl. *Canadian Journal of Microbiology*, 26, 622-629.
- Horimoto, T., Fukuda, N., Iwatsuki-Horimoto, K., Guan, Y., Lim, W., Peiris, M., Sugii, S., Odagiri,

- T., Tashiro, M. & Kawaoka, Y. (2004). Antigenic differences between H5N1 human influenza viruses isolated in 1997 and 2003. *Journal of Veterinary Medical Science*, *66*, 303-305.
- Hulse-Post, D. J., Sturm-Ramirez, K. M., Humberd, J., Seiler, P., Govorkova, E. A., Krauss, S., Scholtissek, C., Puthavathana, P., Buranathai, C., Nguyen, T. D., Long, H. T., Naipospos, T. S. P., Chen, H., Ellis, T. M., Guan, Y., Peiris, J. S. M. & Webster, R. G. (2005). Role of Domestic Ducks in the Propagation and Biological Evolution of Highly Pathogenic H5N1 Influenza Viruses in Asia. *Proceedings of the National Academy of Science USA*, *102*, 10682-10687.
- Hulse-Post, D. J., Franks, J., Boyd, K., Salomon, R., Hoffmann, E., Yen, H. L., Webby, R. J., Walker, D., Nguyen, T. D. & Webster, R. G. (2007). Molecular changes in the polymerase genes (Pa and Pb1) associated with high pathogenicity of H5N1 influenza virus in mallard ducks. *Journal of Virology*, *81*, 8515-8524.
- Imai, M., Ninomiya, A., Minekawa, H., Notomi, T., Ishizaki, T., Tashiro, M. & Odagiri, T. (2006). Development of H5-Rt-Lamp (loop-mediated isothermal amplification) system for rapid diagnosis of H5 avian influenza virus infection. *Vaccine*, *24*, 44-46.
- Isoda, N., Sakoda, Y., Kishida, N., Bai, G. R., Matsuda, K., Umemura, T. & Kida, H. (2006). Pathogenicity of a highly pathogenic avian influenza virus, A/chicken/Yamaguchi/7/04 (H5N1) in different species of birds and mammals. *Archives of Virology*, *151*, 1267-1279.
- Kawaoka, Y., Chambers, T. M., Sladen, W. L. & Webster, R. G. (1988). Is the gene pool of influenza viruses in shorebirds and gulls different from that in wild ducks? *Virology*, *163*, 247-250.
- Keawcharoen, J., van Riel, D., van Amerongen, G., Bestebroer, T., Beyer, W. E., van Lavieren, R., Osterhaus, A. D., Fouchier, R. A. and Kuiken, T. (2008). Wild ducks as long-distance vectors of highly pathogenic avian influenza virus (H5N1). *Emerging Infectious Diseases*, *14*, 600-607.
- Lee, C. W., Suarez, D. L., Tumpey, T. M., Sung, H. W., Kwon, Y. K., Lee, Y. J., Choi, J. G., Joh, S. J., Kim, M. C., Lee, E. K., Park, J. M., Lu, X. H., Katz, J. M., Spackman, E., Swayne, D. E. &

- Kim, J. H. (2005). Characterization of highly pathogenic H5N1 avian influenza A viruses isolated from South Korea. *Journal of Virology*, 79, 3692-3702.
- Li, K. S., Guan, Y., Wang, J., Smith, G. J., Xu, K. M., Duan, L., Rahardjo, A. P., Puthavathana, P., Buranathai, C., Nguyen, T. D., Estoepangestie, A. T., Chaisingh, A., Auewarakul, P., Long, H. T., Hanh, N. T., Webby, R. J., Poon, L. L., Chen, H., Shortridge, K. F., Yuen, K. Y., Webster, R. G. & Peiris, J. S. (2004). Genesis of a highly pathogenic and potentially pandemic H5N1 influenza virus in eastern Asia. *Nature*, 430, 209-213.
- Li, Z.J., Chen, H.L., Jiao, P.R., Deng, G.H., Tian, G.B., Li, Y.B., Hoffmann, E., Webster, R.G., Matsuoka, Y. & Yu, K.Z. (2005). Molecular basis of replication of duck H5N1 influenza viruses in a mammalian mouse model. *Journal of Virology*, 79, 12058-12064.
- Liu, J., Xiao, H., Lei, F., Zhu, Q., Qin, K., Zhang, X. W., Zhang, X. L., Zhao, D., Wang, G., Feng, Y., Ma, J., Liu, W., Wang, J. & Gao, G. F. (2005). Highly Pathogenic H5N1 influenza virus infection in migratory birds. *Science*, 309, 1206.
- Mase, M., Eto, M., Tanimura, N., Imai, K., Tsukamoto, K., Horimoto, T., Kawaoka, Y. & Yamaguchi, S. (2005). Isolation of a genotypically unique H5N1 influenza virus from duck meat imported into Japan from China. *Virology*, 339, 101-109.
- Nguyen, D. C., Uyeki, T. M., Jadhao, S., Maines, T., Shaw, M., Matsuoka, Y., Smith, C., Rowe, T., Lu, X. H., Hall, H., Xu, X. Y., Balish, A., Klimov, A., Tumpey, T. M., Swayne, D. E., Huynh, L. P. T., Nghiem, H. K., Nguyen, H. H. T., Hoang, L. T., Cox, N. J. & Katz, J. M. (2005). Isolation and characterization of avian influenza viruses, including highly pathogenic H5N1, from poultry in live bird markets in Hanoi, Vietnam, in 2001. *Journal of Virology*, 79, 4201-4212.
- Pantin-Jackwood, M. J. & Swayne, D. E. (2007). Pathobiology of Asian Highly Pathogenic Avian Influenza H5N1 Virus Infections in Ducks. *Avian Diseases*, 51, 250-259.
- Perkins, L. E. L. & Swayne, D. E. (2002). Pathogenicity of a Hong Kong-Origin H5N1 Highly Pathogenic Avian Influenza Virus for Emus, Geese, Ducks, and Pigeons. *Avian Diseases*, 46, 53-63.
- Perkins, L. E. L. & Swayne, D. E. (2003). Comparative Susceptibility of Selected Avian and

Mammalian Species to a Hong Kong-Origin H5N1 High-Pathogenicity Avian Influenza Virus. *Avian Diseases*, 47, 956-967.

Rohm, C., Horimoto, T., Kawaoka, Y., Suss, J. & Webster, R. G. (1995). Do hemagglutinin genes of highly pathogenic avian influenza viruses constitute unique phylogenetic lineages? *Virology*, 209, 664-670.

Sims, L. D., Domenich, J., Benigno, C. Kahn, S. Kamaya, A. Lubroth, J. Martin V. & Roeder, P. (2005). Origin and evolution of highly pathogenic H5N1 avian influenza in Asia. *Veterinary Record*, 157, 159-164.

Shortridge, K. F., Zhou, N. N., Guan, Y., Gao, P., Ito, T., Kawaoka, Y., Kodihalli, S., Krauss, S., Markwell, D., Murti, K. G., Norwood, M., Senne, D., Sims, L., Takada, A. & Webster, R. G. (1998). Characterization of avian H5N1 influenza viruses from poultry in Hong Kong. *Virology*, 252, 331-342.

Slomka, M. J., Pavlidis, T., Banks, J., Shell, W., McNally, A., Essen, S. & Brown, I. H. (2007). Validated H5 Eurasian real-time reverse transcriptase-polymerase chain reaction and its APPLICATION in H5N1 outbreaks in 2005-2006. *Avian Diseases*, 51, 373-377.

Stieneke-Grober A., Vey, M., Angliker, H., Shaw, E., Thomas, G., Roberts, C., Klenk, H. D. & Garten, W. (1992). Influenza virus hemagglutinin with multibasic cleavage site is activated by furin, a subtilisin like endoprotease. *EMBO Journal*, 11, 2407-2414.

Sturm-Ramirez, K. M., Hulse-Post, D. J., Govorkova, E. A., Humberd, J., Seiler, P., Puthavathana, P., Buranathai, C., Nguyen, T. D., Chaisingh, A., Long, H. T., Naipospos, T. S. P., Chen, H., Ellis, T. M., Guan, Y., Peiris, J. S. M. & Webster, R. G. (2005). Are ducks contributing to the endemicity of highly pathogenic H5N1 influenza virus in Asia? *Journal of Virology*, 79, 11269-11279.

Subbarao, K., Klimov, A., Katz, J., Regnery, H., Lim, W., Hall, H., Perdue, M., Swayne, D., Bender, C., Huang, J., Hemphill, M., Rowe, T., Shaw, M., Xu, X. Y., Fukuda, K. & Cox, N. (1998). Characterization of an avian influenza-A (H5N1) virus isolated from a child with a fatal respiratory illness. *Science*, 279, 393-396.

Swayne, D. E. & Beck, J. R. (2005). Experimental study to determine if low-pathogenicity and high-

- pathogenicity avian influenza viruses can be present in chicken breast and thigh meat following intranasal virus inoculation. *Avian Diseases*, 49, 81-85.
- Swayne, D. E. (2007). Understanding the Complex Pathobiology of High Pathogenicity Avian Influenza Viruses in Birds. *Avian Diseases*, 51, 242-249.
- Tiensin, T., Chaitaweesub, P., Songserm, T., Chaisingh, A., Hoonsuwan, W., Buranathai, C., Parakamawongsa, T., Premashtira, S., Amonsin, A., Gilbert, M., Nielen, M. & Stegeman, A. (2005). Highly pathogenic avian influenza H5N1, Thailand, 2004. *Emerging Infectious Diseases*, 11, 1664-1672.
- Tumpey, T. M., Suarez, D. L., Perkins, L. E. L., Senne, D. A., Lee, J. G., Lee, Y. J., Mo, I. P., Sung, H. W. & Swayne, D. E. (2002). Characterization of a highly pathogenic H5N1 avian influenza A virus isolated from duck meat. *Journal of Virology*, 76, 6344-6355.
- Vascellari, M., Granato, A., Trevisan, L., Basilicata, L., Toffan, A., Milani, A. & Mutinelli, F. (2007). Pathologic findings of highly pathogenic avian influenza virus A/duck/Vietnam/12/05 (H5N1) in experimentally infected Pekin ducks, based on immunohistochemistry and in situ hybridization. *Veterinary Pathology*, 44, 635-642.
- Webster, R. G., Bean, W. J., Gorman, O. T., Chambers, T. M. & Kawaoka, Y. (1992). Evolution and ecology of influenza A viruses. *Microbiological Reviews*, 56, 152-179.
- Webster, R. G., Yakhno, M., Hinshaw, V. S., Bean, W. J. & Murti, K. G. (1978). Intestinal influenza: replication and characterization of influenza viruses in ducks. *Virology*, 84, 268-278.
- Wood, G. W., Parsons, G. & Alexander, D. J. (1995). Replication of influenza A viruses of high and low pathogenicity for chickens at different sites in chickens and ducks following intranasal inoculation. *Avian Pathology*, 24, 545-551.
- Xu, X., Subbarao, K., Cox, N. J. & Guo, Y. (1999). Genetic characterization of the pathogenic influenza A/goose/Guandong/1/96 (H5N1) virus: similarity of its haemagglutinin gene to those of H5N1 viruses from the 1997 outbreaks in Hong Kong. *Virology*, 261, 15-19.
- Yamamoto, Y., Nakamura, K., Kitagawa, K., Ikenaga, N., Yamada, M., Mase, M. & Narita, M. (2007). Severe Nonpurulent Encephalitis With Mortality and Feather Lesions in Call Ducks

(*Anas Platyrhyncha* Var. *Domestica*) Inoculated Intravenously With H5N1 Highly Pathogenic Avian Influenza Virus. *Avian Diseases*, 51, 52-57.

Zhou, J. Y., Shen, H. G., Chen, H. X., Tong, G. Z., Liao, M., Yang, H. C. & Liu, J. X. (2006).

Characterization of a highly pathogenic H5N1 influenza virus derived from bar-headed geese in China. *Journal of General Virology*, 87, 1823-1833.

For Peer Review Only

### Figure legends

**Figure 1:** Immunohistochemical detection of influenza A nucleoprotein in ducks inoculated intranasally with H5N1 A/turkey/Turkey/1/05. **a.)** Brain, 3 dpi. Multifocal areas of immunolabelled neurons and glial cells. 2.5x. **b.)** Brain, 5 dpi. Diffuse immunolabelling of neurons and glial cells. 2.5x. **c.)** Lung, 1 dpi. Detection of AI nucleoprotein in a small number of air capillary epithelial cells. 5x. **d.)** Lung, 2dpi. Immunolabelling of numerous air capillary epithelial cells. 5x. **e.)** Heart, 3 dpi. Multifocal immunolabelling of myocardiocytes. 5x. **f.)** Heart, 4 dpi. Detection of AI nucleoprotein in myocardiocytes. 5x. **g.)** Feather, 3dpi. Immunolabelling of feather epithelium and pulp. 5x. **h.)** Duodenum, 3dpi. AI viral antigen in myenteric plexus ganglioneurons. 40x.

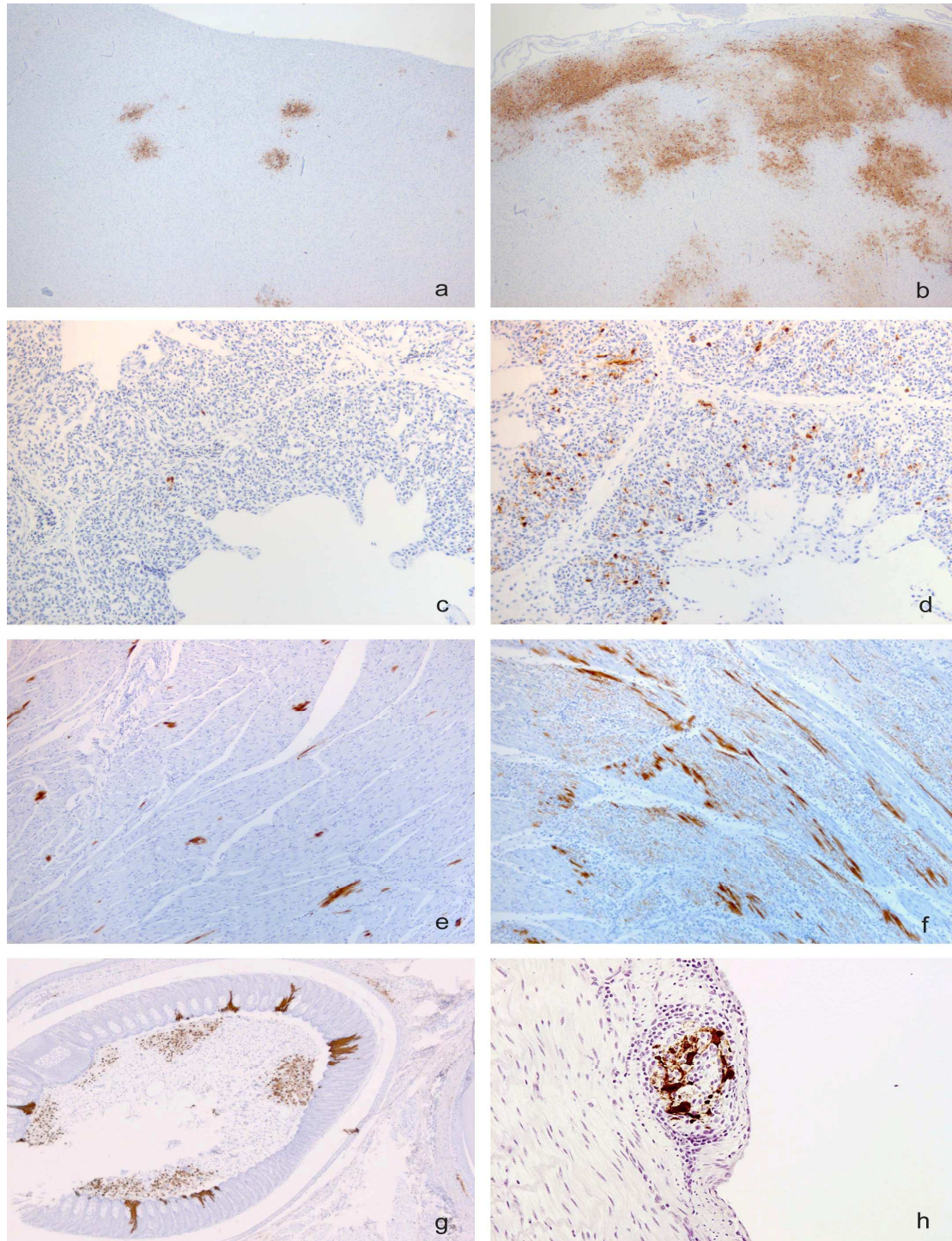
**Figure 2:** Semiquantitative measure of the detection of AI nucleoprotein using immunohistochemistry identified over 5 days in selected tissues of 4-week-old Pekin ducks infected with A/turkey/Turkey/1/05 H5N1 HPAI. "Airways" refers to trachea and main bronchus. IHC was performed using an anti-Influenza A nucleoprotein primary antibody. Semiquantitative scores for each individual organ ranged from 0 to 5 (0: negative; 1: occasional presence of immunolabelled cells; 2: small number of cells; 3: moderate; 4: numerous; 5: widespread immunolabelling). The average score and standard error for the three animals of each time point were calculated for each individual tissue.

**Figure 3:** Matrix gene RRT-PCR results for cloacal (◆) and oropharyngeal (■) swabs taken during 5 days after infection with A/turkey/Turkey/1/05 H5N1 showed a significantly lower level of virus excretion within faeces. Viral RNA detected by RRT-PCR (y axis) was measured as a relative equivalent unit (REU) of RNA against a 10-fold dilution series of RNA purified from infective allantoic fluid of a  $10^6$  EID<sub>50</sub>/0.1ml dose of A/turkey/Turkey/1/2005 H5N1. Error bars indicate SE.

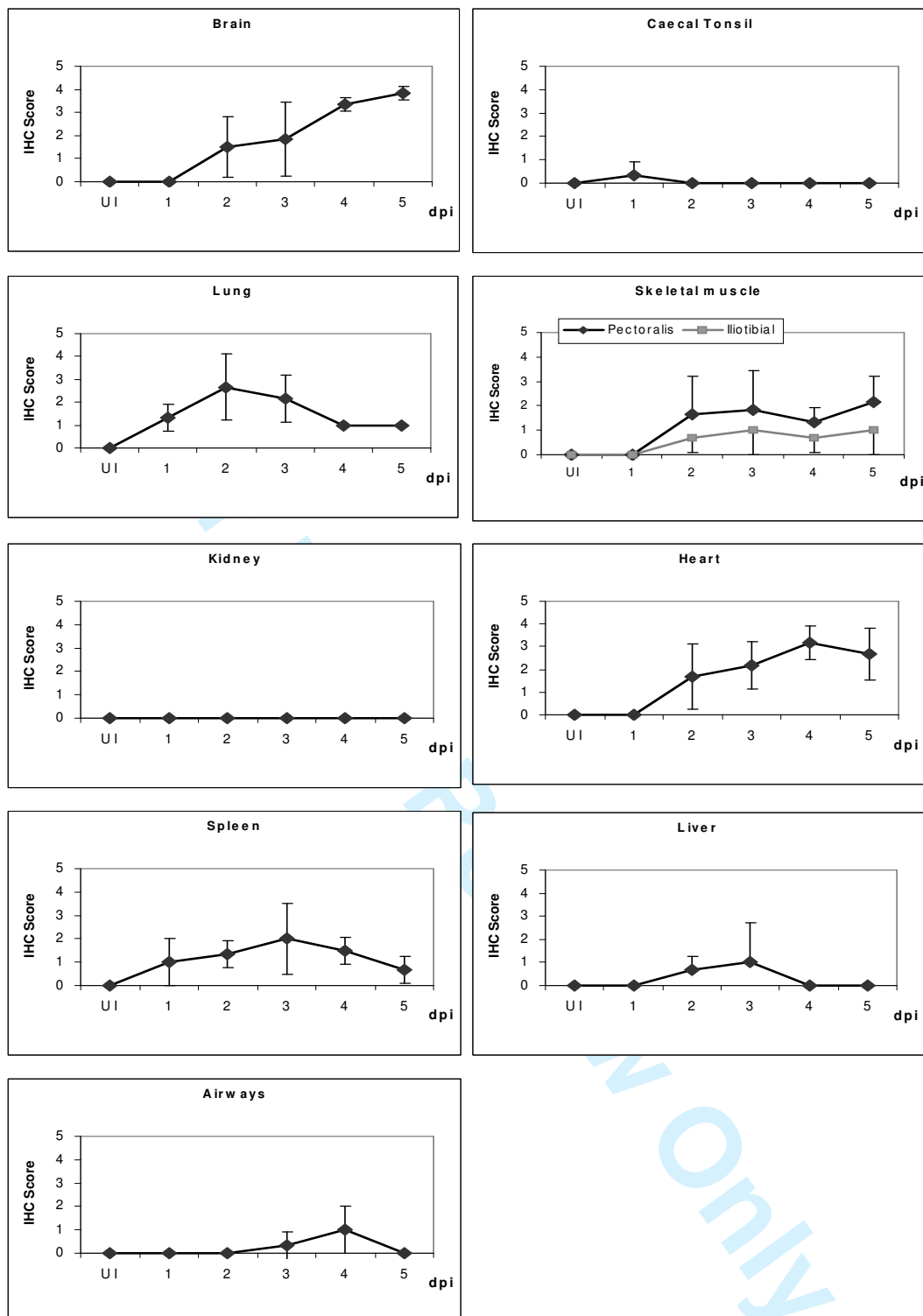
**Figure 4:** *Relative quantitative amounts of viral RNA detected by Matrix gene RRT-PCR over 5 days in selected tissues of 4-week-old Pekin ducks infected with A/turkey/Turkey/1/05 H5N1 HPAI. Viral RNA detected by RRT-PCR was measured as a REU of RNA against a 10-fold dilution series of RNA purified from infective allantoic fluid of a  $10^6$  EID<sub>50</sub>/0.1ml dose of A/turkey/Turkey/1/2005 H5N1. The Y-axes are not shown on the same scale in order to emphasize the trends in viral dissemination in individual tissues. Error bars indicate SE.*

**Figure 5:** *Comparison of the Matrix gene RRT-PCR results for detection of A/turkey/Turkey/1/05 H5N1 HPAI for all tissues identified significantly higher levels of viral RNA in brain and heart. Viral RNA detected by RRT-PCR was measured as a REU of RNA against a 10-fold dilution series of RNA purified from infective allantoic fluid of a  $10^6$  EID<sub>50</sub>/0.1ml dose of A/turkey/Turkey/1/2005 H5N1.*

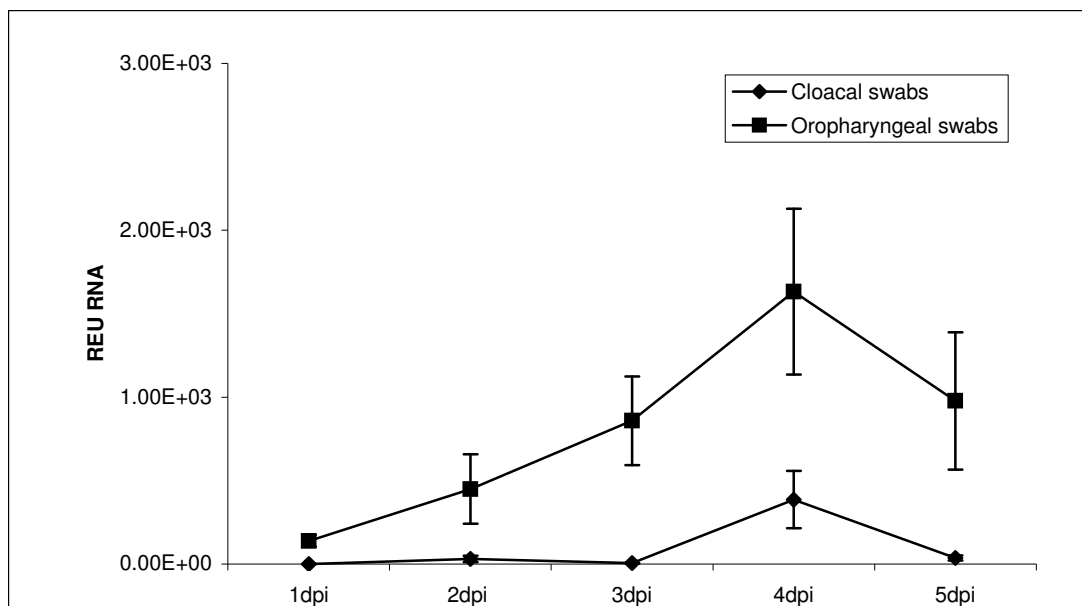




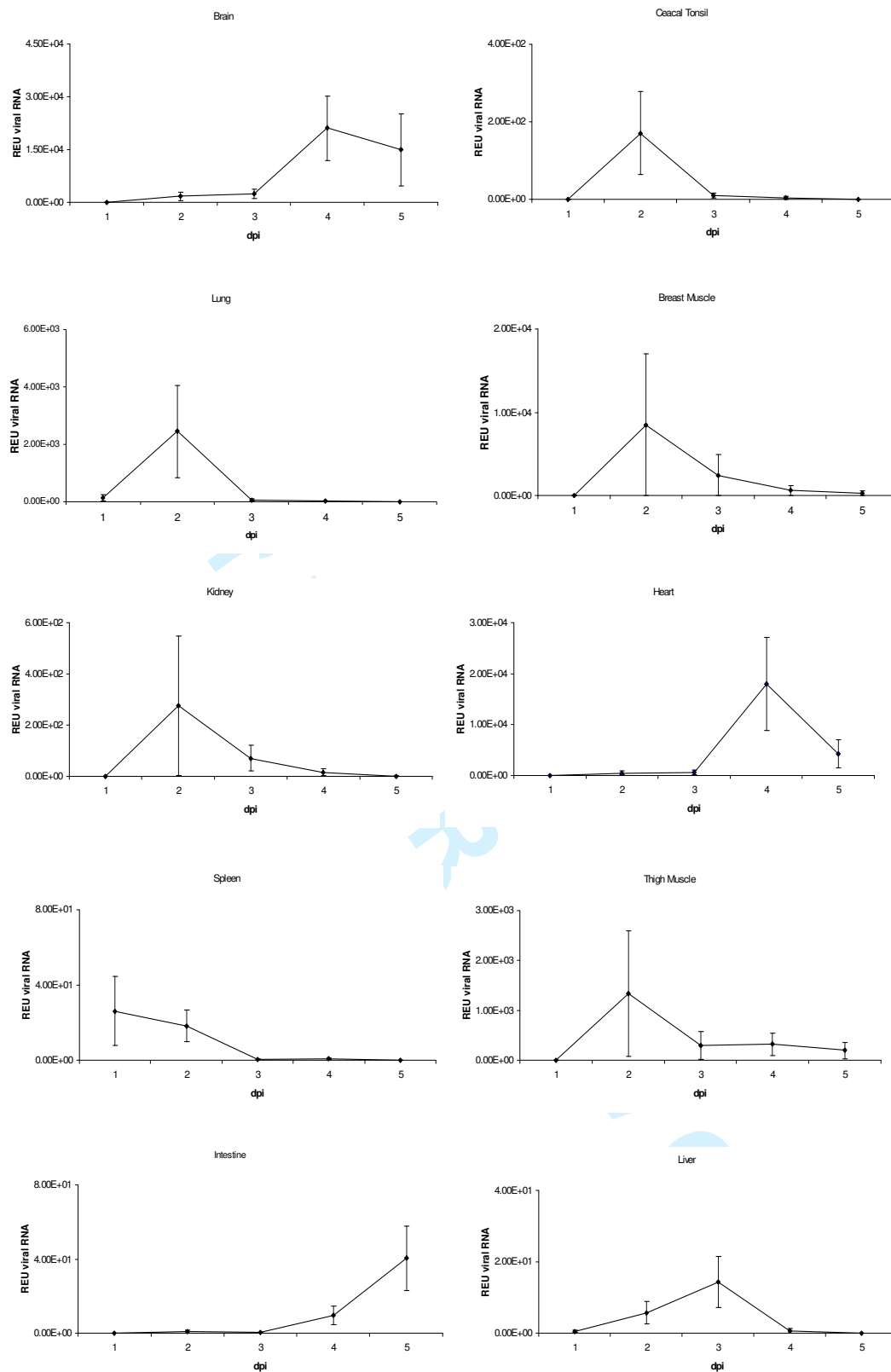
**Figure 1:** Immunohistochemical detection of influenza A nucleoprotein in ducks inoculated intranasally with H5N1 A/turkey/Turkey/1/05. **a.)** Brain, 3 dpi, multifocal areas of immunolabelled neurons and glial cells. 2.5x. **b.)** Brain, 5 dpi, diffuse immunolabelling of neurons and glial cells. 2.5x. **c.)** Lung, 1 dpi, detection of AI nucleoprotein in a small number of air capillary epithelial cells. 5x. **d.)** Lung, 2dpi, immunolabelling of numerous air capillary epithelial cells. 5x. **e.)** Heart, 3 dpi, multifocal immunolabelling of myocardiocytes. 5x. **f.)** Heart, 4 dpi, detection of AI nucleoprotein in myocardiocytes. 5x. **g.)** Feather, 3dpi, immunolabelling of feather epithelium and pulp. 5x. **h.)** Duodenum, 3dpi, AI viral antigen in myenteric plexus ganglioneurons. 40x



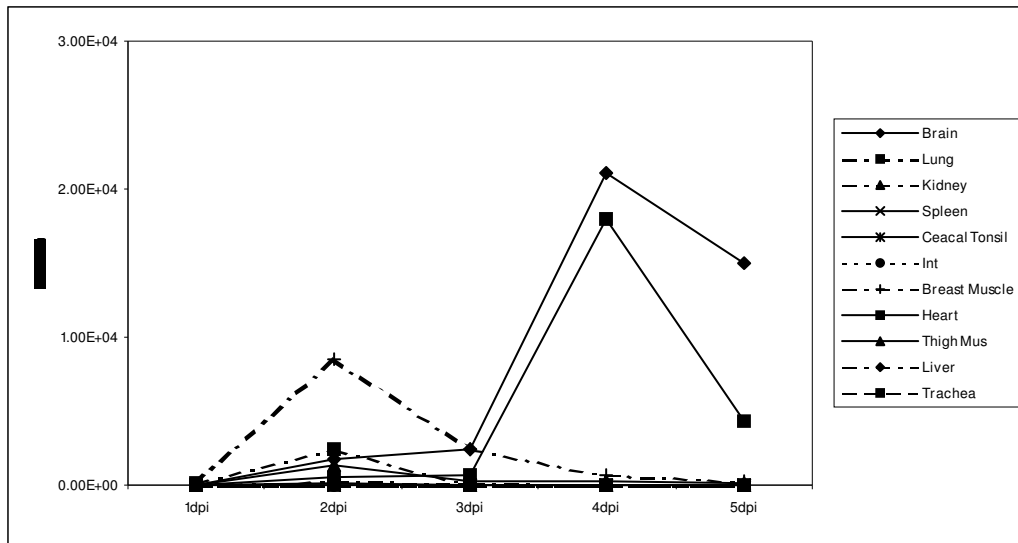
**Figure 2:** Semiquantitative measure of the detection of AI nucleoprotein using IHC identified over 5 days in selected tissues of 4-week-old Pekin ducks infected with A/turkey/Turkey/1/05 H5N1 HPAI. “Airways” refers to trachea and main bronchus. IHC was performed using an anti-Influenza A nucleoprotein primary antibody. Semiquantitative scores for each individual organ ranged from 0 to 5 (0: negative; 1: occasional presence of immunolabelled cells; 2: small number of cells; 3: moderate; 4: numerous; 5: widespread immunolabelling). The average score and standard error for the three animals of each time point were calculated for each individual tissue.



**Figure 3:** Matrix gene RRT-PCR results for cloacal (©) and oropharyngeal (®) swabs taken over 5 days of infection with A/turkey/Turkey/1/05 H5N1 showed a significantly lower levels of virus excretion within faeces. Viral RNA detected by RRT-PCR (y axis) was measured as a relative equivalent unit (REU) of RNA against a 10-fold dilution series of RNA purified from infective allantoic fluid of a  $10^6$  EID<sub>50</sub>/0.1ml dose of A/turkey/Turkey/1/2005 H5N1. Error bars indicate SE.



**Figure 4:** Relative quantitative amounts of viral RNA detected by Matrix gene RRT-PCR over 5 days in selected tissues of 4-week-old Pekin ducks infected with A/turkey/Turkey/1/05 H5N1 HPAI. Viral RNA detected by RRT-PCR was measured as a REU of RNA against a 10-fold dilution series of RNA purified from infective allantoic fluid of a  $10^6$  EID<sub>50</sub>/0.1ml dose of A/turkey/Turkey/1/2005 H5N1. The Y-axes are not shown on the same scale in order to emphasize the trends in viral dissemination in individual tissues. Error bars indicate SE.



**Figure 5:** Comparison of the Matrix gene RRT-PCR results for detection of A/turkey/Turkey/1/05 H5N1 HPAI for all tissues, identified significant higher levels of viral RNA in brain and heart tissues. Viral RNA detected by RRT-PCR was measured as a REU of RNA against a 10-fold dilution series of RNA purified from infective allantoic fluid of a  $10^6$  EID<sub>50</sub>/0.1ml dose of A/turkey/Turkey/1/2005 H5N1.