



HAL
open science

Pathogenicity of a QX strain of infectious bronchitis virus in specific pathogen free and commercial broiler chickens and evaluation of protection induced by a vaccination programme based on the Ma5 and 4/91 serotypes

Calogero Terregino, Anna Toffan, Maria Serena Beato, Roberta de Nardi, Amelio Meini, Giovanni Ortali, Marzia Mancin, Ilaria Capua

► **To cite this version:**

Calogero Terregino, Anna Toffan, Maria Serena Beato, Roberta de Nardi, Amelio Meini, et al.. Pathogenicity of a QX strain of infectious bronchitis virus in specific pathogen free and commercial broiler chickens and evaluation of protection induced by a vaccination programme based on the Ma5 and 4/91 serotypes. *Avian Pathology*, 2008, 37 (05), pp.487-493. 10.1080/03079450802356938 . hal-00540127

HAL Id: hal-00540127

<https://hal.science/hal-00540127>

Submitted on 26 Nov 2010

HAL is a multi-disciplinary open access archive for the deposit and dissemination of scientific research documents, whether they are published or not. The documents may come from teaching and research institutions in France or abroad, or from public or private research centers.

L'archive ouverte pluridisciplinaire **HAL**, est destinée au dépôt et à la diffusion de documents scientifiques de niveau recherche, publiés ou non, émanant des établissements d'enseignement et de recherche français ou étrangers, des laboratoires publics ou privés.



Pathogenicity of a QX strain of infectious bronchitis virus in specific pathogen free and commercial broiler chickens and evaluation of protection induced by a vaccination programme based on the Ma5 and 4/91 serotypes

Journal:	<i>Avian Pathology</i>
Manuscript ID:	CAVP-2008-0004.R1
Manuscript Type:	Original Research Paper
Date Submitted by the Author:	28-Apr-2008
Complete List of Authors:	Terregino, Calogero; OIE/FAO and National reference laboratory for Avian Influenza and Newcastle disease, Virology Laboratory Toffan, Anna; OIE/FAO and National reference laboratory for Avian Influenza and Newcastle disease, Virology Laboratory Beato, Maria Serena; OIE/FAO and National reference laboratory for Avian Influenza and Newcastle disease, Virology laboratory De Nardi, Roberta; OIE/FAO and National reference laboratory for Avian Influenza and Newcastle disease, Virology Laboratory Meini, Amelio; Intervet Italia S.r.l. part of Schering-Plough Ortali, Giovanni; A.I.A. SpA Mancin, marzia; Istituto Zooprofilattico Sperimentale delle Venezie, Centro Regionale di Epidemiologia Veterinaria (CREV) Capua, Ilaria; OIE/FAO and national reference laboratory for Avian Influenza and Newcastle disease, Virology laboratory
Keywords:	Infectious bronchitis, QX serotype, pathogenicity, vaccination

SCHOLARONE™
Manuscripts

CAVP 2008 0004.R1

Formatted: Font: (Default) Times New Roman, 14 pt, Not Bold

Formatted: Font: (Default) Times New Roman, 14 pt, Not Bold

Formatted: Font: (Default) Times New Roman, 14 pt

Formatted: Font: (Default) Times New Roman, Not Bold

Formatted: Left

Pathogenicity of a QX strain of infectious bronchitis virus in specific pathogen free and commercial broiler chickens and evaluation of protection induced by a vaccination programme based on the Ma5 and 4/91 serotypes

Calogero Terregino¹, Anna Toffan¹, Maria Serena Beato¹, Roberta De Nardi¹, Amelio Meini², Giovanni Ortali³, Marzia Mancin⁴ & Ilaria Capua^{1*}

Formatted: Font: (Default) Times New Roman, Bold

Formatted: Left

Formatted: Font: Bold

Formatted: Font: (Default) Times New Roman

Formatted: Font: (Default) Times New Roman

¹OIE/FAO and National Reference Laboratory for Newcastle Disease and Avian Influenza, Istituto Zooprofilattico Sperimentale delle Venezie, Viale dell'Università, 10 - 35020 Legnaro (PD), Italy ²Intervet Italia S.r.l. part of Schering-Plough, Via Walter Tobagi, 7 - 20068 Peschiera Borromeo, Milan, Italy ³A.I.A. SpA Via San Antonio 60, 37036 San Martino Buonalbergo, Verona, Italy ⁴Centro Regionale di Epidemiologia Veterinaria (CREV), Istituto Zooprofilattico Sperimentale delle Venezie, Viale dell'Università, 10 - 35020 Legnaro (PD), Italy

Deleted: ¶

Formatted: Font: (Default) Times New Roman, Italian (Italy)

Formatted: Font: (Default) Times New Roman, Italian (Italy)

Formatted: Font: (Default) Times New Roman, Italian (Italy)

Formatted: Font: (Default) Times New Roman, Italian (Italy)

*Corresponding author: Ilaria Capua. Tel.: +39 049 8084371, Fax: +39 049 8084360;

Formatted: Font: (Default) Times New Roman, Italian (Italy)

e-mail: icapua@izsvenezie.it

Formatted: Font: (Default) Times New Roman

Running title: QXIBV pathogenicity and vaccination

Received: 9 January 2008

Formatted: Font: (Default) Times New Roman, 12 pt, Italic

Abstract**Formatted:** Font: (Default) Times
New Roman

The aims of this study were firstly to evaluate the pathogenicity of an Italian isolate of the QX strain of infectious bronchitis (IB) virus using 1-day-old female SPF chicks (layer type) and 1-day-old female commercial broiler type chickens and secondly to assess the level of protection induced in these birds by a vaccination programme including the IB Massachusetts and 4/91 serotype live attenuated vaccines.

Unvaccinated birds showed clinical signs of varying severity, predominantly affecting the upper respiratory tract. Vaccinated birds appeared healthy, with the exception of a very mild conjunctivitis affecting a limited number of the broilers. Vaccination fully protected SPF birds, since no histopathological lesions were observed, nor was virus detected following challenge. In broilers replication of the challenge virus was not prevented but was significantly reduced.

The present study confirms that vaccination at day-old and at 14 days of age using the Ma5 and 4/91 IB vaccines may be instrumental in reducing the economic impact of QX IBV infections in layer and broiler farms.

Introduction

The Italian poultry industry has observed in recent years an increasing incidence of respiratory pathologies related to infection with infectious bronchitis virus (IBV) (Beato *et al.*, 2005b). The IB viruses involved may be classified into three groups: native viruses with a localized incidence in Italy (624/I serotypes) (Capua *et al.*, 1994; 1999); those that apparently originated in Italy and spread across Europe (IT-02 serotypes) (Jones *et al.*, 2005); those that have originated elsewhere and spread across Italian borders (793B, B1648, CR-84221, Chinese QX-like serotypes) (Beato *et al.*, 2005 a, b).

Some IB variants however, regardless of where they were first isolated, appear to become predominant in several countries over a certain period of time. This has occurred in the past with the so-called Dutch variants (D1466 and D274) during the 1980s, the UK 793B (4/91; CR88) strain during the early 1990s, the Italian strain (IT-02) at the turn of the century and the QX-like IBV in more recent times. These viruses appear to have become widespread in several countries in Europe, and are causing severe losses to both the layer and broiler industry (Worthington *et al.*, 2004; 2006).

Since 2004 the circulation of a new IBV variant has been reported in China (Liu *et al.*, 2004). This virus, identified as QX, was associated predominantly with various forms of renal pathology. Following this first report other investigators have described the circulation of similar strains in China (Liu *et al.*, 2005). Cuiping *et al.*, (2007) confirmed data presented by Liu *et al.* (2005), reporting the isolation of nephropathogenic strains from vaccinated and unvaccinated chicken flocks between 2003 and 2005.

A retrospective phylogenetic analysis on IBV strains isolated in Russia between 1998 and 2002 showed the isolation from a broiler farm of genetically related QX virus in the Far East of Russia in 2001 (near the border with China (Bochkov *et al.*, 2006). The virus appeared in the Western regions of the country in 2002. For both viruses no information was available on the clinical signs seen in birds or on the vaccination status of the flock.

In Europe the first report of the circulation of a similar nephropathogenic IBV was in the Netherlands between 2003 and 2004 (Landman *et al.*, 2005). The viral strain, later characterized as QX-like, was suspected of causing a high incidence of false layers and was detected in the kidneys and oviduct of challenged SPF and commercial chickens (Landman *et al.*, 2005).

The circulation of QXIBV in different European countries such as Belgium, Germany, France and the Netherlands has also been reported (Worthington & Jones, 2006). These results formed part of a survey beginning in 2002 and including a total of 3200 field samples from Western European countries with approximately 12% of viruses being related genetically to the QX strain. In this survey, no QX virus was detected in samples collected in Spain and the UK. In 2005 the presence of a QX strain was reported in Northern Italy from backyard chickens (Beato *et al.*, 2005a) and commercial flocks (Beato *et al.*, 2005b). The first isolation of a QX related strain in UK, from a Pekin bantam presenting with swollen kidneys at post mortem examination has been reported recently (Gough *et al.*, 2008).

No information is available currently on the origin and means of introduction of this strain from China to the Western hemisphere (Gough *et al.*, 2008; Bochkov *et al.*, 2006). In order to explain the very distant geographic locations of this strain,

introduction by wild birds has been hypothesized based on the evidence that IBV may replicate in Anseriformes (Bochkov *et al.*, 2008).

Extensive clinical experience and laboratory studies have shown that vaccination with two or more different live attenuated IBV vaccines confers a broad protection against many important heterologous serotypes (Cook *et al.*, 1999; 2001; Worthington *et al.*, 2006). This has led to the “protectotype” concept, according to which significant cross-protection can be obtained by using strains which are dominant antigenically.

The aims of this study were to evaluate the pathogenicity of an Italian isolate of the IBV QX strain in broiler and layer type chickens and to assess the levels of protection generated by a vaccination programme, commonly used in Italy, including the IB Massachusetts type (Ma5) and the UK variant 4/91 (793B) vaccines against a laboratory challenge with this strain. The trial was carried out in specific pathogen free (SPF) chickens (layer type) and commercial broilers (meat type) with levels of protection following challenge determined on the basis of clinical signs, electron microscopy and histological examination of the tracheas, kidneys, ovary and oviduct, based on information contained in *European Pharmacopoeia* (Council of Europe, 2007).

Materials and Methods

Birds. Twenty-four 1-day-old White Leghorn SPF female chicks (layer type) hatched at the experimental premises were randomly divided and placed in two separate negative pressure isolators. The same number of 1-day-old female broiler chicks

Formatted: Font: (Default) Times New Roman

Formatted: Font: (Default) Times New Roman

Formatted: Font: (Default) Times New Roman

(meat type) supplied by a commercial broiler company were similarly divided and placed in two isolators. Six 1-day-old chicks (3 SPF and 3 broilers) were used as negative controls and housed separately in a fifth isolator. The birds were provided with food and water *ad libitum*. The day-old commercial chicks originated from a parent flock vaccinated against IB with live and inactivated vaccines. Live IBV vaccines in breeders were administered 3 times by spray: at 18 days (H120, Massachusetts serotype) and at 42 and 84 days of age (4/91 serotype). Inactivated vaccine containing Massachusetts and 4/91 serotypes was administered by intramuscular injection before the onset of egg laying (16 weeks). The geometric mean haemagglutination inhibition (HI) maternal antibody titre (using M41 as antigen) in the 1-day-old broiler chicks used in the present study was approximately $\log_2 5$.

IBV challenge strain. A virulent strain of IBV-QX-like virus (1997/V05) isolated

during an outbreak of IB in a broiler farm in Northern Italy, in 2005 was used.

Clinical signs and lesions observed during the outbreak were an increase in mortality rate and nephritis. The challenge virus was isolated from trachea and kidneys of sick and dead broilers in 9 to 11-day-old embryonated SPF chicken eggs. The strain was identified by means of RT-PCR (Adzhar *et al.*, 1996) and sequencing of the amplifier products as described by Keeler *et al.* (1998). The isolate showed a high sequence homology (99%) with the S1 amplified fragment of a Chinese strain (QXIBV) associated with nephritis in broilers (Liu & Kong, 2004). The virus stock for the challenge study was produced by inoculating the field isolates into embryonated SPF chicken eggs via the allantoic cavity and collecting the infectious allantoic fluid 72h post inoculation. The allantoic fluid was clarified by centrifugation at 3000g for 10

Formatted: Font: (Default) Times
New Roman

minutes and filtered with a Teflon membrane. The median embryo infective dose (EID₅₀) was determined by the Reed and Munch formula (Reed & Munch, 1938).

Vaccines. The vaccines used for the trial were Nobilis Ma5 and Nobilis IB 4/91 live attenuated vaccines supplied by Intervet® Italia containing the IB Massachusetts serotype (Ma5) and the UK variant 4/91 (793B) respectively. The vaccines were kept at a temperature of +2-8 °C until used.

The vaccine was dissolved in sterile distilled water (30 ml per 1000 doses) and one drop was applied onto one nostril of each chick in accordance with the manufacturer's instructions.

One bird dose of Nobilis Ma5 contained at least 10^{3.5} EID₅₀. One bird dose of the Nobilis 4/91 vaccine contained 10^{3.6} EID₅₀.

Experimental design. Four groups of 12 birds each were used in the study; two groups of SPF chickens and two groups of commercial broilers. A negative control group composed of 3 SPF chickens and 3 broilers was also included. Two groups of birds were vaccinated and the other two left unvaccinated. The experimental design used is described below and shown in Table 1:

- **Group 1:** 12 SPF chicks vaccinated via the nasal route with Nobilis Ma5 at day-old and boosted with Nobilis IB 4/91 at 14 days.
- **Group 2:** 12 unvaccinated control SPF chicks.
- **Group 3:** 12 commercial broiler chicks vaccinated via the nasal route with Nobilis Ma5 at day-old and with Nobilis IB 4/91 at 14 days.
- **Group 4:** 12 unvaccinated control commercial broiler chicks.

Formatted: Font: (Default) Times New Roman

Formatted: Font: (Default) Times New Roman

Formatted: Font: (Default) Times New Roman

- **Group 5:** 3 SPF chicks and 3 unvaccinated commercial broiler chicks used as a negative control.

Three weeks after the second vaccination, at 35 days of age, chickens from groups 1, 2, 3 and 4 were challenged simultaneously with 100 μ l of challenge virus at a dose of 3.0 log₁₀ EID₅₀ per 0.1 ml, administered via the oculonasal route. Group 5 was left as an unchallenged control.

Prior to challenge, a blood sample was collected from each bird in order to determine the HI antibody titre (Alexander *et al.*, 1983) using M41, 4/91, 624/I, IT02 and QX strains of IBV as haemagglutinating (HA) antigens.

Following challenge, all birds were observed daily for clinical signs attributable to IB infection (see clinical signs in the results section). On the 4th, 5th and 6th day post challenge, four birds from each group and two birds (one SPF chicken and one broiler) from the control group were killed humanely. Trachea, kidney, ovary and oviduct were collected for virus detection. Ovary and oviduct were pooled.

Serological assay. The HI test was used to evaluate the antibody response in SPF and commercial chickens. The strains used as antigens for the HI test, were Italian field isolates identified by means of RT-PCR (Adzhar *et al.*, 1996) with sequencing of the amplified products (Keeler *et al.*, 1998). HA antigens were prepared from chorioallantoic fluid harvest from IBV-inoculated embryonated SPF eggs and concentrated 100-fold by ultracentrifugation. The concentrated IBV strains were treated with bacterial phospholipase C for 2h at 37°C and used as HA antigens in a microtitre HI test as follows: 4 HA units of antigen was added to two-fold dilutions of serum. After incubation for 30 min at room temperature, a chicken red blood cell

Formatted: Font: (Default) Times
New Roman

solution (0.5 %) was added and the test read 45 min later. A serum was considered positive with a titre >1:8.

Virus detection. The trachea was removed from each bird and a portion fixed in 10% buffered formalin for histological and scanning electron microscope (SEM) examinations (Robards & Wilson, 1993), with the remaining part used to attempted virus isolation. For virological examination the tracheal mucosa was scarified with a sterile scalpel blade and transferred into a test tube with 3ml of phosphate buffered saline (PBS) supplemented with antibiotics (10,000 U/mL of penicillin, 10 mg/mL of streptomycin, 0.25 mg/mL of gentamycin and 5,000 U/mL of mycostatin) and 5% of tryptose broth. kidney, ovary and oviduct were also sampled simultaneously and portions fixed in 10% buffered formalin for histological examination. The remaining portions were frozen at -80°C for virus isolation attempts.

To attempt virus isolation from kidney, ovary and oviduct, samples were homogenized with sterile quartz sand, diluted 1:10 with PBS containing antibiotics and left overnight at +4°C before being processed. Samples were inoculated via the allantoic cavity into five, 9 to 11-day-old SPF embryonated hens' eggs with bacteria-free samples. The eggs were candled daily to record embryo mortality. After 7 days, the live embryos were chilled at +4°C and then examined for gross lesions and allantoic fluids harvested for EM examination. Embryo mortality recorded in the first 24 h post inoculation was considered nonspecific. In addition, the allantoic fluid was analyzed by RT-PCR with specific primers for the S1 gene (Adzhar *et al.*, 1996). The cDNA obtained was sequenced (Keeler *et al.*, 1998) and the isolates typed on the basis of the sequence to confirm the identity of the strains.

Formatted: Font: (Default) Times New Roman

Formatted: Font: (Default) Times New Roman

Formatted: Font: (Default) Times New Roman

Samples were considered negative if the embryos did not show lesions after three blind passages at 7day intervals. A positive sample was recorded if EM examination of concentrated allantoic fluid revealed coronavirus-like virions and sequence analysis of the isolate confirmed it as the challenge strain.

Electron microscopy.

Transmission electron microscopy (TEM). Samples were diluted 10 fold in PBS, frozen and thawed repeatedly and clarified by a two-steps centrifugation (2,500g at 8°C for 30 min and 7,000g at 8°C for 30 min). Next, an aliquot of 85 ml of the supernatant was ultracentrifuged for 15 min in a Beckman Airfuge, using rotor A-100, at 20 psi (125,000g), to pellet the viral particles on formwar carbon coated copper grids (Doone & Anderson, 1987). The grids were stained using a 2% sodium phosphotungstate solution in distilled water (pH 6.8) for about 3 min. The dried grids were observed using a TEM Philips operating at 80kV, at 19,000-45,000 x.

Formatted: Font: (Default) Times New Roman, Bold

Formatted: Font: (Default) Times New Roman

Scanning electron microscopy (SEM). Portions of trachea were collected from each animal and immediately fixed in 10% neutral buffered formalin. Formalin fixed samples were then dehydrated by passages in graded solutions of acetone/alcohol (30/70; 50/50; 70/30; 100 absolute alcohol). Critical point drying and sputter coating of the samples was then carried out (Robards & Wilson, 1993). The tracheas were finally observed with the SEM Cambridge Stereoscan, at 20 KV, with 4-50µm of magnitude.

Formatted: Font: (Default) Times New Roman, Italic

Formatted: Font: (Default) Times New Roman

Formatted: Font: (Default) Times New Roman

Formatted: Font: (Default) Times New Roman

Statistical analysis. Virological data were analyzed using Fisher's exact test in order to obtain a statistical analysis of the differences between vaccinated and non-vaccinated groups.

HI titres of broiler and SPF chicken sera tested with different IBV antigens were compared and analyzed statistically with the non-parametric signed rank Wilcoxon test. Moreover a comparison between HI titres obtained with the same antigen in SPF chickens and broilers were compared and analysed statistically using the non-parametric Wilcoxon-Mann-Whitney test (Siegel & Castellan, 1992).

Formatted: Font: (Default) Times New Roman

Results

Clinical signs. At 48h after challenge birds of group 4 (unvaccinated broilers), exhibited severe conjunctivitis, mainly of a frothy type, associated with abundant lacrimation, oedema and cellulitis of the periorbital tissues (Figure 1a). In addition the birds appeared lethargic, reluctant to move and in some cases presented with dyspnoea. These symptoms regressed progressively in intensity until their disappearance approximately 96h after infection. In group 2 (SPF, unvaccinated), depression, conjunctivitis and periorbital oedema were observed, but in a milder form (Figure 1b), with complete disappearance of symptoms 72h after challenge. In groups 1 and 3 (SPF and broiler, vaccinated) no clinical signs attributable to IBV infection were observed, with the exception of a very mild conjunctivitis in some broilers which resolved within 48h.

Formatted: Font: (Default) Times New Roman

Formatted: Font: (Default) Times New Roman

Scanning electron microscopy. The SEM examination of tracheas of both non-vaccinated groups (2 and 4) revealed lesions in the respiratory mucosa caused by replication of the challenge virus (Figures 2a and 3a). This was represented visually by severe erosion of the respiratory epithelium with inflammatory lesions affecting the mucosa. In groups 1 and 3 (vaccinated), no signs of damage or lesions of the trachea were observed (Figures 2b and 3b). The condition of the respiratory epithelium in these birds was comparable to that of the controls (group 5).

Formatted: Font: (Default) Times New Roman

Virus isolation and detection. The results of the virological examinations are shown in Table 2. In groups 2 and 4 (non-vaccinated) challenge virus was re-isolated from the tracheas of all birds and RT-PCR and sequence analysis of the re-isolated viruses revealed a 99% homology of the S1 gene with the IBV QX virus. In the same groups, the IBV QX virus was also isolated from kidneys and ovaries/oviducts in almost all the infected birds.

Formatted: Font: (Default) Times New Roman, Not Bold, Not Italic

Formatted: Font: (Default) Times New Roman

In the vaccinated groups the numbers of infected chickens were lower than in the control groups. No birds were positive in the vaccinated SPF chicks. In the vaccinated broilers, the majority of positive samples were obtained from tracheas (50%) while only in one case was the challenge virus isolated from the urogenital tract (kidney).

Histological examination. The tracheas of non-vaccinated birds showed erosive catarrhal tracheitis with varying degrees of ciliary structure disappearance and infiltration of lymphoid elements in the thickness of the submucosa itself. There was no evidence of histological lesions in the vaccinated birds. Foci of necrosis and large amount of urates in ureters were observed in the kidneys of non-vaccinated birds,

Formatted: Font: (Default) Times New Roman

while no lesions attributable to infection with IBV were observed in the vaccinated ones. No histological evidence of damage in the reproductive tract was noted in any of the infected birds.

Serological results. The recorded antibody titres showed a low humoral response, typical of that induced by live-attenuated IB vaccines. The results of HI tests performed 21 days following the second vaccination (day of challenge) reveal a specific antibody response to the vaccine strains. The HI response to heterologous antigens (624/I, IT/02 and QX) was lower, as expected. The HI geometric mean antibody titres (\log_2) at 21 days after the second vaccination are presented in Table 3.

Formatted: Font: (Default) Times New Roman

Statistical analysis. The analysis of virological results, revealed a significant difference between the number of positive samples among the vaccinates and the non-vaccinates ($p < 0.05$), which was more evident between the groups of SPF chickens. The statistical analysis of HI titres showed higher values ($p < 0.05$) in both SPF and broilers using the vaccine strains (Massachusetts and 4/91 serotypes) as antigens compared to the other antigens. Broilers showed higher HI titres ($p < 0.05$) when sera were tested with the 4/91 antigen than with the M41. This significant difference was not observed for SPF chicken sera. Moreover the HI titres of SPF chickens were higher than those of broiler sera when tested against the vaccine strains ($p < 0.05$).

Formatted: Font: (Default) Times New Roman

Discussion

Formatted: Font: (Default) Times New Roman

Formatted: Font: (Default) Times New Roman

The results presented herein can be considered as additional evidence that protection against challenge with a heterologous strain of IBV may be achieved by using a vaccination programme containing two live IB vaccine strains that differ antigenically, when administered at an interval of two weeks.

According to the European Pharmacopoeia's reference standards, the test to evaluate IBV vaccine protection is considered valid if the challenge virus is isolated from no less than 80% of the control group. A vaccine is considered effective if the challenge virus is isolated from less than 20% of the animals vaccinated. All of the non-vaccinated birds were infected, based on detection of the virus in tracheas, thus the challenge experiment was successful. Vaccination reduced and, in many cases prevented, replication of the challenge virus in the respiratory tract. As a consequence lesions induced by the IBV QX-like virus in the trachea were absent.

The presence of viable virus in the ovary/oviduct and the kidneys confirms the ability of IBV QX challenge virus to replicate in the female reproductive tract, as well as its nephropathogenic potential (Liu & Kong, 2004; Beato *et al.*, 2005a). It is likely that this localisation gives rise to local damage that could cause impaired development of the ovary and the oviduct and therefore impact negatively on future laying activity (Landman *et al.*, 2005; Bano *et al.*, 2006). However in our experiment, no relevant histological lesions were detected in the reproductive tract following IBV QX challenge. The reason for this could be that samples were collected within 6 days after challenge and damage to the ovary and oviduct could take a longer period to develop. IBV infection of very young layer hens can produce permanent damage to the genital tract that could be evident only several weeks after infection, when the birds come into lay, leading to reduced egg production and quality (Cavanagh & Naqi, 2003) or increasing the incidence of false layers in the flock.

The higher susceptibility of vaccinated broiler chicks compared to that recorded in vaccinated SPF chickens could be related to the fact they are offspring of breeders which are immune to IBV as a result of multiple vaccinations. Maternally derived antibodies are known to interfere with IB vaccines administered at day-old (Mondal & Naqi 2001, Cardoso *et al.*, 2006). For this reason, particularly under field conditions, it seems reasonable to recommend a double vaccination similar to the one used in our experimental protocol.

In broilers the HI antibody response against the Massachusetts serotype vaccine strain, administered at day-old, was lower ($p < 0.05$) than the HI antibody response against the 4/91 serotype used for boosting the birds at 14 days of age. By contrast this difference was not observed in SPF chickens. These data show and confirm the interference of the maternal immunity on the response to vaccination performed in one-day-old chicks. On the whole, broiler chicks had lower HI antibody response ($p < 0.05$) to the vaccination compared to SPF chicks.

A medium to low humoral response is in keeping with that expected following the administration of live attenuated IB vaccines. As expected the highest titres were obtained using antigens homologous to vaccine strains. However, birds appeared to be protected against heterologous challenge. The reason for this could be that the presence of local immunity of the upper respiratory tract induced by vaccination reduced the replication of challenge virus after challenge by the oculonasal route. Furthermore immune responses directed to epitopes involved in protective immunity, might not be fully detected by the HI test.

Despite the low level of genetic homology in the S1 protein between the vaccine and challenge strains, the protection achieved with the vaccination programme used in the present study was high. In fact, the genetic relationship

calculated by the alignment of the hypervariable region of the S1 gene (386 bp) between QXIBV and Ma5 and QXIBV and 4/91 strains was 77.1% and 81 % respectively. This confirms previous data (Cook *et al.*, 1999; Worthington *et al.*, 2006) showing that good protection can be achieved by vaccines containing serotypes that differ both antigenically and genetically from the challenge virus. As already proposed, the reason could be that, despite extensive difference in S1 protein, there are epitopes in common among different strains of IBV, which play a major role in protective immunity (Cavanagh *et al.*, 1997).

Based on data presented in this study it can be concluded that under experimental conditions the Nobilis Ma5 and IB 4/91 Intervet® vaccines administered on 1 and 14 days respectively, protect chickens from infection and disease following challenge with the IB QX-like variant. This confirms that such vaccination programmes may be useful under field conditions to reduce the economic losses caused by QX IB infections on commercial layer and broiler farms.

Formatted: Font: (Default) Times New Roman

Acknowledgements

Formatted: Font: (Default) Times New Roman

The authors wish to thank all the staff of Virology and Biotechnology Laboratories of Istituto Zooprofilattico Sperimentale delle Venezie and Dr. Dick Gough for the revision of the manuscript.

References

Formatted: Font: (Default) Times New Roman

Adzhar, A., Shaw, K., Britton, P. & Cavanagh, D. (1996). Universal oligonucleotides for the detection of infectious bronchitis virus by the polymerase chain reaction. *Avian Pathology*, 25, 817-836.

Formatted: Font: (Default) Times New Roman

Alexander, D.J., Allan, W.H., Biggs, P.M., Beacewell, C.D., Darbyshire, J.H., Dawson, O.S., Harris, H.A., Jordan, F.T.W., Macpherson, I., McFerran, J.B., Randall, C.J., Stuart, J.C., Swarbrick, O. & Wilding, G.P. (1983). A standard technique for haemagglutination inhibition test for antibodies to avian infectious bronchitis virus. *The Veterinary Record*, 113, 64.

Formatted: Font: (Default) Times New Roman, Italian (Italy)

Bano, L., Bellato, S., Cocchi, M., Terregino, C., Vascellari, M. & Agnoletti, F. (2006). High incidence of "false layers" in a group of commercial hens. Proceeding of the XLV Annual Convention of the Italian Society of Avian Pathology (SIPA), 28 September 2006, Forlì, 29-32.

Formatted: Font: (Default) Times New Roman

Beato, M. S., De Battisti, C., Terregino, C., Drago, A., Capua, I. & Ortali, G. (2005a). Evidence of circulation of a Chinese strain of infectious bronchitis virus (QXIBV) in Italy. *The Veterinary Record*, 156, 720.

Beato M. S., Terregino C., De Nardi R., Toffan A., Cattoli G. & Capua I. (2005b). "Epidemiological study on circulation of infectious Bronchitis Virus strains in North Eastern Italy". *Italian Journal of Animal Science*, 3, 263-265.

Bochkov, Y.A., Batchenko, G.V., Shcherbakova, L.O., Borisov, A.V. & Drygin V.V. (2006) Molecular epizootiology of avian infectious bronchitis in Russia. *Avian Pathology*, 35, 379-393.

Formatted: Font: (Default) Times New Roman, Italian (Italy)

Capua, I., Gough, R.E., Mancini, M., Casaccia, C. & Weiss, C. (1994). A 'novel' infectious bronchitis strain infecting broiler chickens in Italy. *Zentralbl Veterinarmed B.* 41, 83-89.

Formatted: Font: (Default) Times New Roman

Formatted: Font: (Default) Times New Roman

Capua, I., Minta, Z., Karpinska, E., Mawditt, K., Britton, P., Cavanagh, D. & Gough, R.E.

Formatted: Font: (Default) Times New Roman

(1999). Co-circulation of four types of infectious bronchitis virus (793/B, 624/I, B1648 and Massachusetts). *Avian Pathology*, 28, 587-592.

Cardoso, W.M., Gomes, L.P., Romao, J.M., Salles, R.P.R., Teixeira, R.S.C., Sobral,

M.H.N.R., Camara, S.R. & Oliviera, W.F. (2006) Antibodies specific to infectious bronchitis in broilers in Cearà state, Brazil. *Arq. Bras. Med. Vet. Zooc.*, 58, 327-332.

Cavanagh, D. & Naqi, S. (2003). Infectious bronchitis. In: Y.M. Saif, H.J. Barnes, J.R.

Glisson, A.M. Fadly, L.R. McDougald and D.E. Swayne, Editors, *Disease of Poultry* (11th ed.), Iowa State University Press, Ames, IA, pp. 511–526.

Formatted: Font: (Default) Times New Roman, English (U.S.)

Cavanagh, D., Ellis, M.M. & Cook, J.K.A. (1997). Relationship between sequence variation

Formatted: Font: (Default) Times New Roman

in the S1 spike protein of infectious bronchitis virus and the extent of cross-protection in vivo. *Avian Pathology*, 26, 63-74.

Formatted: Font: (Default) Times New Roman, English (U.K.)

Cook, J.K.A., Cheser, J., Orbell, S.J., Baxendale, W., Greenwood, N. & Huggins M.B.

(1991). Protection of chickens against renal damage caused by nephropathogenic infectious bronchitis virus. *Avian Pathology*, 30, 423-426.

Cook, J.K.A., Orbell, S.J., Woods, M.A. & Huggins, M.B. (1999). Breadth of protection of

Formatted: Font: (Default) Times New Roman

the respiratory tract provided by different live-attenuated infectious bronchitis vaccines against challenge with infectious bronchitis viruses of heterologous serotypes. *Avian Pathology*, 28, 477-485.

Formatted: Font: (Default) Times New Roman, English (U.K.)

© Council of Europe (2007). Avian Infectious Bronchitis Vaccine (live) 01/2008:0442. In

Formatted: Font: (Default) Times New Roman

European Pharmacopoeia sixth edition. Strasbourg, Cedex, France. Printed in Germany by Druckerei C.H. Beck, Nördlingen., 865-867.

Cuiping, X., Jixun, Z., Xudong, H. & Guozhong, Z. (2007). Isolation and identification of

four infectious bronchitis virus strains in China and analyses of their S1 glycoprotein gene. *Veterinary Microbiology*, 122, 71.

Formatted: Font: (Default) Times New Roman, English (U.S.)

Doane, F.W. & Anderson, N. (1987). Electron microscopy in diagnostic virology. A

practical guide and atlas. Ed. Cambridge University Press.

Formatted: Font: (Default) Times New Roman

Gough, R. E., Cox, W. J., de B. Welchman, D., Worthington, K. J. & Jones, R. C. (2008).

Formatted: Font: (Default) Times New Roman

Chinese QX strain of infectious bronchitis virus isolated in the UK. *The Veterinary Record*, 162, 99-100.

Formatted: Font: (Default) Times New Roman

Jones, R.C., Worthington, K.J., Capua I. & Naylor, C.J. (2005). Efficacy of live infectious

bronchitis vaccines against a novel European genotype, Italy 02. *The Veterinary*

Record, 156, 646-647.

Formatted: Font: (Default) Times New Roman, English (U.S.)

Keeler, C.L., Reed, K.L., Nix, W.A. & Gelb, J. (1998). Serotype identification of avian

Formatted: Font: (Default) Times New Roman

infectious bronchitis virus by RT-PCR of the peplomer (S-1) gene. *Avian Diseases*, 42, 275-284.

Landman, W.J.M., Dwars, R.M. & de Wit J.J. (2005). High incidence of false layers in

(re)production hens supposedly attributed to a juvenile infectious bronchitis virus

infection. *14th World Veterinary Poultry Congress*, 22-26 August 2005, Istanbul,

Turkey, 369.

Formatted: Font: (Default) Times New Roman

Monjal, S.P. & Naqi, S.A. (2001). Maternal antibody to infectious bronchitis virus: its role

Formatted: Font: (Default) Times New Roman, English (U.S.)

Liu, S.W. & Kong, X.G. (2004). A new genotype of nephropathogenic infectious

Formatted: Font: (Default) Times New Roman

bronchitis virus circulating in vaccinated and non-vaccinated flocks in China. *Avian*

Formatted: Font: (Default) Times New Roman

Pathology, 33, 321-327.

Formatted: Font: (Default) Times New Roman

Liu, S., Chen, J., Chen, J., Kong, X., Shao, Y., Han, Z., Feng, L., Cai, X., Gu, S. & Liu M.

Formatted: Font: (Default) Times New Roman

(2005). Isolation of avian infectious bronchitis coronavirus from domestic peafowl

Formatted: Font: (Default) Times New Roman

(*Pavo cristatus*) and teal (*Anas*). *Journal of General Virology*, 86, 719-725.

Formatted: Font: (Default) Times New Roman, Italian (Italy)

in protection against infection and development of active immunity to vaccine. *Veterinary*

Formatted: Font: (Default) Times New Roman

Immunology and Immunopathology, 79, 31-40.

Reed, L.J. & Muench, H. (1938). A simple method of estimating fifty percent endpoints.

American Journal of Hygiene, 27, 493-497.

Robards, A.W. & Wilson, A.J. (1993). Basic biological preparation techniques for SEM. In:

Procedures in electron microscopy. John Wiley and Sons Ltd. Baffins Lane,

Chichester, West Sussex PO19 1UD England

Sidney, S N. & J. Castellan, Jr., J. (1992). Statistica non parametrica 2/ed. Curatore edizione

italiana. Ettore Caracciolo, McGraw-Hill libri Italia srl.

Formatted: Font: (Default) Times
New Roman

Worthington, K.J., Savage, C., Naylor, C.J., Wijmenga, W. & Jones, R.C. (2004). An RT-

Formatted: Font: (Default) Times
New Roman

PCR survey of infectious bronchitis virus genotypes in the UK and selected European

countries between 2002 and 2004 and the results from a vaccine trial. Proc. IV

symposium on avian corona and pneumovirus infections, Rauschholzhausen,

Germany, 125-133.

Formatted: Font: (Default) Times
New Roman

Worthington, K.J. & Jones, R.C. (2006). An update in the European RT-PCR IBV survey

and recent findings on a novel IBV genotype. Proceedings of Vth *Symposium on*

Formatted: Font: (Default) Times
New Roman, Not Italic, English (U.K.)

avian corona and pneumovirus infections, Rauschholzhausen, Germany, pp.176-188.

Formatted: Font: (Default) Times
New Roman

Figure Legends.

Formatted: Font: (Default) Times New Roman, Not Italic

Formatted: Font: (Default) Times New Roman

Figure 1: a) Non-vaccinated, broiler, 48 hours post challenge, with the QX strain of IBV. Serous conjunctivitis with abundant lacrimation, oedema and periorbital cellulitis. b) Non-vaccinated SPF chicken, 48 hours post challenge, periorbital oedema.

Figure 2: a) Image of respiratory epithelium from trachea of non-vaccinated SPF chicken, 6 days post-challenge with IB QX. Area of epithelium completely destroyed. Zones without cilia alternating with zones of erosion. Scanning microscope (SEM) image, 2,000 x magnification; b) Image of respiratory epithelium from trachea of vaccinated SPF chicken, 6 days post-IB challenge. Area of epithelium in optimum condition with long well distributed cilia. Image under SEM, 1,600 x magnification.

Figure 3: a) Image of respiratory epithelium from trachea of non-vaccinated broiler chicken, 6 days post-challenge with IB QX. Area of epithelium with extensive zones of erosion. Adhesion of bacterial components to the damaged epithelium can be seen (arrow). Image under SEM, 800 x magnification. b) Image of respiratory epithelium from trachea of vaccinated broiler chicken, 6 days post IB challenge. Area of epithelium in good condition with long, well-distributed cilia. A slight increase in the production of mucus can be seen (white ovals). Image under SEM, 800 x magnification.

VERITY: FIGURES ARE IN THE PDF FILE.
JANE

Table 1. *Experimental design used to study the ability of live attenuated IB vaccines to protect against challenge with the QX strain of IBV*

Group	Vaccination with Nobilis [®] Ma5 (1-day-old)	Vaccination with Nobilis [®] 4/91 (2 weeks)	Challenge (5 weeks)	Collection of trachea, kidneys and ovary/oviduct at 4, 5 and 6 days post challenge
1. vaccinated SPF chickens	Yes	Yes	Yes	Yes
2. unvaccinated SPF chickens	No	No	Yes	Yes
3. vaccinated broilers	Yes	Yes	Yes	Yes
4. unvaccinated broilers	No	No	Yes	Yes
5. SPF chickens + broilers (control group)	No	No	No	Yes

Table 2. *Results of virological examinations*

Groups	Trachea	Kidney	Ovary/ Oviduct
1. SPF vaccinated chickens	0/12 ^a	0/12	0/12
2. SPF unvaccinated chickens	12/12	11/12	10/12
3. vaccinated broilers	6/12	0/12	1/12
4. unvaccinated broilers	12/12	12/12	12/12
5. SPF chickens + broilers (control group)	0/6	0/6	0/6

^a Number of IBV positive birds/number in group.

Table 3. *Infectious bronchitis geometric mean HI antibody titre (\log_2) at 21 days after the second vaccination (day of challenge)*

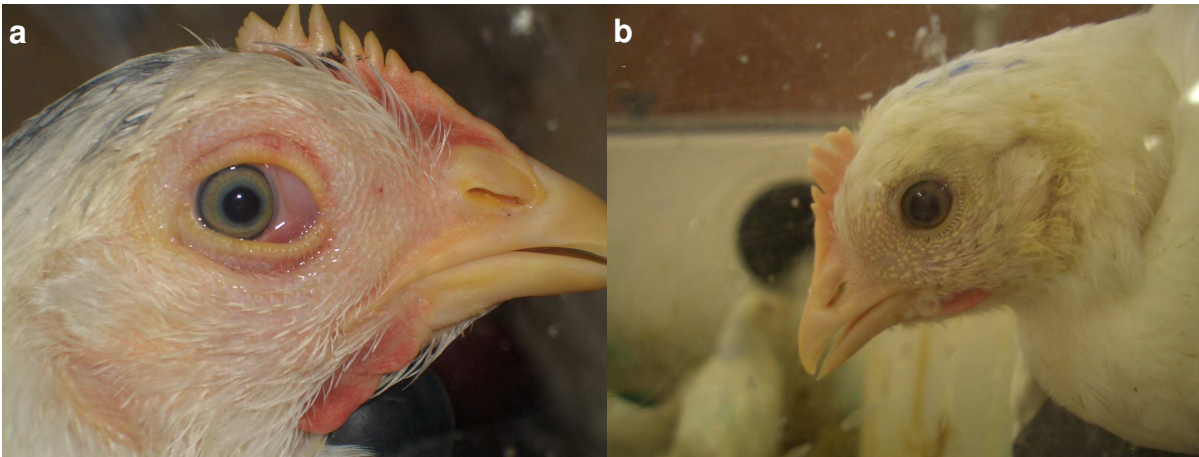
Group	Log ₂ HI antibody titre (mean ± standard deviation) using as antigen				
	M41	4/91	624/I	IT-02	QX

Note to publisher: I COULD NOT COPY OVER THE REST OF THE TABLE (WHICH I DO NOT NEED TO CHANGE). PLEASE CAN YOU GET IT FROM THE PDF FILE.

Formatted: Font: (Default) Times New Roman, Font color: Red

For Peer Review Only

Figure 1: a) Non-vaccinated, broiler, 48 hours post-challenge, serous conjunctivitis with abundant lacrimation, edema and periorbital cellulitis. b) Non-vaccinated SPF chicken, 48 hours post-challenge, periorbital edema.



Review Only

Figure 2: a) Image of respiratory epithelium from trachea of non-vaccinated SPF chicken, 6 days post-challenge. Area of epithelium completely destroyed. Zones without cilia alternating with zones of erosion. Scanning microscope (SEM) image, 2,000 x magnification; b) Image of respiratory epithelium from trachea of vaccinated SPF chicken, 6 days post-challenge Area of epithelium in optimum condition with long well distributed cilia. Image under SEM, 1,600 x magnification.




Figure 3: a) Image of respiratory epithelium from trachea of non-vaccinated broiler chicken, 6 days post-challenge. Area of epithelium with extensive zones of erosion. Adhesion of bacterial components to the damaged epithelium can be seen (arrow). Image under SEM, 800 x magnification;. b) Image of respiratory epithelium from trachea of vaccinated broiler chicken, 6 days post-challenge. Area of epithelium in good condition with long, well-distributed cilia. A slight increase in the production of mucus can be seen (white ovals). Image under SEM, 800 x magnifications.




Table 3. *Infectious bronchitis HI geometric mean antibody titre (log₂ base) at 21 days after the second vaccination (day of challenge)*

Group	Log ₂ HI antibody titre (mean ± standard deviation) using				
	M41	4/91	624/I	IT-02	QX
1- SPF vaccinated chickens	4.92 ± 1.08	5.33 ± 0.88	3.66 ± 0.77	3.16 ± 0.57	3.33 ± 0.49
2 - SPF unvaccinated chickens	0.00	0.00	0.00	0.00	0.00
3 -vaccinated broilers	4.16 ± 0.83	4.50 ± 1.00	3.33 ± 0.65	3.00 ± 0.42	3.25 ± 0.45
4 - unvaccinated broilers	0.00	0.00	0.00	0.00	0.00

For Peer Review Only