



## Rhabdomyosarcoma of the pectoral muscles in a free-living European robin (*Erithacus rubecula*)

Giovanni Manarolla, Enrico Radaelli, Giuseppe Sironi, Giuliano Pisoni,  
Tiziana Rampin

### ► To cite this version:

Giovanni Manarolla, Enrico Radaelli, Giuseppe Sironi, Giuliano Pisoni, Tiziana Rampin. Rhabdomyosarcoma of the pectoral muscles in a free-living European robin (*Erithacus rubecula*). *Avian Pathology*, 2009, 37 (03), pp.311-314. 10.1080/03079450802043767 . hal-00540114

**HAL Id: hal-00540114**

**<https://hal.science/hal-00540114>**

Submitted on 26 Nov 2010

**HAL** is a multi-disciplinary open access archive for the deposit and dissemination of scientific research documents, whether they are published or not. The documents may come from teaching and research institutions in France or abroad, or from public or private research centers.

L'archive ouverte pluridisciplinaire **HAL**, est destinée au dépôt et à la diffusion de documents scientifiques de niveau recherche, publiés ou non, émanant des établissements d'enseignement et de recherche français ou étrangers, des laboratoires publics ou privés.



**Rhabdomyosarcoma of the pectoral muscles in a free-living European robin (*Erithacus rubecula*)**

Journal:	<i>Avian Pathology</i>
Manuscript ID:	CAVP-2007-0190.R3
Manuscript Type:	Short Communication
Date Submitted by the Author:	18-Feb-2008
Complete List of Authors:	Manarolla, Giovanni; Università degli Studi di Milano, Dipartimento di Patologia Animale, Igiene e Sanità Pubblica Veterinaria Radaelli, Enrico; Università degli Studi di Milano, Dipartimento di Patologia Animale, Igiene e Sanità Pubblica Veterinaria Sironi, Giuseppe; Università degli Studi di Milano, Dipartimento di Patologia Animale, Igiene e Sanità Pubblica Veterinaria Pisoni, Giuliano; Università degli Studi di Milano, Dipartimento di Patologia Animale, Igiene e Sanità Pubblica Veterinaria Rampin, Tiziana; Università degli Studi di Milano, Dipartimento di Patologia Animale, Igiene e Sanità Pubblica Veterinaria
Keywords:	<i>Erithacus rubecula</i> , tumor, rhabdomyosarcoma, immunohistochemistry

SCHOLARONE™  
Manuscripts

Cavp-2007-0190.R3

Rhabdomyosarcoma of the pectoral muscles of a free-living European robin  
(*Erithacus rubecula*)

G. Manarolla<sup>1\*</sup>, E. Radaelli<sup>1</sup>, G. Pisoni<sup>2</sup>, G. Sironi<sup>1</sup>, T. Rampin<sup>1</sup>

*Dipartimento di Patologia Animale, Igiene e Sanità Pubblica Veterinaria – <sup>1</sup>Sezione di Anatomia Patologica Veterinaria e Patologia Aviare – <sup>2</sup>Sezione di Malattie Infettive  
Università degli Studi di Milano, via Celoria 10, 20133 Milano, Italy*

Short title: Rhabdomyosarcoma in a robin

\*To whom correspondence should be addressed. Tel: 0039 2 50318115. Fax: 0039 2 50318106. E-mail: giovanni.manarolla@unimi.it

**There are 2 sets of figures. Black and white versions are with R3. Colour versions are attached.**

**IT IS ESSENTIAL THAT FIGURE 3 IS PUBLISHED IN COLOUR. If AvP bears the cost, then figures 1 and 2 should appear in Black and white in printed copy, BUT in colour online.**

**If author has to pay for colour, then all images should be printed on one page IN colour.**

**I don't see the figure legends in the original files, but they are in the PDF version.**

Cavp-2007-0190.R3

Rhabdomyosarcoma of the pectoral muscles of a free-living European robin  
(*Erithacus rubecula*)

G. Manarolla<sup>1\*</sup>, E. Radaelli<sup>1</sup>, G. Pisoni<sup>2</sup>, G. Sironi<sup>1</sup>, T. Rampin<sup>1</sup>

**Abstract**

An adult free living European robin (*Erithacus rubecula*) with a large, firm, subcutaneous mass on the pectoral muscle was examined. The bird was unable to fly and died spontaneously. Necropsy revealed a yellowish, bilobate mass almost completely replacing the pectoral muscles with extensive osteolysis of the keel bone. Histopathology revealed a poorly demarcated, highly cellular sarcomatous tumour with metastases to the lungs, pulmonary blood vessels and heart. Immunohistochemistry was negative for neuron-specific enolase, S-100 protein and the p-27 major capsid protein of avian-leukosis viruses. The homogeneously positive immunolabeling for vimentin and scattered positivity for myoglobin and desmin suggested a diagnosis of rhabdomyosarcoma. A retrospective examination of the records for 194 birds of the thrush family including 64 robins submitted over a 20 year period, showed no diagnoses of neoplasia.

## Introduction

Primary tumours of the skeletal muscle are occasionally observed in avian species. Properly constructed surveys are needed to determine their incidence. Most cases are fibromas, fibrosarcomas, rhabdomyomas and rhabdomyosarcomas (RMS), that are reported in chickens usually as a consequence of infection with avian retroviruses (alpharetroviruses), avian leukosis virus (ALV) group (Riddel, 1996; Fadly & Payne, 2003). As for pet and free-living birds, rare reports of skeletal muscle tumours exist (Latimer, 1994; Friend & Thomas, 1999; Schimdt *et al.*, 2003). Generally, malignant muscle neoplasms are reported twice as frequently as their benign counterparts (Latimer, 1994). A site predilection for these tumours is not observed (Schimdt *et al.*, 2003). Grossly, RMS are often elevated, lobulated, relatively firm subcutaneous swellings. Microscopically, these neoplasms are composed of a pleomorphic population of fusiform to elongated cells (Latimer, 1994). The histopathologic diagnosis of RMS may be difficult; and confirmation of the diagnosis requires the use of electron microscopy or immunohistochemistry (IHC). Immunohistochemical characterization of these tumours requires a panel of antibodies. For this reason, antibodies against vimentin, desmin, actin, myoglobin, myosin and titin have proven to be useful in mammals (Cooper & Valentine, 2002) and in avian species as well (Frazier *et al.*, 1993; Duncan & Fitzgerald, 1997; Hafner *et al.*, 1998; Ijzer *et al.*, 2002).

We describe a primary RMS in the pectoral muscles of a free living European robin (*Erithacus rubecula*) with metastases to lungs and myocardium. We also examined the findings for birds of the thrush family submitted to our institute over the last 20 years to determine the incidence of neoplasia.

## Materials and Methods

**Case history** An adult free living European robin was presented to our laboratory in July 2007. The bird was found in a garden unable to fly and it was easily caught by hand. The clinical examination revealed a firm, non ulcerated, bilobate, subcutaneous mass that blended into and almost completely replaced the pectoral muscles. The birds died spontaneously a few hours after submission and was immediately necropsied.

Samples of the mass and of lung, testes, heart, liver, intestine, spleen, kidneys, and brain were fixed in 4% neutral buffered formalin, processed routinely, sectioned at 4 µm and sections were stained with haematoxylin and eosin. In addition, immunohistochemical stains were carried out on sections of the tumour. The primary antibodies, antigen retrieval methods, and incubation conditions used are described in Table 1. Biotinylated goat anti-mouse or goat anti-rabbit antibodies (as appropriate) were used as secondary antibodies, followed by the avidin/biotin complex (ABC) immunoperoxidase procedure (Hsu *et al.*, 1981). Diaminobenzidine (DAKO, Milan, ITALY) with 0.5% H<sub>2</sub>O<sub>2</sub> in imidazol buffer (pH 7.2, 0.1 M) was used as the chromogen. Replicate sections of neoplastic tissue were similarly immunostained using normal rabbit serum (p-27, S-100 protein, myoglobin) and normal mouse serum (NSE, vimentin, desmin, α-smooth muscle actin) instead of the primary antiserum, as negative controls. Unaffected pectoral muscle included in the sections was used as positive controls for myoglobin, vimentin, desmin, α-smooth muscle actin. Sections of mouse nervous system were used as positive controls for NSE and S-100. Section of multiple organs from a subgroup J avian leukosis virus J infected chicken was used as a positive control for p-27. Replicate sections of tumour were immunostained using normal rabbit and mouse serum for use as negative controls for the respective polyclonal and monoclonal antibodies. To determine the incidence of neoplasia, the caseload of our laboratory was

checked since 1987. The findings for 194 birds of the thrush family including 64 robins were examined.

## Results and Discussion

The bird was in poor body condition. The left pectoral muscle was completely effaced by a bulging, yellowish mass (2.5x2 cm) that invaded the keel bone and more than half of the right pectoral muscle. The wing joints were unaffected. The firm cut surfaces of the neoplastic lobules revealed necrotic centres surrounded by small, multifocal haemorrhages (Figure 1). The testes were inactive. Microscopically the tumour was densely cellular, unencapsulated and infiltrated the skeletal muscle. Large areas of necrosis and scattered haemorrhages were also detectable. The tumour was composed of streams and bundles of spindle cells (20-30  $\mu$ m in length) with small amount of fibrous stroma. Neoplastic cells exhibited indistinct cell borders, marked anisocytosis- anisokaryosis, a high nuclear to cytoplasmic ratio, moderate amount of eosinophilic cytoplasm, and plump oval to elongated, centrally located nuclei with coarsely clumped to vacuolated chromatin and one or two prominent magenta nucleoli. A few multinucleated giant cells with up to seven nuclei were also observed. Mitosis were 6-7 per high-power field (40x) and were frequently bizarrely configured. Small metastases of the aforementioned neoplastic cells were observed in the lungs, in pulmonary blood vessels (Figure 2) and in the myocardium. It is conceivable that the bird died from the metastases possibly causing cardiac arrhythmia and circulatory changes. Additionally, several small granulomatous lesions centred on remnants of helminth parasites were detected in liver and intestine. Immunolabeling for vimentin was homogeneous and intense (Figure 3). About 30% of neoplastic cells were immunopositive for myoglobin (Figure 3), 15% of neoplastic cells

were immunopositive for desmin, while immunostaining for  $\alpha$ -sm actin was intense for perivascular and interstitial cells but less intense and rare in neoplastic cells. Staining for p-27, NSE, S-100 was absent in the tumour cells but strongly positive in all control tissues.

Histologically, this tumour showed undifferentiated sarcomatous characteristics which can be shared by tumours such as including leiomyosarcoma, RMSs, fibrosarcomas or even schwannomas. In similar cases immunohistochemistry is routinely used to discriminate among the possible diagnoses (Cooper & Valentine, 2002). It is important to use a panel of antibodies for immunohistochemical characterization of these tumours because the antigens are variably expressed depending upon the degree of differentiation of the neoplastic cells. Moreover, care is required in interpreting the results of this immunohistochemistry as staining, even though specific, may be focal (Cooper & Valentine, 2002). Lack of immunostaining for S-100 and NSE suggested a non-neural differentiation of this tumour, but homogeneous and intense vimentin positivity suggested the mesenchymal origin. Although scattered, the positive immunostaining for the myogenic components myoglobin and desmin led to the diagnosis of RMS. These results may be interpreted as a sign of poor differentiation. Vimentin is expressed early in rhabdomyocytes differentiation but is later lost. Desmin is also expressed early but persists; myoglobin is expressed later than desmin. Therefore poorly differentiated RMS may express desmin but lack myoglobin (Cooper & Valentine, 2002). Our results partially agrees with previous reports of avian RMS. Fernandez-Bellon *et al.* (2003) found positive and homogeneous immunostaining for vimentin and myoglobin in a RMS of a racing pigeon but neoplastic cells were negative for desmin. In contrast, Gulbahar *et al.* (2005) reported intense immunolabeling for both vimentin and desmin but immunostaining for myoglobin was not performed. As for  $\alpha$ -sm actin, rare positive immunostaining is not surprising in RMS as indicated previously (Cooper & Valentine, 2002; Gulbahar *et al.* (2005). Finally, negative immunostaining for p-27 excluded the involvement of ALV infection which



in chickens, and rarely in other birds, may be associated with the onset of similar tumours (Fadly & Payne, 2003).

Free ranging wild birds are commonly afflicted with numerous parasites which occasionally cause illness and death (Cole & Friend, 1999). The parasitic granuloma observed in the sections of liver and intestine of the robin, although numerous, were considered as incidental findings. The granulomatous reaction and fixation artefacts prevented identification of the parasites remnants by histopathological examination.

In conclusion, a case of RMS in a robin is described. Primary tumours of skeletal muscle are infrequent avian species (Reece, 2003; Schmidt *et al.*, 2003) particularly in free living birds. Over a 20-year period, we have examined 194 birds belonging to the thrush family including 64 European robins, and this was the only tumour found. Curiously, the bird was an adult, male robin found on the outskirts of Milan in summertime. In Northern Italy robins are used to spending the breeding season in mountain forests up to an altitude of 2,000 meters whereas they are common in the plains and in urban areas during fall and winter (Bottoni & Massa, 1992). It is therefore possible to speculate that the tumour prevented the bird from reaching the breeding areas at the proper time as it led to a progressive inability to fly.

## References

- Bottoni , L. & Massa, R. (1992). Pettiroso (*Erithacus rubecula*). In L. Fornasari, Bottoni, L., Massa, R., Fasola, M., Brichetti, P., & V. Vigorita. (1992). *Atlante degli uccelli svernanti in Lombardia* (pp.232-233). Milano: Regione Lombardia – Università degli Studi di Milano.
- Cole, R.A. & Friend, M. (1999). Miscellaneous parasitic diseases. In M. Friend, & J.C. Franson. (1999). *Field Manual of Wildlife Diseases - General Field Procedures and Diseases of Birds* (p.249). Washington, D.C.:U.S. Department of The Interior Fish and Wildlife Service *Resource Publication 167*.
- Cooper, B.J. & Valentine, B.A. (2002). Tumors of muscle. In D.J. Meuten. (2002). *Tumors in Domestic Animals* 4th edn (pp.319-363). Ames: Iowa State Press.
- Duncan, A.E. & Fitzgerald, S.D. (1997). Clinical challenge: multiple primary rhabdomyosarcomas within the myocardium of a vulture. *Journal of Zoo and Wildlife Medicine*, 28, 501-503.
- Fadly, A.M & Payne, L.N. Neoplastic Diseases. In Y.M. Saif, H.J. Barnes, J.R. Glisson, A.M. Fadly, L.R. McDougald, & D.E. Swayne. (2003). *Diseases of Poultry* 11th edn (pp.405-407). Ames: Iowa State Press.
- Fernandez-Bellon, H., Martorell, J., Rabanal, R. & Ramis, A. (2003) Rhabdomyosarcoma in a racing pigeon (*Columba livia*). *Avian Pathology*, 32, 613-616.
- Frazier, K.S., Herron, A.J., Hines, M.E., Miller, C.L., Hensley, G.T. & Altman, N.H. (1993). Metastasis of a myxoid leiomyosarcoma via the renal and hepatic portal circulation in a sarus crane (*Grus antigone* ). *Journal of Comparative Pathology*, 108, 57-63.
- Friend, M. & Thomas, N.J. (1999). Miscellaneous Diseases. In M. Friend, & J.C. Franson. *Field Manual of Wildlife Diseases - General Field Procedures and Diseases of Birds on*

- line edn (pp.261-267). Washington, D.C.:U.S. Department of The Interior Fish and Wildlife Service *Resource Publication 167*.
- Gulbahar, M.Y. Ozak, A., Guvenç, T., Yarim, M. (2005). Retrobulbar rhabdomyosarcoma in a budgerigar (*Melopsittacus undulatus*) *Avian Pathology*, 34, 486-488.
- Hafner, S., Goodwin, M.A., Smith, E.J., Fadly, A. & Kelley, L.C.(1998). Pulmonary sarcomas in a young chicken. *Avian Diseases*, 42, 824-828.
- Hsu, S.M., Raine, L. & Fanger, H. (1981). Use of avidin-biotin-peroxidase complex (ABC) in immunoperoxidase techniques: a comparison between ABC and unlabeled antibody (PAP) procedures. *The journal of histochemistry and cytochemistry*, 29, 577-580.
- Ijzer, J., Dorrestein, G.M. & van der Hage, M.H. (2002). Metastatic subcutaneous sarcoma and abdominal carcinoma in a peach-faced lovebird (*Agapornis roseicolis*). *Avian Pathology*, 31, 101-104.
- Latimer, K.S. (1994). Oncology. In B.W. Ritchie, G.J. Harrison, & L.R. Harrison. (1994). *Avian Medicine: Principles and Application* (pp.647-648). Lake Worth, FL: Wingers Publishing, Inc.
- Reece, R.L. (2003). Neoplastic Diseases. In Y.M. Saif, H.J. Barnes, J.R. Glisson, A.M. Fadly, L.R. McDougald, & D.E. Swayne. (2003). *Diseases of Poultry* 11th edn (pp.541-564). Ames: Iowa State Press.
- Riddel, C. Muscular System. (1996) In C. Riddell. (1996). *Avian Histopathology* 2nd edn (p.66). Saskatchewan, Canada: American Association of Avian Pathologists.
- Schmidt, R.E., Reavill, D.R. & Phalen, D.N. Musculoskeletal system. (2003). In R.E. Schmidt, D.R. Reavill, & D.N. Phalen. (2003). *Pathology of Pet and Aviary Birds* (p.153). Ames: Iowa State Press.

**Table 1** Primary antibodies, antigen retrieval methods and dilutions used for immunohistochemistry

ANTIBODY	HOST SPECIES	SOURCE	ANTIGEN RETRIEVAL	DILUTION
Vimentin (clone 3B4)	mouse	DAKO <sup>a</sup>	Sodium citrate (pH 6) water bath sub-boiling 30 min	1:1000
$\alpha$ -smooth muscle actin (clone 1A4)	mouse	DAKO <sup>a</sup>	-	1:2000
Desmin	mouse	Novocastra <sup>b</sup>	Sodium citrate (pH 6) microwave, 75% power, 5 min twice	1:200
Myoglobin	rabbit	DAKO <sup>a</sup>	-	1:10
S-100 protein	rabbit	DAKO <sup>a</sup>	Sodium citrate (pH 6) microwave, 75% power, 5 min twice	1:20000
Neuron-specific enolase (NSE)	rabbit	DAKO <sup>a</sup>	-	1:25
p-27 major capsid protein of Avian Leukosis Viruses (ALV)	rabbit	SPAFAS <sup>c</sup>	-	1:8000

<sup>a</sup> Dako Italia S.p.A., Milan (ITALY) <sup>b</sup> Novocastra Laboratories Ltd, Newcastle upon Tyne •(United Kingdom)

<sup>c</sup> Spafas® Inc., Preston, CT, (USA)

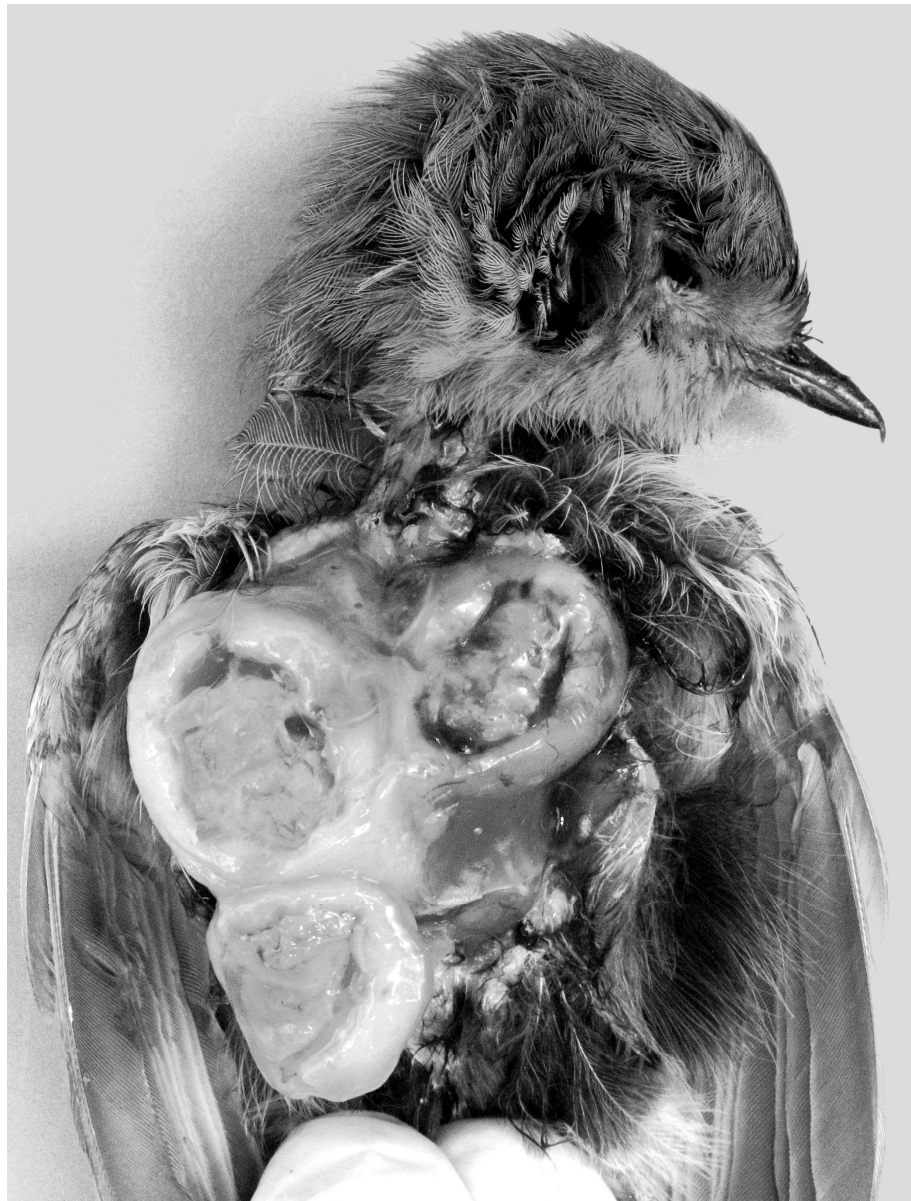


Figure 1. Bulging, yellowish mass almost completely effacing the pectoral muscles of a robin. The cut surfaces reveal necrotic centres surrounded by multifocal haemorrhages.  
104x137mm (600 x 600 DPI)

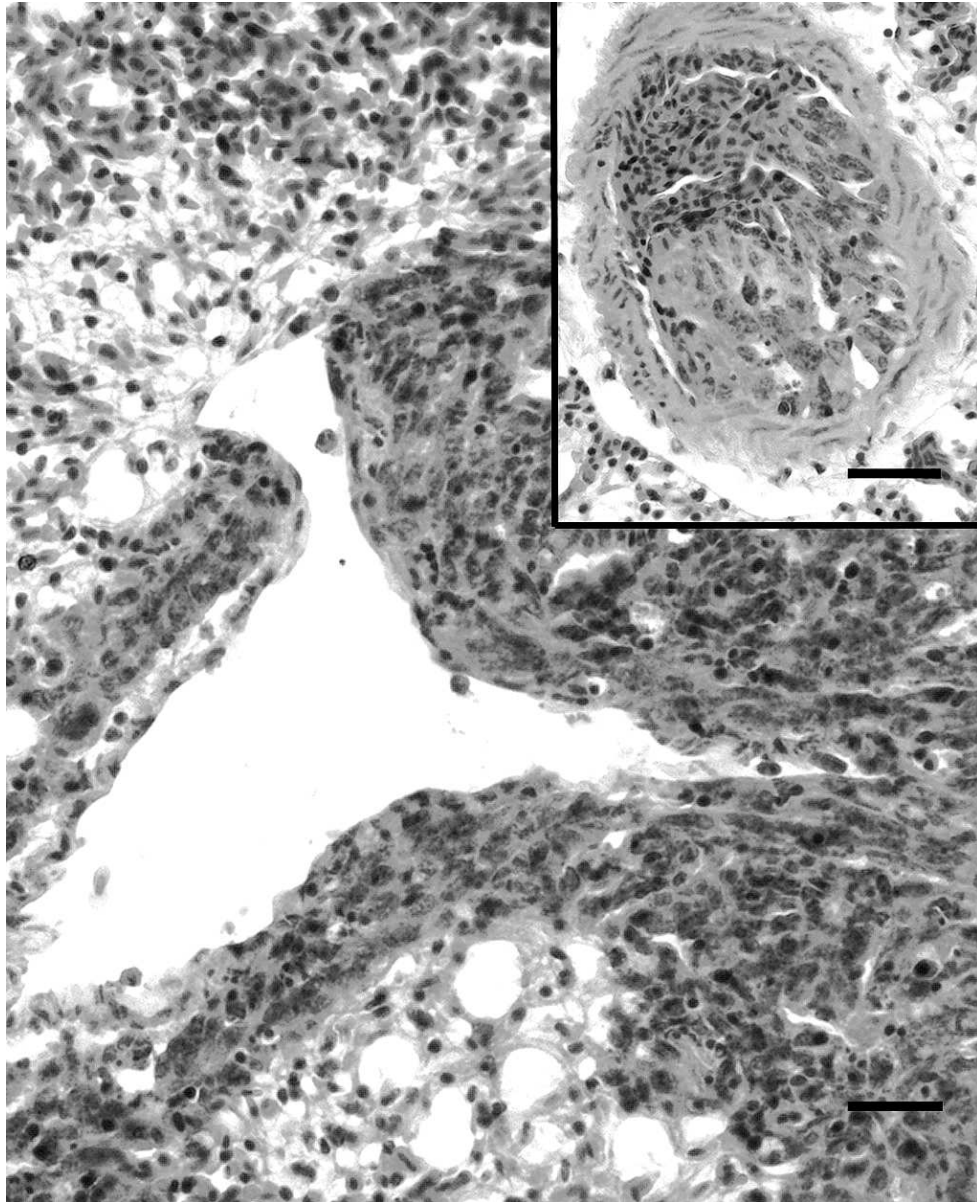


Figure 2. Micrograph showing metastases of the tumour in the lung parenchyma. Haematoxylin-eosin. Bar = 20  $\mu$ m. Inset: neoplastic embolus in a pulmonary blood vessel. Haematoxylin-eosin. Bar = 35  $\mu$ m.

79x98mm (324 x 324 DPI)



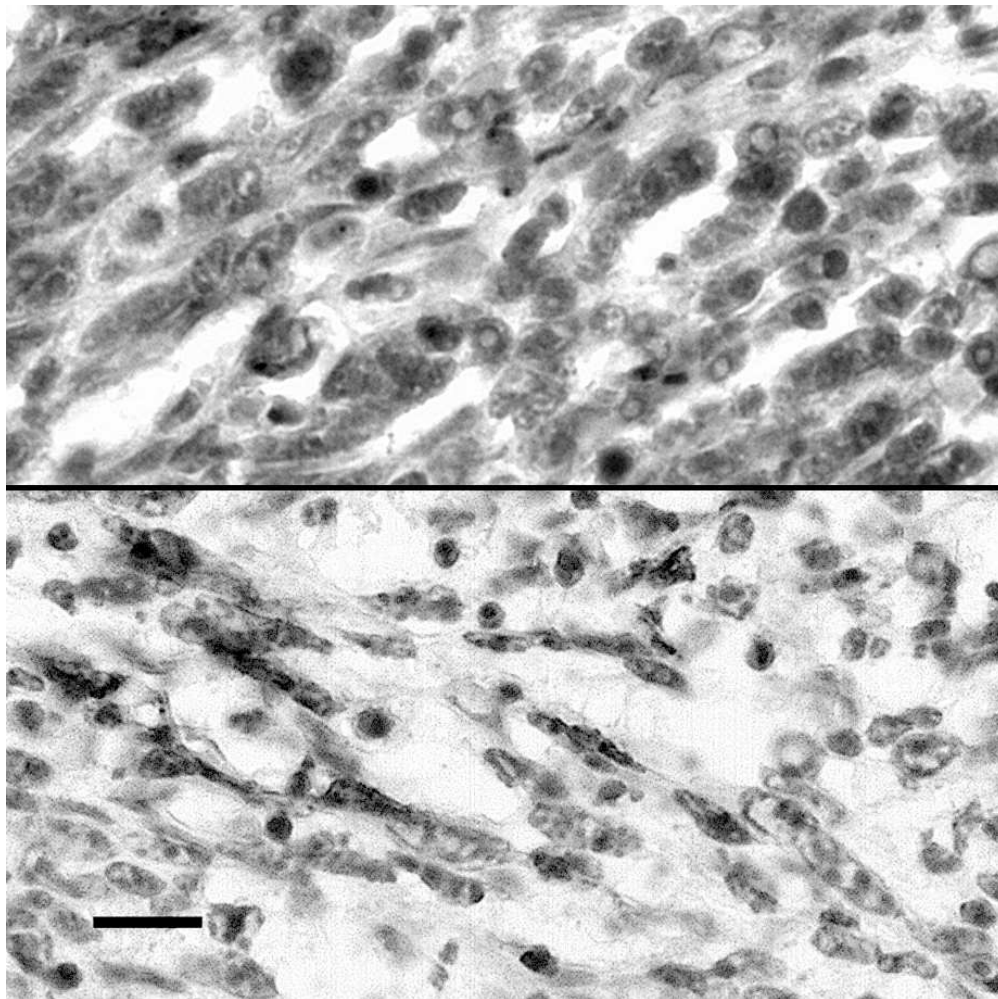


Figure 3. Upper half: vimentin immunolabeling in the majority of the neoplastic cells. Lower half: myoglobin immunoreactivity in scattered neoplastic cells. ABC method, Mayer's haematoxylin counterstain. Bar = 10  $\mu$ m. 79x79mm (293 x 293 DPI)

