



HAL
open science

Foot pad dermatitis in growing turkeys is associated with cytokine and cellular changes indicative of an inflammatory immune response

Paul Hocking, Rod Else

► **To cite this version:**

Paul Hocking, Rod Else. Foot pad dermatitis in growing turkeys is associated with cytokine and cellular changes indicative of an inflammatory immune response. *Avian Pathology*, 2007, 36 (06), pp.453-459. 10.1080/03079450701639327 . hal-00540099

HAL Id: hal-00540099

<https://hal.science/hal-00540099>

Submitted on 26 Nov 2010

HAL is a multi-disciplinary open access archive for the deposit and dissemination of scientific research documents, whether they are published or not. The documents may come from teaching and research institutions in France or abroad, or from public or private research centers.

L'archive ouverte pluridisciplinaire **HAL**, est destinée au dépôt et à la diffusion de documents scientifiques de niveau recherche, publiés ou non, émanant des établissements d'enseignement et de recherche français ou étrangers, des laboratoires publics ou privés.



Foot pad dermatitis in growing turkeys is associated with cytokine and cellular changes indicative of an inflammatory immune response

Journal:	<i>Avian Pathology</i>
Manuscript ID:	CAVP-2007-0043.R1
Manuscript Type:	Original Research Paper
Date Submitted by the Author:	11-Jul-2007
Complete List of Authors:	Hocking, Paul; Roslin Institute, Genetics and Genomics Else, Rod; R(D)SVS, Veterinary Pathology
Keywords:	foot pad dermatitis, cytokines, inflammation, allergy

SCHOLARONE™
Manuscripts

Cavp-2007-0043.R1

Foot pad dermatitis in growing turkeys is associated with cytokine and cellular changes indicative of an inflammatory immune response

R. K. Mayne^{1,3}, F. Powell², R. W. Else¹, P. Kaiser² and P. M. Hocking^{3*}

¹Department of Veterinary Pathology, University of Edinburgh, Easter Bush Veterinary

Centre, Midlothian, Scotland, ²Institute for Animal Health, Compton, Berkshire RG20 7NN,

³Roslin Institute, Division of Genetics and Genomics, Midlothian, EH25 9PS, Scotland

Short title: Inflammatory responses in foot pad dermatitis

- To whom correspondence should be addressed. Tel: +44(0)131-527-4462. Fax: +44(0)131-440-0434. Email: paul.hocking@bbsrc.ac.uk

Received: 20 March 2007

Cavp-2007-0043.R1

Foot pad dermatitis in growing turkeys is associated with cytokine and cellular changes indicative of an inflammatory immune response

R. K. Mayne^{1,3}, F. Powell², R. W. Else¹, P. Kaiser² and P. M. Hocking^{3*}

Abstract

Cell and cytokine responses during the development of foot pad dermatitis (FPD) in growing turkeys were studied in a model system. The objective was to evaluate the hypothesis that FPD is an allergic response to the environmental materials. Hybrid female turkeys at 28 days of age were exposed to wet litter for 48 hours in a randomised block experiment. Expression levels of pro-inflammatory (IL-1 β , IL-6, and CXCLi2) and signature Th1 (IFN- γ), Th2 (IL-13) and Treg (IL-10) cytokines were measured in the foot pad tissues using real-time quantitative RT-PCR. Sections of foot pad tissue were stained for CD4⁺ and CD8⁺ T lymphocytes, B lymphocytes and macrophages using antibodies which specifically recognise the relevant cell types in the turkey. In the footpads of birds suffering from FPD, there were large fold increases in mRNA expression levels for the pro-inflammatory cytokines IL-1 β (+ 635), IL-6 (+ 65), and CXCLi2 (+ 1924), and IFN- γ (+ 32) whereas there was only a small increase in IL-13 mRNA (+ 2) and no change in IL-10 mRNA expression levels. CD4⁺ and CD8⁺ T lymphocytes were present in the footpads of more than 90 % of birds housed on wet litter compared with 25 % or less on dry litter. Macrophages were observed in the footpads of approximately 85 % of birds housed on wet litter compared with none in birds housed on

dry litter. B lymphocytes were not detected in tissue from any of the birds. The data suggest that FPD is associated with a rapidly occurring inflammatory response, rather than a Th2-mediated allergic reaction.

For Peer Review Only

Introduction

Foot pad dermatitis (FPD) is very common in flocks of growing turkeys and is a potential welfare and economic problem in intensive production systems. FPD develops rapidly in commercial flocks where fully developed lesions occur by 3 weeks of age and from 6 weeks lesions simply increase in size (Mayne *et al.*, 2006; Mayne *et al.*, 2007a). FPD is associated with redness, swelling and tissue necrosis and may also be accompanied by pain (Martland, 1984, 1985; Mayne, 2005; Mayne *et al.*, 2007b). Histopathologically, FPD is associated with massive increases in heterophils and macrophages and the loss of surface keratin (Mayne *et al.*, 2006)

We have developed a simple model for inducing FPD in turkeys that consists of exposing 6 birds at 28 days of age to clean wet wood shavings in large floor pens for 6 to 8 days (Mayne *et al.*, 2007b). We have also shown that the presence of excreta is not necessary for the development of FDP and that wet litter alone causes similarly severe lesions as wet dirty litter (Mayne *et al.*, 2007b). The rate of progression and extent of lesions are variable both within and between different experiments but external signs of FPD are evident as soon as 24 hours after initial exposure. Similar responses to those on wood shavings litter were obtained with paper and cardboard litters, and FPD was worse in birds housed on long barley straw, suggesting that any putative causal factor is not specific to wood shavings (Mayne *et al.*, 2007b). What is not clear is whether FPD in this model represents an inflammatory immune response or an allergic reaction to an environmental stimulus.

Inflammatory responses are driven by pro-inflammatory cytokines and chemokines (typically IL-1 β , IL-6 and IL-8) produced mainly by macrophages. The cytokines cause

dilation of local small blood vessels and changes in the endothelial cells lining their walls. This leads to the extravasation of leukocytes, initially heterophils and monocytes, but followed by T and B lymphocytes, into the inflamed tissue, guided by the chemokines produced by the activated macrophages. Plasma proteins and fluids also leak into the tissues as the blood vessels become more permeable. In mammals, dermatitis is typically caused by an inflammatory response, although allergic dermatitis is caused by a Th2 cytokine-driven immunological reaction following previous exposure (sensitisation) to an allergen.

Cytokines and chemokines are soluble chemical messengers that regulate all aspects of immune responses. Measurement of the change in levels of specific cytokines can be indicative of the level of inflammation and potential tissue damage. CD4⁺ T lymphocytes are helper cells (Th) that, through the production of specific cytokine subsets, drive either inflammatory, cell-mediated immune responses (Th1, for which the signature cytokine is IFN- γ) or humoral (allergic) immune responses (Th2, for which the signature cytokines are IL-4 and IL-13) or act as regulatory cells (Treg, for which the signature cytokines are IL-10 and TGF- β 1).

We recently characterised the chicken genome's full complement of cytokines and chemokines (Kaiser *et al.*, 2005). The chicken genome encodes orthologues of mammalian IL-1 β , IL-6, IFN- γ , IL-4, IL-13, IL-10 and TGF- β 1 (called TGF- β 4 in the chicken). However, it has a different repertoire of pro-inflammatory chemokines, for which we proposed a simple nomenclature until their biological functions and ligand-receptor relationships are better characterised. For example, in human IL-8 is a single copy gene. By contrast, the chicken genome contains two genes, CXCLi1 (K60: Sick *et al.*, 2000) and CXCLi2 ((IL-8/CAF: Martins-Green and Feugate 1998; Kaiser *et al.*, 1999), both of which

have high identity with human IL-8 and share similar biological properties. We have also cloned many of these cytokines and chemokines, and developed reagents to them, to measure their expression in the turkey (Lawson *et al.*, 2001/ F. Powell, M. Clarkson and P. Kaiser, unpublished results).

The hypothesis tested in this experiment was that the reaction to wet litter in FPD was caused by an allergy rather than an inflammatory response. Cellular and cytokine responses were evaluated in foot pad tissue from turkeys that were housed on wet or dry wood shavings litter for 48 h. Immunohistochemistry of turkey foot pad sections was carried out to identify CD4⁺ and CD8⁺ T lymphocytes, macrophages and B lymphocytes and the expression of pro-inflammatory (IL-1 β , IL-6, and CXCLi2), signature Th1 (IFN- γ), Th2 (IL-13) and Treg (IL-10) cytokines was measured using real-time quantitative RT-PCR.

Materials and Methods

Birds and husbandry. 72 newly-hatched female T8 Large White Broad Breasted turkeys (British United Turkeys, Chester, UK) were obtained from a commercial hatchery. The birds were housed in a single large pen for 7 days and then distributed equally to 12 pens measuring 2m by 3m. The pens were littered with clean white wood shavings that had been polythene wrapped by the suppliers but had not been sterilised. Excreta were removed from all pens daily to maintain clean litter. Each pen contained a hanging bell drinker, a feeder and a suspended heat lamp. The air temperature was maintained at 28 °C by controlled ventilation and heating. The daily photoperiod was 14 hours of light with 10 hours of darkness and light

intensity was 20 lux throughout the experiment.

Experimental treatments. Starting at 28 days, approximately 10 l of tap water was added to the litter of 6 pens to achieve a litter score of at least 4 on the Tucker and Walker (1999) scale. After 24 hours a further 5 l were applied to the wet pens and excreta and soiled litter were removed. The remaining 6 pens were kept dry (score 1) and clean by removing excreta and soiled litter.

Observations. At 48 hours post-treatment all turkeys were assessed for FPD and assigned an external foot pad score on a 7-point scale (Mayne *et al.*, 2007b). Three birds, two for the experiments and one as a back-up, were randomly selected from each pen and killed with an overdose of sodium pentobarbitone and the remaining birds were used for another experiment (Mayne *et al.*, 2007b). The dissecting table, instruments and gloves were cleaned with RNazap (Ambion, Cambridgeshire, UK) and these procedures was repeated between bird dissections. The skin of the foot pad was removed and cut into 2 pieces. One small piece (approximately 5 mm x 5 mm) was placed on a round cork tile (20 mm x 3 mm), covered in OTC (BDH Laboratory Supplies, Dorset, UK), snap-frozen in liquid nitrogen and placed in a zip-lock bag in liquid nitrogen until it could be stored in a -80 °C freezer. The second part of the skin of the foot pad was stored in RNAlater (Ambion, Cambridgeshire, UK) in a sterile 15 ml centrifuge tube and kept on ice until being transferred to a refrigerator at 4°C.

Preparation of tissue sections. Sections, 6 µm thick, were cut from the frozen tissue and cork blocks in a Leica CM 1900 cryostat (Leica Microsystems, Wetzlar, Germany) and

mounted on slides. After fixation in ice-cold acetone for 10 min, they were air-dried and then stored at -80 °C until used.

Immunohistochemistry. Processed sections were circled with a hydrophobic pen and allowed to dry for 2 min. Foot pad sections were rehydrated with 200 µl of PBS pipetted onto each sample and left for 5 min. Processed sections were stained using a Vectastain ABC α-mouse IgG HPR staining kit (Vector Laboratories, Burlingham, CA, USA), following the manufacturer's instructions. Staining for the different cells used the following murine anti-chicken antibodies, previously demonstrated to cross-react with the equivalent turkey cells (Lawson et al., 2001): CD4⁺ (AV29; 1:5 dilution), CD8⁺ (11-39, 1:5), macrophage (KuL01,1:500) and B lymphocytes (AV10, 1:5). NovaRed (200 µl) was pipetted onto each sample and left for 30 s to 3 min depending on the colour intensity required (Vector NovaRED substrate kit SK-4800, Vector Laboratories, Burlingham, CA, USA). Slides were allowed to dry overnight before mounting with a cover slip using Surgipath Clearium Mounting Medium (Surgipath, Illinois, USA). Slides stained for specific cell types, and foot pad sections stained with haematoxylin and eosin, were examined under a light microscope and samples with positive staining were recorded.

RNA extraction and real-time quantitative RT-PCR. Approximately 30 mg foot pad tissue was homogenised in 600 µl lysis buffer (RLT, Qiagen, Crawley, UK) using a bead mill (Retsch MM300, Retsch UK Ltd, Leeds, UK). Complete disruption of tissue was ensured by using a QIAshredder (Qiagen, Crawley, UK) following the manufacturer's instructions. Total RNA was prepared from the homogenised tissues using an RNeasy mini kit (Qiagen,

Crawley, UK), again following the manufacturer's instructions. Purified RNA was eluted in 50 μ l RNase-free water and stored at -70 °C.

Cytokine and chemokine mRNA levels in foot pad tissues were quantified using previously described method (Kaiser *et al.*, 2000; Kaiser *et al.*, 2003; Kogut *et al.*, 2003a; Kogut *et al.*, 2003b; Peters *et al.*, 2003; Sijben *et al.*, 2003). Turkey IFN- γ had been cloned previously (Lawson *et al.*, 2001). The remaining turkey cytokine and chemokine cDNAs (except IL-6) were cloned and sequenced (F. Powell and P. Kaiser, unpublished). For IL-1 β , IL-6 and the housekeeping gene 28S the previously described chicken primer-probe sets could be used. For others (CXCLi2, IL-10 and IL-13) turkey-specific primer-probe sets were developed.

Primers and probes were designed using the Primer Express software program (Applied Biosystems, Foster City, CA) and details are given in Table 1. For all cytokines and chemokines, either a primer or probe was designed, from the sequence of the relevant genes, to lie across intron:exon boundaries. All probes were labelled with the fluorescent reporter dye 5-carboxyfluorescein (FAM) at the 5' end and the quencher N, N, N, N'-tetramethyl-6-carboxyrhodamine (TAMRA) at the 3' end.

Real-time quantitative RT-PCR was performed using the Reverse Transcriptase qPCR Master Mix RT-PCR kit (Eurogentec, Seraing, Belgium). Amplification and detection of specific products were performed using the ABI PRISM 7700 Sequence Detection System (Applied Biosystems) with the following cycle profile: one cycle of 50 °C for 2 minutes, 60 °C for 30 minutes, and 95 °C for 5 minutes, and 40 cycles of 94 °C for 20 seconds, 59 °C for 1 minute. Quantification was based on the increased fluorescence detected due to hydrolysis of the target-specific probes by the 5'-exonuclease activity of the *rTth* DNA polymerase during PCR amplification. The passive reference dye 6-carboxy-c-rhodamine, which is not

involved in amplification, was used for normalization of the reporter signal. Results are expressed in terms of the threshold cycle value (Ct), the cycle at which the change in the reporter dye passes a significance threshold (ΔR_n).

To account for variation in sampling and RNA preparation, the Ct values for cytokine- or chemokines-specific product for each sample were standardised using the Ct value of 28S rRNA product for the same sample. To normalise RNA levels between samples within an experiment, the mean Ct value for 28S rRNA-specific product was calculated by pooling values from all samples in that experiment. Tube to tube variations in 28S rRNA Ct values about the experimental mean were calculated. The slope of the 28S rRNA \log_{10} dilution series regression line was used to calculate differences in input total RNA. Using the slopes of the respective cytokine, chemokine or 28S rRNA \log_{10} dilution series regression lines, the difference in input total RNA, as represented by the 28S rRNA, was then used to adjust cytokine- and chemokine-specific Ct values, as follows: Corrected Ct value = Ct + (Nt-Ct')* S/S' where Ct = mean sample Ct, Nt = experimental 28S mean, Ct'= mean 28S of sample, S = cytokine or chemokine slope, S'= 28S slope. Results were expressed as 40-Ct values and each sample was assayed in triplicate.

Statistical analysis. The experiment was a randomised block design with 2 blocks of 6 pens and 2 treatments (wet and dry litter). External foot pad scores were analysed with a one-way ANOVA of pen means (n=3). Cellular responses were compared by maximum likelihood χ^2 of the number of birds with or without positive staining in the two treatments (n=12). Results for qRT-PCR were analysed using a split plot ANOVA of pen means (n=2).

Results

Mean external scores of FPD of turkeys after 48 hours on wet and dry litter respectively were 6.2 and 1.2 on a 7-point scale (Mayne *et al.*, 2007b), illustrating the extent of inflammation that can be caused in a comparatively short period of time by housing birds on wet litter. Furthermore all the birds on the wet litter treatment were strongly affected: the range of external foot pad scores was 5 to 7 compared with 0 to 3 on the dry treatment.

Cell staining. Typical sections stained for macrophages, CD4⁺ and CD8⁺ T lymphocytes and B lymphocytes respectively for birds on wet and dry litter with different external footpad scores are presented in Figures 1 to 4. Positively stained cells are dark red-brown. Artefacts of processing, likely to be contaminants, were present in most sections and appeared as large black particles, greater in size and darker in colour than positively stained cells. Artefacts of processing also had an uneven edge, whilst cells were more regularly shaped. The pale brown background stain on all sections was non-specific.

Positive staining for macrophages (Figure 1) was seen in 85 % of birds (10 of 12) housed on wet litter within the uppermost layer of the epidermis just below the keratin layer (surface keratin had been lost), whereas there was no staining for macrophages in birds housed on dry litter ($\chi^2 = 21.8$, $P < 0.001$). CD4⁺ T lymphocytes (Figure 2) were evident throughout the upper and lower dermis of all birds housed on wet litter compared with only 15 % (2 of 12) housed on dry litter ($\chi^2 = 15.5$, $P < 0.001$). Positive staining for CD8⁺ T lymphocytes (Figure 3) was present in over 90 % of birds (11 of 12) housed on wet litter

compared with 25 % of birds (3 of 12) housed on dry litter ($\chi^2 = 13.7$, $P < 0.001$). No staining for B lymphocytes was observed in any of the sections (Figure 4).

qRT-PCR. Means, standard errors and fold changes of corrected $40-C_t$ values for each cytokine and chemokines are presented in Table 2. There was a significant difference ($P < 0.05$) between the mRNA expression levels of the majority of cytokines and chemokines measured in the foot pad tissues of birds housed on wet and dry litter after 48 hours, the only exception being the Treg cytokine IL-10, for which there was no significant difference in mRNA expression levels. For the pro-inflammatory cytokines, mRNA expression levels were upregulated dramatically in foot pad tissues from birds housed on wet litter, as opposed to those housed on dry litter, from 65-fold for IL-6 to 1924-fold for CXCLi2. IFN- γ mRNA expression levels were also greatly increased (32-fold). IL-13 mRNA expression levels, although significantly different, were only increased 2-fold.

Discussion

Our primary objective was to determine whether the inflammation associated with FPD in turkeys was due to an allergic reaction to an allergen in the litter, or a classical inflammatory response. To this end, we measured cytokine mRNA expression levels, and used immunohistochemistry to identify subsets of immune cells, in the footpad tissues in a previously validated model for inducing FPD in turkeys (Mayne *et al.*, 2007b).

In previous experiments a marked inflammatory response was observed by 48 hours

after exposure to wet litter and we chose this time point to ensure that a severe immune repose was observed and also to avoid any secondary reparative changes. Footpad tissue sections stained for specific immune cell subsets showed that birds housed on wet litter had increased levels of macrophages and CD4⁺ and CD8⁺ T lymphocytes, but no detectable B cells. Also, mRNA expression levels for the pro-inflammatory cytokines IL-1 β , IL-6 and CXCLi2 were all highly upregulated in these tissues, with CXCLi2 increasing by more than 1900-fold. Pro-inflammatory reactions commonly lead to a Th1, IFN- γ -mediated response that results in an influx of CD8⁺ cytotoxic T cells whereas only 25 % of birds housed on dry litter showed positive staining for CD8⁺ T lymphocytes. This was not unexpected, however, as naïve T lymphocytes only respond in substantial numbers to an inflammatory reaction 4-5 days post initial inflammation. For the Th signature cytokines, both IFN- γ and IL-13 mRNA expression levels were upregulated, the former by more than 30-fold, whereas IL-13 only increased 2-fold, a difference that would not normally be considered of biological significance.

In contrast to our results for macrophage staining, Igyarto et al (2006) reported that 50 % of epidermal dendritic cells were positive for the KuL01 antibody in featherless skin of 8-week-old chickens. We failed to detect macrophage cells in the footpad of birds on the dry treatment and the differences between the two data sets may be a consequence of different housing, age, tissue or species and warrant further research.

The results are consistent with the conclusion that FPD in these turkeys was a non-specific inflammatory reaction. Although an allergic reaction, perhaps to a water-soluble antigen in the litter released when the litter was wet, could have occurred, it is unlikely that this would have happened in 48 h unless the turkeys had been previously exposed to the

allergen causing the reaction. Damp patches are inevitably present in normal dry litter and it is likely that the skin of the foot pads of these turkeys was exposed to water soluble allergens in the period before the experiment. If sensitisation to these allergens had occurred, exposure to the experimental treatment should induce a secondary allergic response in 48 hours which we did not observe: the cytokines that would be indicative of an allergic response (IL-10 and IL-13) were not recorded at high levels.

In conclusion, these data suggest that there was a rapidly occurring inflammatory response in the foot pads of birds housed on wet litter for 48 hours and that an allergic response was unlikely. Further research is required to clarify the mode of action of litter moisture in the aetiology of turkey FPD.

Acknowledgements

We are grateful to the farm staff at the Roslin Institute for daily care of the birds and Lisa Rothwell for technical help. The Turkey Sector Group of the British Poultry Council funded this research through PhD studentships for RKM and FP. Roslin Institute and the Institute for Animal Health are supported by the BBSRC.

References

- Igyarto, B. Z., Lacko, E., Olah, I. & Magyar, A. (2006). Characterization of chicken epidermal dendritic cells. *Immunology*, *119*, 278-288.
- Kaiser, P., Hughes, S. & Bumstead, N. (1999). The chicken 9E3/CEF4 CXC chemokine is the avian orthologue of IL8 and maps to chicken Chromosome 4 syntenic with genes flanking the mammalian chemokine cluster. *Immunogenetics*, *49*, 673-684.
- Kaiser, P., Poh, T. Y., Rothwell, L., Avery, S., Balu, S., Pathania, U. S., Hughes, S., Goodchild, M., Morrell, S., Watson, M., Bumstead, N., Kaufman, J. & Young, J. R. (2005). A genomic analysis of chicken cytokines and chemokines. *Journal of Interferon and Cytokine Research*, *25*, 467-484.
- Kaiser, P., Rothwell, L., Galyov, E. E., Barrow, P. A., Burnside, J. & Wigley, P. (2000). Differential cytokine expression in avian cells in response to invasion by *Salmonella typhimurium*, *Salmonella enteritidis* and *Salmonella gallinarum*. *Microbiology*, *146*, 3217-3226.
- Kaiser, P., Underwood, G. & Davison, T. F. (2003). Differential cytokine responses following Marek's disease virus infection of chickens differing in resistance to Marek's disease. *Journal of Virology*, *77*, 762-768.
- Kogut, M. H., Rothwell, L. & Kaiser, P. (2003a). Differential regulation of cytokine gene expression by avian heterophils during receptor-mediated phagocytosis of opsonized and non-opsonized *Salmonella enteritidis*. *Journal of Interferon and Cytokine Research*, *23*, 319-327.
- Kogut, M. H., Rothwell, L. & Kaiser, P. (2003b). Priming by recombinant chicken interleukin-2 induces selective expression of IL-8 and IL-18 mRNA in chicken

- heterophils during receptor-mediated phagocytosis of opsonized and nonopsonized *Salmonella enterica* serovar enteritidis. *Molecular Immunology*, *40*, 603-610.
- Lawson, S., Rothwell, L., Lambrecht, B., Howes, K., Venugpal, K. & Kaiser, P. (2001). Turkey and chicken interferon-gamma, which share high sequence identity, are biologically cross-reactive. *Developmental and Comparative Immunology*, *25*, 69-82.
- Martins-Green, M. & Feugate, J. E. (1998). The 9E3/CEF4 gene product is a chemotactic and angiogenic factor that can initiate the wound-healing cascade *in vivo*. *Cytokine*, *10*, 522-535.
- Martland, M. F. (1984). Wet litter as a cause of plantar pododermatitis leading to foot ulceration and lameness in fattening turkeys. *Avian Pathology*, *13*, 241-252.
- Martland, M. F. (1985). Ulcerative dermatitis in broiler chickens: the effects of wet litter. *Avian Pathology*, *14*, 353-364.
- Mayne, R. K. (2005). A review of the aetiology and possible causative factors of foot pad dermatitis in growing turkeys and broilers. *Worlds Poultry Science Journal*, *61*, 256-267.
- Mayne, R. K., Else, R. W. & Hocking, P. M. (2007a). High dietary concentrations of biotin did not prevent foot pad dermatitis in growing turkeys and external scores were poor indicators of histopathological lesions. *British Poultry Science*, *48*, (in press).
- Mayne, R. K., Else, R. W. & Hocking, P. M. (2007b). High litter moisture alone is sufficient to cause foot pad dermatitis in growing turkeys *British Poultry Science*, *48*, (in press).
- Mayne, R. K., Hocking, P. M. & Else, R. W. (2006). Foot pad dermatitis develops at an early age in commercial turkeys. *British Poultry Science*, *47*, 36-42.

- Peters, M. A., Browning, G. F., Washington, E. A., Crabb, B. S. & Kaiser, P. (2003). Embryonic age influences the capacity for cytokine production in chicken thymocytes. *Immunology Reviews*, *110*, 358-367.
- Sick, C., Schneider, K., Staeheli, P. & Weining, K. C. (2000). Novel chicken CXC and CC chemokines. *Cytokine*, *12*, 181-186.
- Sijben, J. W. C., Klasing, K. C., Schrama, J. W., Parmentier, H. K., Van Der Poel, J. J., Savelkoul, H. F. & Kaiser, P. (2003). Early in vivo cytokine genes expression in chickens after challenge with *Salmonella typhimurium* lipopolysaccharide and modulation by dietary n-3 polyunsaturated fatty acids. *Developmental and Comparative Immunology*, *27*, 611-619.
- Tucker, S. & Walker, A. (1999). Hock Burn in Broilers. In *Recent developments in poultry nutrition*, vol. 2 (ed. J. Wiseman and P. C. Garnsworthy), pp. 107-122. Nottingham University Press, Nottingham.

Figure legends

Figure 1 Presence of macrophages in footpad tissue sections from turkeys housed on (a) dry or (b, c) wet litter for 48 h. Original magnification $\times 10$ (a, b) or $\times 20$ (c). External footpad scores were 0 (a) and 7 (b, c). Key: A = keratin, B = lost surface keratin, C = epidermis, D = dermis and E = positively stained cells in epidermis and dermis; Bar -100 μm (a, b) or 50 μm (c).

Figure 2. Presence of CD4⁺ T lymphocytes in footpad tissue sections from turkeys housed on (a) dry or (b, c) wet litter for 48 h. Original magnification $\times 10$ (a, b) or $\times 20$ (c). External footpad scores were 0 (a) and 7 (b, c). Key: A = keratin, B = lost surface keratin, C = epidermis, D = dermis and E = positively stained cells in epidermis and dermis; bar is 100 μm (a, b) or 50 μm (c).

Figure 3. Presence of CD8⁺ T lymphocytes in footpad tissue sections from turkeys housed on (a) dry or (b, c) wet litter for 48 h. Original magnification $\times 10$ (a, b) or $\times 20$ (c). External footpad scores were 3 (a) and 6 (b, c). Key: A = keratin, B = lost surface keratin, C = epidermis, D = dermis and E = positively stained cells in epidermis and dermis; bar is 100 μm (a, b) or 50 μm (c).

Figure 4. Absence of B lymphocytes in footpad tissue sections from turkeys housed on (a) dry or (b) wet litter for 48 h. Original magnification $\times 10$. External footpad scores were 0 (a) and 7 (b). Key: A = keratin, B = lost surface keratin, C = epidermis and D = dermis; bar is

100μm (a, b).

For Peer Review Only

Table 1. Real-time quantitative RT-PCR probes and primers.

RNA target	Probe/primer sequence	Specific for	Accession No.	Exon boundaries ^c
28S	Probe 5'-(FAM)-AGGACCGCTACGGACCTCCACCA-(TAMRA)-3'	Chicken		
	F ^a 5'-GGCGAAGCCAGAGGAAACT-3'	and	X59733	-
IL-1 β	R ^b 5'-GACGACCGATTTGCACGTC-3'	turkey		
	Probe 5'-(FAM)-CCACACTGCAGCTGGAGGAAGCC-(TAMRA)-3'	Chicken		
IL-6	F 5'-GCTCTACATGTCGTGTGTGATGAG-3'	and	AJ245728	5/6
	R 5'-TGTCGATGTCCCGCATGA-3'	turkey		
CXCLi2	Probe 5'-(FAM)-AGGAGAAATGCCTGACGAAGCTCTCCA-(TAMRA)-3'	Chicken		
	F 5'-GCTCGCCGGCTTCGA-3'	and	AJ250838	3/4
IFN- γ	R 5'-GGTAGGTCTGAAAGGCGAACAG-3'	turkey		
	Probe 5'-(FAM)-CAGCTCTGTCACAAGGTAGGACCCTGGT-(TAMRA)-3'			
IL-13	F 5'-TGGCTCTCCTCCTGGTTTCA-3'	Turkey	AM493430	1/2
	R 5'-GCAGCTCGTTCCCATCTT-3'			
IL-10	Probe 5'-(FAM)-AAAGATATCATGGACCTGGCCAAGCTTCA-(TAMRA)-3'			
	F 5'-AACCTTCCTGATGGCGTGAA-3'	Turkey	AJ000725	3/4
IL-13	R 5'-CTTGCCTGGATTCTCAAGTC-3'			
	Probe 5'-(FAM)-TGCCAGCTGAGCACCGACAACG-(TAMRA)-3'			
IL-10	F 5'-CCTGCACGGCCAGATGA-3'	Turkey	AM493431	3/4
	R 5'-GGCAAGAAGTCCCGCAGGTA-3'			
IL-10	Probe 5'-(FAM)-CCTGAAGATGACAATGAAGCGCTGTCA-(TAMRA)-3'			
	F 5'-CGACCTGGGCAACATGCT-3'	Turkey	AM493432	3/4
	R 5'-CCTCTCGCAGGTGAAGAAGTG-3'			

^aForward primer.

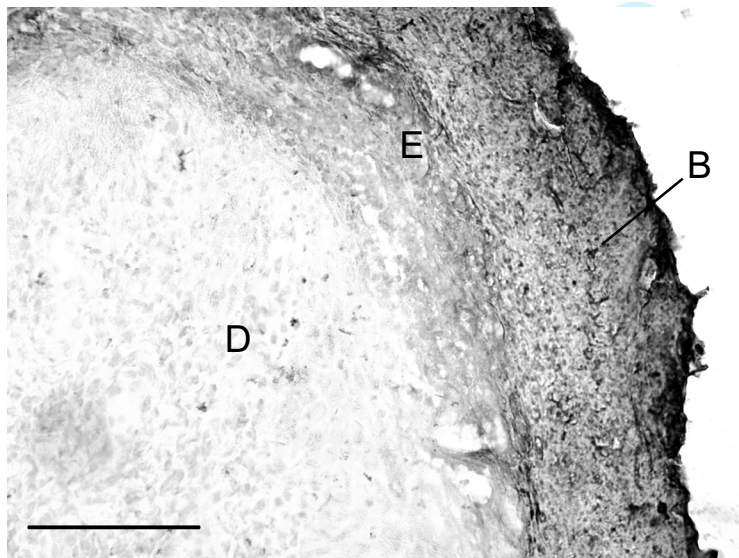
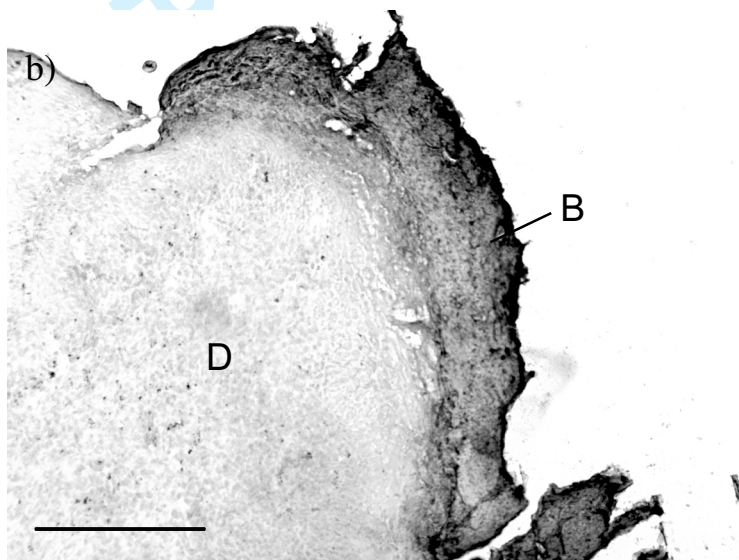
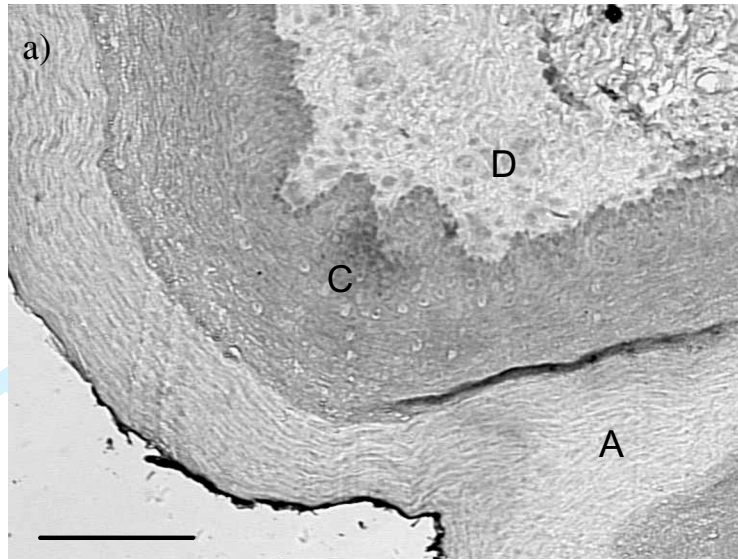
^bReverse primer.


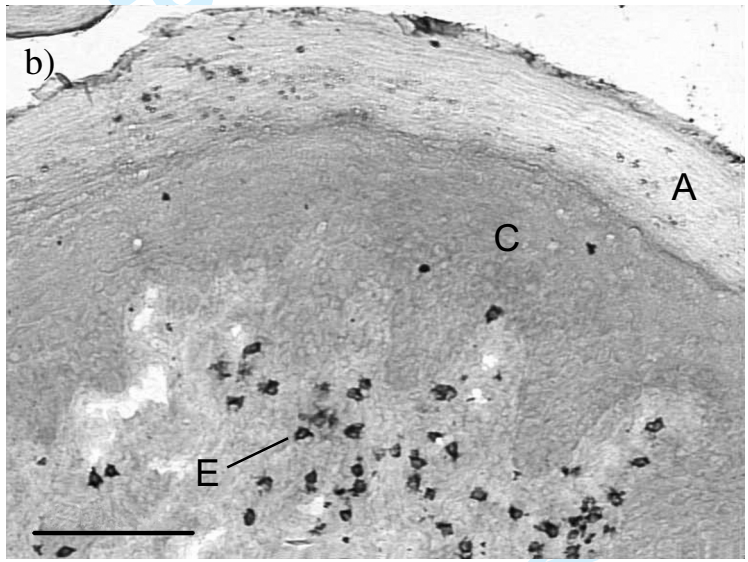
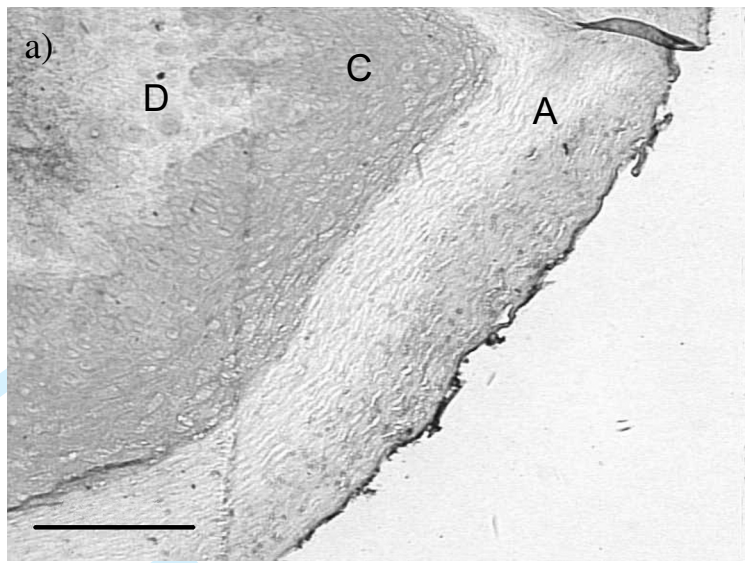
^cExon boundaries in the chicken gene (gene structures have not yet been determined for the turkey genes).

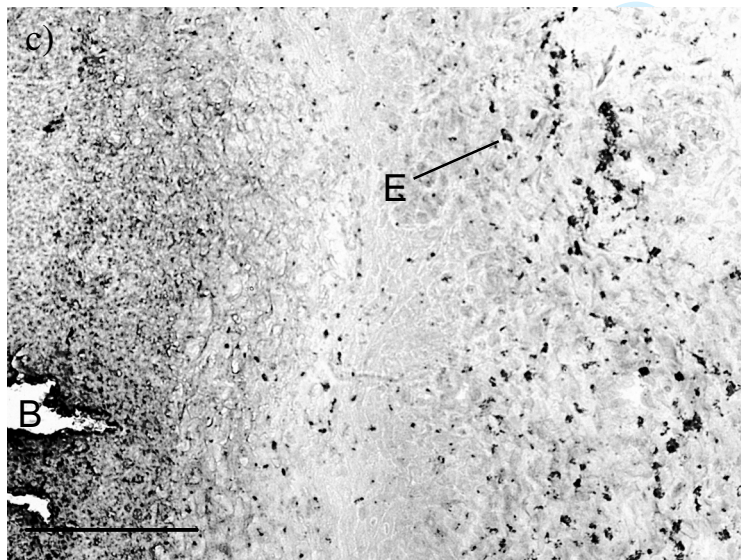
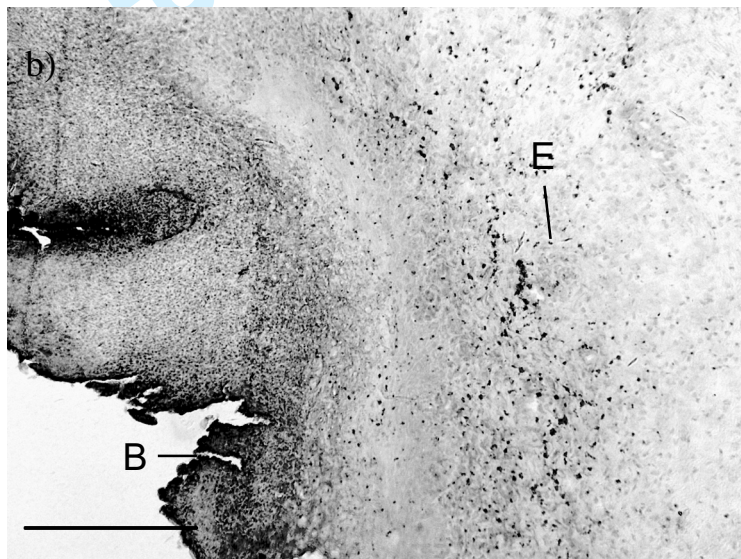
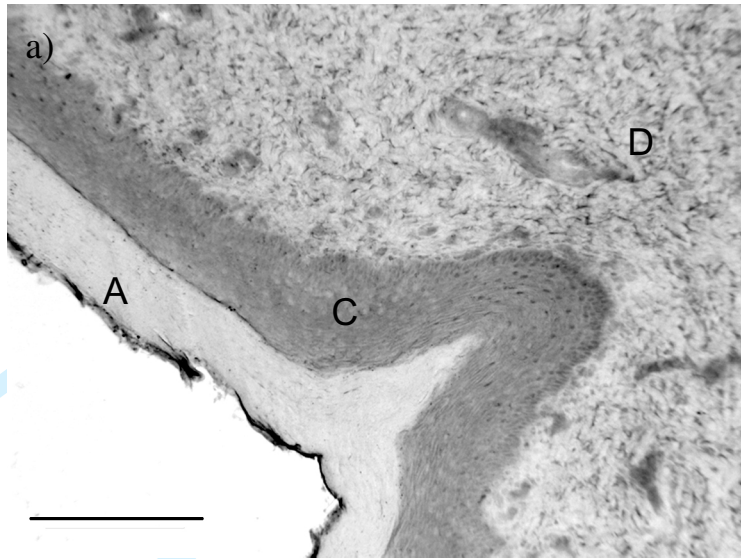
Table 2. Corrected cytokine 40-C_t values for foot pad tissue of turkeys raised on dry litter and exposed to dry or wet litter for 48 h at 28 d of age.

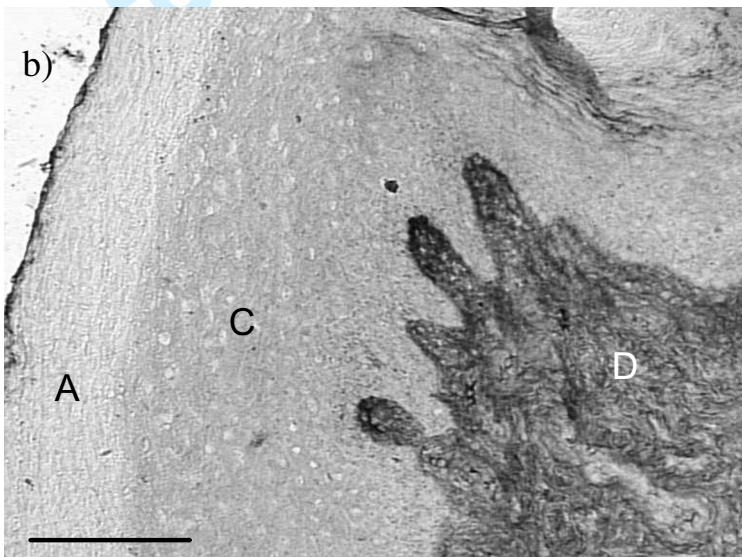
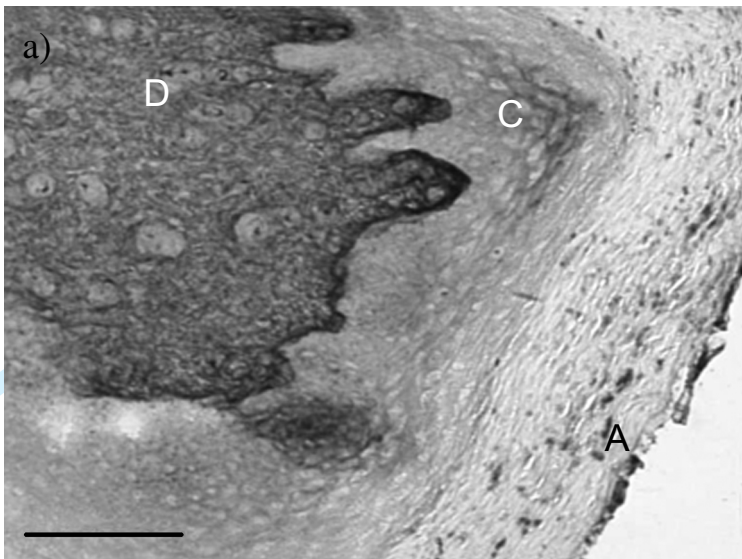
Cytokine/chemokine	Corrected 40-C _t value		SED	P	Fold change ^a	
	Dry litter	Wet litter				
IL-1β	3.66	12.97	0.854	<0.001	+635	
Pro-inflammatory	IL-6	7.50	10.51	1.057	0.019	+65
	CXCLi2	10.10	21.01	1.014	<0.001	+1924
Th1	IFN-γ	1.44	6.45	0.563	<0.001	+32
Th2	IL-13	7.43	8.52	0.262	0.002	+2
Treg	IL-10	4.02	2.51	0.780	0.086	-

^aCalculated as $2^{(\text{wet litter 40-Ct value} - \text{dry litter 40-Ct value})}$









1 **Foot pad dermatitis in growing turkeys is associated with cytokine and**
2 **cellular changes indicative of an inflammatory immune response**

3

4 **R. K. Mayne^{1,3}, F. Powell², R. W. Else¹, P. Kaiser² and P. M. Hocking^{3*}**

5

6

7 *¹Department of Veterinary Pathology, University of Edinburgh, Easter Bush Veterinary*
8 *Centre, Midlothian, Scotland, ²Institute for Animal Health, Compton, Berkshire RG20 7NN*
9 *and ³Roslin Institute, Division of Genetics and Genomics, Midlothian, EH25 9PS, Scotland*

10

11

12 Short title: Inflammatory responses in foot pad dermatitis

13

14

15

16

17

18

19

20

21 * To whom correspondence should be addressed. Tel: +44(0)131-527-4462. Fax: +44(0)131-

22 440-0434. Email: paul.hocking@bbsrc.ac.uk

23 **Abstract**

24 Cell and cytokine responses during the development of foot pad dermatitis (FPD) in growing
25 turkeys were studied in a model system. The objective was to evaluate the hypothesis that
26 FPD is an allergic response to material in the environment. Hybrid female turkeys at 28 d of
27 age were exposed to wet litter for 48 h in a randomised block experiment. Expression levels
28 of pro-inflammatory (IL-1 β , IL-6, and CXCLi2) and signature Th1 (IFN- γ), Th2 (IL-13) and
29 Treg (IL-10) cytokines were measured in the foot pad tissues using real-time quantitative
30 RT-PCR. Sections of foot pad tissue were stained for CD4⁺ and CD8⁺ T lymphocytes, B
31 lymphocytes and macrophages using antibodies which specifically recognise the relevant cell
32 types in the turkey. In the footpads of birds suffering from FPD, there were large fold
33 increases in mRNA expression levels for the pro-inflammatory cytokines IL-1 β (+ 635), IL-6
34 (+ 65), and CXCLi2 (+ 1924), and IFN- γ (+ 32) whereas there was only a small increase in
35 IL-13 mRNA (+ 2) and no change in IL-10 mRNA expression levels. CD4⁺ and CD8⁺ T
36 lymphocytes were present in the footpads of more than 90 % of birds housed on wet litter
37 compared with 25 % or less on dry litter. Macrophages were observed in the footpads of
38 approximately 85 % of birds housed on wet litter compared with none in birds housed on dry
39 litter. B lymphocytes were not detected in tissue from any of the birds. The data suggest that
40 FPD is associated with a rapidly occurring inflammatory response, rather than a Th2-
41 mediated allergic reaction.

Deleted: at 28 d of age

Deleted: large

Deleted: ;

Deleted: expression levels

Formatted: Superscript

42 **Introduction**

43

44 Foot pad dermatitis (FPD) is very common in flocks of growing turkeys and is a potential
 45 welfare and economic problem in intensive production systems. FPD develops rapidly in
 46 commercial flocks where fully developed lesions occur by 3 weeks of age and from 6 weeks
 47 lesions simply increase in size (Mayne *et al.*, 2006; Mayne *et al.*, 2007a). FPD is associated
 48 with redness, swelling and tissue necrosis and may also be accompanied by pain (Martland,
 49 1984, 1985; Mayne, 2005; Mayne *et al.*, 2007b). Histopathologically FPD is associated with
 50 a massive increase in heterophils and macrophages and the loss of surface keratin (Mayne *et*
 51 al., 2006).

Deleted: in growing turkeys

Deleted: and

Field Code Changed

Field Code Changed

Field Code Changed

Deleted: FPD develops rapidly and fully developed lesions occur by 3 weeks of age and from 6 weeks lesions simply increase in size (Mayne *et al.*, 2007a; Mayne *et al.*, 2007b). FPD is very common in flocks of growing turkeys and is a potential welfare and economic problem in intensive production systems.

Field Code Changed

Field Code Changed

52 We have developed a simple model for inducing FPD in turkeys that consists of
 53 exposing 6 birds at 28 d of age to clean wet wood shavings in large floor pens for 6 to 8 d
 54 (Mayne *et al.*, 2007b). We have also shown that the presence of excreta is not necessary for
 55 the development of FDP and that wet litter alone causes similarly severe lesions as wet dirty
 56 litter (Mayne *et al.*, 2007b). The rate of progression and extent of lesions are variable both
 57 within and between different experiments but external signs of FPD are evident as soon as 24
 58 h after initial exposure. Similar responses to those on wood shavings litter were obtained
 59 with paper and cardboard litters, and FPD was worse in birds housed on long barley straw,
 60 suggesting that any putative causal factor is not specific to wood shavings (Mayne *et al.*,
 61 2007b). What is not clear is whether FPD in this model represents an inflammatory immune
 62 response or an allergic reaction to an environmental stimulus.

Deleted: .

63 Inflammatory responses are driven by pro-inflammatory cytokines and chemokines
 64 (typically IL-1 β , IL-6 and IL-8) produced mainly by macrophages. The cytokines cause

65 dilation of local small blood vessels and changes in the endothelial cells lining their walls.
 66 This leads to the extravasation of leukocytes, initially heterophils and monocytes but
 67 followed by T and B lymphocytes, into the inflamed tissue, guided by the chemokines
 68 produced by the activated macrophages. Plasma proteins and fluids also leak into the tissues
 69 as the blood vessels become more permeable. In mammals, dermatitis is typically caused by
 70 an inflammatory response, although allergic dermatitis is caused by a Th2 cytokine-driven
 71 immunological reaction following previous exposure (sensitisation) to an allergen.

Deleted: neutrophils

72 Cytokines and chemokines are soluble chemical messengers that regulate all aspects
 73 of immune responses. Measurement of the change in levels of specific cytokines can be
 74 indicative of the level of inflammation and potential tissue damage. CD4⁺ T lymphocytes are
 75 helper cells (Th) that, through the production of specific cytokine subsets, drive either
 76 inflammatory, cell-mediated immune responses (Th1, for which the signature cytokine is
 77 IFN- γ) or humoral (allergic) immune responses (Th2, for which the signature cytokines are
 78 IL-4 and IL-13) or act as regulatory cells (Treg, for which the signature cytokines are IL-10
 79 and TGF- β 1).

Deleted: titres

80 We recently characterised the chicken genome's full complement of cytokines and
 81 chemokines (Kaiser *et al.*, 2005). The chicken genome encodes orthologues of mammalian
 82 IL-1 β , IL-6, IFN- γ , IL-4, IL-13, IL-10 and TGF- β 1 (called TGF- β 4 in the chicken).
 83 However, it has a different repertoire of pro-inflammatory chemokines, for which we
 84 proposed a simple nomenclature until their biological functions and ligand-receptor
 85 relationships are better characterised. For example, in human IL-8 is a single copy gene. By
 86 contrast, the chicken genome contains two genes, CXCLi1 (K60; Sick *et al.*, 2000) and
 87 CXCLi2 (IL-8/CAF; Martins-Green and Feugate 1998; Kaiser *et al.*, 1999), both of which

Field Code Changed

Field Code Changed

Field Code Changed

Formatted: Font: Italic

Deleted: (IL-8/CAF: Martins-Green and Feugate 1998; Kaiser *et al.*, 1999)

88 have high identity with human IL-8 and share similar biological properties. We have also
89 cloned many of these cytokines and chemokines, and developed reagents to them, to measure
90 their expression in the turkey (Lawson *et al.*, 2001/ F. Powell, M. Clarkson and P. Kaiser,
91 unpublished results).

Field Code Changed

Formatted: Font: Italic

Deleted: (Lawson *et al.*, 2001 F. Powell, M. Clarkson and P. Kaiser, unpublished results)

92 The hypothesis tested in this experiment was that the reaction to wet litter in FPD was
93 caused by an allergy rather than an inflammatory response. Cellular and cytokine responses
94 were evaluated in foot pad tissue from turkeys that were housed on wet or dry wood shavings
95 litter for 48 h. Immunohistochemistry of turkey foot pad sections was carried out to identify
96 CD4⁺ and CD8⁺ T lymphocytes, macrophages and B lymphocytes and the expression of pro-
97 inflammatory (IL-1 β , IL-6, and CXCLi2), signature Th1 (IFN- γ), Th2 (IL-13) and Treg (IL-
98 10) cytokines was measured using real-time quantitative RT-PCR.

Deleted: simple immune

100 **Materials and Methods**

101
102 **Birds and husbandry.** 72 newly-hatched female T8 Large White Broad Breasted turkeys
103 (British United Turkeys, Chester, UK) were obtained from a commercial hatchery. The birds
104 were housed in a single large pen for 7 d and then equally distributed to 12 pens measuring 2
105 m by 3 m. The pens were littered with clean white wood shavings that had been polythene
106 wrapped by the suppliers but had not been sterilised. Excreta were removed from all pens
107 daily to maintain clean litter. Each pen contained a hanging bell drinker, a feeder and a
108 suspended heat lamp. The air temperature was maintained at 28 °C by controlled ventilation
109 and heating. The daily photoperiod was 14 h of light with 10 h of darkness and light intensity
110 was 20 lux throughout the experiment.

111

112 **Experimental treatments.** Starting at 28 d, approximately 10 l of tap water was added to the

113 litter of 6 pens to achieve a litter score of at least 4 on the Tucker and Walker (1999) scale.

114 After 24 h a further 5 l were applied to the wet pens and excreta and soiled litter were

115 removed. The remaining 6 pens were kept dry (score 1) and clean by removing excreta and

116 soiled litter.

117

118 **Observations.** At 48 h post-treatment all turkeys were assessed for FPD and assigned an

119 external foot pad score on a 7-point scale (Mayne *et al.*, 2007b). Three birds, two for the

120 experiments and one as a back-up, were randomly selected from each pen and killed with an

121 overdose of sodium pentobarbitone and the remaining birds were used for another

122 experiment (Mayne *et al.*, 2007b). The dissecting table, instruments and gloves were cleaned

123 with RNAzap (Ambion, Cambridgeshire, UK) and these procedures were repeated between

124 bird dissections. The skin of the foot pad was removed and cut into 2 pieces. One small piece

125 (approximately 5 mm x 5 mm) was placed on a round cork tile (20 mm x 3 mm), covered in

126 OTC (BDH Laboratory Supplies, Dorset, UK), snap-frozen in liquid nitrogen and placed in a

127 zip-lock bag in liquid nitrogen until it could be stored in a -80 °C freezer. The second part of

128 the skin of the foot pad was stored in RNAlater (Ambion, Cambridgeshire, UK) in a sterile

129 15 ml centrifuge tube and kept on ice until being transferred to a refrigerator at 4 °C.

130

131 **Preparation of tissue sections.** Sections, 6 µm thick, were cut from the frozen tissue and

132 cork blocks in a Leica CM 1900 cryostat (Leica Microsystems, Wetzlar, Germany) and

133 mounted on slides. After fixation in ice-cold acetone for 10 min, they were air-dried and then

Field Code Changed

Deleted: [, 1999 #1248]

Deleted: any

Deleted: was

Deleted: s

Field Code Changed

Deleted: was

Field Code Changed

Deleted: this

Deleted: b

Deleted:

134 stored at -80 °C until used.

135

136 **Immunohistochemistry.** Processed sections were circled with a hydrophobic pen and
137 allowed to dry for 2 min. Foot pad sections were rehydrated with 200 µl of PBS pipetted onto
138 each sample and left for 5 min. Processed sections were stained using a Vectastain ABC α-
139 mouse IgG HPR staining kit (Vector Laboratories, Burlingham, CA, USA), following the
140 manufacturer's instructions. Staining for the different cells used the following murine anti-
141 chicken antibodies, previously demonstrated to cross-react with the equivalent turkey cells
142 (Lawson et al., 2001): CD4+ (AV29; 1:5 dilution), CD8+ (11-39, 1:5), macrophage
143 (KuL01,1:500) and B lymphocytes (AV10, 1:5). NovaRed (200 µl) was pipetted onto each
144 sample and left for 30 s to 3 min depending on the colour intensity required (Vector
145 NovaRED substrate kit SK-4800, Vector Laboratories, Burlingham, CA, USA). Slides were
146 allowed to dry overnight before mounting with a cover slip using Surgipath Clearium
147 Mounting Medium (Surgipath, Illinois, USA). Slides stained for specific cell types, and foot
148 pad sections stained with haematoxylin and eosin, were examined under a light microscope
149 and samples with positive staining were recorded.

Field Code Changed

150

151 **RNA extraction and real-time quantitative RT-PCR.** Approximately 30 mg foot pad
152 tissue was homogenised in 600 µl lysis buffer (RLT, Qiagen, Crawley, UK) using a bead mill
153 (Retsch MM300, Retsch UK Ltd, Leeds, UK). Complete disruption of tissue was ensured by
154 using a QIAshredder (Qiagen, Crawley, UK) following the manufacturer's instructions. Total
155 RNA was prepared from the homogenised tissues using an RNeasy mini kit (Qiagen,
156 Crawley, UK), again following the manufacturer's instructions. Purified RNA was eluted in

157 50 µl RNase-free water and stored at -70 °C.

158 Cytokine and chemokine mRNA levels in foot pad tissues were quantified using a
159 previously described method (Kaiser *et al.*, 2000; Kaiser *et al.*, 2003; Kogut *et al.*, 2003a; Kogut
160 *et al.*, 2003b; Peters *et al.*, 2003; Sijben *et al.*, 2003). Turkey IFN- γ had been cloned previously
161 (Lawson *et al.*, 2001). The remaining turkey cytokine and chemokine cDNAs (except IL-6)
162 were cloned and sequenced (F. Powell and P. Kaiser, unpublished). For IL-1 β , IL-6 and the
163 housekeeping gene 28S the previously described chicken primer-probe sets could be used.
164 For others (CXCLi2, IL-10 and IL-13) turkey-specific primer-probe sets were developed.

Field Code Changed

Field Code Changed

165 Primers and probes were designed using the Primer Express software program
166 (Applied Biosystems, Foster City, CA) and details are given in Table 1. For all cytokines and
167 chemokines, either a primer or probe was designed, from the sequence of the relevant genes,
168 to lie across intron:exon boundaries. All probes were labelled with the fluorescent reporter
169 dye 5-carboxyfluorescein (FAM) at the 5' end and the quencher N, N, N, N'-tetramethyl-6-
170 carboxyrhodamine (TAMRA) at the 3' end.

171 Real-time quantitative RT-PCR was performed using the Reverse Transcriptase
172 qPCR Master Mix RT-PCR kit (Eurogentec, Seraing, Belgium). Amplification and detection
173 of specific products were performed using the ABI PRISM 7700 Sequence Detection System
174 (Applied Biosystems) with the following cycle profile: one cycle of 50 °C for 2 min, 60 °C
175 for 30 min, and 95 °C for 5 min, and 40 cycles of 94 °C for 20 sec, 59 °C for 1 min.
176 Quantification was based on the increased fluorescence detected due to hydrolysis of the
177 target-specific probes by the 5'-exonuclease activity of the *rTth* DNA polymerase during
178 PCR amplification. The passive reference dye 6-carboxy-c-rhodamine, which is not involved
179 in amplification, was used for normalization of the reporter signal. Results are expressed in

180 terms of the threshold cycle value (Ct), the cycle at which the change in the reporter dye
181 passes a significance threshold (ΔR_n).

182 To account for variation in sampling and RNA preparation, the Ct values for
183 cytokine- or chemokines-specific product for each sample were standardised using the Ct
184 value of 28S rRNA product for the same sample. To normalise RNA levels between samples
185 within an experiment, the mean Ct value for 28S rRNA-specific product was calculated by
186 pooling values from all samples in that experiment. Tube to tube variations in 28S rRNA Ct
187 values about the experimental mean were calculated. The slope of the 28S rRNA \log_{10}
188 dilution series regression line was used to calculate differences in input total RNA. Using the
189 slopes of the respective cytokine, chemokine or 28S rRNA \log_{10} dilution series regression
190 lines, the difference in input total RNA, as represented by the 28S rRNA, was then used to
191 adjust cytokine- and chemokine-specific Ct values, as follows: Corrected Ct value = Ct +
192 $(Nt - Ct') * S/S'$ where Ct = mean sample Ct, Nt = experimental 28S mean, Ct' = mean 28S of
193 sample, S = cytokine or chemokine slope, S' = 28S slope. Results were expressed as 40-Ct
194 values and each sample was assayed in triplicate.

195

196 **Statistical analysis.** The experiment was a randomised block design with 2 blocks of 6 pens
197 and 2 treatments (wet and dry litter). External foot pad scores were analysed with a one-way
198 ANOVA of pen means (n=3). Cellular responses were compared by maximum likelihood χ^2
199 of the number of birds with or without positive staining in the two treatments (n=12). Results
200 for qRT-PCR were analysed using a split plot ANOVA of pen means (n=2).

Deleted: treatments

Deleted: .

201

202 **Results**

203 [Mean external scores of FPD of turkeys after 48 h on wet and dry litter respectively were 6.2](#)
 204 [and 1.2 on a 7-point scale \(Mayne *et al.*, 2007b\), illustrating the extent of inflammation that](#)
 205 [can be caused in a comparatively short period of time by housing birds on wet litter.](#)
 206 [Furthermore all the birds on the wet litter treatment were strongly affected: the range of](#)
 207 [external foot pad scores was 5 to 7 compared with 0 to 3 on the dry treatment.](#)

Field Code Changed

Deleted: X

Deleted: Y

208

209 **Cell staining.** [Typical](#) sections stained for macrophages, CD4⁺ and CD8⁺ T lymphocytes and
 210 B lymphocytes respectively [for birds on wet and dry litter with different external footpad](#)
 211 [scores](#) are presented in Figures 1 to 4. Positively stained cells are dark red-brown. Artefacts
 212 of processing, likely to be contaminants, were present in most sections and appeared as large
 213 black particles, greater in size and darker in colour than positively stained cells. Artefacts of
 214 processing also had an uneven edge, whilst cells were more regularly shaped. The pale
 215 brown background stain on all sections was non-specific.

Deleted: Representative

Deleted: ,

216 Positive staining for macrophages (Fig. 1) was seen in 85 % of birds (10 of 12)
 217 housed on wet litter within the uppermost layer of the epidermis just below the keratin layer
 218 (surface keratin had been lost), whereas there was no staining for macrophages in birds
 219 housed on dry litter ($\chi^2 = 21.8, P < 0.001$). CD4⁺ T lymphocytes (Fig. 2) were evident
 220 throughout the upper and lower dermis of all birds housed on wet litter compared with only
 221 15 % (2 of 12) housed on dry litter ($\chi^2 = 15.5, P < 0.001$). Positive staining for CD8⁺ T
 222 lymphocytes (Fig. 3) was present in over 90 % of birds (11 of 12) housed on wet litter
 223 compared with 25 % of birds (3 of 12) housed on dry litter ($\chi^2 = 13.7, P < 0.001$). No staining
 224 for B lymphocytes was observed in any of the sections (Fig. 4).

225

226 **qRT-PCR.** Means, standard errors and fold changes of corrected 40-C_t values for each
 227 cytokine and chemokines are presented in Table 2. There was a significant difference
 228 ($P<0.05$) between the mRNA expression levels of the majority of cytokines and chemokines
 229 measured in the foot pad tissues of birds housed on wet and dry litter after 48 h, the only
 230 exception being the Treg cytokine IL-10, for which there was no significant difference in
 231 mRNA expression levels. For the pro-inflammatory cytokines, mRNA expression levels
 232 were upregulated dramatically in foot pad tissues from birds housed on wet litter, as opposed
 233 to those housed on dry litter, from 65-fold for IL-6 to 1924-fold for CXCLi2. IFN- γ mRNA
 234 expression levels were also greatly increased (32-fold). IL-13 mRNA expression levels,
 235 although significantly different, were only increased 2-fold.

236

237 Discussion

238 Our primary objective was to determine whether the inflammation associated with FPD in
 239 turkeys was due to an allergic reaction to an allergen in the litter, or a classical inflammatory
 240 response. To this end, we measured cytokine mRNA expression levels, and used
 241 immunohistochemistry to identify subsets of immune cells, in the footpad tissues in a
 242 previously validated model for inducing FPD in turkeys (Mayne *et al.*, 2007b).

243 In previous experiments a marked inflammatory response was observed by 48 h after
 244 exposure to wet litter and we chose this time point to ensure that a severe immune repose
 245 was observed and also to avoid any secondary reparative changes. Footpad tissue sections

246 stained for specific immune cell subsets showed that birds housed on wet litter had increased
 247 levels of macrophages and CD4⁺ and CD8⁺ T lymphocytes, but no detectable B cells. Also,
 248 mRNA expression levels for the pro-inflammatory cytokines IL-1 β , IL-6 and CXCLi2 were

Deleted: ¶
 Mean external scores of FPD of turkeys after 48 h on wet and dry litter respectively were 6.2 and 1.2 on a 7-point scale (Mayne *et al.*, 2007b), illustrating the inflammation caused by housing birds on wet litter. We wished

Formatted: Font: Not Bold

Deleted: this

Formatted: Font: Not Bold

Deleted: reaction

Deleted: .

Deleted: .

Deleted: phase

249 all highly upregulated in these tissues, with CXCLi2 increasing by more than 1900-fold. Pro-
250 inflammatory reactions commonly lead to a Th1, IFN- γ -mediated response that results in an
251 influx of CD8⁺ cytotoxic T cells whereas only 25 % of birds housed on dry litter showed
252 positive staining for CD8⁺ T lymphocytes. This was not unexpected, however, as naïve T
253 lymphocytes only respond in substantial numbers to an inflammatory reaction 4-5 days post
254 initial inflammation. For the Th signature cytokines, both IFN- γ and IL-13 mRNA
255 expression levels were upregulated, the former by more than 30-fold, whereas IL-13 only
256 increased 2-fold, a difference that would not normally be considered of biological
257 significance.

258 In contrast to our results for macrophage staining, Igyarto et al (2006) reported that
259 50 % of epidermal dendritic cells were positive for the KuL01 antibody in featherless skin of
260 8 wk old chickens. We failed to detect macrophage cells in the footpad of birds on the dry
261 treatment and the differences between the two data sets may be a consequence of different
262 housing, age, tissue or species and warrant further research.

263 The results are consistent with the conclusion that FPD in these turkeys was a non-
264 specific inflammatory reaction. Although an allergic reaction, perhaps to a water-soluble
265 antigen in the litter released when the litter was wet, could have occurred, it is unlikely that
266 this would have happened in 48 h unless the turkeys had been previously exposed to the
267 allergen causing the reaction. Damp patches are inevitably present in normal dry litter and it
268 is likely that the skin of the foot pads of these turkeys was exposed to water soluble allergens
269 in the period before the experiment. If sensitisation to these allergens had occurred, exposure
270 to the experimental treatment should induce a secondary allergic response in 48 h which we
271 did not observe; the cytokines that would be indicative of an allergic response (IL-10 and IL-

Deleted: As the turkeys had been housed on dry litter until exposure to the wet litter, it is hard to imagine the nature of any such allergen.

Deleted: Furthermore,

272 13) were not recorded at high levels.

273 In conclusion, these data suggest that there was a rapidly occurring inflammatory
274 response in the foot pads of birds housed on wet litter for 48 h and that an allergic response
275 was unlikely. Further research is required to clarify the mode of action of litter moisture in
276 the aetiology of turkey FPD.

277

278 Acknowledgements

279

280 We are grateful to the farm staff at the Roslin Institute for daily care of the birds and Lisa
281 Rothwell for technical help. The Turkey Sector Group of the British Poultry Council funded
282 this research through PhD studentships for RKM and FP. Roslin Institute and the Institute for
283 Animal Health are supported by the BBSRC.

284

285 References

286

287 Igyarto, B. Z., Lacko, E., Olah, I. & Magyar, A. (2006). Characterization of chicken
288 epidermal dendritic cells. *Immunology*, 119, 278-288.

289 Kaiser, P., Hughes, S. & Bumstead, N. (1999). The chicken 9E3/CEF4 CXC chemokine is
290 the avian orthologue of IL8 and maps to chicken Chromosome 4 syntenic with genes
291 flanking the mammalian chemokine cluster. *Immunogenetics*, 49, 673-684.

292 Kaiser, P., Poh, T. Y., Rothwell, L., Avery, S., Balu, S., Pathania, U. S., Hughes, S.,
293 Goodchild, M., Morrell, S., Watson, M., Bumstead, N., Kaufman, J. & Young, J. R.

Formatted: Line spacing: Double

Formatted: Font: Italic

Formatted: Font: Italic

Formatted: Font: Bold

Formatted: Font: Italic

Formatted: Font: Italic

Formatted: Font: Bold

- 294 (2005). A genomic analysis of chicken cytokines and chemokines. *Journal of*
 295 *Interferon and Cytokine Research*, 25, 467-484.
- 296 Kaiser, P., Rothwell, L., Galyov, E. E., Barrow, P. A., Burnside, J. & Wigley, P. (2000).
 297 Differential cytokine expression in avian cells in response to invasion by *Salmonella*
 298 *typhimurium*, *Salmonella enteritidis* and *Salmonella gallinarum*. *Microbiology*, 146,
 299 3217-3226.
- 300 Kaiser, P., Underwood, G. & Davison, T. F. (2003). Differential cytokine responses
 301 following Marek's disease virus infection of chickens differing in resistance to
 302 Marek's disease. *Journal of Virology*, 77, 762-768.
- 303 Kogut, M. H., Rothwell, L. & Kaiser, P. (2003a). Differential regulation of cytokine gene
 304 expression by avian heterophils during receptor-mediated phagocytosis of opsonized
 305 and non-opsonized *Salmonella enteritidis*. *Journal of Interferon and Cytokine*
 306 *Research*, 23, 319-327.
- 307 Kogut, M. H., Rothwell, L. & Kaiser, P. (2003b). Priming by recombinant chicken
 308 interleukin-2 induces selective expression of IL-8 and IL-18 mRNA in chicken
 309 heterophils during receptor-mediated phagocytosis of opsonized and nonopsonized
 310 *Salmonella enterica* serovar enteritidis. *Molecular Immunology*, 40, 603-610.
- 311 Lawson, S., Rothwell, L., Lambrecht, B., Howes, K., Venugopal, K. & Kaiser, P. (2001).
 312 Turkey and chicken interferon-gamma, which share high sequence identity, are
 313 biologically cross-reactive. *Developmental and Comparative Immunology*, 25, 69-82.
- 314 Martins-Green, M. & Feugate, J. E. (1998). The 9E3/CEF4 gene product is a chemotactic
 315 and angiogenic factor that can initiate the wound-healing cascade *in vivo*. *Cytokine*,
 316 10, 522-535.

Formatted: Font: Italic

Formatted: Font: Italic

Formatted: Font: Bold

Formatted: Font: Italic

Formatted: Font: Italic

Formatted: Font: Italic

Formatted: Font: Italic

Formatted: Font: Italic

Formatted: Font: Bold

Formatted: Font: Italic

Formatted: Font: Italic

Formatted: Font: Bold

Formatted: Font: Italic

Formatted: Font: Italic

Formatted: Font: Italic

Formatted: Font: Bold

Formatted: Font: Italic

Formatted: Font: Italic

Formatted: Font: Bold

Formatted: Font: Italic

Formatted: Font: Italic

Formatted: Font: Bold

Formatted: Font: Italic

Formatted: Font: Italic

Formatted: Font: Italic

Formatted: Font: Bold

- 317 Martland, M. F. (1984). Wet litter as a cause of plantar pododermatitis leading to foot
 318 ulceration and lameness in fattening turkeys. *Avian Pathology*, 13, 241-252. Formatted: Font: Italic
 Formatted: Font: Italic
 Formatted: Font: Bold
- 319 Martland, M. F. (1985). Ulcerative dermatitis in broiler chickens: the effects of wet litter.
 320 *Avian Pathology*, 14, 353-364. Formatted: Font: Italic
 Formatted: Font: Italic
 Formatted: Font: Bold
- 321 Mayne, R. K. (2005). A review of the aetiology and possible causative factors of foot pad
 322 dermatitis in growing turkeys and broilers. *Worlds Poultry Science Journal*, 61, 256-
 323 267. Formatted: Font: Italic
 Formatted: Font: Italic
 Formatted: Font: Bold
- 324 Mayne, R. K., Else, R. W. & Hocking, P. M. (2007a). High dietary concentrations of biotin
 325 did not prevent foot pad dermatitis in growing turkeys and external scores were poor
 326 indicators of histopathological lesions. *British Poultry Science*, 48, (in press). Formatted: Font: Italic
 Formatted: Font: Italic
 Formatted: Font: Bold
- 327 Mayne, R. K., Else, R. W. & Hocking, P. M. (2007b). High litter moisture alone is sufficient
 328 to cause foot pad dermatitis in growing turkeys *British Poultry Science*, 48, (in press). Formatted: Font: Italic
 Formatted: Font: Italic
 Formatted: Font: Bold
- 329 Mayne, R. K., Hocking, P. M. & Else, R. W. (2006). Foot pad dermatitis develops at an early
 330 age in commercial turkeys. *British Poultry Science*, 47, 36-42. Formatted: Font: Italic
 Formatted: Font: Italic
 Formatted: Font: Bold
- 331 Peters, M. A., Browning, G. F., Washington, E. A., Crabb, B. S. & Kaiser, P. (2003).
 332 Embryonic age influences the capacity for cytokine production in chicken
 333 thymocytes. *Immunology Reviews*, 110, 358-367. Formatted: Font: Italic
 Formatted: Font: Italic
 Formatted: Font: Bold
- 334 Sick, C., Schneider, K., Staeheli, P. & Weining, K. C. (2000). Novel chicken CXC and CC
 335 chemokines. *Cytokine*, 12, 181-186. Formatted: Font: Italic, Danish
 Formatted: Danish
 Formatted: Font: Italic, Danish
 Formatted: Font: Bold, Danish
 Formatted: Danish
- 336 Sijben, J. W. C., Klasing, K. C., Schrama, J. W., Parmentier, H. K., Van Der Poel, J. J.,
 337 Savelkoul, H. F. & Kaiser, P. (2003). Early in vivo cytokine genes expression in
 338 chickens after challenge with *Salmonella typhimurium* lipopolysaccharide and Formatted: Font: Italic

339 modulation by dietary n-3 polyunsaturated fatty acids. *Developmental and*
 340 *Comparative Immunology*, 27, 611-619.

341 Tucker, S. & Walker, A. (1999). Hock Burn in Broilers. In *Recent developments in poultry*
 342 *nutrition*, vol. 2 (ed. J. Wiseman and P. C. Garnsworthy), pp. 107-122. Nottingham
 343 University Press, Nottingham.

344

Formatted: Font: Italic

Formatted: Font: Italic

Formatted: Font: Bold

Formatted: Font: Italic

Formatted: Indent: Left: 0 pt, First line: 0 pt, Line spacing: Double

Deleted: Kaiser, P., Hughes, S. & Bumstead, N. (1999). The chicken 9E3/CEF4 CXC chemokine is the avian orthologue of IL8 and maps to chicken Chromosome 4 syntenic with genes flanking the mammalian chemokine cluster. *Immunogenetics*, 49, 673-684.¶

Kaiser, P., Poh, T. Y., Rothwell, L., Avery, S., Balu, S., Pathania, U. S., Hughes, S., Goodchild, M., Morrell, S., Watson, M., Bumstead, N., Kaufman, J. & Young, J. R. (2005). A genomic analysis of chicken cytokines and chemokines. *Journal of Interferon and Cytokine Research*, 25, 467-484.¶

Kaiser, P., Rothwell, L., Galyov, E. E., Barrow, P. A., Burnside, J. & Wigley, P. (2000). Differential cytokine expression in avian cells in response to invasion by *Salmonella typhimurium*, *Salmonella enteritidis* and *Salmonella gallinarum*. *Microbiology*, 146, 3217-3226.¶

Kaiser, P., Underwood, G. & Davison, T. F. (2003). Differential cytokine responses following Marek's disease virus infection of chickens differing in resistance to Marek's disease. *Journal of Virology*, 77, 762-768.¶

Kogut, M. H., Rothwell, L. & Kaiser, P. (2003a). Differential regulation of cytokine gene expression by avian heterophils during receptor-mediated phagocytosis of opsonized and non-opsonized *Salmonella enteritidis*. *Journal of Interferon and Cytokine Research*, 23, 319-327.¶

Kogut, M. H., Rothwell, L. & Kaiser, P. (2003b). Priming by recombinant chicken interleukin-2 induces selective expression of IL-8 and IL-18 mRNA in chicken heterophils during receptor-mediated phagocytosis of opsonized and nonopsonized *Salmonella enterica* serovar enteritidis. *Molecular Immunology*, 40, 603-610.¶

Lawson, S., Rothwell, L., Lambrecht, B., Howes, K., Venugopal, K. & Kaiser, P. (2001). Turkey and chicken interferon-gamma, which share high sequence identity, are biologically cross-reactive. *Developmental and Comparative Immunology*, 25, 69-82.¶

Martins-Green, M. & Feugate, J. E. (1998). The 9E3/CEF4 gene product is a chemotactic and angiogenic factor that can initiate the wound-healing cas[... [1]

Formatted: English (U.S.)

Formatted: Indent: Left: 0 pt, Hanging: 36 pt

345 **Figure legends**

346

347 **Figure 1.** Presence of macrophages in footpad tissue sections from turkeys housed on (a) dry
348 or (b, c) wet litter for 48 h. Original magnification x 10 (a, b) or x 20 (c). External footpad
349 scores were 0 (a) and 7 (b,c). Key: A = keratin, B = lost surface keratin, C = epidermis, D =
350 dermis and E = positively stained cells in epidermis and dermis; bar is 100 μm (a, b) or 50
351 μm (c).

352

353 **Figure 2.** Presence of CD4^+ T lymphocytes in footpad tissue sections from turkeys housed
354 on (a) dry or (b, c) wet litter for 48 h. Original magnification x 10 (a, b) or x 20 (c). External
355 footpad scores were 0 (a) and 7 (b,c). Key: A = keratin, B = lost surface keratin, C =
356 epidermis, D = dermis and E = positively stained cells in epidermis and dermis; bar is 100
357 μm (a, b) or 50 μm (c).

358

359 **Figure 3.** Presence of CD8^+ T lymphocytes in footpad tissue sections from turkeys housed
360 on (a) dry or (b, c) wet litter for 48 h. Original magnification x 10 (a, b) or x 20 (c). External
361 footpad scores were 3 (a) and 6 (b,c). Key: A = keratin, B = lost surface keratin, C =
362 epidermis, D = dermis and E = positively stained cells in epidermis and dermis; bar is 100
363 μm (a, b) or 50 μm (c).

Deleted: 0

364 **Figure 4.** Absence of B lymphocytes in footpad tissue sections from turkeys housed on (a)
365 dry or (b) wet litter for 48 h. Original magnification x 10. External footpad scores were 0 (a)
366 and 7 (b). Key: A = keratin, B = lost surface keratin, C = epidermis and D = dermis; bar is
367 100 μm (a, b).

For Peer Review Only

368 **Table 1.** Real-time quantitative RT-PCR probes and primers.

RNA target	Probe/primer sequence	Specific for	Accession No.	Exon boundaries ^c
28S	Probe 5'-(FAM)-AGGACCGCTACGGACCTCCACCA-(TAMRA)-3'	Chicken	X59733	-
	F ^a 5'-GGCGAAGCCAGAGGAAACT-3'	and		
	R ^b 5'-GACGACCGATTGACGTC-3'	turkey		
IL-1 β	Probe 5'-(FAM)-CCACACTGCAGCTGGAGGAAGCC-(TAMRA)-3'	Chicken	AJ245728	5/6
	F 5'-GCTCTACATGTCGTGTGTGATGAG-3'	and		
	R 5'-TGTCGATGTCCCGCATGA-3'	turkey		
IL-6	Probe 5'-(FAM)-AGGAGAAATGCCTGACGAAGCTCTCCA-(TAMRA)-3'	Chicken	AJ250838	3/4
	F 5'-GCTCGCCGGCTTCGA-3'	and		
	R 5'-GGTAGGTCTGAAAGCGAACAG-3'	turkey		
CXCLi2	Probe 5'-(FAM)-CAGCTCTGTCCACAAGGTAGGACCCTGGT-(TAMRA)-3'	Turkey	AM493430	1/2
	F 5'-TGGCTCTCCTCCTGGTTTCA-3'			
	R 5'-GCAGCTCGTCCCATCTT-3'			
IFN- γ	Probe 5'-(FAM)-AAAGATATCATGGACCTGGCCAAGCTTCA-(TAMRA)-3'	Turkey	AJ000725	3/4
	F 5'-AACCTTCCTGATGGCGTGAA-3'			
	R 5'-CTTGCGCTGGATTCTCAAGTC-3'			
IL-13	Probe 5'-(FAM)-TGCCAGCTGAGCACCGACAACG-(TAMRA)-3'	Turkey	AM493431	3/4
	F 5'-CCTGCACGGCCAGATGA-3'			
	R 5'-GGCAAGAAGTTCCGCAGGTA-3'			
IL-10	Probe 5'-(FAM)-CCTGAAGATGACAATGAAGCGCTGTCA-(TAMRA)-3'	Turkey	AM493432	3/4
	F 5'-CGACCTGGGCAACATGCT-3'			
	R 5'-CCTCTCGCAGGTGAAGAAGTG-3'			

369

370 ^aForward.371 ^bReverse.372 ^cExon boundaries in the chicken gene (gene structures have not yet been determined for the

373 turkey genes).

374 **Table 2.** Corrected cytokine 40-C_t values for foot pad tissue of turkeys raised on dry litter
 375 and exposed to dry or wet litter for 48 h at 28 d of age.

376

Cytokine/chemokine		Corrected 40-C _t value		SED	P	Fold change ^a
		Dry litter	Wet litter			
Pro-inflammatory	IL-1 β	3.66	12.97	0.854	<0.001	+635
	IL-6	7.50	10.51	1.057	0.019	+65
	CXCLi2	10.10	21.01	1.014	<0.001	+1924
Th1	IFN- γ	1.44	6.45	0.563	<0.001	+32
Th2	IL-13	7.43	8.52	0.262	0.002	+2
Treg	IL-10	4.02	2.51	0.780	0.086	Deleted: NS

377

378 ^aCalculated as $2^{(\text{wet litter 40-Ct value} - \text{dry litter 40-Ct value})}$

Page 16: [1] Deleted hocking 7/5/2007 3:24:00 PM

Kaiser, P., Hughes, S. & Bumstead, N. (1999). The chicken 9E3/CEF4 CXC chemokine

is the avian orthologue of IL8 and maps to chicken Chromosome 4 syntenic with genes flanking the mammalian chemokine cluster. *Immunogenetics*, 49, 673-684.

Kaiser, P., Poh, T. Y., Rothwell, L., Avery, S., Balu, S., Pathania, U. S., Hughes, S.,

Goodchild, M., Morrell, S., Watson, M., Bumstead, N., Kaufman, J. & Young, J.

R. (2005). A genomic analysis of chicken cytokines and chemokines. *Journal of Interferon and Cytokine Research*, 25, 467-484.

Kaiser, P., Rothwell, L., Galyov, E. E., Barrow, P. A., Burnside, J. & Wigley, P. (2000).

Differential cytokine expression in avian cells in response to invasion by

Salmonella typhimurium, *Salmonella enteritidis* and *Salmonella gallinarum*.

Microbiology, 146, 3217-3226.

Kaiser, P., Underwood, G. & Davison, T. F. (2003). Differential cytokine responses

following Marek's disease virus infection of chickens differing in resistance to

Marek's disease. *Journal of Virology*, 77, 762-768.

Kogut, M. H., Rothwell, L. & Kaiser, P. (2003a). Differential regulation of cytokine gene

expression by avian heterophils during receptor-mediated phagocytosis of

opsonized and non-opsonized *Salmonella enteritidis*. *Journal of Interferon and*

Cytokine Research, 23, 319-327.

Kogut, M. H., Rothwell, L. & Kaiser, P. (2003b). Priming by recombinant chicken

interleukin-2 induces selective expression of IL-8 and IL-18 mRNA in chicken

heterophils during receptor-mediated phagocytosis of opsonized and

nonopsonized *Salmonella enterica* serovar *enteritidis*. *Molecular Immunology*,

40, 603-610.

- Lawson, S., Rothwell, L., Lambrecht, B., Howes, K., Venugpal, K. & Kaiser, P. (2001). Turkey and chicken interferon-gamma, which share high sequence identity, are biologically cross-reactive. *Developmental and Comparative Immunology*, 25, 69-82.
- Martins-Green, M. & Feugate, J. E. (1998). The 9E3/CEF4 gene product is a chemotactic and angiogenic factor that can initiate the wound-healing cascade *in vivo*. *Cytokine*, 10, 522-535.
- Martland, M. F. (1984). Wet litter as a cause of plantar pododermatitis leading to foot ulceration and lameness in fattening turkeys. *Avian Pathology*, 13, 241-252.
- Martland, M. F. (1985). Ulcerative dermatitis in broiler chickens: the effects of wet litter. *Avian Pathology*, 14, 353-364.
- Mayne, R. K. (2005). A review of the aetiology and possible causative factors of foot pad dermatitis in growing turkeys and broilers. *Worlds Poultry Science Journal*, 61, 256-267.
- Mayne, R. K., Else, R. W. & Hocking, P. M. (2007a). High dietary concentrations of biotin did not prevent foot pad dermatitis in growing turkeys and external scores were poor indicators of histopathological lesions. *British Poultry Science*, 48, (in press).
- Mayne, R. K., Else, R. W. & Hocking, P. M. (2007b). High litter moisture alone is sufficient to cause foot pad dermatitis in growing turkeys *British Poultry Science*, 48, (in press).
- Mayne, R. K., Hocking, P. M. & Else, R. W. (2006). Foot pad dermatitis develops at an early age in commercial turkeys. *British Poultry Science*, 47, 36-42.

- Peters, M. A., Browning, G. F., Washington, E. A., Crabb, B. S. & Kaiser, P. (2003). Embryonic age influences the capacity for cytokine production in chicken thymocytes. *Immunology Reviews*, *110*, 358-367.
- Sick, C., Schneider, K., Staeheli, P. & Weining, K. C. (2000). Novel chicken CXC and CC chemokines. *Cytokine*, *12*, 181-186.
- Sijben, J. W. C., Klasing, K. C., Schrama, J. W., Parmentier, H. K., Van Der Poel, J. J., Savelkoul, H. F. & Kaiser, P. (2003). Early in vivo cytokine genes expression in chickens after challenge with *Salmonella typhimurium* lipopolysaccharide and modulation by dietary n-3 polyunsaturated fatty acids. *Developmental and Comparative Immunology*, *27*, 611-619.
- Tucker, S. & Walker, A. (1999). Hock Burn in Broilers. In *Recent developments in poultry nutrition*, vol. 2 (ed. J. Wiseman and P. C. Garnsworthy), pp. 107-122. Nottingham University Press, Nottingham.