



HAL
open science

Pathogenicity of *Mycoplasma lipofaciens* (Strain ML64) for turkey embryos

Michael Lierz, Stefanie Deppenmeier, Achim D. Gruber, Sebastian Brokat,
Hafez Mohamed Hafez

► **To cite this version:**

Michael Lierz, Stefanie Deppenmeier, Achim D. Gruber, Sebastian Brokat, Hafez Mohamed Hafez. Pathogenicity of *Mycoplasma lipofaciens* (Strain ML64) for turkey embryos. *Avian Pathology*, 2008, 36 (05), pp.389-393. 10.1080/03079450701589126 . hal-00540091

HAL Id: hal-00540091

<https://hal.science/hal-00540091>

Submitted on 26 Nov 2010

HAL is a multi-disciplinary open access archive for the deposit and dissemination of scientific research documents, whether they are published or not. The documents may come from teaching and research institutions in France or abroad, or from public or private research centers.

L'archive ouverte pluridisciplinaire **HAL**, est destinée au dépôt et à la diffusion de documents scientifiques de niveau recherche, publiés ou non, émanant des établissements d'enseignement et de recherche français ou étrangers, des laboratoires publics ou privés.



Pathogenicity of *Mycoplasma lipofaciens* (Strain ML64) for turkey embryos

Journal:	<i>Avian Pathology</i>
Manuscript ID:	CAVP-2007-0039.R1
Manuscript Type:	Original Research Paper
Date Submitted by the Author:	03-May-2007
Complete List of Authors:	Lierz, Michael; Free University of Berlin, Institute for Poultry Diseases Deppenmeier, Stefanie; Free University of Berlin, Department of Veterinary Pathology Gruber, Achim; Free University of Berlin, Department of Veterinary Pathology Brokat, Sebastian; Charite, Center for Cardiovascular Research Hafez, Hafez; Free University Berlin
Keywords:	vertical transmission, raptors, mycoplasma PCR, embryonic death

SCHOLARONE™
Manuscripts

Pathogenicity of *Mycoplasma lipofaciens* strain ML64 for turkey embryos

Lierz, M.^{1*}, S. Deppenmeier², A.D. Gruber², S. Brokat³ and H. M. Hafez¹

¹ Institute for Poultry Diseases, Freie Universitaet Berlin, Koenigsweg 63, 14163 Berlin, Germany, ² Department of Veterinary Pathology, Freie Universitaet Berlin, Germany, ³ Charité – Universitaetsmedizin Berlin, Germany

Short title: *M. lipofaciens* in turkey embryos

* To whom correspondence should be addressed. Tel: +49 30 83862699. E-mail: lierz.michael@vetmed.fu-berlin.de

Received: 17 March 2007

Cavp-2007-0039.R1

Pathogenicity of *Mycoplasma lipofaciens* strain ML64 for turkey embryos

Lierz, M.^{1*}, S. Deppenmeier², A.D. Gruber², S. Brokat³ and H. M. Hafez¹

¹ Institute for Poultry Diseases, Freie Universitaet Berlin, Koenigsweg 63, 14163 Berlin, Germany, ² Department of Veterinary Pathology, Freie Universitaet Berlin, Germany, ³ Charité – Universitaetsmedizin Berlin, Germany

Abstract

Mycoplasma lipofaciens strain ML64, isolated from an egg of a northern goshawk (*Accipiter gentilis*), has been found to be pathogenic for chicken embryos causing mortality during first two weeks of incubation. The same strain was inoculated in turkey embryos to evaluate its pathogenicity and its ability to be transmitted laterally in the hatchery. The strain was found to be pathogenic for turkey embryos causing a high mortality (88.9%) during late incubation as well as haemorrhages of the legs, dwarfing, curled toes and a severe, multifocal, purulent to necrotizing bronchopneumonia. In addition, lateral transmission between turkey poults hatched from infected eggs and poults from non-infected controls, was observed in the incubator.

Introduction

Several *Mycoplasma* species are well known pathogens of poultry and such infections in turkeys are often accompanied by severe considerable loss. These infections spread by vertical and horizontal routes and in the past were thought to have a relatively restricted host range. However, recent observations have cast doubt on that theory, as several avian *Mycoplasma* species have been isolated from a number of different avian hosts including birds of prey (Lierz *et al.*, 2000a, b; 2002; Bradbury, 2006) and there is even a report of isolation of a mammalian *Mycoplasma* (*M. capricolum*-like) from chickens (Bencina *et al.*, 2006).

M. lipofaciens was first described in 1983 as a new species isolated from the infraorbital sinus of a chicken without any clinical signs (Bradbury *et al.*, 1983). Subsequently, isolation of *M. lipofaciens* was reported from the chicken, turkey and duck (Bencina *et al.*, 1987). Recently, Lierz *et al.* (2007a) isolated *M. lipofaciens* from an egg of an imprinted 4 year old Northern Goshawk (*Accipiter gentilis*). Identification was carried out by immunobinding assay as well as sequencing a fragment (928bp) of the 16S rRNA gene (GenBank Accession No: DQ653410). Therefore *M. lipofaciens* seems capable of crossing avian taxonomic divides, and is not strictly specific to a particular avian species.

Vertical transmission of mycoplasmas is well known in poultry, and can cause embryonic death and poorly developed embryos especially in chickens and turkeys, often without causing clinical signs in the parent flock (Yamamoto and Ortmayer 1966; Carpenter *et al.*, 1981; Lin and Kleven 1982; Glisson and Kleven 1984; 1985). The pathogenicity of mycoplasmas for the embryo is strain dependent, as demonstrated for *M. synoviae* (Lockaby *et al.*, 1999) and *M. iowae* (Bradbury & McCarthy, 1983). *M. gallisepticum* causes liver necrosis in the chicken embryo (Lin & Kleven, 1982), whereas *M. iowae* is able to cause

oedema, dwarfing, congestion of the chicken embryo or mustard coloured liver and spleen with a low incidence of air sac lesions (Bradbury & McCarthy, 1983). The pathogenicity of *M. lipofaciens* strain ML64 for chicken embryos was demonstrated by Lierz *et al.* (2007b). The authors described high embryo mortality accompanied by severe tissue oedema with infiltrates of heterophils and necrosis in liver, intestine and chorioallantoic membrane (CAM). Since *M. lipofaciens* has been reported to occur in turkeys (Bencina *et al.*, 1987), the study described here was designed to investigate if strain ML64 (isolated from a Northern goshawk egg, and possibly vertically transmitted), was pathogenic for turkey embryos and if so, to see if the pathogenicity differed from that in chicken embryos. In addition, the capability of this isolate to spread horizontally within the turkey hatchery was investigated.

Material and Methods

Preparation of bacterial suspension. The fifth single colony subculture of mycoplasma strain ML64 that had been used for the immunobinding assay and DNA-sequencing (GenBank Accession No: DQ653410) for identification as *M. lipofaciens* (Lierz *et al.*, 2007a) was cultured (24 h, 37°C, 5% CO₂) in liquid mycoplasma media as described by Bradbury (1998) but without thallium acetate. The number of colony-forming units (CFU) was determined according to standard methods (Albers & Fletcher, 1982) and the suspension was diluted with sterile mycoplasma broth to the required dose (see below) directly prior to inoculation and without additional incubation.

Pathogenicity and infectivity test in turkey embryos. Pathogenicity of the isolate was estimated by inoculating the yolk sac of turkey embryos from a parent flock known to be free of mycoplasmas, using a 0.8 x 40 mm (21 gauge) needle (Sterican®, Luer-Lock, Braun

Melsungen, Germany). Fifteen embryonated turkey eggs were infected at day 8 of incubation with 2×10^6 CFU *M. lipofaciens* strain ML64. A further group of 15 was inoculated with 2×10^4 CFU and another with 2×10^2 CFU. In each case the inoculum was contained in 0.1 ml mycoplasma broth. In addition, a negative control group of 10 embryonated turkey eggs was inoculated with 0.1 ml sterile mycoplasma broth per egg. As a positive control 15 SPF-embryonated chicken eggs (Valo®, Lohmann, Cuxhaven, Germany) were infected at day 7 of incubation with 2×10^6 CFU/ 0.1 ml *M. lipofaciens* strain ML64.

All eggs were candled daily post inoculation (p.i.) to observe embryonic death and from day 11 of incubation onwards embryo viability was also monitored using the Buddy® Digital Egg Monitor (Lierz *et al.*, 2006) for a more precise evaluation. In cases of embryonic death, each embryo was subjected to a necropsy and a sample of vitelline membrane was used to inoculate mycoplasma broth for re-isolation of the pathogen according to standard methods. Directly after inoculation and after incubation (37°C, 5% CO₂) for 5 days, the broth was subcultured (0.2 ml) onto solid mycoplasma agar medium (Bradbury, 1998). The solid medium was observed for up to 10 days to detect the occurrence of mycoplasma colonies. Any mycoplasmas that were isolated were subjected to an immunobinding assay (IBA) according to Kotani and McGarrity (1986). Briefly, mycoplasma colonies were transferred onto nitrocellulose membranes and incubated with 200µl of rabbit antiserum directed against *M. lipofaciens* (diluted 1:1000) for 45min. After three washing steps, 200µl of a peroxidase-conjugated goat-anti-rabbit serum (diluted 1:1000) was added and again incubated for 45 min. Following repeated washing steps, 200µl of a 4-chloro-1-naphthol-solution was added as substrate and incubated until a blue colour reaction was visible. After a final washing, positive colonies appear blue while negative colonies remain white.

Samples of vitelline membrane were also taken to detect *Mycoplasma* genus-specific DNA using a PCR described by Lierz *et al.* (2007a). The PCR samples were first stored at -20°C and tested only if isolation from the embryo was negative.

Liver, egg yolk, allantoic and amniotic fluids of each embryo were streaked on blood (5% sheep erythrocytes) and Gassner agars (Oxoid, Germany) and incubated at 37°C for 2 days in both aerobic and anaerobic conditions to exclude bacterial contamination.

For hatching and for 24 h afterwards, all turkey eggs were placed in the same incubator to observe possible horizontal transmission of *M. lipofaciens* between the infected groups and the negative controls. After this time all poults were killed and the trachea and vitelline membrane examined for isolation of mycoplasmas as well as for the *Mycoplasma* genus-specific PCR as described above.

Finally embryos and poults were fixed in 10% neutral buffered formaldehyde-solution for 48 h. Heart, lung, air sac, spleen, kidney, liver, proventriculus, gizzard, intestine, joints (including cartilage, bone, tendon and muscle), vitelline membrane and also CAM for dead-in-shell embryos, were embedded in paraffin wax according to standard methods. They were sectioned at 5µm, stained with haematoxylin and eosin and examined for microscopic lesions. Any embryo deaths at day 1 or 2 p.i. was considered non-specific and histopathological examination was not performed.

Statistical methods. The Kaplan-Meier method was used to construct survival curves, which were then compared by the log-rank test, with correction for multiple comparisons. A p value of <0.05 was considered significant.

Results

Twelve of the 15 chicken embryos (positive controls) died within 7 days after infection. In total only five (11.1%) of the 45 infected turkey embryos hatched. Forty (88.9%) turkey embryos of the infected groups died, mainly on days 19 and 20 p.i.. No differences in the

mortality rate were detected between the three infected groups. The number of embryos and their time of death are shown in Table 1.

From the negative control group five out of six embryos hatched (three were killed as controls for the infected groups and one died during inoculation of mycoplasma medium).

The survival rate was significantly reduced in the group given 10^2 CFU ($p=0.001$), the group given 10^4 CFU ($p=0.001$), the group given 10^6 CFU ($p<0.001$) and the positive control group ($p=0.001$) compared to the negative control group (Figure 1). The time of embryonic death was independent on the infectious dose of *M. lipofaciens* for the three turkey groups. The positive control (chicken embryos) revealed a significantly earlier onset of mortality than the three infected turkey groups ($p<0.05$).

Re-isolation of mycoplasmas identified as *M. lipofaciens* by the IBA was possible from all infected embryos. The mycoplasma broths that were inoculated with vitelline membrane and then plated onto agar without further incubation demonstrated a heavy growth of mycoplasma colonies indicating multiplication of the pathogen within the embryo. Mycoplasmas were not isolated from any embryo of the negative control group (three killed and one unhatched). The *Mycoplasma* genus-specific PCR performed on the negative samples of the control group did not detect *Mycoplasma* DNA and bacterial contamination was not found in any of the samples.

In the turkey embryos that died after infection, the *M. lipofaciens* strain caused petechial haemorrhages, haemorrhages on the legs, curled toes and, in a few cases, oedema and dwarfing (see Figures 2-5). Dislocation of the toes was also observed in two hatched chicks. Histopathological examination revealed severe, multifocal, purulent to necrotizing pneumonia with infiltration of heterophils within the bronchi (see Figure 6). There were no pathological lesions in the air sacs. In two cases a purulent- necrotizing gastritis was observed and in one case a purulent-necrotizing hepatitis.

After hatching in contact with the infected poult, it was possible to isolate *M. lipofaciens* from the trachea of two out of the five poult from the negative control group. The vitelline membrane of all poult from the negative control group and the tracheas of three from this group were negative for both mycoplasma isolation and for detection of *Mycoplasma* DNA. It was possible to isolate *M. lipofaciens* from all the vitelline membranes and tracheas from the hatched poult of the infected groups.

Discussion

Mycoplasma lipofaciens was isolated from healthy chicken and turkeys (Bradbury *et al.*, 1983; Bencina *et al.*, 1987) and also from an egg of a northern goshawk (Lierz *et al.*, 2007a) demonstrating its potential to be vertically transmitted.

The pathogenicity of *M. lipofaciens* strain ML64 for chicken embryos was described by Lierz *et al.* (2007b) as leading to a rapid embryonic death 7 days p.i. The survival rates of the infected turkey embryos were significantly lower than the negative control group, demonstrating the pathogenicity of *M. lipofaciens* strain ML64 for turkey embryos with a very high mortality (88.9%). This mortality is a greater than that described for pathogenic strains of *M. iowae* in chicken embryos (10% – 30%) (Bradbury & McCarthy, 1983) where a dose-response was not observed. Infected turkey embryos died mainly directly prior to hatching, which is significantly later than chicken embryos.

In addition it was possible to isolate *M. lipofaciens* from the trachea of two out of five hatched poult from the negative control group after 24h contact in the incubator with hatched infected poult, demonstrating the lateral transmission of *M. lipofaciens* strain ML64 between turkey poult within the incubator and its potential to spread within the turkey population.

The post mortem lesions of the turkey embryos which died, including haemorrhages on the legs, curled toes and dwarfing, are similar to those described in chicken embryos (Lierz *et al.*, 2007b) and also those caused by other pathogenic *Mycoplasma* spp. (Bradbury and McCarthy, 1983; Lockaby *et al.*, 1999). Such alterations seem to be typical for infections by mycoplasmas (Lin & Kleven, 1982; Glisson & Kleven, 1984, 1985). Interestingly, the histopathological findings in turkey embryos infected with *M. lipofaciens* were mainly located in the lung with a severe purulent to necrotizing bronchopneumonia while in chicken embryos the major findings were in the liver (Lierz *et al.*, 2007b). This might be the reason why chicken embryos died earlier after infection because they use their liver during embryonic development. In contrast the lung is needed only immediately prior to pipping and onwards, when the poults enter the air space of the egg and adapt to lung breathing (Steinke, 1983). It is surprising that the air sacs were without histopathological changes but this was also described for *M. iowae* in chick embryos (Bradbury and Mc Carthy, 1983).

Turkey breeder flocks are routinely monitored for mycoplasmas using serology and PCR (Hafez and Jodas, 1997). Usually the laboratory tests employed are specific for certain mycoplasma species, in particular *M. meleagridis*, *M. iowae*, *M. gallisepticum* or *M. synoviae*. Using such tests would fail to detect an infection of the breeder flock with *M. lipofaciens*, which is theoretically possible since this organism has already been isolated from turkeys (Bencina *et al.*, 1987). Should future investigations suggest that *M. lipofaciens* is of importance in turkey flocks, it might become necessary to include this mycoplasma in the differential diagnosis of hatching problems in breeders. The use of a *Mycoplasma* genus-specific PCR (Lierz *et al.*, 2007a) together with mycoplasma culture and identification of any isolates could be of value in cases where there is suspicion of mycoplasma infection but where negative results are obtained for the standard poultry pathogenic mycoplasma species.

Acknowledgement

The authors thank Prof. J. Bradbury, University of Liverpool, for provision of the mycoplasma antisera used in the IBA.

References

- Albers, A.C. & Fletcher, R.D. (1982). Simple method for quantitation of viable mycoplasmas. *Applied Environmental Microbiology*, 43, 958-960.
- Bencina, D., Dorrer, D. & Tadina, T. (1987). *Mycoplasma* species isolated from six avian species. *Avian Pathology*, 16, 653-664.
- Bencina, D., Bradbury, J.M., Stipkovits, L., Varga, Z., Razpet, A., Bidovec, A. & Dovc, P. Isolation of *Mycoplasma capricolum*-like strains from chickens. *Veterinary Microbiology*, 112, 23-31.
- Bradbury, J.M. (1998). Recovery of mycoplasmas from birds. In R. Miles & R. Nicholas (Eds). *Mycoplasma Protocols* (pp. 45-51). New Jersey, Humana Press Inc..
- Bradbury, J.M. & McCarthy J.D. (1983). Pathogenicity of *Mycoplasma iowae* for chick embryos. *Avian Pathology*, 12, 483-496.
- Bradbury, J.M., Forrest, M. & Williams, A. (1983). *Mycoplasma lipofaciens*, a new species of avian origin. *International Journal of Systematic Bacteriology*, 33, 329-335
- Bradbury, J.M. (2006). Mycoplasmas: a century and not out. *Turkeys*, 54, 9-11.
- Carpenter, T.E., Edson, R.K & Yamamoto, R. (1981). Decreased hatchability of turkey eggs caused by experimental infection with *Mycoplasma meleagridis*. *Avian Diseases*, 25, 151-156.

- Glisson, J.R. & Kleven, S.H. (1984). *Mycoplasma gallisepticum* vaccination: effects on egg transmission and egg production. *Avian Diseases*, 28, 406-415.
- Glisson, J.R. & Kleven, S.H. (1985). *Mycoplasma gallisepticum* vaccination: further studies on egg transmission and egg production. *Avian Diseases*, 29, 408-415.
- Hafez H.M. & Jodas, S. (1997). Mykoplasmosen. In Hafez H.M. und Jodas S. (Hrsg). *Putenkrankheiten*. (pp. 86-93). Enke Verlag, Stuttgart.
- Kotani, H. & McGarrity, G.J. (1986). Identification of mycoplasma colonies by immunobinding. *Journal of Clinical Microbiology*, 23, 783-785.
- Lierz, M., Schmidt, R., Brunnberg, L., & Runge, M. (2000a). Isolation of *Mycoplasma meleagridis* from free- ranging birds of prey in Germany. *Journal of Veterinary Medicine B*, 47, 63-67.
- Lierz, M., Schmidt, R., Goebel, T., Ehrlein, J. & Runge, M. (2000b). Detection of *Mycoplasma* spp. in raptorial birds in Germany. In: Lumeij, J.T., Remple, J.D., Redig, P.T., Lierz, M. & Cooper, J.E. (Eds.). *Raptor Biomedicine 3*. Zoological Education Network, Lake Worth, Florida, USA.
- Lierz, M., Schmidt, R. & Runge, M. (2002). *Mycoplasma* species isolated from falcons in the Middle East. *Veterinary Record*, 151, 92-93.
- Lierz, M., Hagen, N., Harcourt-Brown, N., Hernandez-Divers, S. J., Lueschow, D. & Hafez, H. M. (2007a). Prevalence of mycoplasmas in eggs from birds of prey using culture and a genus-specific mycoplasma polymerase chain reaction. *Avian Pathology*, 36, 145-150.
- Lierz, M., Stark, R., Brokat, S. & Hafez, H.M. (2007b). Pathogenicity of *M. lipofaciens* strain ML64, isolated from an egg of a Northern Goshawk (*Accipiter gentilis*), for chicken embryos. *Avian Pathology*, 36, 151-153.
- Lierz, M., Gooss, O. & Hafez, H.M. (2006). Measurement of avian embryos heart rate using a novel non-invasive method (Buddy® digital egg monitor). *Journal of Avian Medicine and Surgery*, 20, 141-146.

- Lin, M.Y. & Kleven, S.H. (1982). Egg transmission of two strains of *Mycoplasma gallisepticum* in chickens. *Avian Diseases*, 26, 487-495.
- Lockaby, S.B., Hoerr, F.J., Kleven, S.H. & Lauerma, L.H. (1999). Pathogenicity of *Mycoplasma synoviae* in chicken embryos. *Avian Diseases*, 43, 331-337
- Steinke, L. (1989). Embryonalentwicklung. In Mehner, A & Hartfiel, W. (eds.). Handbuch der Geflügelphysiologie- Teil 2. (p. 1056). Karger, Basel, Munich, London, New York, Tokyo, Sydney.
- Yamamoto, R. & Ortmayer, H.B. (1966). Pathogenicity of *Mycoplasma meleagridis* for turkey and chicken embryos. *Avian Diseases*, 10, 268-272.

Table 1. Numbers of turkey embryo deaths and of those which hatched after inoculation with *M. lipofaciens* strain ML64

<i>Group</i>	<i>n</i>	2	3	5	6	Day 7	p.i. 12	13	14	19	20	Total deaths	<i>No.</i> <i>hatched</i>
2 x10 ^{6a}	15	1 ^b	0	0	2	1	0	0	1	7	2	14	1
2 x 10 ⁴	15	1	0	0	1	1	1	0	0	6	3	13	2
2 x 10 ²	15	2	0	0	1	0	1	1	0	4	4	13	2
NC	10	1	0	0	0	0	1 ^c	0	0	1 ^c	1 ^c	1	5/6
PC	15	0	4	5	0	3	0	0	0	0	0	12	3

^aDose (CFU) of inoculum per embryo.

^bNumber dead.

^cKilled.

NC, negative controls; turkey embryos inoculated with sterile mycoplasma broth.

PC, positive controls; chick embryos inoculated with 2 x10⁶CFU strain ML64.

Figure 1. *Survival curves for turkey embryos inoculated with different doses of M. lipofaciens strain ML64. NC, negative controls; turkey embryos inoculated with sterile mycoplasma broth; PC, positive controls; chick embryos inoculated with 2×10^6 CFU strain ML64.*

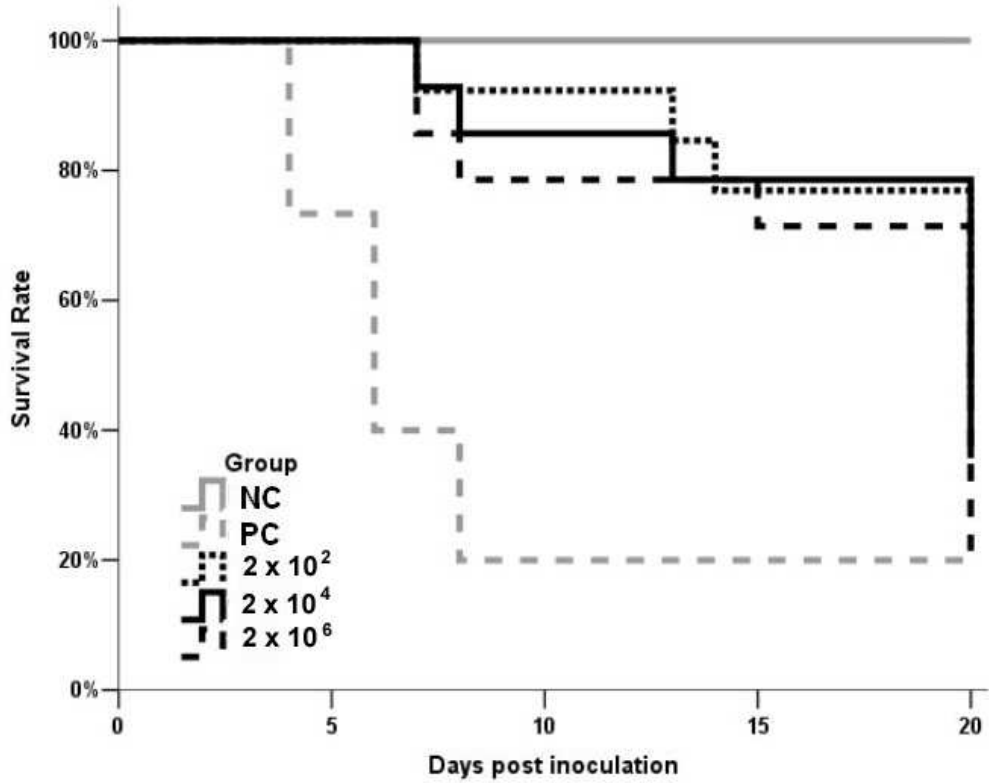
Figure 2. *Haemorrhages on the leg of a turkey embryo 12 days after inoculation (day 20 of incubation) with 2×10^2 CFU of M. lipofaciens strain ML64.*

Figure 3. *Petechial haemorrhages in a turkey embryo 19 days after inoculation (day 27th of incubation) with 2×10^2 CFU of M. lipofaciens strain ML64.*

Figure 4. *Right: Dwarfed turkey embryo, 20 days after inoculation (day 28 of incubation) with 2×10^2 CFU of M. lipofaciens strain ML64. Left: Turkey embryo of the control group at same age for comparison.*

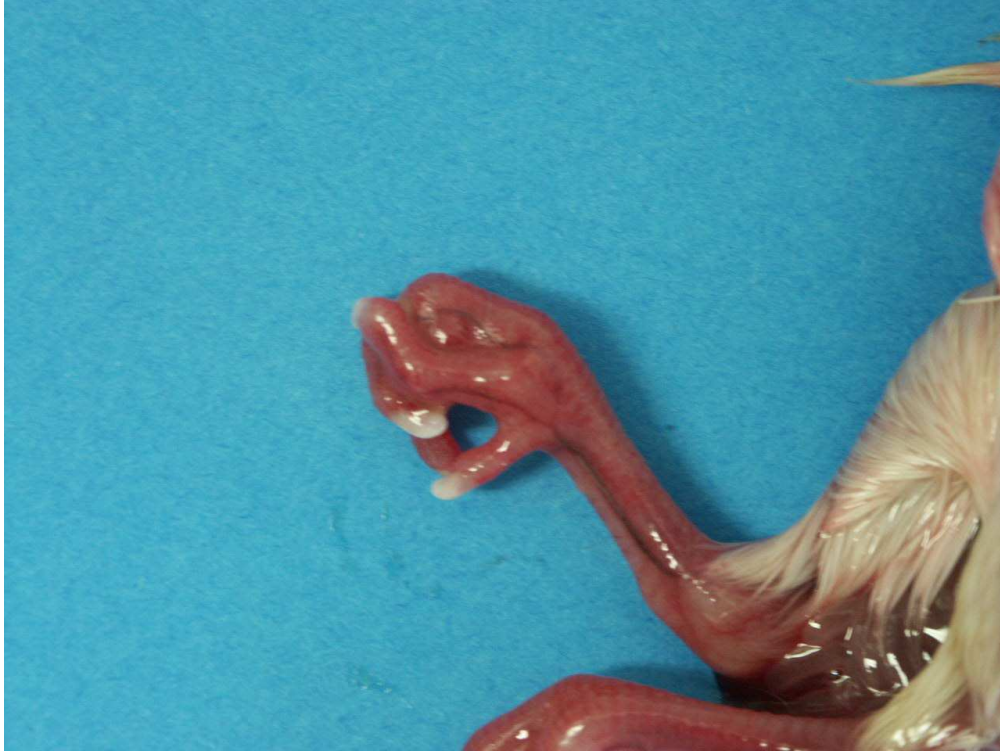Figure 5. *Turkey embryo with curled toes, 19 days after inoculation (day 27 of incubation) with 2×10^2 CFU of M. lipofaciens strain ML64.*

Figure 6. *Severe, multifocal, purulent to necrotizing bronchopneumonia in a turkey embryo 20 days after inoculation (day 28 of incubation) with 2×10^2 CFU of M. lipofaciens strain ML64. HE- stained, 250 x magnification.*



232x183mm (72 x 72 DPI)

Pre-proof Only



451x338mm (72 x 72 DPI)

ew Only

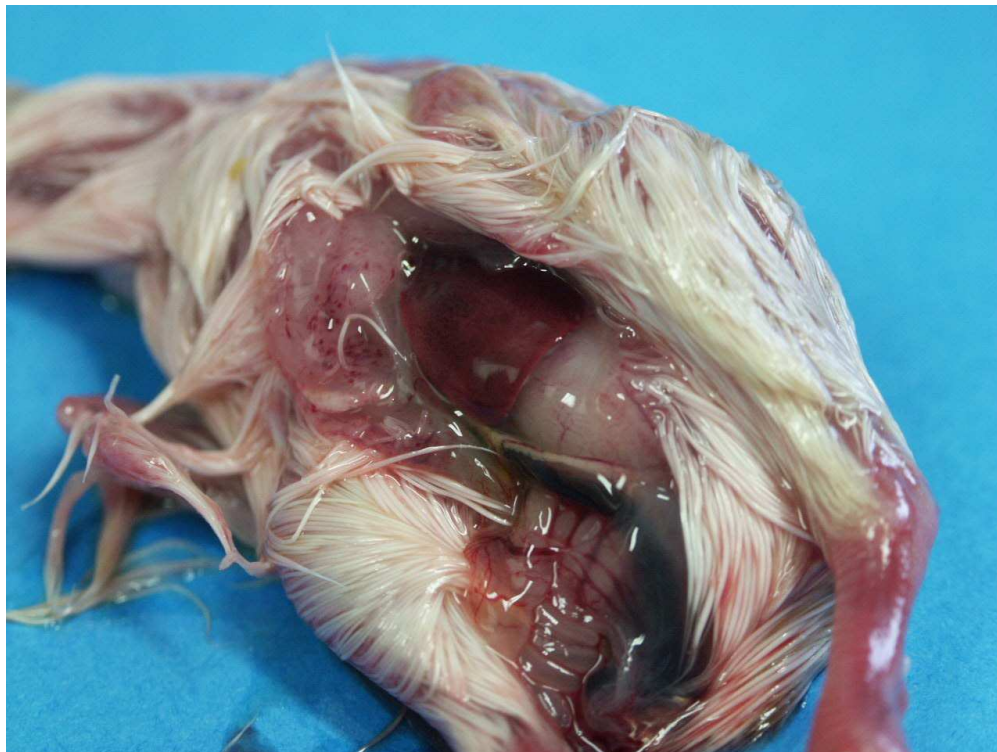

Fig. 2 Petechial haemorrhages in a turkey embryo 19 days after inoculation (27th day of incubation) with 2×10^2 CFU of *M. lipofaciens* (strain ML64).
451x338mm (72 x 72 DPI)

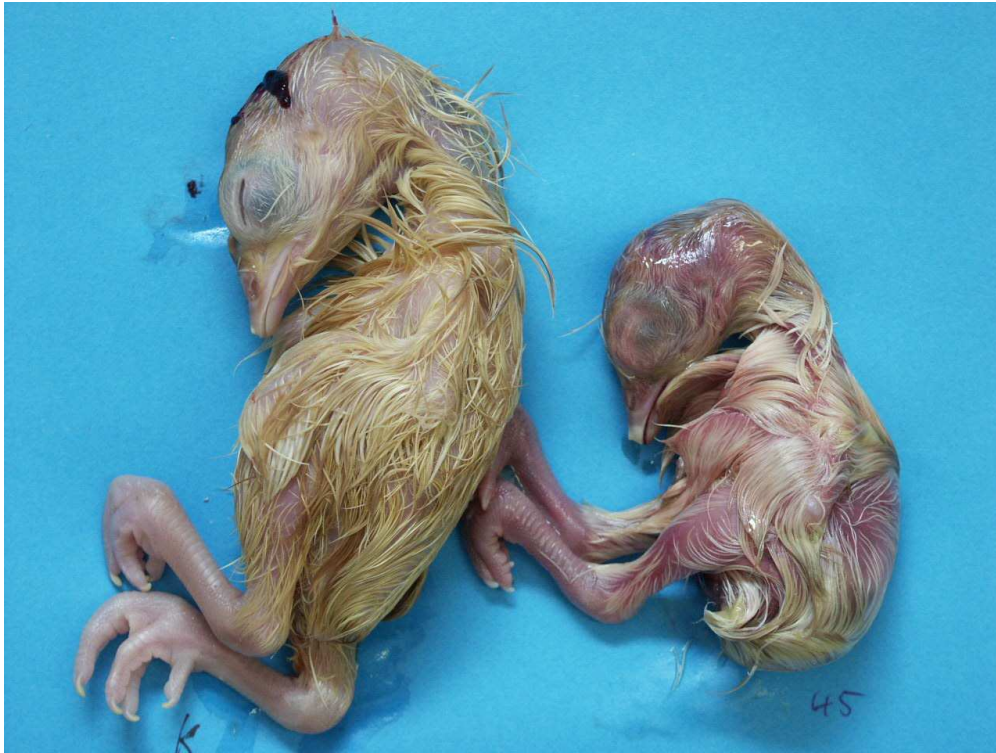
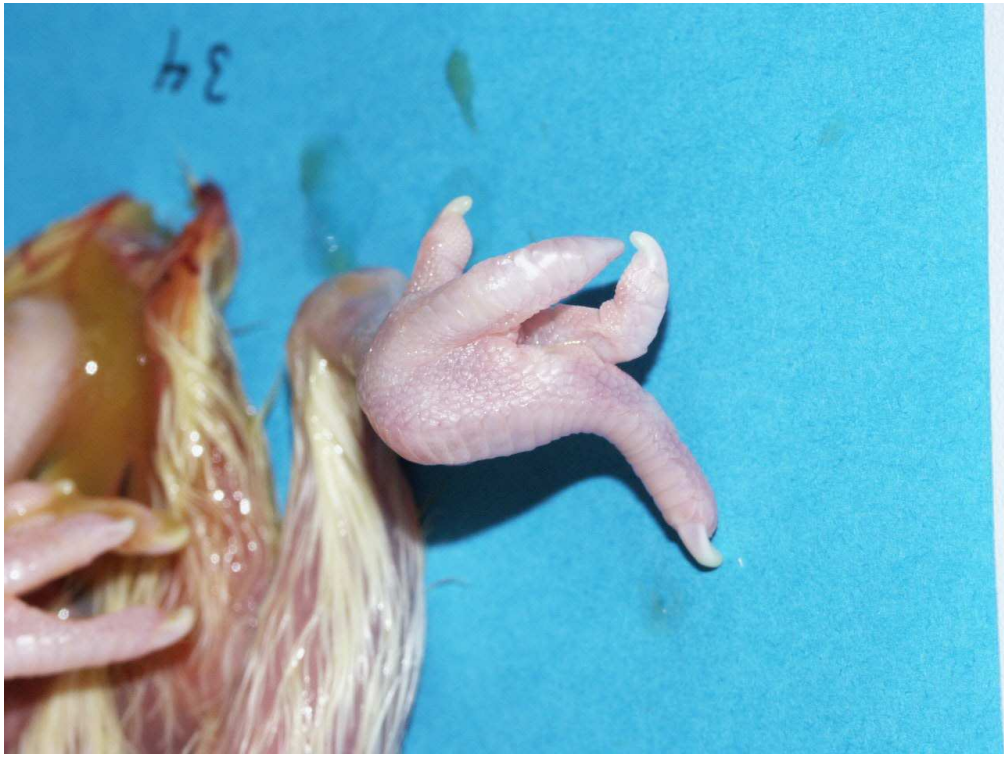
Fig. 3 Right: Dwarfed turkey embryo, 20 days after inoculation (28th day of incubation) with 2×10^2 CFU of *M. lipofaciens* (strain ML64). Left: Turkey embryo of the control group at same age for comparison.

451x338mm (72 x 72 DPI)



451x338mm (72 x 72 DPI)

View Only

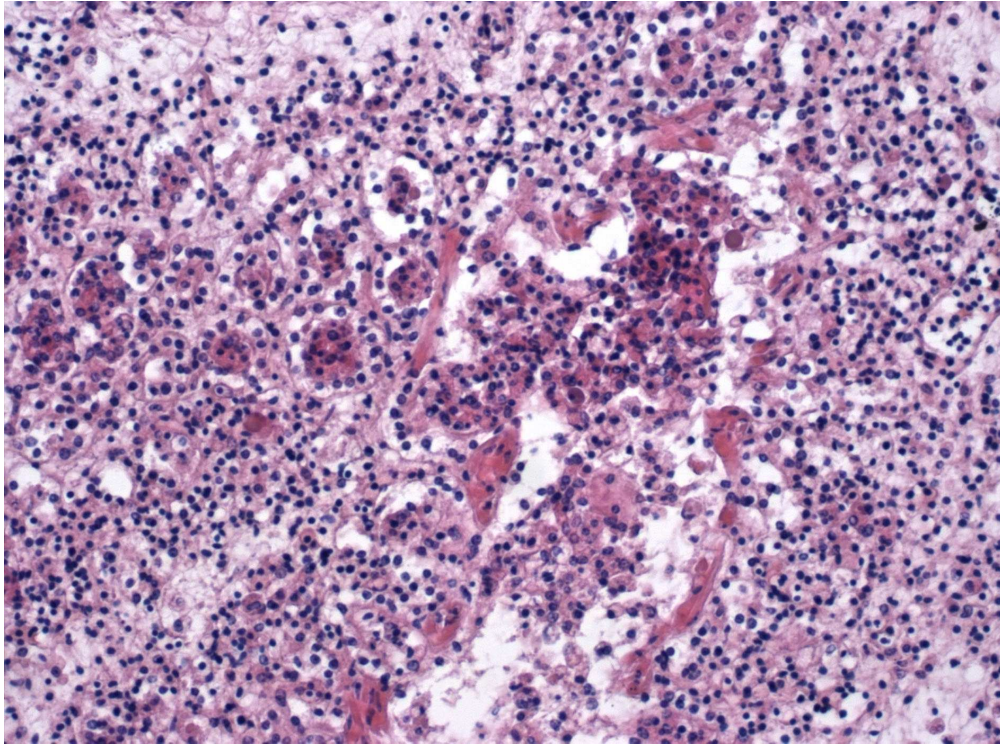


Fig. 5 Severe, multifocal, purulent to necrotizing broncho-pneumonia in a turkey embryo 20 days after inoculation (28th day of incubation) with 2×10^2 CFU of *M. lipofaciens* (strain ML64). HE-stained, 250x magnification. 160x118mm (300 x 300 DPI)