



**HAL**  
open science

## Pathobiology of highly pathogenic avian influenza virus (H5N1) infection in mute swans (*Cygnus olor*)

Nimród Pálmai, Károly Erdélyi, Ádám Bálint, Lázár Márton, Ádám Dán, Zoltán Deim, Krisztina Ursu, Brandon Z. Löndt, Ian H. Brown, Róbert Glávits

► **To cite this version:**

Nimród Pálmai, Károly Erdélyi, Ádám Bálint, Lázár Márton, Ádám Dán, et al.. Pathobiology of highly pathogenic avian influenza virus (H5N1) infection in mute swans (*Cygnus olor*). *Avian Pathology*, 2007, 36 (03), pp.245-249. 10.1080/03079450701341957 . hal-00540080

**HAL Id: hal-00540080**

**<https://hal.science/hal-00540080>**

Submitted on 26 Nov 2010

**HAL** is a multi-disciplinary open access archive for the deposit and dissemination of scientific research documents, whether they are published or not. The documents may come from teaching and research institutions in France or abroad, or from public or private research centers.

L'archive ouverte pluridisciplinaire **HAL**, est destinée au dépôt et à la diffusion de documents scientifiques de niveau recherche, publiés ou non, émanant des établissements d'enseignement et de recherche français ou étrangers, des laboratoires publics ou privés.



**Pathobiology of highly pathogenic avian influenza virus (H5N1) infection in mute swans (*Cygnus olor*)**

Journal:	<i>Avian Pathology</i>
Manuscript ID:	CAVP-2006-0077.R1
Manuscript Type:	Short Communication
Date Submitted by the Author:	24-Jan-2007
Complete List of Authors:	Pálmai, Nimród; Central Veterinary Institute, Histopathology Erdélyi, Károly; Central Veterinary Institute, Pathology of Domestic Mammals and Wildlife Diseases Bálint, Ádám; Central Veterinary Institute, Virology Márton, Lázár; Central Veterinary Institute, Virology Dán, Ádám; Central Veterinary Institute, Molecular Biology Deim, Zoltán; Central Veterinary Institute, Pathology of Domestic Mammals and Wildlife Diseases Ursu, Krisztina; Central Veterinary Institute, Molecular Biology Löndt, Brandon; Veterinary Laboratories Agency Brown, Ian; Veterinary Laboratories Agency Glávits, Róbert; Central Veterinary Institute, Histopathology
Keywords:	highly pathogenic avian influenza, H5N1, mute swan, pathology

SCHOLARONE™  
Manuscripts

CAVP-2006-0077

**Formatted:** Font: 12 pt, Not Bold**Formatted:** Right

Pathobiology of highly pathogenic avian influenza virus (H5N1) infection

**Formatted:** Font: 14 pt, Not Bold, Complex Script Font: 14 pt**Formatted:** Leftin mute swans (*Cygnus olor*)**Formatted:** Font: 14 pt, Complex Script Font: 14 ptNimród Pálmai<sup>1</sup>, Károly Erdélyi<sup>1\*</sup>, Ádám Bálint<sup>1</sup>, Lázár Márton<sup>1</sup>, Ádám Dán<sup>1</sup>,**Formatted:** Font: BoldZoltán Deim<sup>1</sup>, Krisztina Ursu<sup>1</sup>, Brandon Z. Löndt<sup>2</sup>, Ian H. Brown<sup>2</sup> and RóbertGlávits<sup>1</sup>Short title: Pathobiology of avian influenza (H5N1) in mute swans**Formatted:** Font: Not Bold<sup>1</sup>*Central Veterinary Institute, H-1149 Tábornok u. 2, Budapest, Hungary***Formatted:** Font: Italic**Formatted:** Font: Not Bold, Italic<sup>2</sup>*Veterinary Laboratories Agency (Weybridge), Addlestone, Surrey, United Kingdom***Formatted:** Font: Italic**Formatted:** Font: Not Bold, Italic

\*corresponding author:

**Formatted:** Font: ItalicReceived: 14 June 2006**Formatted:** Normal, Left, Line spacing: single**Formatted:** Font: Times New Roman**Formatted:** Font: Times New Roman, Italic

CAVP-2006-0077

Pathobiology of highly pathogenic avian influenza virus (H5N1) infection  
in mute swans (*Cygnus olor*)

Nimród Pálmai<sup>1</sup>, Károly Erdélyi<sup>1\*</sup>, Ádám Bálint<sup>1</sup>, Lázár Márton<sup>1</sup>, Ádám Dán<sup>1</sup>,  
Zoltán Deim<sup>1</sup>, Krisztina Ursu<sup>1</sup>, Brandon Z. Löndt<sup>2</sup>, Ian H. Brown<sup>2</sup> and Róbert  
Glávits<sup>1</sup>

**Abstract**

The results of pathological, virological and PCR examinations carried out on 35 mute swans (*Cygnus olor*) that succumbed to a highly pathogenic avian influenza virus (H5N1) infection during an outbreak in Southern Hungary are reported.

The most frequently observed macroscopic lesions included haemorrhages under the epicardium, in the proventricular and duodenal mucosa and pancreas; focal necrosis in the pancreas; myocardial degeneration; acute mucous enteritis; congestion of the spleen and lung and the accumulation of sero-mucinous exsudate in the body cavity.

Histopathological lesions comprised lymphocytic meningo-encephalomyelitis accompanied by gliosis and occasional perivascular haemorrhages; multi-focal myocardial necrosis with lympho-histiocytic infiltration; pancreatitis with focal necrosis; acute desquamative mucous enteritis; lung congestion and oedema; oedema of the tracheal mucosa and in young birds, the atrophy of the bursa of Fabricius as a result of lymphocyte depletion and apoptosis.

Formatted

Formatted: Normal, Line spacing: single

Formatted: Indent: First line: 36 pt

The observed lesions and the moderate to good body conditions were compatible with findings in acute HPAI infections of other bird species reported in the literature. Skin lesions and lesions typical for infections caused by strains of lower pathogenicity (LPAI) like emaciation or fibrinous changes in the reproductive and respiratory organs, sinuses and airsacs were not observed.

The H5N1 subtype avian influenza virus was isolated in embryonated fowl eggs from all cases and it was identified by classical and molecular virological methods.

## Introduction

The term “influenza” refers to an upper respiratory tract disease of humans, horses, pigs, numerous bird species, mink and sea mammals caused by viruses of the Orthomyxoviridae family (England et al., 1986; Kilbourne, 1987; Lvov et al., 1978; Webster et al., 1992). The manifestation of influenza virus infections in poultry ranges from subclinical infection through upper respiratory disease and lowered egg production to peracute, systemic disease leading to 100% mortality (Easterday et al., 1997; Swayne and Suarez, 2000).

Formatted

Formatted: Normal, Line spacing: single

The latter form is caused by highly pathogenic avian influenza virus (HPAI) strains belonging to the H5 and H7 subtypes (Perdue et al., 1999; Shortridge et al., 1998; Spackman et al., 2002; Swayne, 1997; Swayne and Halvorson, 2003). In wild birds, most infections are caused by LPAI viruses and are subclinical, possibly resulting in a carrier state (Swayne and Halvorson, 2003). However, as demonstrated in the recent European epidemic, HPAI subtypes like the Asian lineage H5N1 virus may cause lethal infections in some species.

Formatted: Indent: First line: 36 pt

The H5N1 HPAI strains circulating presently emerged from Guandong, China in 1996 spreading to Hong Kong in 1997, then first into Eastern Asia (Webster et al., 2006) and then gradually west to Mongolia, Kazakhstan, Russia, Romania, Turkey, Greece, Croatia (ProMED-mail, 2006; Terregino et al., 2006) and recently to many countries of the European Union, including Hungary.

Certain observations on the susceptibility of swans to influenza viruses and their possible epidemiological role were reported from Japan in 1982 (Otsuki et al., 1982) and in connection with the present European epidemics (Terregino et al., 2006; DEFRA news release at: <http://www.defra.gov.uk/news/2006/060406c.htm>).

However, detailed descriptions of the course, pathogenesis and pathological lesions caused by H5N1 infection in swans are not available.

## Materials and Methods

Carcasses of 3300 wild and domestic birds, belonging to a wide range of species (including 165 mute swans), were examined between 01.01. and 31. 03. 2006., within the scope of the avian influenza monitoring programme in Hungary. In this period HPAI infection was diagnosed in 67 mute swans, 2 black-headed gulls (*Larus ridibundus*), 1 cormorant (*Phalacrocorax carbo*), 1 coot (*Fulica atra*) and 1 mallard (*Anas platyrhynchos*). All cases occurred either on the river Danube or in nearby areas, between the town of Mohács in the South and Szentendre in the North. The bulk of the positive cases came from one outbreak in the south of the country.

From the 165 mute swan carcasses submitted for post mortem examination to the Central Veterinary Institute during February and March 2006 we performed necropsy and histopathological investigations on 35 randomly selected cases according to an extended, more detailed protocol. All these birds were infected with an H5N1 strain of HPAI and died during the epidemic affecting an area along the left bank of the river Danube in Southern Hungary near the village of Nagybaracska.

**Gross pathology and histopathology.** Necropsy was performed on all submitted cases. Tissue samples were routinely taken from the brain, heart and pancreas. A panel of 35 cases was sampled according to a detailed protocol, comprising the above organs and the trachea, lung, spinal chord, pectoral and thigh muscles, liver, spleen, kidney, proventriculus, small and large intestine and when available, bursa Fabricii.

Formatted

Formatted: Normal, Line spacing: single

Formatted: Indent: First line: 36 pt

Deleted: ¶

Formatted: Font: Not Italic

Tissues were fixed in 10% v/v buffered formaldehyde solution embedded into paraffin blocks and then cut into 3-4  $\mu\text{m}$  thin sections and stained with hematoxylin-eosin (H.-E.).

**Preparation of samples for virus isolation.** For isolation and characterisation of the highly pathogenic avian influenza strains, we followed OIE guidelines (Alexander, 2000). Tissue samples (lung, trachea and intestine) were homogenised in phosphate-buffered saline solution with an enclosed blender or using pestle and mortar. 10-20% w/v suspensions were prepared in phosphate buffered saline containing antibiotics and antimycotics (0.25 mg/ml gentamycin, 5000 IU/ml nystatin). Suspensions were incubated for 1–2 hours at room temperature and then centrifuged at 1000g for 10 minutes.

Formatted

Formatted: Normal, Line spacing: single

Deleted: ¶

**Virus isolation and characterisation.** From each sample, 100  $\mu\text{l}$  aliquots of the supernatant were inoculated into the allantoic sacs of at least five embryonated SPF fowl eggs of 9–11 days' incubation. The eggs were incubated at 35–37°C for 4–7 days. Eggs containing dead or dying embryos, and all eggs remaining healthy at the end of the incubation period, were chilled to 4°C and the allantoic fluids were tested for haemagglutination (HA) activity. Fluids, which gave negative reactions, were passaged in at least one further batch of eggs. Determination of the haemagglutination subtype was carried out with reference polyclonal sera (VLA Weybridge, UK) in haemagglutination inhibition tests. To rule out cross-reactions, two H5 (H5N2, H5N7) and two H7 (H7N1 and H7N7) sera were applied.

Deleted: ¶

**RT-PCR and sequencing.** Parallel with the classical virological methods all samples were tested by molecular methods recommended by the EU Community Reference

Deleted: ¶



Laboratory. Influenza virus type A was identified with the real-time PCR method described by Spackman et al. (2002). The H5 gene was also identified by real-time PCR and conventional PCR analysis utilising the H5-kha-1/H5-kha-3 and/or J3/B2A primer pairs.

For phylogenetic analysis, the HA1 fragment for the A/mute swan/Hungary/3472-I/2006 isolate was amplified with gene-specific primers S1 (5'-AGCAGGGGTATAATCTCTCA-3') & B2a (5'-TTTTGTCAATGATTGAGTTGACCTTATTGG-3') with the use of One-step RT-PCR kits (QIAGEN, UK). PCR amplicons were visualised by ethidium bromide staining after 2% w/v agarose gel (Invitrogen, UK) electrophoresis and purified using QIAquick gel extraction kits (QIAGEN, UK). RT-PCR products were sequenced by cycle-sequencing reactions using ABI Terminator cycle sequencing V3.1 chemistry on a ABI Prism™ 3130xl Genetic Analyser (Applied Biosystems, UK).

**Sequence analysis.** Sequence data was assembled and edited using the Lasergene version 7 SEQMAN software (DNASTAR Inc, USA). Sequence alignments, Neighbour-joining phylogenetic trees and nucleotide distance matrices were performed using the Lasergene version 7 MEGALIGN software (DNASTAR Inc, USA). For phylogenetic tree construction and comparison, sequences generated from isolates submitted to VLA Weybridge as part of its EU/OIE/FAO Reference Laboratory status or obtained from the Influenza Sequence Database (ISD), Los Alamos, USA (Macken, C., Lu, H., Goodman, J., & Boykin, L, 2001) were included.

## Results

Formatted: Indent: First line: 36 pt

Deleted: ¶

Formatted

Formatted: Normal, Line spacing: single

**Gross pathology and histopathology.** The frequencies of the occurrence of gross- and histopathological lesions in 35 HPAI infected swans are presented in Table 1.

The majority of swans submitted for post mortem examination were in moderate to good body condition, which is one of the indications of the acute course of the disease. The most frequent gross lesions were: haemorrhages (34/35) and focal necrosis (19/35) within the parenchyma of the pancreas, focal haemorrhages under the epicardium (30/35) and in the mucous membrane of the proventriculus (25/35) and duodenal mucosa (21/35), focal myocardial degeneration (12/35), accumulation of sero-mucinous exudate in the body cavity (9/35), acute mucous enteritis (35/35), and congestion of the lung (35/35) and spleen (35/35) (Figures 1-3).

The most consistent histological lesions were: lymphocytic meningoencephalitis (35/35) or meningoencephalomyelitis (17/35) with focal gliosis, neuronal necrosis and neuronophagia (Figure 4), multifocal degeneration and necrosis in the heart (29/35) (Figure 5), pancreas (27/35) (Figure 6), liver (16/35), and less frequently in skeletal muscles (14/35) congestion and oedema in the lung (35/35). In juvenile birds lymphocyte depletion and apoptosis was regularly observed in the bursa of Fabricius (22/22).

**Virology.** Virological investigations confirmed HPAI infections in 67 swan carcasses. Inoculated chicken embryos died within 30 hours, suggesting the presence of HPAI. The haemagglutination titres of the virus isolates ranged from 32 to 1024. In each case, haemagglutination activity of the isolates were inhibited by the H5N2 and H5N7 antisera, but were not affected by H7N1, H7N7 and Newcastle disease polyclonal antisera.

Deleted: ¶

Formatted: Heading 3

Formatted: Font: Not Italic,  
Complex Script Font: Not Italic

Formatted: Font: Not Italic

Formatted: Indent: First line: 36 pt

Deleted: ¶

**Genetic analysis.** All results obtained by classical virological methods were confirmed by the molecular methods described in materials and methods. All 67 H5 positive samples were sequenced and pathotyped as HPAI viruses.

Deleted: ¶

DNA sequencing of the HA1 fragment (967nt) of the haemagglutinin gene of isolate A/mute swan/Hungary/3472-I/2006 identified a cleavage site motif (PQGERRRKKR\*GLF) consistent with H5N1 HPAI viruses isolated in eastern parts of Europe and South East Asia during 2005/2006.

Formatted: Indent: First line: 36 pt

Genetic analysis of A/mute swan/Hungary/3472-I/2006 revealed very high nucleotide identities (99.9%) and close grouping phylogenetically with viruses isolated from wild bird species, especially including swans and ducks from Northern Europe and the Balkans in late 2005 and early 2006 -A/swan/Germany/R65/2006 and A/cygnus olor/Croatia/1/2005 respectively (data not shown). These results indicate that the viruses analysed in the present study appear to have been similar to others of wild bird origin, in the same lineage as the progenitor viruses isolated at Qinghai lake, China in April 2005.

## Discussion

Macroscopic and histopathological changes caused by avian influenza viruses of all pathogenicity levels are widely reported in the literature. Most of these reports present observations on natural and experimental infections of domestic fowl and turkeys (Beard and Helfer, 1972; Capua et al., 2000; Capua and Marangon, 2000; Cooley et al., 1989; Jungherr et al., 1946; Krohn, 1925; Laudert et al., 1993; Perdue et al., 1999; Swayne et al., 1992; Swayne and Halvorson, 2003; Swayne and Slemons, 1994; Swayne and Slemons 1995; Swayne and Suarez, 2000; Tanyi, 1997; Webster et al., 1992). There are also a few reports on avian influenza infections in domestic ducks,

Formatted

Formatted: Normal, Line spacing: single

geese, emus and rheas (Alexander, 1982; Cooley et al., 1989; Laudert et al., 1993; Swayne and Halvorson, 2003; Tanyi, 1997). However, no detailed descriptions of the pathological lesions caused by H5N1 infection in swans are available.

In chicken and turkeys macroscopic and microscopic lesions caused by HPAI infections are dominated by acute haemorrhages, oedema and necrosis (e.g. oedema in the skin of the head, neck and legs, in lungs; haemorrhages in the skin, under serous membranes, in the mucosa, and pectoral muscles; necrosis in the skin, pancreas, spleen and heart) (Acland et al., 1984; Alexander, 1982; Alexander, 1993; Kobayashi et al., 1996; Swayne and Halvorson, 2003; Swayne and Suarez, 2000). Specific lesions, apart from signs of circulatory collapse, may be absent in peracute cases. The most important microscopic lesions are lymphocytic encephalitis and meningitis, focal necrosis and focal lympho-histiocytic infiltration of the myocardium, focal necrosis in the pancreas, and occasionally in other organs e.g. lungs, lymphatic organs and skeletal muscles. Lesions of the respiratory tract may vary from mild to severe.

We found, that the pathological changes observed in swans were similar to those described in other bird species observed in HPAI infections. However, lesions of the skin and head appendages observed in HPAI infections of domestic fowl were not present (e.g. cyanosis, haemorrhages, necrosis, periorbital oedema). Fibrinopurulent inflammation of the upper respiratory tract, sinuses, air sacs or reproductive organs which are typical for infections by AI strains of low pathogenicity (Hooper and Selleck, 1998; Mo et al., 1997) were also absent.

LPAI strains mainly cause protracted disease accompanied by emaciation (Hooper and Selleck, 1998; Mo et al., 1997; Swayne and Halvorson, 2003). Gross lesions include seromucinous to purulent inflammation in nasal and perinasal cavities, the conjunctiva, trachea and lung, which are frequently accompanied by fibrinous air-

Formatted: Indent: First line: 36 pt

Formatted: Indent: First line: 36 pt

sacculitis and peritonitis, inflammation of ovaries, oviducts and enteritis. These latter lesions are usually the result of secondary bacterial infections (e.g. *Pasteurella multocida*, *E. coli*). Necrotic pancreatitis is less frequent in chicken than in turkeys.

In our experience, the gross lesions and histopathological findings described above, especially lesions in the brain, spinal cord, heart and pancreas, are strongly suggestive of HPAI infection in mute swans, therefore histopathology may be considered an important diagnostic tool.

Our pathological observations suggest that mute swans are highly susceptible to infection with the H5N1 subtype of HPAI, which results in an acute illness and high mortality. Therefore, the chances for the development of a protracted disease and a prolonged virus carrier state are unlikely in this species. However, this hypothesis will have to be confirmed by further studies of the clinical-virology of the disease in this species. We believe that these observations provide an important basis for the assessment of the role of swans in the epidemiology of HPAI infections.

Formatted: Indent: First line: 36 pt

**References**

Acland, H.M., Silverman, L.A. & Eckroade, R.J. (1984). Lesions in broiler and layer chickens in an outbreak of highly pathogenic avian influenza virus infection.

*Veterinary Pathology*, 21, 564-569.

Formatted: Font: Italic

Alexander, D.J. (1982). Avian influenza. Recent developments. *Veterinary Bulletin*,

52, 341-359.

Formatted: Font: Italic

Alexander, D.J. (1993). Orthomyxovirus Infections. In J.B. McFerran & M.S. McNulty (Eds). *Virus infections of birds*, Elsevier Science, London, 287-316.

Alexander, D.J. (2000). Highly pathogenic avian influenza (fowl plague). In *OIE Manual of standards for diagnostic tests and vaccines*. List A and B diseases of mammals, birds and bees. 4-th ed., *Office International des Epizooties* (pp. 212-220). Paris, France.

Beard, C.W. & Helfer, D.H. (1972). Isolation of two turkey influenza viruses in

Oregon. *Avian Diseases*, 16, 1133-1136.

Formatted: Font: Italic

Capua, I., Mutinelli, F., Marangon, S. & Alexander, D.J. (2000). H7N1 avian influenza in Italy (1999 to 2000) in intensively reared chickens and turkeys. *Avian*

*Pathology*, 29, 537-543.

Formatted: Font: Italic

Capua, I. & Marangon, S. (2000). The avian influenza epidemic in Italy, 1999-2000:

A review. *Avian Pathology*, 29: 289-294.

Formatted: Font: Italic

Cooley, A.J., Van Campen, H., Philpott, M.S., Easterday, B.C. & Hinshaw, V.S.

(1989). Pathological lesions in the lungs of ducks infected with influenza A viruses. *Veterinary Pathology*, 26, 1-5.

Formatted: Font: Italic

Easterday, B.C., Hinshaw, V.S. & Halvorson, D.A.: Influenza. In Calnek, B.W.,

Barnes, H.J., Beard, C.W., McDougald, L.R. & Saif, Y.M. (eds). (1997). *Diseases of Poultry*, 10th ed. Iowa State University Press: Ames, IA, 583-605.

England, L., Klingeborn, B. & Mejerland, T. (1986). Avian influenza A virus causing an outbreak of contagious interstitial pneumonia in mink. *Acta Veterinaria Scandinavica*, *27*, 497-504.

Formatted: Font: Italic

Hooper, P & Selleck, P.: Pathology of low and high virulent influenza virus infections. In: Swayne, D.E. & Slemons, R.D. (eds). (1998). Proceedings of the *Fourth International Symposium on Avian Influenza of the U.S. Animal Health Association* (pp. 134-141). Richmond, VA, USA.

Jungherr, E.L., Tyzzer, E.E., Brandly, C.A. & Moses H.E. (1946). The comparative pathology of fowl plague and Newcastle disease. *American Journal of Veterinary Research*, *7*, 250-288.

Kilbourne, E.D. (1987). *Influenza*. Plenum (pp. 1-359) New York, USA

Kobayashi, Y., Horimoto, R., Kawaoka, Y., Alexander, D.J. & Itakura, C. (1996). Pathological studies of chickens experimentally infected with two highly pathogenic avian influenza viruses. *Avian Pathology*, *25*, 285-304.

Formatted: Font: Italic

Krohn, L.D. (1925). A study on the recent outbreak of a fowl disease in New York City. *Journal of the American Veterinary Medicine Association* *20*, 146-170.

Formatted: Font: Italic

Laudert, E., Halvorson, D., Sivanandan, V. & Shaw, D. (1993). Comparative evaluation of tissue tropism characteristics in turkeys and mallard ducks after intravenous inoculation of type A influenza viruses. *Avian Diseases* *37*, 773-780.

Formatted: Font: Italic

Lvov, D.K., Zdanov, V.M., Sazonov, A.A., Braude, N.A., Vladimirtceva, E.A., Agafonova, L.V., Skljanskaja, E.I., Kaverin, N.V., Reznik, V.I., Pysina, R.V., Oserovic, A.M., Berzin, A.A., Mjasnikova, I.A., Podcernjaeva, R.Y., Klimenko, S.M., Andrejev, V.P. & Yakhno, M.A. (1978). Comparison of influenza viruses isolated from man and from whales. *Bulletin of the World Health Organization*, *56*, 923-930.

Formatted: Font: Italic

Macken, C., Lu, H., Goodman, J., & Boykin, L., "The value of a database in surveillance and vaccine selection." in *Options for the Control of Influenza IV*. A.D.M.E. Osterhaus, N. Cox & A.W. Hampson (Eds.) Amsterdam: Elsevier Science, 2001, 103-106.

Mo, I.P., Brugh, M., Fletcher, O.J., Rowland, G.N. & Swayne, D.E. (1997). Comparative pathology of chickens experimentally inoculated with avian influenza viruses of low and high pathogenicity. *Avian Diseases* *41*, 125-136.

Formatted: Font: Italic

Otsuki, K., Kawaoka, Y., Nakamura, T. & Tsubokura, M. (1982). Pathogenicity for chickens of avian influenza viruses isolated from whistling swans and a black-tailed gull in Japan. *Avian Diseases* *26*, 314-320.

Formatted: Font: Italic

Perdue, M.L., Suarez, D.L. & Swayne, D.E. (1999). Avian Influenza in the 1990s. *Poultry and Avian Biology Reviews*, *11*, 1-20.

Formatted: Font: Italic

ProMED-mail. Avian influenza - Eurasia (11): Romania, H5N1. ProMED-mail 2005; 15 Oct: 20051015.3009. <<http://www.promedmail.org>>. Accessed 06 June 2006.

ProMED-mail. Avian influenza - Eurasia (23): Croatia, H5N1, swan. ProMED-mail 2005; 21 Oct: 20051021.3076. <<http://www.promedmail.org>>. Accessed 06 June 2006.

ProMED-mail. Avian influenza - Eurasia (05): Turkey, H5N1. ProMED-mail 2005; 13 Oct: 20051013.2989. <<http://www.promedmail.org>>. Accessed 06 June 2006.

ProMED-mail. Avian influenza - worldwide (10): Nigeria, Greece, Italy. ProMED-mail 2006; 11 Feb: 20060211.0461. <<http://www.promedmail.org>>. Accessed 06 June 2006.

Shortridge, K.F., Zhou, N.N., Guan, Y., Gao, P., Ito, T., Kawaoka, Y., Kodihalli, S., Krauss, S., Markhill, D., Murti, G., Norwood, M., Senne, D., Sims, L., Takada, A.



- & Webster, R.G. (1998). Characterization of avian H5N1 influenza viruses from poultry in Hong Kong. *Virology*, *252*, 331-342. Formatted: Font: Italic
- Spackman, E., Senne, D. A., Myers T. J., Bulaga, L. L., Garber, L. P., Perdue, M. L., Lohman, K., Daum, L. T. & Suarez D. L. (2002). Development of a Real-Time Reverse Transcriptase PCR Assay for Type A Influenza Virus and the Avian H5 and H7 Hemagglutinin Subtypes. *Journal of Clinical Microbiology*, *40*, 3256–3260. Formatted: Font: Italic
- Swayne, D.E. (1997). Pathobiology of H5N1 Mexican avian influenza virus infections of chickens. *Veterinary Pathology*, *34*, 557-567. Formatted: Font: Italic
- Swayne, D.E., Ficken, M.D. & Guy, J.S. (1992). Immunohistochemical demonstration of influenza A nucleoprotein in lungs of turkeys with natural and experimental influenza respiratory disease. *Avian Pathology*, *21*, 547-557. Formatted: Font: Italic
- Swayne, D.E. & Halvorson, D.A. (2003). Influenza. In: Y.M. Saif (ed.) *Diseases of Poultry* 11th edn (pp. 135-160). Ames: Iowa State Press.
- Swayne, D.E. & Slemons, R.D. (1994). Comparative pathology of a chickens origin and two duck-origin influenza virus isolates in chickens: The effect of route of inoculation. *Veterinary Pathology*, *31*, 237-245. Formatted: Font: Not Italic
- Swayne, D.E. & Slemons, R.D. (1995). Comparative pathology of intravenously inoculated wild duck- and turkey-origin type A influenza virus in chickens. *Avian Diseases*, *39*, 74-84. Formatted: Font: Italic
- Swayne, D.E. & Suarez, D. (2000). Highly pathogenic avian influenza. Scientific and Technical Review, *Office International des Epizooties*, *19*, 463-482. Formatted: Font: Italic
- Tanyi J. (1997). Egyes állatbetegségek diagnosztikai eredményeinek és járványtanának értékelése. [Evaluation of diagnostic results and epidemiology of selected animal diseases]. Doctoral Thesis, Debrecen, Hungary

Terregino, C., Milani, A., Capua, I., Marino, A. & Cavaliere, N. (2006). Highly pathogenic avian influenza H5N1 subtype in mute swans in Italy. (Letter) *Veterinary Record*, 8, 491.

Formatted: Font: Italic

Webster, R.G., Bean, W.J., Gorman, O.T., Chambers, T.M. & Kawaoka, Y. (1992). Evolution and ecology of influenza A viruses. *Microbiology Review*. 56, 152-179.

Formatted: Font: Italic

Webster, R.G., Peiris, M., Chen, H. & Guan, Y. (2006). H5N1 outbreaks and enzootic influenza. *Emerging Infectious Diseases*. 12, 123-128.

Formatted: Line spacing: Double

Formatted: Font: Italic

**Table 1:** Frequency of occurrence of macroscopic and microscopic lesions caused by HPAI (H5N1 subtype) infection in 35 mute swans.

		LESIONS	Number of affected birds (n=35)
GROSS LESIONS		-good	10
	Body condition:	-moderate	22
		-poor	3
	Pancreas:	-haemorrhages	34
		-necrosis	19
	Heart:	-haemorrhages under the epicardium	30
		-focal myocardial degeneration	12
	Lung:	-congestion	35
		-oedema	10
	Body cavity:	-sero-mucinous exsudate	9
	Proventriculus:	-haemorrhages	35
		-mucous enteritis	35
	Intestines:	-haemorrhages in the duodenal mucosa	21
	Spleen:	-congestion	35
HISTOPATHOLOGICAL LESIONS	Brain:	-lymphocytic meningo-encephalitis	35
		-perivascular haemorrhages	9
	Spinal cord:	-mild lymphocytic myelitis	8
	Heart:	-focal myocardial necrosis	29
		-lympho-histiocytic infiltration	31
	Pancreas:	-necrotic foci	27
		-lympho-histiocytic infiltration	19
	Lung:	-congestion	35
		-interstitial oedema	35
	Trachea:	-mucosal oedema	21
	Liver:	-interstitial lympho-histiocytic infiltration	24
		-necrotic foci	16
	Intestines:	-desquamative mucous enteritis	35
		-haemorrhages	29
Bursa of Fabricius (n=22)*:	-lymphocyte depletion	22	
	-apoptosis	22	
Skeletal muscle:	-focal myocyte degeneration, necrosis	14	
	-haemorrhages	17	

\*Samples originating from 22 juvenile birds.

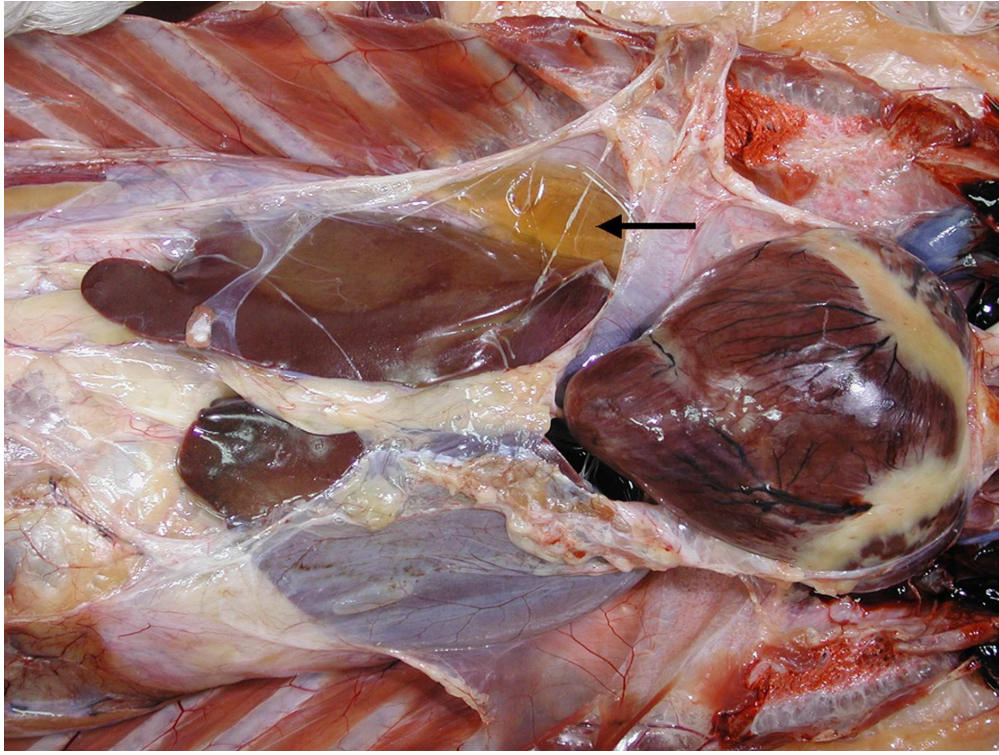

Figure 1. Sero-mucinous exudate in the body cavity (↑)  
80x60mm (600 x 600 DPI)

View Only

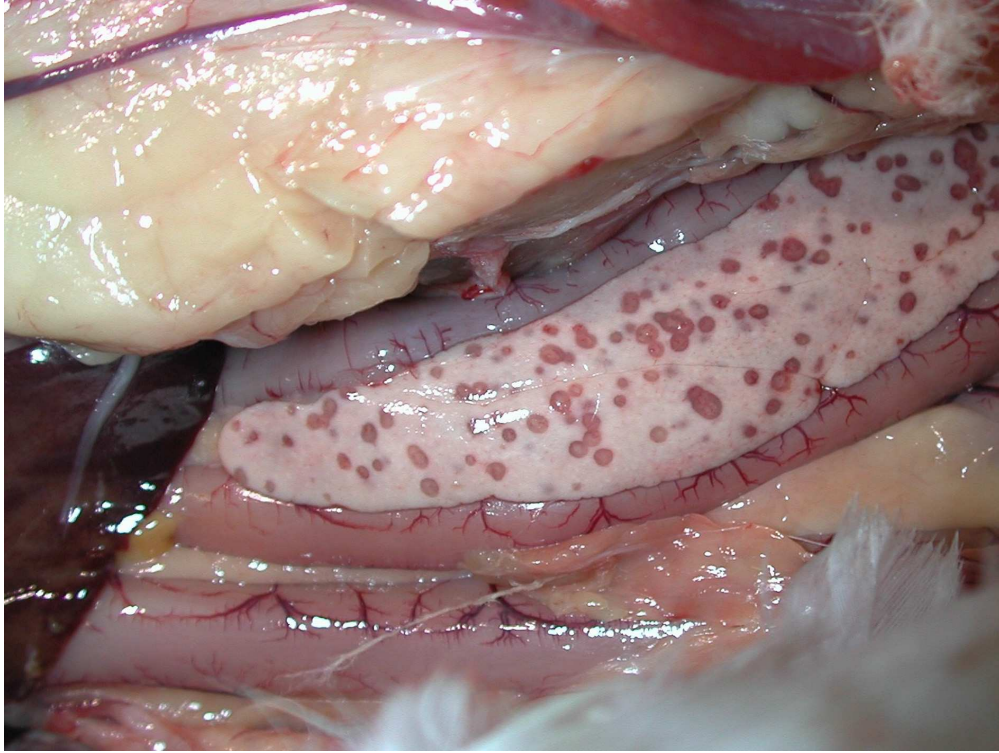


Figure 2. Necrotic foci and haemorrhages in the pancreas  
80x60mm (600 x 600 DPI)

Preview Only

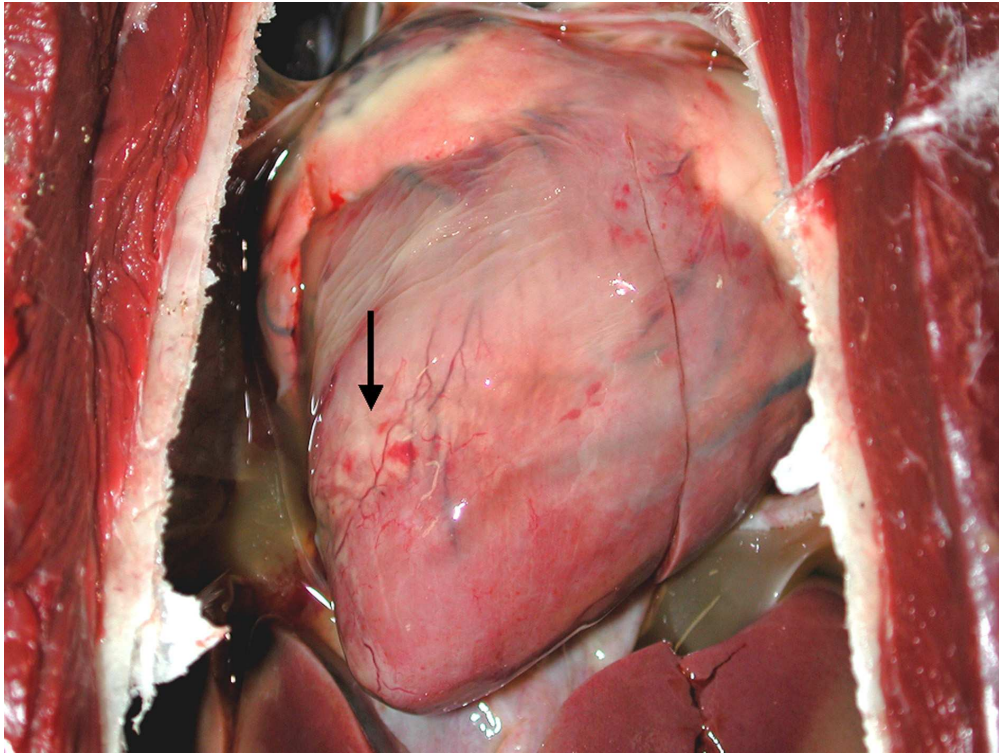


Figure 3. Haemorrhages and areas of focal degeneration in the myocard (↑)  
80x60mm (600 x 600 DPI)

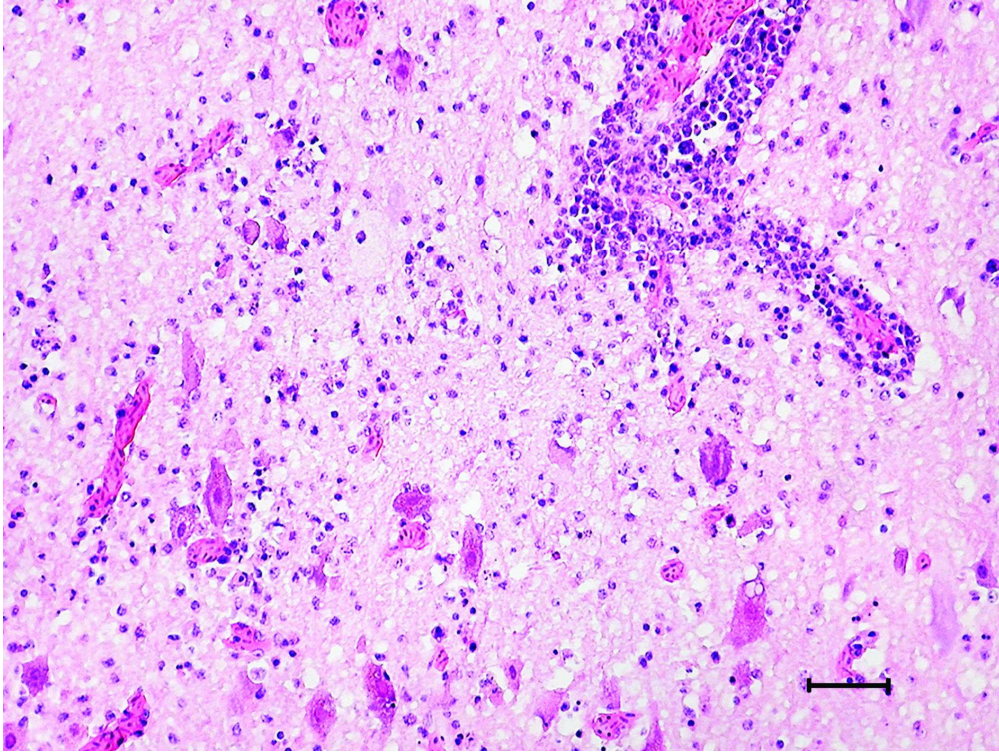


Figure 4. Lymphocytic perivascular cuffing, diffuse glial cell proliferation and neuronal degeneration in the cerebral cortex. (Haematoxylin-eosin (H.-E.)). Bar = 50µm  
80x60mm (600 x 600 DPI)

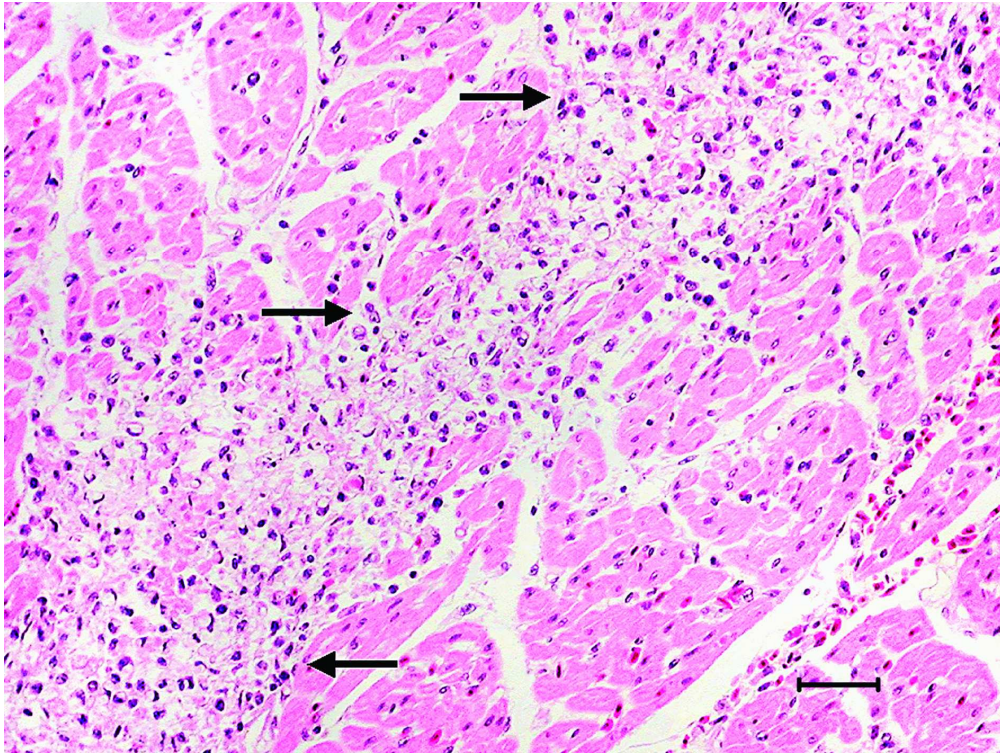


Figure 5. Degeneration and necrosis of myocardial cells and lympho-histiocytic infiltration (↑) in the myocardium. (H.-E.), Bar = 50µm  
80x60mm (600 x 600 DPI)



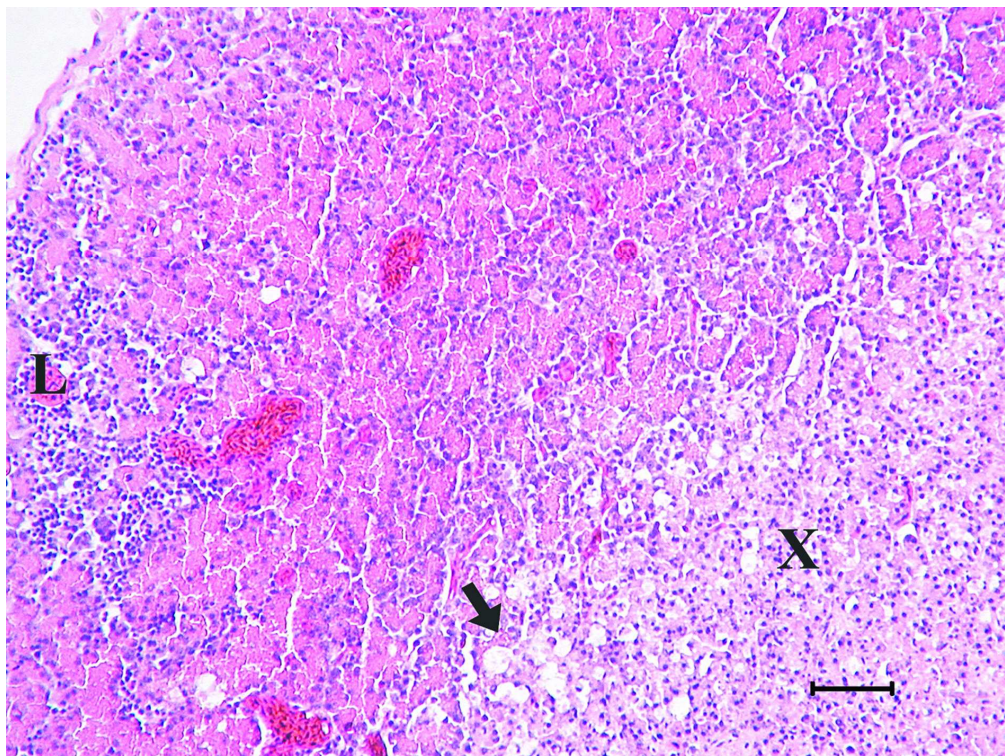


Figure 6. Necrotic areas (↑), vacuolar degeneration (X), and lympho-histiocytic infiltration (L) in the pancreas. (H.-E.), Bar = 100µm  
80x60mm (600 x 600 DPI)

ew Only