



HAL
open science

Clinical, mycological and pathological findings in turkeys experimentally infected by *Aspergillus fumigatus*

Francoise Femenia, Jean-Jacques Fontaine, Sybille Lair-Fullerenger, Nadia Berkova, Dominique Huet, Narcisse Towanou, Farasoa Rakotovao, Oumaima Granet, Guillaume Le Loch, Pascal Arné, et al.

► To cite this version:

Francoise Femenia, Jean-Jacques Fontaine, Sybille Lair-Fullerenger, Nadia Berkova, Dominique Huet, et al.. Clinical, mycological and pathological findings in turkeys experimentally infected by *Aspergillus fumigatus*. *Avian Pathology*, 2007, 36 (03), pp.213-219. 10.1080/03079450701332337 . hal-00540076

HAL Id: hal-00540076

<https://hal.science/hal-00540076>

Submitted on 26 Nov 2010

HAL is a multi-disciplinary open access archive for the deposit and dissemination of scientific research documents, whether they are published or not. The documents may come from teaching and research institutions in France or abroad, or from public or private research centers.

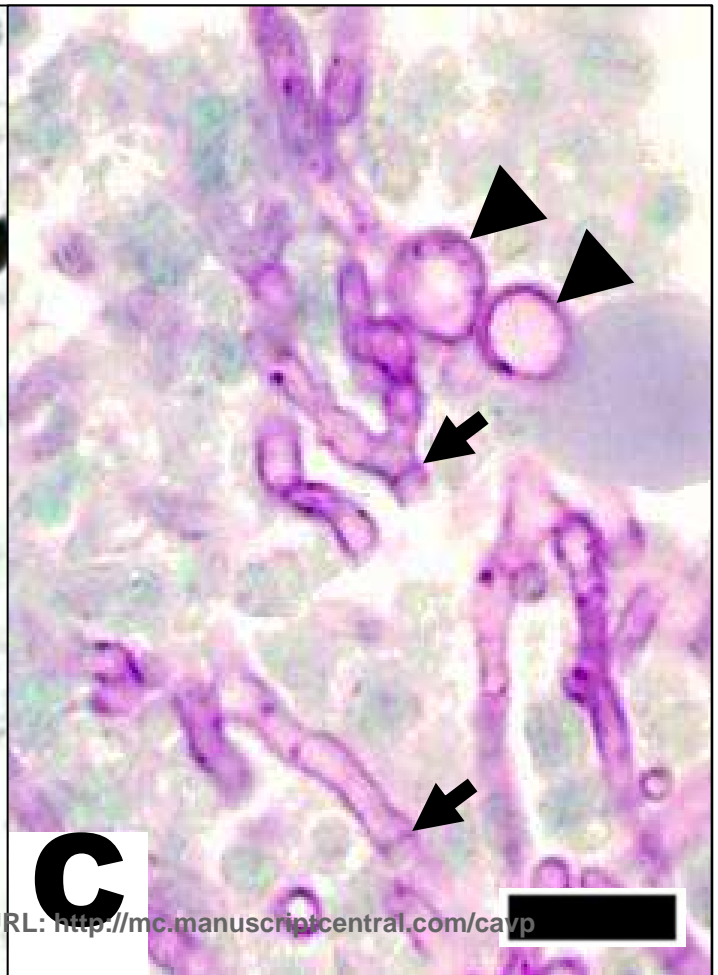
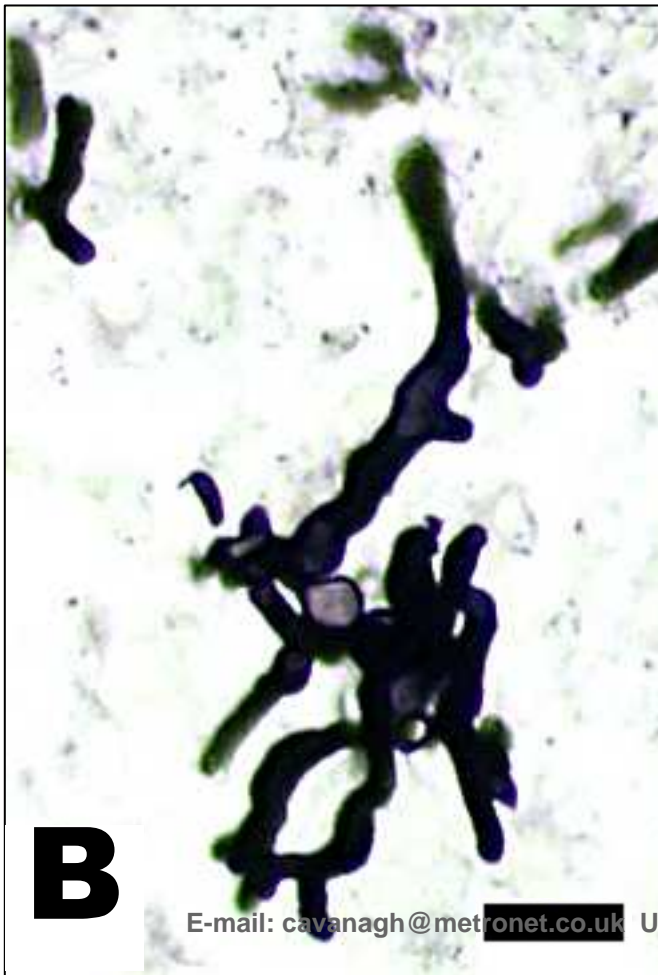
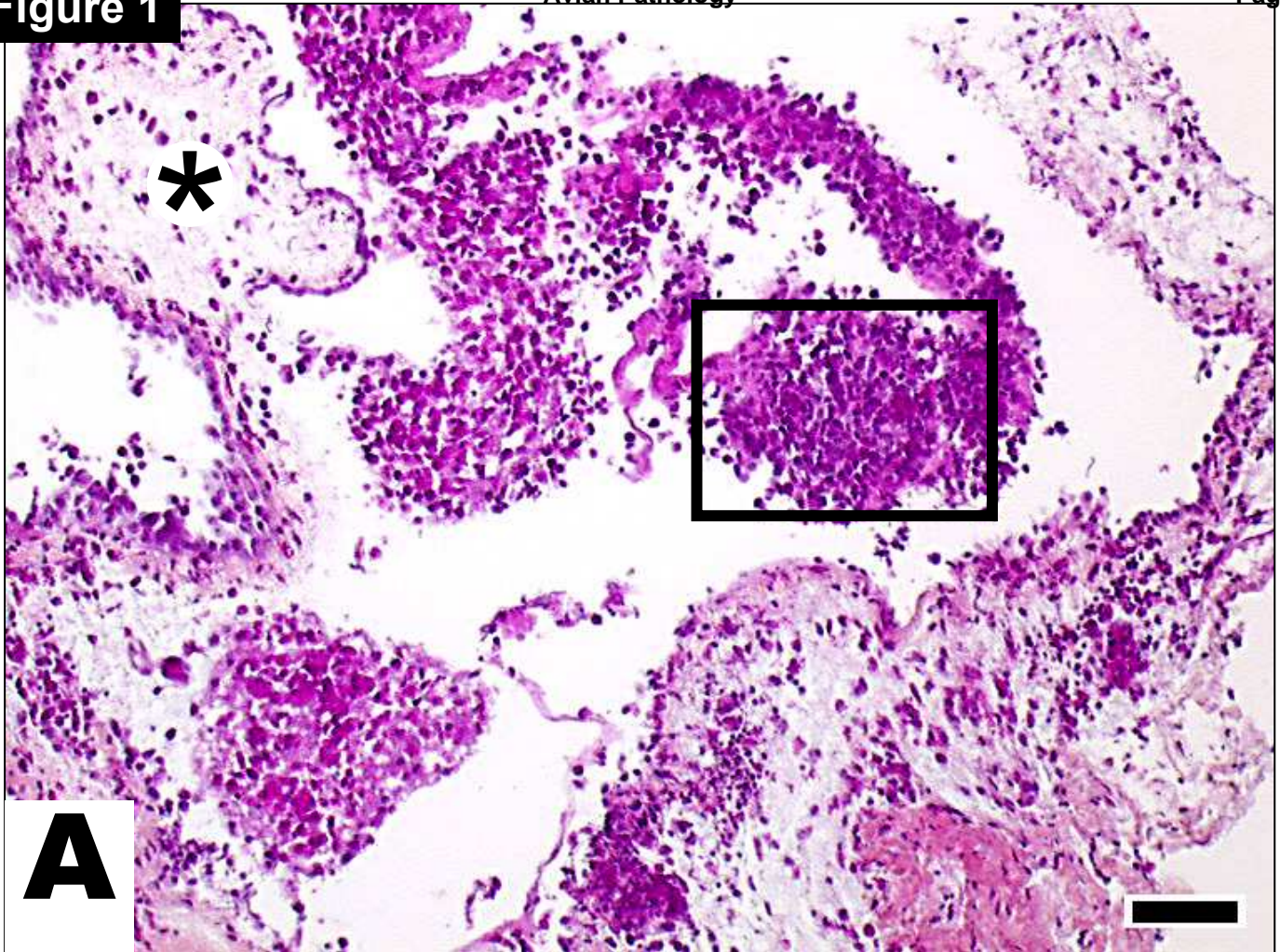
L'archive ouverte pluridisciplinaire **HAL**, est destinée au dépôt et à la diffusion de documents scientifiques de niveau recherche, publiés ou non, émanant des établissements d'enseignement et de recherche français ou étrangers, des laboratoires publics ou privés.

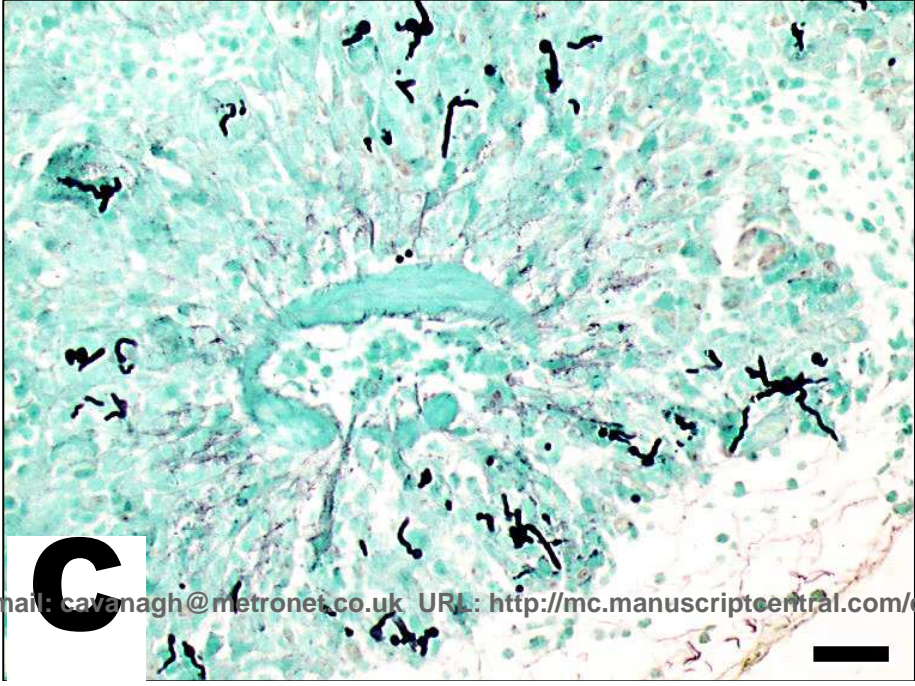
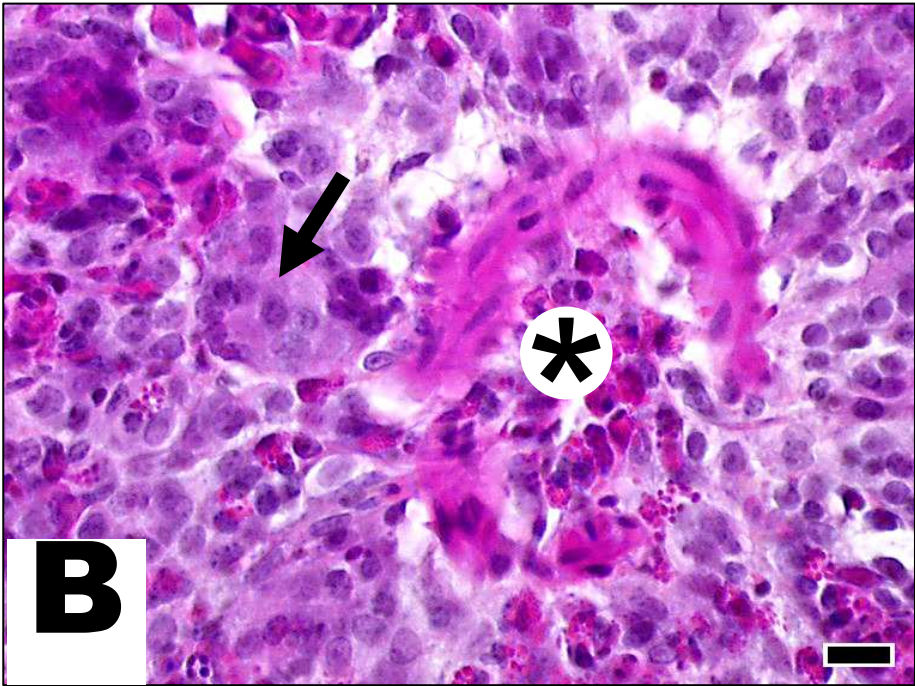
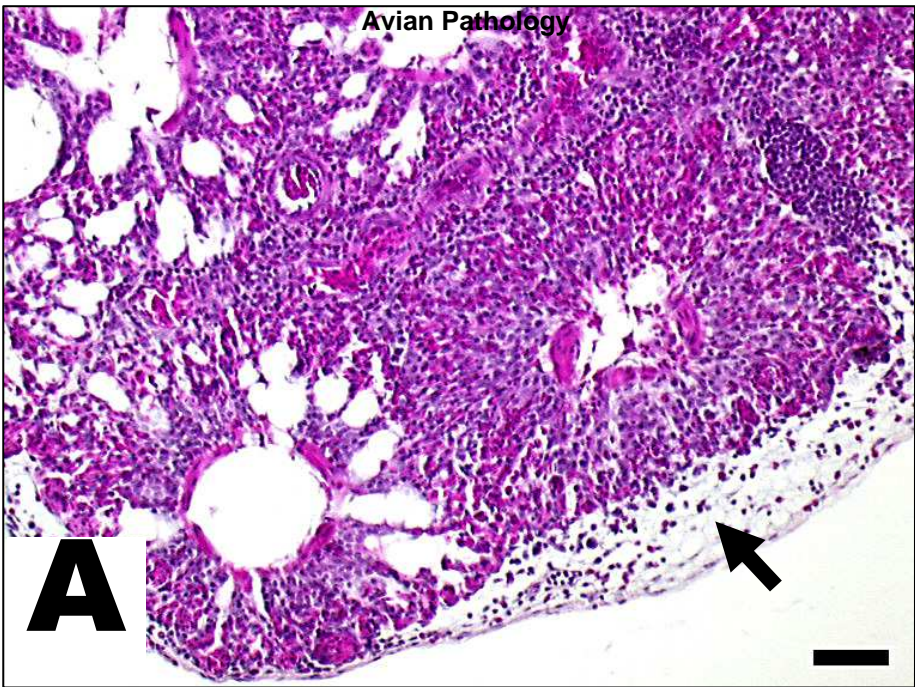


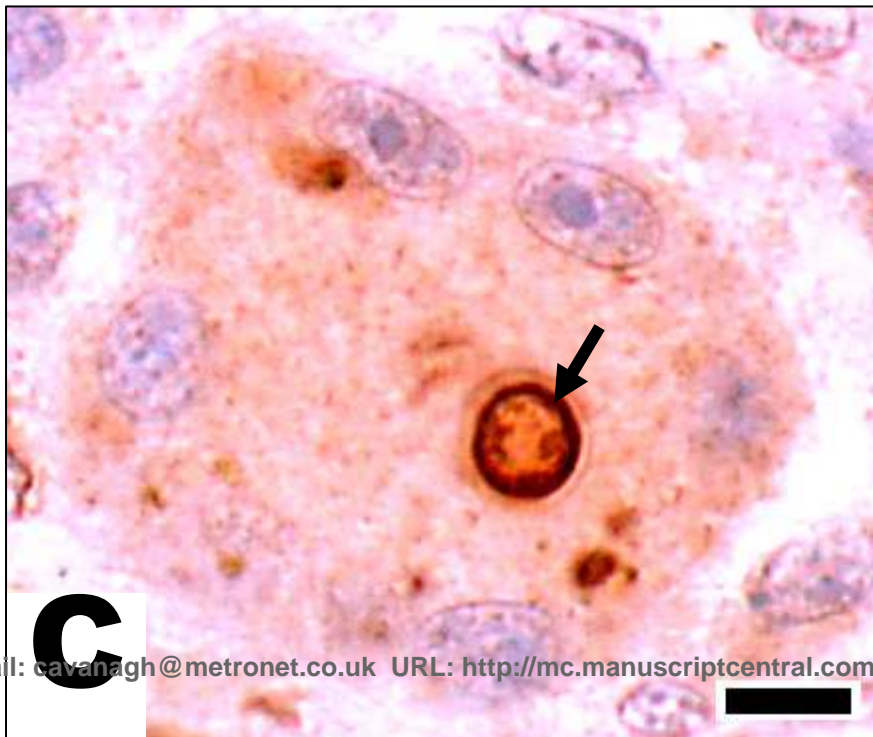
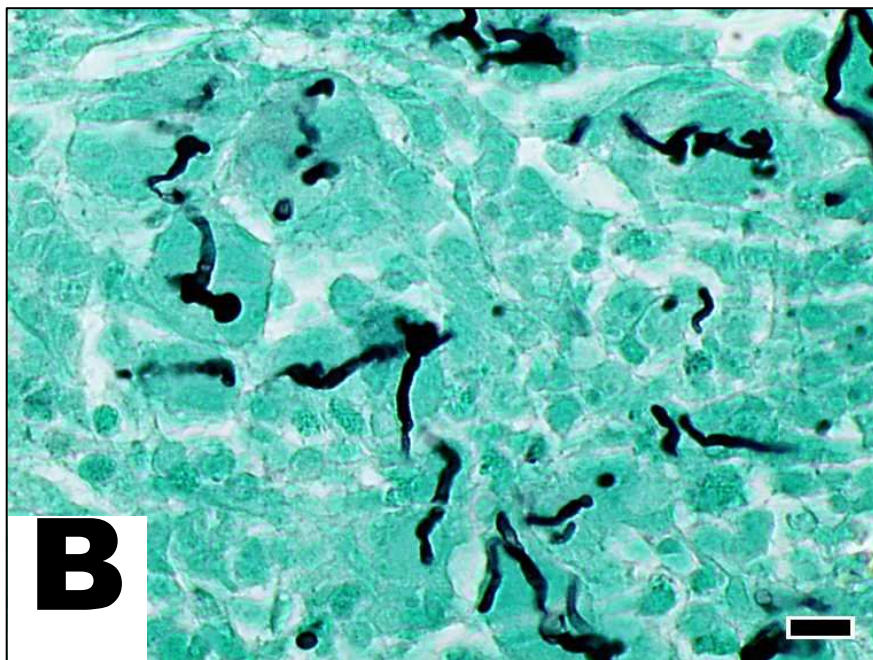
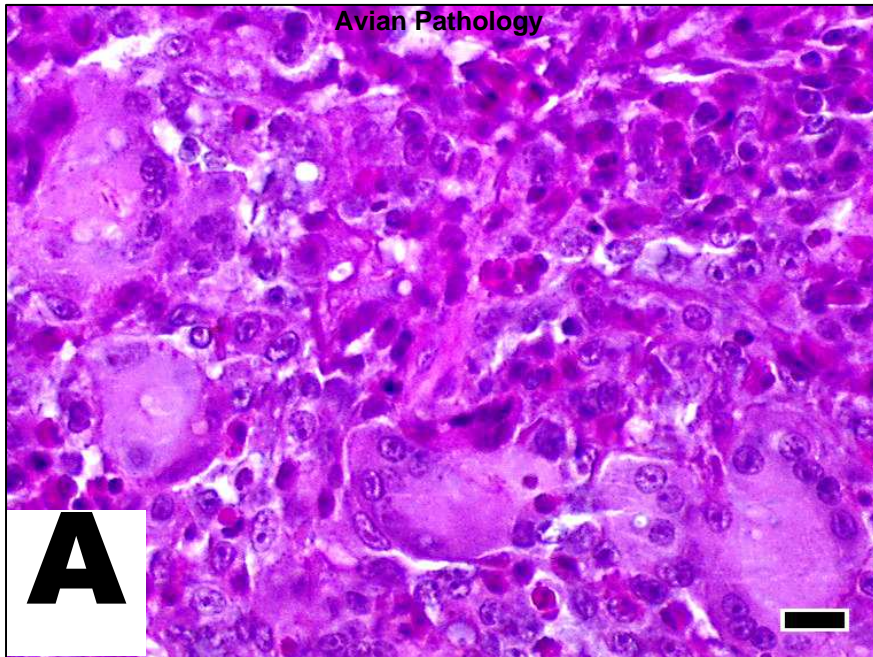
Clinical, mycological and pathological findings in turkeys experimentally infected by *Aspergillus fumigatus*

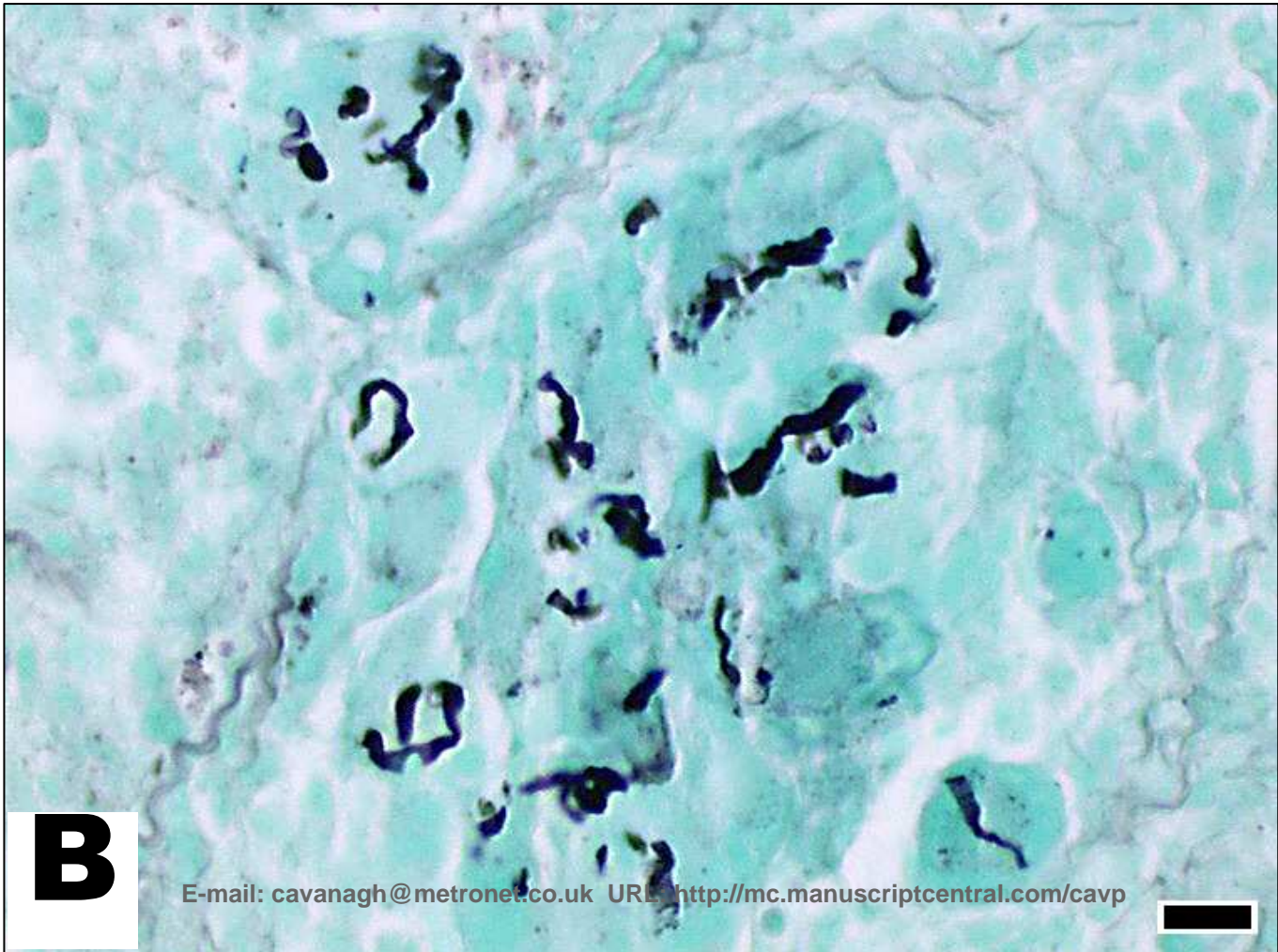
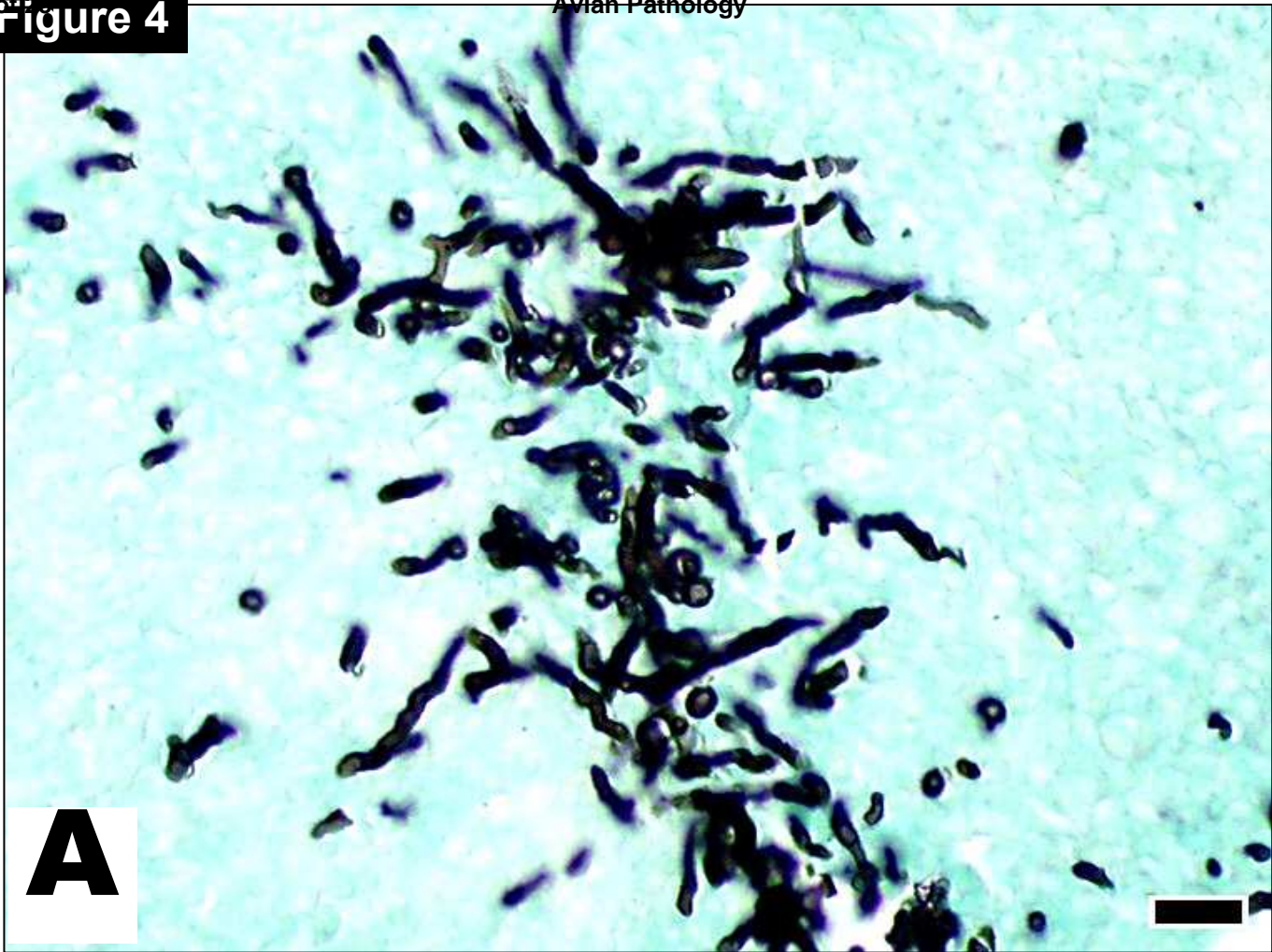
Journal:	<i>Avian Pathology</i>
Manuscript ID:	CAVP-2006-0154.R1
Manuscript Type:	Original Research Paper
Date Submitted by the Author:	29-Jan-2007
Complete List of Authors:	FEMENIA, Francoise; Ecole Nationale Vétérinaire d'Alfort, UMR BIPAR FONTAINE, Jean-Jacques; Ecole Nationale Vétérinaire d'Alfort, Pathology; Ecole Nationale Vétérinaire d'Alfort, UMR BIPAR LAIR-FULLERINGER, Sybille; Ecole Nationale Vétérinaire d'Alfort, UMR BIPAR BERKOVA, Nadia; Ecole Nationale Vétérinaire d'Alfort, UMR BIPAR HUET, Dominique; Ecole Nationale Vétérinaire d'Alfort, UMR BIPAR TOWANOU, Narcisse; Ecole Nationale Vétérinaire d'Alfort, Pathology RAKOTOVAO, Faraso; Ecole Nationale Vétérinaire d'Alfort, Pathology GRANET, Oumaima; Institut Pasteur de Paris, Laboratoire des Aspergillus LE LOCH, Guillaume; Ecole Nationale Vétérinaire d'Alfort, UMR BIPAR ARNE, Pascal; Ecole Nationale Vétérinaire d'Alfort, UMR BIPAR GUILLOT, Jacques; Ecole Nationale Vétérinaire d'Alfort, UMR BIPAR; Ecole nationale Veterinaire d'Alfort (ENVA), Parasitology-Mycology
Keywords:	aspergillosis, turkey, air-sac, lung

For Peer Review Only









cavp 2006-0154.R1

Clinical, mycological and pathological findings in turkeys experimentally infected by *Aspergillus fumigatus*

Françoise Femenia¹, Jean-Jacques Fontaine², Sybille Lair-Fulleriger¹, Nadia Berkova¹, Dominique Huet¹, Narcisse Towanou², Faraso Rakotovao, Oumaima Granet³, Guillaume Le Loc'h¹, Pascal Arné¹, and Jacques Guillot^{1*}

¹ UMR INRA, AFSSA, ENVA, UPVM, 956 BIPAR Ecole Nationale Vétérinaire d'Alfort, 7 Avenue du Général deGaulle 94704 Maisons-Alfort, France

² Unité d'Anatomie pathologique, Ecole Nationale Vétérinaire d'Alfort, 7 Avenue du Général de Gaulle 94704 Maisons-Alfort, France

³ Laboratoire des Aspergillus, Institut Pasteur, 25 Rue du Docteur Roux 75724 Paris, France

Running title: Pathology of experimental aspergillosis

*Corresponding author. Tel: 33 1 43 96 71 57, Fax: 33 1 43 96 71 90,

E-mail address: jguillot@vet-alfort.fr

Received: 9 October 2007

cavp 2006-0154.R1

Clinical, mycological and pathological findings in turkeys experimentally infected by *Aspergillus fumigatus*

Françoise Femenia¹, Jean-Jacques Fontaine², Sybille Lair-Fulleriger¹, Nadia Berkova¹, Dominique Huet¹, Narcisse Towanou², Faraso Rakotovao, Oumaima Granet³, Guillaume Le Loc'h¹, Pascal Arné¹, and Jacques Guillot^{1*}

Abstract

Experimental aspergillosis was induced in one-day-old turkeys by intra-air sac inoculation of a spore suspension of a 3-day-old *Aspergillus fumigatus* culture (CBS 144.89) containing 10^7 spores. Ten additional poults were used as controls. Infected and non-infected animals were closely observed at least twice a day for the appearance of clinical signs and were sequentially sacrificed at days 1, 2, 3, 5 and 7 post-inoculation (pi). In the infected group, most lung tissues and air sac swabs were culture positive from day 1 to day 5. At one-day pi air sac membranes were multifocally and moderately to severely thickened by an oedema and covered by an exudate. A small number of germinating conidia were present in the superficial exudate, already giving rise to small radiating hyphae. Lung lesions were mild, dominated by a diffuse congestion and a mild heterophilic infiltration. From two to 3 days pi air sac membranes were more severely affected and several granulomas were observed. Both granulomas and exudates were rich in germinated conidia and hyphae. Pulmonary lesions consisted in a diffuse pneumonia. Five days pi air sac membrane lesions progressed to a severe, multifocal, heterophilic and granulomatous inflammation. Seven days pi a reduction of the severity of the diffuse pneumonia was detected. Concomitantly, the fungal elements were mainly observed as fragmented tubules in the cytoplasm of multinucleate giant cells. The present study

demonstrated that healthy turkey poult s might be able to withstand exposure to 10^7 *A. fumigatus* spores.

For Peer Review Only

Introduction

In the early 1800s, moulds, probably belonging to the genus *Aspergillus*, were described in wild birds in Europe. Since then aspergillosis has been described worldwide in a very large number of avian species and probably all birds are susceptible to infection (Richard, 1997; Kearns, 2003; Tell, 2005). Turkey poults in large confinement houses, quail, marine birds that are brought into rehabilitation, captive raptors, and penguins being maintained in zoological parks commonly die from aspergillosis. Young birds appear to be much more susceptible than adults. In turkey poults, aspergillosis leads to consequential economic losses related to low productivity, mortality and carcass condemnations at slaughter inspection (Morris & Fletcher, 1988; Richard 1997). Two forms of the disease are regularly reported in turkey poults. The first form is an acute aspergillosis leading to severe outbreaks in very young birds. Clinical signs usually include dyspnoea, gasping and inappetence. The chronic form of aspergillosis most commonly occurs in 13 to 18 week-old turkeys, late in the growing cycle.

Aspergillus spp. is opportunistic pathogens, causing disease in immunocompromised birds or in birds exposed to overwhelming numbers of fungal spores. In most cases, the primary site of development is the respiratory tract (air sacs and lungs) but blood dissemination frequently occurs, leading to macroscopic lesions in a wide range of organs or tissues. In spontaneous cases, lesions range from miliary to larger granulomatous foci (Olson, 1969; Reece *et al.*, 1986; Perelman & Kuttin, 1992; Singh *et al.*, 1994), which are white in colour and protrusive to the surface of the internal organ (Reece *et al.*, 1986; Perelman & Kuttin, 1992; Richard, 1997). Thickening of the walls of the air sacs is frequently reported. Microscopic examination reveals the presence of

granulomatous foci and necrosis with a surrounding region of proliferation including giant cells, macrophages, heterophils and lymphocytes and an outer capsule of connective tissue. Branching and septate fungal hyphae are systematically observed within the lesions (Reece *et al.*, 1986; Perelman & Kuttin, 1992; Singh *et al.*, 1994). Despite advances in the study of diseases related to *Aspergillus* spp., the physiopathology of avian aspergillosis has not yet been fully elucidated. In previous investigations, experimental aspergillosis was induced in chickens (O'Meara & Chute, 1959; Taylor & Burroughs, 1973; Van Cutsem, 1983; Fadl Elmula *et al.* 1984), turkeys (Richard *et al.*, 1981; Richard & Thurston, 1983; Redig, 1986; Richard *et al.*, 1991; Kunkle & Rimler, 1996; Kunkle & Sacco, 1998; Kunkle *et al.*, 1999), starlings (Atasaver & Gümüşsoy, 2004), ducks (Graczyk *et al.*, 1998), Japanese quail (Olson, 1969; Chaudhary & Sadana, 1988; Gümüşsoy *et al.* 2004), pigeons (Van Cutsem *et al.*, 1989) and ostriches (Walker, 1915).

The aim of the present study was to evaluate clinical, mycological and pathological findings in turkey poultts experimentally infected by *Aspergillus fumigatus*. Experimentally infected poultts were killed from day 1 to 7 post-inoculation (pi) and a subsequent histological analysis was performed in order to describe the first steps of *Aspergillus* development and concomitant immune response in tissues.

Materials and methods

Animals. Thirty-one turkey poults of the British United Turkeys (BUT) 9 strain were selected for the present study. These animals originated from a conventional breeding unit in France. Throughout the experiment, the poults were housed in cages (cages E1CCBAC010 Charles River Laboratories, France) with filtering covers (E4FVC04910). They were fed a commercial poult mash and water *ad libitum*. The feed was sterilized by ionisation. The water was sterilized by heat.

Experimental inoculum. The strain CBS 144.89, initially isolated from a human patient with invasive aspergillosis in France and obtained from the Centraalbureau voor Schimmelcultuur, Utrecht, The Netherlands was used. The strain was routinely maintained on Sabouraud dextrose agar plates supplemented with chloramphenicol (0.5 g/L). To obtain asexual spores (= conidia), cultures were grown on YM agar (0.3 % yeast extract, 0.3% malt extract, 0.5% peptone, and 0.5% agar) at 37°C. After 3 days growth, a large number of conidia was produced from specific cells (= phialids) that radiate from a vesicle at the top of a conidiophorous hypha. The conidia were harvested by flooding the plates with sterile distilled water. They were then pelleted by centrifugation, washed in phosphate-buffered saline (0.15M, PBS) and quantified using a Malassez cell.

Experimental design. Six one-day-old poults were killed at the beginning of the experiment (pre-inoculation controls). Their lungs were removed and contamination by *A. fumigatus* was checked for by application of lung sections onto Sabouraud dextrose agar. The plates were incubated at 41°C and the presence of *A. fumigatus* colonies was checked for every day for a week. The remaining one-day-old poults were randomly

divided into two groups. Each bird in the infected group (n=15) was anaesthetised by intramuscular injection of 15µl ketamine and 10µl diazepam (5mg/kg), 15µl imalgene 1000 mg/10ml + 10µl valium, 5 mg/ml; then inoculated by transcutaneous injection into the right caudal thoracic air sac with 100µl of a spore suspension of a 3-day-old *A. fumigatus* culture containing 10^7 spores. The birds in the control group (n=10) were anaesthetised and similarly given 20µl sterile saline solution. Birds from the two groups were placed in separate cages. The poults were closely observed at least twice a day for the appearance of clinical signs. Three randomly selected poults from the infected group and two from the control group were killed 1, 2, 3, 5 and 7 days pi. A *post mortem* examination was performed and the following organs were removed: lungs, thoracic air sac, liver and brain.

Mycological and histological analyses. Sections of lung, liver and brain were applied on Sabouraud dextrose agar with 0.5% chloramphenicol in Petri dishes. Sampling of the thoracic air sac was made with a sterile cotton-swab. The plates were incubated for four days at 37°C. When fungal colonies developed, species identification was done by microscopic examination of conidiophores and conidia, in addition to the observation of colony morphology. *A. fumigatus* is characterized by green echinulate conidia, 2 to 3µm in diameter, produced in chains from greenish phialids, 6 to 8 by 2 to 3µm in size (de Hoog *et al.*, 2000). All the organs and tissues were further fixed in 10% formaldehyde. Paraffin wax-embedded specimens were sectioned at 4µm and stained with haematoxylin-eosine-safran (HES), methenamine silver stain (MS) and periodic acid Schiff (PAS). Immuno-histochemical staining was performed with a Ventana NexES

automated immunostainer on 4µm sections using the avidine-biotin-peroxidase complex method with diaminobenzidine as a substrate and haematoxylin as counterstaining (Ventana iView DAB detection kit). After deparaffinisation, unmasking of the antigens by heat (microwave 750W, 10 min) and inhibition of endogenous peroxidase activity (by a specific buffer included in the Ventana iView DAB detection kit), some sections were incubated with a rabbit polyclonal antibody specific for *A. fumigatus* conidia (Sturtevant & Latgé, 1992) diluted 1:50, for 30 min at 37°C.

Results

Clinical signs. In the infected group no clinical signs were noticed until day 6 pi, when one poult (out of 6) presented respiratory distress and diarrhoea. The birds in the control group remained apparently normal throughout the study.

Mycological cultures. *A. fumigatus* was not recovered from the 6 poult that were killed at the beginning of the study. In the infected group, a large number of *A. fumigatus* colonies could be isolated from thoracic air sac and lung tissue from days 1 to 5 p. (Table 1). Mycological cultures were negative at 7 days pi. A small number of *A. fumigatus* colonies were isolated from liver tissue in two experimentally-infected animals at day 3 and 5. *A. fumigatus* was not isolated from brain tissue. In the control group, mycological cultures were all negative.

Macroscopic lesions. Gross lesions were detected at necropsy in 9 infected birds (Table 1). Lesions consisted of small (1-3 mm), white nodules protrusive to the surface of the lungs. A thickening of the walls of the thoracic air sacs (along with small plaques) was also noticed in some animals. No macroscopic lesions were detected in the liver or the brain of experimentally infected poult, or in the control group.

Histological observations. The development of the lesions was followed from 1 to 7 days pi on air sac membranes and lung parenchyma. The character and severity of the lesions were generally comparable between the different animals of the same group, in spite of a slight individual variability. No lesions or fungal elements were seen in the liver or the brain. At one day pi, air sac membranes were multifocally and moderately to severely thickened by a clear oedema containing dispersed, non-degenerate, heterophils; mononuclear inflammatory cells were rare. Multifocally, the epithelium was ulcerated and replaced by a loosely arranged eosinophilic exudate, containing blood cells (mainly red blood cells) and degenerate heterophils (Figure 1A). In other places, the epithelium was intact or slightly hyperplastic. No granuloma could be observed at this stage. A small number of swollen and germinating conidia was present in the superficial exudate, giving already rise to small radiating hyphae (Figures 1B and 1C). No fungal element was observed in intact structures or in the interstitial exudative changes. Lung lesions were mild, dominated by a diffuse congestion and a mild heterophilic infiltration. A few, more severe, inflammatory lesions were focally present on the pleura and the underlying pulmonary lobules (Figure 2A). Those focal pleural lesions were characterized by a severe thickening due to a clear oedema and a moderate infiltration by heterophils, lymphocytes and plasma cells. Lesions of the underlying pulmonary alveoli were severe

and characterized by a parenchymal infiltration with similar numbers of heterophils and macrophages; rare, small, multinucleated giant cells began to appear (Figure 2B). A moderate perivascular cuffing by lymphocytes and macrophages was inconstantly present. The epithelium of parabronchi was necrotic and their lumen was filled with a slightly eosinophilic exudate containing few red blood cells and numerous heterophils. A small number of germinating conidia was present in the pulmonary lesions, confined to the lobular parenchyma, leaving free the parabronchi and the overlying pleura (Figure 2C).

Two days pi, air sac membranes were more severely affected, being diffusely thickened, either by a clear oedema containing few cells, or focally by a protein-rich exudate containing numerous heterophils and macrophages. Several granulomas were observed, composed of a necrotic, amorphous, eosinophilic centre, surrounded by degenerate and intact heterophils, and by a thin, discontinuous rim of macrophages. The superficial exudate was condensed in highly eosinophilic deposits, containing numerous necrotic and degenerate heterophils. Both types of lesions were rich in germinated conidia and hyphae. Multinucleate giant cells were present but remained rare. Pulmonary lesions were also more severe, consisting in a diffuse pneumonia, with a marked mixed cellular infiltrate associating heterophils, macrophages and lymphocytes. These lesions were especially severe in superficial lobules, with a strong macrophagic infiltration, rich in multinucleate giant cells (Figure 3A). Germinating conidia were numerous in giant cell-rich areas (Figure 3B).

By 3days pi, pleural lesions were characterized by a less severe oedema than in previous stages and by a stronger infiltration with heterophils, macrophages and

lymphocytes. Large areas of the lung presented a severe pneumonia dominated by macrophages, epithelioid cells and multinucleate giant cells; the infiltration by heterophils was diffuse and moderate; small foci of lymphoid cells were present and inconstantly organized in periarteriolar sheets. Several granulomas were present in the lobular parenchyma, with a central core of necrotic heterophils and a large rim of multinucleate giant cells. Fungal elements were numerous and obvious, either with HES or with MS staining. Immunohistochemical techniques, using a rabbit polyclonal antibody specific for *A. fumigatus* conidia (Sturtevant & Latgé, 1992), confirmed that the fungal elements observed in the lesions belonged to *A. fumigatus* (Figure 3C).

At 5 days pi, air sac membrane lesions progressed to a severe, multifocal, heterophilic and granulomatous inflammation, with large accumulations of necrotic heterophils, surrounded by a continuous rim of epithelioid and multinucleate giant cells. Fungal elements were mainly confined to the centre of the granulomas. Pleural and pulmonary lesions were similar to those observed at day 3, with persistence of well-organized granulomas where fungi were restricted.

At 7 days pi, a reduction in the severity of the diffuse pneumonia was detected. Concomitantly, destruction of the fungal elements occurred. These elements were mainly observed in the cytoplasm of multinucleate giant cells, either in the air sac membranes or in the alveolar parenchyma, as irregular and fragmented tubules (Figure 4) or dust-like debris, attesting their destruction by the inflammatory cells.

Discussion

Aspergillosis is considered to be a common and life-threatening infection in many avian species. Predisposition of birds to aspergillosis may be attributed to some anatomical peculiarities which preclude the mechanisms of ejection of inhaled fungal spores. The absence of resident macrophages within airway lumens and the dependence on heterophils (that use cationic proteins, hydrolase and lysosyme rather than catalase and myeloperoxidase) may also be responsible for the increased sensitivity of birds to aspergillosis (Klika *et al.*, 1996; Harmon, 1998). As a consequence, information provided by models using common laboratory animals (rodents and rabbit) may not be valuable for birds. Therefore, the development of specific avian models is critical to our current understanding of the pathogenesis of avian aspergillosis and to the advancement of prevention and therapy. Previous models have used a variety of avian species (chickens, turkeys, quail, starling, pigeon and ostriches), with ages ranging from hatchlings to adult birds. Different routes of inoculation and challenge dosage have been tested. Inhalation chambers have been used to obtain experimental aspergillosis in chickens (O'Meara & Chute, 1959; Taylor & Burroughs, 1973) and turkeys (Richard *et al.*, 1981; Richard & Thurston, 1983; Richard *et al.*, 1991). Intra-tracheal challenge has been performed in ducks (Graczyk *et al.*, 1998), quail (Chaudhary & Sadana, 1988) and ostriches (Walker, 1915). Intra-air sac inoculation was tested in turkeys (Kunkle & Rimler, 1996; Kunkle & Sacco, 1998; Kunkle *et al.*, 1999). Exposure to aerosolised spores probably represents the model that most closely mimics natural conditions. However, this model requires specific equipment (inhalation chambers) and the standardization of challenge dose may be difficult. In the present study, intra-air sac inoculation was selected with a controlled inoculum of 10^7 spores / animal. Experimental infection was performed in one-day old

turkeys because aspergillosis is regularly reported in this species and because young turkeys are believed to be more susceptible than adults. In the present study, sequential observations from 1 to 3 days pi did not differ significantly from previous ones, especially from those of Kunkle & Rimler (1996) performed using 9- and 19-week-old turkeys. Our observations confirmed that lesions are confined to air sac membranes and lungs and that the formation of granulomas occurs very soon after experimental inoculation. However, Kunkle & Rimler (1996) detected granulomas (50 to 200µm in diameter) as soon as one day pi, whereas in the present study similar lesions were first observed 2 days pi. Kunkle & Rimler examined experimentally infected turkeys only at days 1, 2, 3 and 4 pi, whereas in the present study, the lesions were described for a longer period (one week) and this allowed us to demonstrate that fungal elements begin to be destroyed by the multinucleate giant cells at day 7 pi. This result suggests that healthy turkey poults can withstand considerable exposure to *A. fumigatus* spores. Chaudhary & Sadana (1988) made similar observations in quail. Clinical signs were consistently observed for 7-10 days following intra-tracheal inoculation, but thereafter the surviving birds appeared normal. O'Meara and Chute (1959) reported that hatching poults were easily infected with *A. fumigatus* spores, but poults older than 3 days were resistant to the infection. In the study by Taylor & Burroughs (1973) histological evidence of *Aspergillus* infection was noted in lung tissue at about the third day post aerosol exposure of chickens, but generally disappeared during the subsequent 7 to 10 days. On the contrary, lesions persisted in air sacs, for 3 or more weeks in some birds.

Acute inflammatory reactions in birds frequently include multinucleate giant cells that are characteristic of more chronic reactions in mammals (Kunkle & Rimler, 1996).

These elements, together with the findings from the present study, suggest that the involvement of macrophages and multinucleate giant cells in the early development of aspergillosis in turkeys is a non-specific process. Effective destruction of *A. fumigatus* was confirmed in the present study by negative cultures from lungs and air sacs at day 7 pi. Further experiments have to be conducted with older animals. Of course, a single injection of a large amount of *Aspergillus* conidia within an air sac does not represent the model that most closely mimics natural conditions. In animal facilities, birds may be exposed to a small number of airborne *Aspergillus* conidia for a long time (several days). In such circumstances, we can imagine that pathogenesis of avian aspergillosis may be different from that described after a single inoculation. Pathogenesis of avian aspergillosis may also be related to the virulence of *A. fumigatus* isolates. Using the analysis of microsatellite markers polymorphism, a recent investigation demonstrated that the same genotype was detected in both healthy and infected birds, suggesting the absence of particular virulent genotypes for turkeys (Lair-Fulleriner *et al.*, 2003). However, Peden & Rhoades (1992) reported that *A. fumigatus* isolates from different sources showed a range of virulence and lethal infection in intra-air sac inoculated turkeys. The single environmental isolate produced no mortality. The strain used in the present study (CBS 144.89) was initially isolated from a human with invasive aspergillosis. In further experiments, turkeys should be challenged with *A. fumigatus* of avian origin.

Acknowledgements

The authors express their gratitude to Agnès Champeix, Patricia Wattier and Sophie Chateau-Joubert (Ecole Nationale Vétérinaire d'Alfort) for the histological technique.

References

- Atasever, A. & Gümüşsoy, K.S. (2004). Clinical and mycological findings in experimental aspergillosis infections of starlings. *Journal of Veterinary Medicine Series A*, 51, 19–22.
- Chaudhary, S.K. & Sadana, J.R. (1988). Experimental aspergillosis in Japanese quails (*Coturnix coturnix japonica*), clinical signs and haematological changes. *Mycopathologia*, 102, 179-184.
- de Hoog, G.S., Gene, J. & Figueras, M.J. (2000). Atlas of clinical fungi, 2nd ed. Centraalbureau voor Schimmelcultures, Utrecht, The Netherlands.
- Fadl Elmula, A., Abu Elgasim, A.I. & El Mubarak, A.K. (1984). Experimental aspergillosis in young chicks. *Revue Elevage et Médecine Vétérinaire Pays tropicaux*, 37, 437–441.
- Graczyk, T.K., Cranfield, M.R. & Klein, P.N. (1998). Value of antigen and antibody detection, and blood evaluation parameters in diagnosis of avian aspergillosis. *Mycopathologia*, 140, 121-127.
- Gümüşsoy, K.S., Uyanik, F., Atasever, A. & Çam, Y. (2004). Experimental *Aspergillus fumigatus* infection in quails and results of treatment with itraconazole. *Journal of Veterinary Medicine Series B*, 51, 34-38.

- Harmon, B. (1998). Avian heterophils in inflammation and disease resistance. *Poultry Sciences*, 77, 972-977.
- Kearns, K.L. (2003). Avian aspergillosis. *In: Recent advances in avian infectious diseases*.
- Kearns KS, Loudis B (Eds). Ithaca, International Information Service.
- Klika, E., Scheuermann, D.W., De Groot-Lasseel, M.H.A., Bazantova, I. & Switka, A. (1996). Pulmonary macrophages in birds (barn owl, *Tyto tyto alba*), domestic fowl (*Gallus gallus domestica*), quail (*Coturnix coturnix*) and pigeon (*Columbia livia*). *Anatomy Record*, 246, 87-97.
- Kunkle, R.A. & Sacco, R.E. (1998). Susceptibility of convalescent turkeys to pulmonary aspergillosis. *Avian Diseases*, 42, 787-790.
- Kunkle, R.A. & Rimler, R.B. (1996). Pathology of acute aspergillosis in turkeys. *Avian Diseases*, 40, 875-886.
- Kunkle, R.A., Rimler, R.B. & Steadham, E.M. (1999). Absence of protection against challenge with *Aspergillus fumigatus* by adoptive transfer of splenocytes from convalescent turkeys. *Avian Diseases*, 43, 678-684.
- Lair-Fullerger, S., Guillot, J., Desterque, C., Seguin, D., Warin, S., Chermette, R. & Bretagne, S. (2003). Differentiation of *Aspergillus fumigatus* isolates from breeding turkeys and their environment by genotyping with microsatellite markers. *Journal of Clinical Microbiology*, 41, 1798-1800.
- Morris, M.P. & Fletcher, O.J. (1988). Disease prevalence in Georgia turkey flocks in 1986. *Avian Diseases*, 32, 404-406.

- O'Meara, D.C. & Chute, H.L. (1959). Aspergillosis experimentally produced in hatching chicks. *Avian Diseases*, 3, 404-406.
- Olson, L. (1969). Aspergillosis in Japanese quail. *Avian Diseases*, 13, 225-227.
- Peden, W.M. & Rhoades, K.R. (1992). Pathogenicity differences of multiple isolates of *Aspergillus fumigatus* in turkeys. *Avian Diseases*, 36, 537-542.
- Perelman, B. & Kuttin, E.S. (1992). Aspergillosis in ostriches. *Avian Pathology*, 21, 159-163.
- Redig, P.T. (1993). Avian aspergillosis. In: Fowler ME (Ed) Zoo and wild animals medicine. WB. Saunders Company, Philadelphia, 178-181.
- Redig, P.T., Post, G.S., Concannon, T.M. & Dunette, J. (1986). Development of an ELISA for the detection of aspergillosis in avian species. *Proceedings of the Association Avian Veterinarians*, 165-178.
- Reece, R.L., Taylor T.K. & Dickson, D.B. (1986). Mycosis of commercial Japanese quail, ducks and turkeys. *Australian Veterinary Journal*, 63, 196-197.
- Richard, J.L. (1997). Aspergillosis. In: Diseases of poultry. Calnek B.W. (Ed), Mosby-Wolfe, London, 351-365.
- Richard, J.L. & Thurston, J.R. (1983). Rapid hematogenous dissemination of *Aspergillus fumigatus* and *A. flavus* spores in turkey poults following aerosol exposure. *Avian Diseases*, 27, 1025-1033.
- Richard, J.L., Cutlip, R.C., Thurston, J.R. & Songer, J. (1981). Response of turkey poults to aerosolized spores of *Aspergillus fumigatus* and aflatoxinogenic and non aflatoxinogenic strains of *Aspergillus flavus*. *Avian Diseases*, 25, 53-67.

- Richard, J.L., Peden, W.M. & Sacks, J.M. (1991) Effects of adjuvant-augmented germling vaccines in turkey poultts challenged with *Aspergillus fumigatus*. *Avian Diseases*, 35, 93- 99.
- Singh, H., Grewal, G.S. & Singh, N. (1994). Mycotic salpingitis in a Japanese quail (*Coturnix coturnix japonica*). *Avian Diseases*, 38, 910-913.
- Sturtevant, J. & Latgé, J.P. (1992). Interactions between the spore of *Aspergillus fumigatus* and human complement component C3. *Infection and Immunity*, 60, 1913-1918.
- Taylor, J.J. & Burroughs, E.J. (1973). Experimental avian aspergillosis. *Mycopathologia Mycologia Applicata*, 51, 131-141.
- Tell, L.A. (2005). Aspergillosis in mammals and birds: impact in veterinary medicine. *Medical Mycology*, 43, S71-S73.
- Van Cutsem, J. (1983). Antifungal activity of enilconazole on experimental aspergillosis in chickens. *Avian Diseases*, 27, 36-42.
- Van Cutsem, J. Van Gerven, F., Janssen, P.A. (1989). Oral and parenteral therapy with saperconazole (R 66905) of invasive aspergillosis in normal and immunocompromised animals. *Antimicrobial Agents and Chemotherapy*, 33, 2063-2068.
- Walker, J. (1915). Aspergillosis in the ostrich chick. *Union South Africa Department Agriculture Annual Report*, 3-4, 535-574.

Figure legends

Figure 1. *Air sac 1-day post-inoculation. (A) Oedema of the air sac membrane (star) and heterophil-rich exudate collected in the lumen (frame). Haematoxylin-Eosin-Safran (HES). Bar = 50µm. (B) Details of the exudate, showing numerous small radiating hyphae strongly stained in black by Methenamine Silver (MS). Bar = 10µm. (C) Same sample stained with Periodic Acid-Schiff (PAS), allowing the observation of septae within the hyphae (arrows); swollen conidia (arrowheads) are present and characterised by a larger diameter than the hyphae. Bar = 10µm.*

Figure 2. *Lung, 1 day post-inoculation. (A) Pleural oedema (arrow); diffuse densification of the parenchyma by a congestion and by an inflammatory cellular infiltration. HES. Bar = 50µm. (B) Details showing a parabronchus filled by a heterophil-rich exudate (star) and a parenchymal infiltration by heterophils and mononuclear inflammatory cells (presumptive macrophages); a multinucleate giant cell is already present (arrow). HES. Bar = 10µm. (C) Small hyphae radiating in a pulmonary lobule. MS. Bar = 25µm.*

Figure 3. *Early evolution of the inflammatory cell population. (A) Pulmonary parenchyma, 3 days post-inoculation. Mononuclear cells are more numerous than at 1 day post-inoculation and heterophils are fewer. HES. Bar = 10µm. (B) Same sample showing hyphae in black within the multinucleated giant cells (cytoplasm stained in green). MS. Bar = 10µm. (C) A swollen conidium, phagocytized by a multinuclear giant cell. Anti-Aspergillus immunolabelling, showing that the fungi stained by MS belong to the species *Aspergillus fumigatus*. Bar = 5µm.*

Figure 4. *Morphological evolution of fungi. (A) Numerous, well-stained and well-delineated conidia and hyphae in an acute exudative lesion, 2 days post-inoculation. MS. Bar = 10µm. (B) Intra-granulomatous fungi, phagocytised by multinucleate giant cells, 7 days post inoculation. Hyphae are badly delineated and fragmented, attesting their destruction by the inflammatory cells. MS. Bar = 10µm.*

For Peer Review Only

Table 1. Recovery of *A. fumigatus* and evidence of macroscopic lesions in lung tissue and thoracic air sac of experimentally infected turkey poults.

Days post inoculation	Lung tissue		Thoracic air sac	
	<i>A. fumigatus</i> recovery (by culture)	Evidence of gross lesions (nodules)	<i>A. fumigatus</i> recovery (by culture)	Evidence of gross lesions (exudation)
1	1 ^a	0 ^b	3	0
2	1	0	3	0
3	1	3	2	0
5	1	3	1	2
7	0	3	0	3

^a Number from which *A. fumigatus* was isolated of 3 examined.

^b Number with lesions of 3 examined.