



**HAL**  
open science

## Avipoxvirus in great tits ()

Ivan Literak, Pavel Kulich, Blanka Robesova, Peter Adamik, Eva Roubalova

► **To cite this version:**

Ivan Literak, Pavel Kulich, Blanka Robesova, Peter Adamik, Eva Roubalova. Avipoxvirus in great tits (). European Journal of Wildlife Research, 2009, 56 (4), pp.529-534. 10.1007/s10344-009-0345-5 . hal-00539081

**HAL Id: hal-00539081**

**<https://hal.science/hal-00539081>**

Submitted on 24 Nov 2010

**HAL** is a multi-disciplinary open access archive for the deposit and dissemination of scientific research documents, whether they are published or not. The documents may come from teaching and research institutions in France or abroad, or from public or private research centers.

L'archive ouverte pluridisciplinaire **HAL**, est destinée au dépôt et à la diffusion de documents scientifiques de niveau recherche, publiés ou non, émanant des établissements d'enseignement et de recherche français ou étrangers, des laboratoires publics ou privés.

## Avipoxvirus in great tits (*Parus major*)

Ivan Literak · Pavel Kulich · Blanka Robesova ·  
Peter Adamik · Eva Roubalova

Received: 7 September 2009 / Revised: 3 November 2009 / Accepted: 5 November 2009 / Published online: 24 November 2009  
© Springer-Verlag 2009

**Abstract** A total of six cases and 37 suspect cases of skin avipoxvirus infection in great tits (*Parus major*) have been described in central Europe since 2005. Most of the cases were diagnosed during the winter season, from October to March. Analyses of the 4b core protein gene showed identical or almost identical DNA sequence in six isolates (one from Austria, three from Hungary, and two from Czech Republic). A morphogenesis of the avipoxvirus including a constitution of acidophilic-type inclusions (ATIs) was documented by electron microscopy in cells from lesions on great tits found in Czech Republic. Moreover, the ATI body protein gene was demonstrated using polymerase chain reaction in the isolate that caused ATIs. A number of new cases of poxvirus infection in great tits have emerged in central Europe since 2005, and the reason for this sudden increase remains unknown.

**Keywords** Bird · Virus · Disease · Czech Republic · Slovakia · Germany

---

Communicated by W. Lutz

---

I. Literak (✉) · E. Roubalova  
Department of Biology and Wildlife Diseases,  
Faculty of Veterinary Hygiene and Ecology,  
University of Veterinary and Pharmaceutical Sciences,  
Palackeho 1-3,  
Brno 612 42, Czech Republic  
e-mail: literaki@vfu.cz

P. Kulich · B. Robesova  
Veterinary Research Institute,  
Hudcova 70,  
Brno 621 00, Czech Republic

P. Adamik  
Department of Zoology, Faculty of Science, Palacky University,  
tr. Svobody 26,  
Olomouc 771 46, Czech Republic

### Introduction

Avipoxviruses (Poxviridae) are double-stranded DNA viruses of birds that usually cause proliferative skin lesions and/or upper digestive/respiratory tract lesions (Buller et al. 2005). Avipoxvirus infection has been documented in about 232 bird species in 23 orders (Bolte et al. 1999). Nevertheless, the genus *Avipoxvirus* includes only ten well-defined species and three tentative species (Buller et al. 2005).

In passerine birds (Passeriformes) from the family Paridae, the avipoxvirus infection has been described in tufted titmouse (*Baeolophus bicolor*) in the USA (Goodpasture and Anderson 1962), African blue tit (*Cyanistes teneriffae*) in the Canary Islands (Illera et al. 2008), and great tit (*Parus major*) in Europe (Holt and Krogsrud 1973; Literak et al. 2004; Gruber et al. 2007; Palade et al. 2008). The fact that great tits are among species susceptible to avipoxvirus infection was proven by experimental infections already in 1901 (Polowinkin 1901). Until recently, naturally occurring avipoxvirus infection had been described only in Scandinavia. Five cases of infected great tits including an isolation of avipoxviruses were documented in one location in Norway (Holt and Krogsrud 1973). The viral 4b core protein gene was analyzed in three of these isolates (Weli et al. 2004). Three other suspect cases of great tits avipoxvirus infection were described later in two locations in Sweden (Literak et al. 2004). Four other great tits showing cutaneous nodular lesions on the head were observed in a garden in Vienna, Austria, at the end of October 2005 (Gruber et al. 2007). Recently, three cases and 12 suspect cases of avipoxvirus infection in great tits were described in Hungary during winter 2006/2007 (Palade et al. 2008). Analyses of two of the cases from Hungary and one of the cases from Austria included characterization of 4b core protein gene sequences.

We have recorded 24 new cases of suspect avipoxvirus infections with nodular skin lesions in great tits in different locations in central Europe (Czech Republic, Slovakia, and Germany) from December 2005 to May 2009. Description of these cases, including characterization of the 4b core protein gene and acidophilic-type inclusion (ATI) body protein gene from two avipoxvirus isolates, is the main subject of this work.

## Material and methods

Two great tits with suspect avipoxvirus nodular cutaneous lesions were euthanized and necropsied. Avipoxviruses were detected in the lesions by means of electron microscopy and isolated using methods described elsewhere (Kulich et al. 2008). The first individual was captured in Olomouc (eastern Czech Republic, 49°35' N, 17°15' E) in December 2007. A nodular skin lesion 8×4×4 mm in size was located on the right side of the head next to the beak. The surface of the lesion was necrotic with drab scabs. The individual was in good nutritional condition, and no additional pathomorphological lesions were present. The second individual was captured in Moravske Kninice (southeastern Czech Republic, 49°17' N, 16°29' E) in December 2008. A sizable nodular skin lesion 12×30×5 mm in size was located on the ventral side of the chest, extending to one-third of the abdomen. The lesion had a soft consistency and was bright red color in section. The surface of the lesion was dark brown-black, covered with scabs. This individual was also in good nutritional condition and free of additional pathomorphological lesions. Another 22 great tits with nodular skin lesions suspected of avipoxvirus etiology were photographically documented by nonprofessional bird lovers and ornithologists. A great tit with characteristic skin avipoxvirus lesion is shown in Fig. 1.

DNA was isolated from pox skin lesions of two great tits in which poxviruses were found by electron microscopy. DNA was isolated using the NucleoSpin® Tissue kit (Machery–Nagel) according to the manufacturer's instructions. Skin lesions were cut into small pieces prior to DNA isolation. Tissue samples were lysed overnight at 56°C in the presence of the lysis buffer and proteinase K. Polymerase chain reactions (PCRs) were performed using a pair of primers complementary to a partial sequence of gene encoding for the 4b core protein in conditions described previously (Lee and Lee 1997) and primers for amplification of a sequence of orthopoxvirus ATI body protein gene (Meyer et al. 1997). DNA fragments were visualized on 1% agarose gel stained with ethidium bromide. PCR products of the amplification of a portion of the 4b core protein gene were purified using QIAquick® PCR Purification kit (Qiagen), resuspended in 50 µl of redistilled water, and



**Fig. 1** A great tit with characteristic skin avipoxvirus lesion. Photographed by Karel Novotny

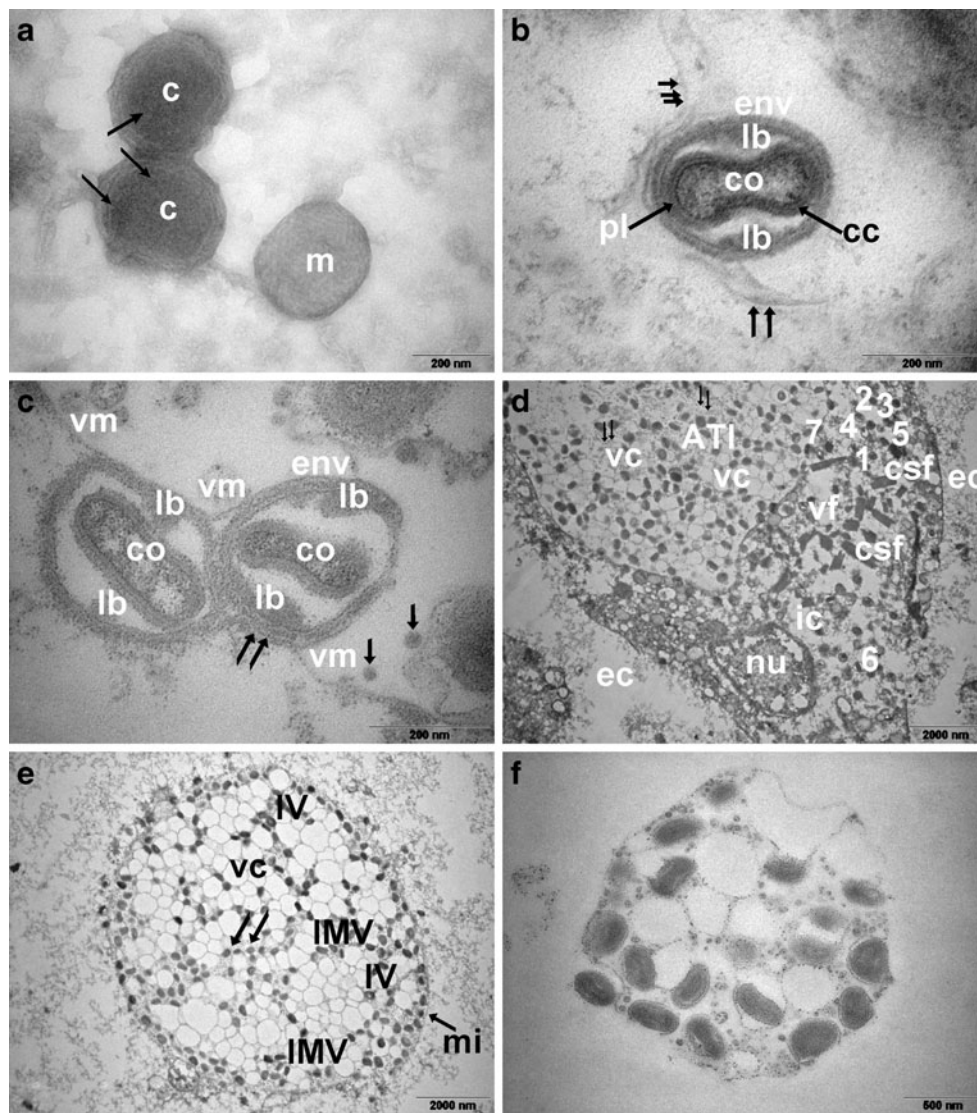
sequenced on both strands using a CEQ™ 8000 Genetic Analyzer (Beckman Coulter). Sequences of the 4b core protein gene were analyzed, and translations into proteins and alignments were carried out using Molecular Evolutionary Genetics Analysis version 4 (29) and basic local alignment search tool (BLAST; National Center for Biotechnology Information; <http://www.ncbi.nlm.nih.gov/BLAST>) softwares.

## Results

### Electron microscopy

Avipoxviruses were found in cutaneous lesions on great tits both from Olomouc and Moravske Kninice. Negative staining showed predominantly the M (mulberry) form of avipoxvirus particles, which were round-shaped, 300×250 nm in size, and with randomly arranged filaments on the surface (Fig. 2a). Approximately 10 M-form particles per visual field were detected using 18,000× magnification. C (capsular) form particles without surface tubules and with capsular body inside were found sporadically (Fig. 2a).

Ultrathin sections of skin lesions from the great tit from Moravske Kninice contained individual stages of avipoxviruses maturation in the cytoplasmic area referred to as “virus factories” (Fig. 2d–vf) or B-type inclusions: the crescent (Fig. 2d–1), circular structures encircling fine electron-dense material (Fig. 2d–2), enclosed formations with condensed nucleoid (Fig. 2d–3, 4, 5), structures containing oval-shaped nucleoids (Fig. 2c, d–6), particles whose core was compressed at the sides by two lateral bodies (Fig. 2c), and A-type inclusions containing mature viruses (Fig. 2d–7). Mature viruses were composed of the core (Fig. 2b–co), core coat (Fig. 2b–cc), palisade layer (Fig. 2b–pl), and envelope (Fig. 2b–env) covered with



**Fig. 2** Morphogenesis of avipoxviruses from a skin pox lesion of a great tit (*P. major*) from Moravske Kninice, Czech Republic. **a** Electron micrographs, negative staining method. M form of avipoxvirus particle (*m*) covered by randomly arranged filaments. C form of avipoxvirus particle without surface filaments (*c*) with radial layer on its surface (*arrow*) and containing corpuscular body. **b–f** Electron micrographs, ultrathin sections. **b** Mature viral particle in the A-type inclusion: envelope (*env*), lateral bodies (*lb*), core (*co*), core coat (*cc*), palisade layer of the envelope (*pl*), filaments binding to the envelope (*arrows*). **c** Avipoxvirus maturation in intracytoplasmatic A-type inclusion: core (*co*), lateral bodies (*lb*), vacuolar membrane. **d**

Individual developmental stages of the virus in the cell: crescent (*1*), partially enclosed oval formations (*2*), immature viruses containing fine electron-dense material (*3*), nucleoid condensation (*4*, *5*), oval-shaped nucleoid (*6*), mature viral particle binding to inclusion membrane (*7*), nucleus (*nu*), intracellular space (*ic*), extracellular space (*ec*), A-type inclusions (*ATIs*), filaments (*arrows*), fibrils showing periodic cross striation (*csf*). **e** Reticular A-type inclusion in the cytoplasm: vacuoles (*vc*), inclusion membrane (*mi*), immature virus (*IV*), mature virus (*IMV*), filaments (*arrows*). **f** Released A-type inclusion containing mature virions is located outside the cell

filaments (Fig. 2b—arrows). A-type inclusions were formed by mature virions (Fig. 2e—IMV), vacuoles (Fig. 2e—vc), filaments (Fig. 2e—arrows), and immature virions (Fig. 2c, e—IV). The envelopes of mature virions are known to be formed by entering the A-type inclusions (Fig. 2d—7), by binding vacuolar membranes inside the A-type inclusion (Fig. 2c—vm), and by binding filaments (Fig. 2b—arrows). An observed reticular structure of A-type inclusions was caused by a joining of individual

small vacuoles. Each vacuole contained one or two viral particles, and filaments were located among the vacuoles (Fig. 2d, e—arrows). Intact A-type inclusions were found also outside the cells (Fig. 2f).

#### Virus isolation

During virus isolation on chicken chorioallantoic membrane (CAM), the changes in the form of pock formation were not

detected until the tenth passage, and viral particles were detected by means of electron microscopy in the samples from the 11th passage. Pocks were approximately 1–2 mm in size, numbering about eight pocks per CAM. The number of pocks increased in subsequent passages.

#### Sequence analysis

Total DNA from skin pox lesions of two great tits was isolated, and a portion of the 4b core protein encoding gene was amplified. Products of approximately expected size were sequenced on both strands, and the acquired sequences were deposited in the GenBank database under accession numbers FJ863096 (566-bp sequence of isolate OL1 from the great tit from Olomouc) and FJ863095 (508-bp sequence of isolate KN1 from the great tit from Moravske Kninice). Corresponding regions of the two sequences of both analyzed samples were identical. Using BLAST software, we searched nucleotide databases for similar sequences. Our sequences showed 100% identity to ten sequences. Five of these belonged to poxviruses isolated previously from great tits (Weli et al. 2004; Gruber et al. 2007; Palade et al. 2008). The five other identical sequences originated from poxviruses from unrelated birds: Eurasian stone curlew (*Burhinus oedicnemus*) (Burhinidae, Charadriiformes), Hawaii amakihi (*Hemignathus virens*), and apapane (*Himatione sanguinea*) (the last two being Drepanididae, Passeriformes; Lueschow et al. 2004; Lierz et al. 2007; Jarvi et al. 2008). To specify the relationships between our sequences and all previously published sequences of poxviruses isolated from great tits, we aligned our sequence with corresponding 428-bp regions of the 4b core protein encoding genes of two additional previously published sequences acquired from GenBank. The sequences EF634351 and AY453173 (Gruber et al. 2007; Palade et al. 2008) differed from our sequences only in one and three nucleotides, respectively.

A sequence of approximately 750 bp of the ATI body protein gene was also amplified in the two great tit avipoxvirus isolates.

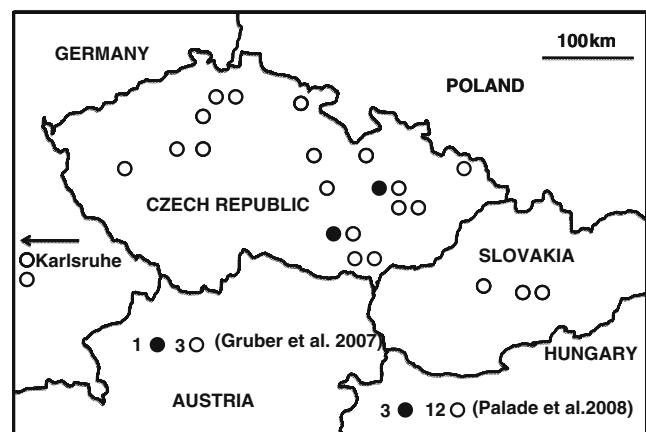
#### New suspect cases of avipoxvirus infection in great tits in central Europe

Photographs of lesions in another 22 great tits with nodular skin lesions were analyzed, and the cutaneous form of bird pox was strongly suspected based on morphological characteristics typical for avipoxvirus etiology. These lesions were either single or multiple, located mainly on the head, especially around the eyes and beak, rarely on the wing flexure, on the shank, and on the finger. We have recorded 17 such cases in the Czech Republic and three in Slovakia, 15 of which were documented from October to April (most of them in December—seven cases) and four in May.

Two additional cases were recorded in Germany, in the Karlsruhe region (Fig. 3).

#### Discussion

Avipoxvirus infection of great tits had not been recorded in central Europe until 2005, although this bird species is quite abundant in this region (Bejcek et al. 1995; Stastny et al. 2006). Moreover, great tits are often subjected to intensive ornithological investigation, including intentional population strengthening by providing bird boxes for nesting. They also are among the species most frequently visiting bird feeders in winter. The first cases of avipoxvirus infection were described recently in Austria and Hungary (Gruber et al. 2007; Palade et al. 2008). In the present work, we describe new cases and suspect cases of avipoxvirus infection in the Czech Republic, Slovakia, and Germany that occurred mostly in winter. Some central European tit populations are migratory, while others are sedentary. We can presume that if avipoxvirus infection would affect the nonmigratory populations, the affected individuals would be detected all year round. Clearly, this was not the case. However, some of the great tits occurring in central Europe in winter (mostly juveniles) belong to populations originating from northeastern Europe and which migrate from northeast to southwest and vice versa (Adamik 2008). Populations wintering in the Czech Republic thus include birds coming from northeastern Europe, and we can speculate that these north European great tits are primarily affected by the avipoxvirus infection which is manifested clinically in winter. This idea is supported by the fact that the other cases described so far



**Fig. 3** Map of cutaneous lesions occurrence in great tits in Central Europe since 2005. Filled circles indicate locations with great tits in which avipoxvirus lesions were examined by electron microscopy and by amplification of specific DNA sequences. Empty circles show locations where suspect avipoxvirus lesions in great tits were diagnosed based on morphological characteristics typical for avipoxvirus etiology. The numbers next to the circles in Austria and Hungary represent numbers of cases described in appropriate references

were detected in Norway and Sweden (Holt and Krogsrud 1973; Literak et al. 2004). The emerging character of avian pox infection among great tits in central Europe is undeniable, but a reason for this sudden increase remains unknown.

Avipoxviruses were demonstrated in both great tits' skin lesions using both the negative staining and ultrathin section methods. Intracytoplasmatic A-type inclusions were found in ultrathin sections, while negative staining showed the presence of M- and C-form particles. M forms of viral particles were oval shaped with randomly arranged filaments on the surface, while C-form particles were brick-shaped without surface filaments as it was described elsewhere (Williams et al. 1962; Noyes 1965; Easterbrook 1966; Prose et al. 1969; Westwood et al. 1964). Using the ultrathin sections method, we detected some developmental stages corresponding to stages described during morphogenesis of avipoxviruses obtained from other bird species (Purcell et al. 1972; Sadasiv 1985; Boulanger et al. 2000; Kulich et al. 2008). Nevertheless, A-type inclusions in great tits differ from the aforementioned poxviruses. Inclusions described in our samples showed a reticular structure formed by vacuoles with double membrane, and we observed filaments located among the vacuoles. Cross sections of these filaments appeared as electron-dense granules. Such inclusion structure is unique and had not previously been described in birds. It resembles most closely vacuolar complexes described in the cytoplasm of swine epidermal cells infected by swine poxvirus (Cheville 1966; Teppema and Boer 1975). Moreover, we have demonstrated core maturation in some of the viral particles present in A-type inclusions. Findings of striated fibrils correspond to the findings in both experimental (Teppema and Boer 1975; Meyer et al. 1997) and natural epidermis infections by swine poxviruses (Smid et al. 1973).

The DNA data show that both our field isolates obtained from skin lesions of great tits have the same sequences, suggesting that the two viruses analyzed could belong to the same avipoxvirus strain/species/cluster. So far as we can assume based on available sequence data, avian poxviruses isolated from great tits show a very high degree of similarity of the 4b core gene sequences compared to poxviruses from other bird hosts, but identical sequences of the 4b core protein gene have been described also in isolates from bird species unrelated to great tits and not belonging to the family Paridae. A low correlation between host species and the 4b core sequence in some bird species (e.g., pigeons and sparrows) was previously observed (Jarmin et al. 2006). Therefore, further sequence analysis, as well as an investigation into biological features as antigenetical differences and virulence for different bird species of the diverse isolates seems to be necessary for accurate taxonomical classification of the great tit isolates. The antigenetical

differences were already demonstrated for avian pox viruses (Lierz et al. 2007).

The ATI gene encodes for insoluble proteins constituting the protein matrix of cytoplasmic ATIs that are thought to protect mature virions from environmental insults, and the presence of this gene is among the features identified for discriminating orthopoxviruses from other poxviruses (Meyer et al. 1997). However, the ATI gene was later found also in fowl poxvirus and canary poxvirus (Afonso et al. 2000; Tulman et al. 2004). Using electron microscopy, we detected ATI formation in cells infected with great tit avipoxvirus, and subsequently, we amplified a portion of the ATI gene. It seems that the ATI gene is important in forming ATI also in great tit avipoxviruses.

**Acknowledgments** We would like to thank S. Bosch, J. Cepak, J. Chytil, P. Kafka, V. Kovar, A. Kristin, P. Kverek, L. Novak, K. Novotny, P. Obona, M. Polak, T. Pospisil, J. Stolarczyk, and M. Strnad for information about findings of great tits skin lesion in the wild. This study was funded by grants nos. MSM6215712402 and MZe0002716202 from the Ministry of Education, Youth, and Sports of the Czech Republic and Ministry of Agriculture of the Czech Republic, respectively. The authors declare that the study complies with the current laws of the Czech Republic.

## References

- Adamik P (2008) Great tit. In: Cepak J, Klvana P, Skopek J, Schropfer L, Jelinek M, Horak D, Formanek J, Zarybnicky J (eds) Czech and Slovak bird migration atlas. Aventinum, Prague, pp 473–474 In Czech with a summary in English
- Afonso CL, Tulman ER, Lu Z, Zsak L, Kutish GF, Rock DL (2000) The genome of fowlpox virus. *J Virol* 74:3815–3831
- Bejcek V, Stastny K, Hudec K (1995) The atlas of wintering birds in the Czech Republic, 1982–1985 (270pp.). H and H Publishing, Jinocany In Czech with a summary in English
- Bolte AL, Meurer J, Kaleta EF (1999) Avian host spectrum of avipoxviruses. *Avian Pathol* 28:415–432
- Boulanger D, Smith T, Skinner MA (2000) Morphogenesis and release of fowlpox virus. *J Gen Virol* 81:675–687
- Buller RM, Arif BM, Black DN, Dumbell KR, Esposito JJ, Lefkowitz EJ, McFadden G, Moss B, Mercer AA, Moyer RW, Skinner MA, Tripathy DN (2005) Family Poxviridae. In: Fauquet CM, Mayo MA, Maniloff J, Desselberger U, Ball LA (eds) Virus taxonomy, classification and nomenclature of viruses, eighth report of the International committee on the taxonomy of viruses. Elsevier Academic Press, San Diego, pp 117–133
- Cheville NF (1966) Cytopathologic changes in fowlpox (turkey origin) inclusion body formation. *Am J Pathol* 49:723–737
- Easterbrook KB (1966) Controlled degradation of vaccinia virions in vitro: an electron microscopic study. *J Ultrastruct Res* 14:484–496
- Goodpasture EW, Anderson K (1962) Isolation of wild avian pox virus including both cytoplasmic and nuclear inclusions. *Am J Pathol* 40:437–453
- Gruber A, Grabensteiner E, Kolodziejek J, Nowotny N, Loupal G (2007) Poxvirus infection in a Great tit (*Parus major*). *Avian Dis* 51:623–625
- Holt G, Krogsrud J (1973) Pox in wild birds. *Acta Vet Scand* 14:201–203
- Illera JC, Emerson BC, Richardson DS (2008) Genetic characterization, distribution and prevalence of avian pox and avian malaria

- in the Berthelot's pipit (*Anthus berthelotii*) in Macaronesia. *Parasitol Res* 103:1435–1443
- Jarmin S, Manvell R, Gough RE, Laidlaw MS, Skinner MA (2006) Avipoxvirus phylogenetics: identification of a PCR length polymorphism that discriminates between the two major clades. *J Gen Virol* 87:2191–2201
- Jarvi SI, Triglia D, Giannoulis A, Farias M, Bianchi K, Atkinson CT (2008) Diversity, origins and virulence of avipoxviruses in Hawaiian forest birds. *Conserv Genet* 9:339–348
- Kulich P, Roubalova E, Dubska L, Sychra O, Smid B, Literak I (2008) Avipoxvirus in blackcaps (*Sylvia atricapilla*). *Avian Pathol* 37:101–107
- Lee LH, Lee KH (1997) Application of the polymerase chain reaction for the diagnosis of fowlpox virus infection. *J Virol Methods* 63:113–119
- Lierz M, Bergmann V, Czerny CP, Lueschow D, Mwanzia J, Prusas C, Hafez HM (2007) Recurrence of an avipox-infection in a collection of captive stone curlew (*Burhinus oedicnemus*). *J Avian Med Surg* 21:50–55
- Literak I, Hromadko M, Blazkova P, Holmberg T (2004) Fagelkoppor vid Ansjon och i Narke (Avian pox in Ansjon and Orebro, Sweden, in Swedish with a summary in English). *Arsrapport Annsjons fagelstation 2003* (Lake Annsjon Bird Observatory, Sweden, Annual Report 2003). *Faglar i Jamtland-Hajedalen* 1:4–7
- Lueschow D, Hoffmann T, Hafez HM (2004) Differentiation of avian poxvirus strains on the basis of nucleotide sequences of 4b gene fragment. *Avian Dis* 48:453–462
- Meyer H, Ropp SL, Esposito JJ (1997) Gene for A-type inclusion body protein is useful for a polymerase chain reaction assay to differentiate orthopoxviruses. *J Virol Methods* 64:217–221
- Noyes WF (1965) Observations on two pox-tumor viruses. *Virology* 25:666–669
- Palade EA, Biro N, Dobos-Kovacs M, Demeter Z, Mandoki M, Rusvai M (2008) Poxvirus infection in Hungarian Great tits (*Parus major*): case report. *Acta Vet Hung* 56:539–546
- Polowinkin P (1901) Beitrag zur pathologischen Anatomie der Taubenpocke. *Schweiz Arch Tierh.* 27:86–109
- Prose PH, Friedman-Kien AE, Vilcek J (1969) *Molluscum contagiosum* virus in adult human skin cultures. *Am J Pathol* 55:349–366
- Purcell DA, Clarke JK, McFerran JB, Hughes DA (1972) The morphogenesis of pigeon poxvirus. *J Gen Virol* 15:79–83
- Sadasiv EC (1985) Morphogenesis of canary poxvirus and its entrance into inclusion bodies. *Am J Vet Res* 46:529–535
- Smid B, Valicek L, Mensik J (1973) Replication of swine pox virus in the skin of naturally infected pigs. Electron microscopy study. *Zbl Vet Med B* 20:603–612
- Stastny K, Bejcek V, Hudec K (2006) The atlas of breeding birds in the Czech Republic, 2001–2003 (463 pp.). Aventinum, Prague In Czech with a summary in English
- Teppema JS, Boer GF (1975) Ultrastructural aspects of experimental swine pox with special reference to inclusion bodies. *Arch Virol* 49:151–163
- Tulman ER, Afonso CL, Lu Z, Zsak L, Kutish GF, Rock DL (2004) The genome of canary poxvirus. *J Virol* 78:353–366
- Weli SC, Traavik T, Tryland M, Coucheron DH, Nilssen O (2004) Analysis and comparison of the 4b core protein gene of avipoxviruses from wild birds: evidence for interspecies spatial phylogenetic variation. *Arch Virol* 149:2035–2046
- Westwood JCN, Harris WJ, Zwartouw HT, Titmussand DHJ, Appleyard G (1964) Studies on the structure of vaccinia virus. *J Gen Microbiol* 34:67–78
- Williams MG, Almeida JD, Howatson AF (1962) Electron microscopy studies on viral skin lesions. A simple and rapid method of identifying virus particles. *Arch Dermatol* 86:290–297