HAL
open science

Recombinant human erythropoietin delays loss of gray matter in chronic schizophrenia

Hannelore Ehrenreich, Torsten Wüstenberg, Martin Begemann, Claudia Bartels, Olaf Gefeller, Sabina Stawicki, Dunja Hinze-Selch, Alexander Mohr, Peter Falkai, Josef B Aldenhoff, et al.

To cite this version:

Hannelore Ehrenreich, Torsten Wüstenberg, Martin Begemann, Claudia Bartels, Olaf Gefeller, et al.. Recombinant human erythropoietin delays loss of gray matter in chronic schizophrenia. Molecular Psychiatry, 2010, 10.1038/mp.2010.51 . hal-00537260

HAL Id: hal-00537260

https://hal.science/hal-00537260v1

Submitted on 18 Nov 2010

HAL is a multi-disciplinary open access archive for the deposit and dissemination of scientific research documents, whether they are published or not. The documents may come from teaching and research institutions in France or abroad, or from public or private research centers.

L'archive ouverte pluridisciplinaire **HAL**, est destinée au dépôt et à la diffusion de documents scientifiques de niveau recherche, publiés ou non, émanant des établissements d'enseignement et de recherche français ou étrangers, des laboratoires publics ou privés.

RE-RE-REVISED MANUSCRIPT

Recombinant human erythropoietin delays loss of gray matter in chronic schizophrenia

T. Wüstenberg, MA[1§], M. Begemann, MD[2§], C. Bartels, PhD[2], O. Gefeller, PhD[3], S. Stawicki, PhD[2], D. Hinze-Selch, MD[4], A. Mohr, MD[1], P. Falkai, MD[5,7], J.B. Aldenhoff, MD[4], M. Knauth, MD[1], K.-A. Nave, PhD[6,7] and H. Ehrenreich, MD[2,7*]

[1]Department of Neuroradiology, Georg-August-University, Göttingen;
[2]Clinical Neuroscience, Max Planck Institute of Experimental Medicine, Göttingen;
[3]Department of Medical Informatics, Biometry, and Epidemiology, University of Erlangen-Nürnberg
[4]Department of Psychiatry and Psychotherapy, Christian-Albrechts-University, Kiel;
[5]Department of Psychiatry and Psychotherapy, Georg-August-University, Göttingen;
[6]Department of Neurogenetics, Max Planck Institute of Experimental Medicine, Göttingen,
[7]DFG Research Center for Molecular Physiology of the Brain, Göttingen,
GERMANY

Note the present address of TW: Department of Psychiatry and Psychotherapy, Charité Universitätsmedizin Berlin, Campus Mitte, Germany

[§]Authors contributed equally to the work

Running title: Erythropoietin delays cortical atrophy in schizophrenia

***Correspondence:**

Prof. Hannelore Ehrenreich, MD, DVM
Division of Clinical Neuroscience
Max Planck Institute of Experimental Medicine
Hermann-Rein Str. 3, 37075 Göttingen, Germany
Tel.: 49-551-3899628
Fax: 49-551-3899670
E-Mail: ehrenreich@em.mpg.de

RE-RE-REVISED MANUSCRIPT

Abstract

Neurodevelopmental abnormalities together with neurodegenerative processes contribute to schizophrenia, an etiologically heterogeneous, complex disease phenotype which has been difficult to model in animals. The neurodegenerative component of schizophrenia is best documented by magnetic resonance imaging (MRI), demonstrating progressive cortical gray matter loss over time. No treatment exists to counteract this slowly proceeding atrophy. The hematopoietic growth factor erythropoietin (EPO) is neuroprotective in animals. Here we show by voxel-based morphometry in 32 human subjects in a placebo-controlled study that weekly high-dose EPO for as little as 3 months halts the progressive atrophy in brain areas typically affected in schizophrenia, including hippocampus, amygdala, nucleus accumbens, and several neocortical areas. Specifically, gray matter protection is highly associated with improvement in attention and memory functions. These findings suggest that a neuroprotective strategy is effective against common pathophysiological features of schizophrenic patients, and strongly encourage follow-up studies to optimize EPO treatment dose and duration.

Key words:
Hematopoietic growth factor, neuroregeneration, neuroprotection, voxel-based morphometry, brain atrophy, cognition, schizophrenia

Introduction

Schizophrenia is the common term of an etiologically and pathophysiologically heterogeneous group of diseases, characterized by psychotic symptoms, loss of affect, social withdrawal and cognitive dysfunction. Neurodegenerative processes on top of neurodevelopmental abnormalities contribute to disease manifestation and progression. The neurodegenerative component of schizophrenia is best reflected by progressive cortical gray matter density (GMD) loss over time[e.g. 1]. This loss is prominent in the early phase of schizophrenia, reaching a slower steady state progression once the disease process has turned into the chronic phase. In this phase of schizophrenia, approximately 0.5% of gray matter are lost yearly compared to 0.2% in healthy individuals[2], and this loss goes hand in hand with increasing functional deficits, in particular cognitive decline, comprising deficits in processing speed, attention, memory, and executive functioning.

No treatment exists to date to counteract these neurodegenerative processes. Clinical studies using various different first and second generation antipsychotics yielded inconsistent results regarding progression of GMD loss[e.g. 3, 4]. Greater GMD loss upon first generation antipsychotics was found transiently in the recovery phase from a first schizophrenic episode despite parallel symptomatic relief comparable to second generation drugs[e.g. 4]. Importantly, in the majority of studies, GMD changes were neither correlated with clinical nor with neurocognitive readouts[e.g. 3, 4]. Cognitive improvements were small and unlikely to be greater than placebo or practice effects[5, 6]. Also, less adverse consequences of an antipsychotic

drug on neurocognition in comparison to its respective comparator drug have been discussed as 'false positive' effects[7].

To explore a neuroprotective strategy in schizophrenia, for which adequate animal models do not exist, we performed a clinical trial with recombinant human EPO. Originally established for the treatment of anemia, this drug is well tolerated, clinically safe, crosses the blood-brain-barrier[8] and possesses multifaceted direct neuroprotective properties[9, 10]. EPO is able to prevent brain atrophy following parietal cortical lesion of juvenile mice[11] or middle cerebral artery occlusion in mice[12], and to improve cognitive performance in various disease models as well as in healthy rodents[8, 13, 14].

We show here that treatment of schizophrenic men over 3 months with weekly high-dose EPO reduces GMD loss in discrete brain regions typically affected in schizophrenia, and that this reduction in GMD loss is strongly associated with improved attention and memory functions.

Patients and Methods

Study design and patients

The protocol for the present double-blind, placebo-controlled randomised study was approved as part of a larger multicenter trial protocol[15] by the ethical committees of the Georg-August-University of Göttingen as well as of the Christian-Albrechts-University, Kiel. Total duration of the study was 2 years. After

written informed consent, own and/or authorized legal representatives, chronic schizophrenic men (N = 32, aged 29-54 years) with a disease duration of ≥10 years, stable medication and disease state (no acute episode within 6 months before start of the study) were included. They had to have a defined cognitive and psychopathological deficit (Repeatable Battery for the Assessment of Neuropsychological Symptoms[16] = RBANS ≥1SD below normal; Positive and Negative Syndrome Scale = PANSS[17], negative ≥20, general ≥48, positive ≤28). Thus, patients with severe positive symptoms (according to their PANSS score) have been excluded in this first study on EPO in schizophrenia. The reasons for this rigorous selection (considering the small number of patients to be included) were: (1) High positive PANSS scores would have severely compromised the evaluation of cognitive outcomes; (2) Acute psychosis with its unpredictable change in state, often also requiring additional intervention, would have made cognitive and perhaps also MRI follow-up testing unreliable; (3) Strict PANSS (all subscales) and RBANS limits were set to ascertain a highly homogenous sample of chronic schizophrenic patients (even at the cost of a difficult recruitment process with a ratio of screened versus included patients amounting to 4:1). Additionally, patients had to be free of other severe diseases, any suspicion of organic psychosis, alcohol or drug abuse, myeloproliferative disorder (including hematocrit ≥50%), allergies against or antibodies to EPO. Patients were treated with a weekly short intravenous infusion (15min) of 40000IU EPO (recombinant human erythropoietin-beta, Roche, Grenzach, Whylen, Germany) or placebo for 12 weeks. Cognitive readouts for the present study were assessed at baseline and at 12

weeks of study drug treatment using the RBANS[16]. Psychopathology rating included the positive, negative and general psychopathological symptoms of schizophrenia as evaluated by the PANSS scales[17]. Blood workup was conducted weekly. MRI was performed at baseline and repeated after 12 weeks of study drug treatment (repetition in the same MR-scanner).

Data acquisition and preprocessing

For analysis of cognitive test results, raw data were subjected to ANCOVA with age as covariate. For determining the composite score out of selected significant RBANS subtests (figure recall, digit span and coding), raw data were z-transformed. Calculation of the z-scores was based on the means and standard deviations of the respective measurements at baseline. MRI scans were conducted on a Siemens Magnetom Sonata (Siemens Medical Systems, Erlangen, Germany) or a Philips Medical Systems MR-scanner (Gyroscan Intera Archieva, Hamburg, Germany), all operating at 1.5 Tesla. A T1-weighted 3-dimensional structural MRI of each subject was acquired (pulse sequence type: ultra fast gradient echo (Siemens: MPRAGE, Philips: 3D TFE), time to repetition (TR): 30ms; echo time (TE): 4.6ms; flip angle: 30°; matrix size: 256×256x150; voxel size of 1×1×1.5mm^3). At the time of data processing, the investigator was neither aware of treatment assignment (EPO or placebo group) nor of any hypothesis regarding EPO effects (increase or decrease of GMD), or of brain regions typically affected in schizophrenia and likely to respond to neuroprotection. In other words, this

investigator, despite performing essentially all imaging/statistical analysis, was initially completely 'blinded'.

Before preprocessing *(a priori),* all structural images were checked for too low signal-to-noise ratio (SNR), usually caused by motion artifacts or wideband and narrowband radiofrequency-noise, respectively. To this end, we calculated slice-wise SNR profiles of each image. The criteria applied were based on the investigations of Wetzel et al[18]. They reported for the T1-weighted gradient echo sequences, also used in our study, an SNR of 23.1±5.2 for gray matter and of 27.8±5.0 for white matter. Thus, we chose an SNR threshold of 20 for ALL slices containing parts of the brain to keep only those images with sufficient quality for further processing. Already a single slice with an SNR below 20 within the slices containing brain tissue was considered a sufficient exclusion criterion for the whole MRI scan (Supplementary Figure 1)[18, 19]. Finally, images from only 32 (of originally 39) patients (16 EPO, 16 placebo) were included in data analysis. The image origin was placed on the anterior commissure, and images were reoriented manually to approximate the anterior and posterior commissure to the horizontal plane.

The Statistical Parametric Mapping 5 (SPM5) Software package (http://www.fil.ion.ucl.ac.uk/spm/) was used for the preprocessing and statistical analysis of the imaging data. The preprocessing of the imaging data was performed corresponding to an established voxel-based morphometry (VBM) protocol[20]. This method minimizes the probability of misclassifications within the tissue segmentation by the introduction of additional preprocessing steps prior to

normalization and subsequent segmentation. Briefly, this method comprises the following steps:

(i) Initially, a group-specific template was generated by normalizing each MR image to the template provided by the Montreal Neurological Institute, using linear (ordinary least square, 12 parameter affine transformation) and nonlinear (modeled by the linear combination of a set of harmonic basis functions, cut-off = 25mm) algorithms[21]. The normalized images were segmented into gray matter, white matter, and cerebrospinal fluid, smoothed with an isotropic Gaussian kernel of 10mm full width at half maximum (FWHM), and separately averaged for gray and white matter. Thus, 2 group- and tissue-specific templates were created with a voxel size of $1x1x1mm^3$.

(ii) MR images (in native space) were segmented into tissue classes, followed by a series of additional automated morphological operations to remove unconnected non-brain voxels from the segments. The gray and white matter images were normalized to the group-specific templates as described in (i).

(iii) The calculated normalization parameters were then reapplied to the structural images and these images were re-sliced to a voxel size of $1x1x1mm^3$. This approach led to improved normalization for the full brain images. It also guaranteed an optimal final segmentation because of the probability maps used as Bayesian priors being located in stereotactic space.

(iv) The normalized structural images were segmented again. Because of local volume effects (growing or shrinking) in nonlinear spatial normalization, a voxel-wise multiplication with the Jacobian determinant (derived from normalization parameters) was performed to preserve the signal within a particular brain region.

(v) Finally, the tissue segments were smoothed with a 10mm FWHM Gaussian kernel[21].

For the following statistical analyses we only utilized those smoothed gray matter tissue segments.

Data analyses

In search of structural treatment effects and their relation to clinical readouts the following analyses were carried out: (1) Due to the factorial character of the presented study, we performed a voxel-wise analysis of covariance (ANCOVA) to identify brain regions showing significant interaction between study medication and evolution of GMD over time of treatment. (2) To verify the regional findings of ANCOVA, we conducted a voxel-wise linear discriminant analysis (vwLDA). (3) Subsequently, regions with joint effects were outlined computing the voxel-wise logical AND-relation between ANCOVA and vwLDA. (4) A region of interest based linear discriminant analysis (rbLDA) was employed to test the association between GMD changes within joint regions and clinical readouts. Details of these approaches are explained in the following paragraphs.

Regional gray matter density analysis

(1) A voxel-wise 2-factorial analysis of covariance for repeated measurements (ANCOVA, between subject factor: TREATMENT, within subject factor: TIME, covariates: age, MR-scanner, study site) was applied to identify gray matter regions which show an interaction of TREATMENT*TIME. These regions were anatomically and, if possible, probabilistically cytoarchitectonically identified using the Anatomy Toolbox as implemented in SPM5[22]. To test for the direction of changes in GMD, we calculated post-hoc t-tests for the individual GMD values at the peak voxel positions. For this purpose, we adjusted the data for the group specific median of GMD in the first MRI.

(2) To verify the results of the ANCOVA, a voxel-wise linear discriminant analysis (vwLDA) using the pre- and post-treatment GMD (corrected for age, MR-scanner and study site) was calculated as implemented in the statistics toolbox[23] of MATLab Version 7.4 (Mathworks, Inc., Natick, MA). The estimated discriminant function separates the data into 2 subsets. Goodness of classification (GoC), the corresponding χ^2 value and the error probability for false positive findings were calculated.

(3) Although potentially important brain regions might have been identified by only one statistical approach (ANCOVA or vwLDA, see Supplementary Tables 1 and 2), we decided to go for a more conservative procedure, particularly in light of the small sample size potentially increasing the instability of results. Anatomical

regions with a treatment effect detectable by only one of the before mentioned statistical analyses were not considered. In fact, to yield more robust results with respect to regional differences, we calculated the spatial intersection of both statistical maps. For this calculation, only voxels which passed a significance threshold of $p<0.005$ (uncorrected for multiple comparisons) and a minimal cluster size of $100mm^3$ were used.

A mean anatomical image was calculated from the normalized T1-weighted images of all 32 patients. The 3 statistical maps calculated (ANCOVA: Interaction TREATMENT*TIME; vwLDA; Intersection Interaction$\cap$vwLDA) were overlaid on this mean anatomical image using MRIcron software (http://www.sph.sc.edu/comd/rorden/mricron/).

Analysis of associations between joint regions of GMD change and clinical readouts

A region of interest based linear discriminant analysis (rbLDA) was performed in order to demonstrate interactions between changes of GMD (corrected for age, MR-scanner and study site) over time [z(ΔGMD)] and cognition (corrected for age), determined as sum of z-scaled longitudinal differences for selected RBANS subscales, i.e. cognitive sum score of figure recall, digit span and coding [Σz(ΔCSS)]. Likewise, possible interactions between [z(ΔGMD)] and psychopathology (PANSS subscales) were evaluated. Moreover, potential effects

of hemoglobin or hematocrit changes over time (ΔHb or ΔHct week 12 minus baseline) on cognition [Σz(ΔCSS)] were controlled for by employing ANCOVA (covariates age and ΔHb or ΔHct).

Results

Chronic schizophrenic men were randomly assigned to receive weekly intravenous infusions of high-dose (40000IU) EPO (N=16) versus placebo (N=16) over 12 weeks in a double-blind setting. Patient characteristics were found well matched in both groups (Table 1). Only age tended to be different, with EPO patients being slightly younger. Therefore, all calculations include age correction together with correction for MR-scanner and study site (see above).

EPO prevents progressive gray matter loss in discrete brain areas typically affected in schizophrenia

VBM results revealed a recognizable neuroprotective effect of EPO in schizophrenic patients after a treatment period of only 12 weeks (Table 2, Figure 1), extending to a total of 4470mm^3 of brain volume (sum of all clusters listed in Supplementary Table 1, referring to ANCOVA). In the **voxel-wise 2-factorial analysis of covariance for repeated measurements (ANCOVA),** the effect of EPO treatment became apparent in the interaction TREATMENT*TIME,

demonstrating clearly reduced evolution of GMD loss upon EPO compared to placebo. Such interaction was noted in several frontal and temporal cortical and subcortical regions known for cortical thinning in schizophrenia. The most pronounced and extensive effect (~860mm^3) of EPO was found in the right ventral frontal cortex including ventral striatum with nucleus accumbens and rectal gyrus. In the left nucleus accumbens, a smaller effect (~120mm^3) was noted. In frontal regions, effects were found in the ventral part of the right anterior cingulate gyrus (~460mm^3), the right middle frontal gyrus (~140mm^3) as well as in the left insula (~200mm^3). Several perisylvian cortical regions of the left hemisphere, like inferior frontal gyrus, including Broca's area (~680mm^3), inferior parietal cortex (~660mm^3), including the parietal operculum and the supramarginal gyrus, as well as 2 clusters of about 290mm^3 and 150mm^3 volume in the middle temporal gyrus exhibited a delay in cortical atrophy upon EPO. In the right temporal cortex, the GMD in the temporal pole was influenced by EPO treatment (~330mm^3). Effects of treatment were further detectable in the left entorhinal cortex (~340mm^3), specifically the fusiform gyrus, several parts of the hippocampus (cornu ammonis, subicular complex, fascia dentata) and a small part of the superficial section and laterobasal nucleus of the amygdala (~250mm^3) (Supplementary Table 1).

Compared to ANCOVA, the **voxel-wise linear discriminant analysis (vwLDA) for morphological data** provided more spatially extended results (~17470mm^3) (Table 2, Figure 1, and Supplementary Table 2). GMD data from the 2 experimental groups, corrected for age, MR-scanner and study site, arranged in a

2-dimensional scatter plot, can be separated using a linear discriminant function. For discrete brain regions, data allow to predict with an accuracy of ≥75% whether they are derived from EPO or placebo treated individuals. Similar to ANCOVA, clusters with significant classification accuracy are located mainly in frontal and temporal regions. The largest cluster with significant differences in GMD evolution between EPO and placebo (~2470mm^3) and 2 additional distinct regions of about 440mm^3 and 430mm^3 volumes were found in the medial frontal cortex associated with primary and supplementary motor function. In the area of the left medial wall, 2 clusters in middle cingulate structures (~240mm^3 and ~210mm^3) also show treatment effects. Further discriminant effects in the left frontal lobe were found in the inferior frontal gyrus (~1840mm^3, Brodmann areas 44 and 45), superior frontal gyrus (~740mm^3) and precentral gyrus (~220mm^3). Effects detected with a peak location in the right ventral frontal cortex including nucleus accumbens, head of caudate nucleus and anterior part of putamen were comparable to those found in the ANCOVA (~400mm^3). In the left hemisphere, effects were noted in insula (~260mm^3) and more extended in superior (~1130mm^3), middle (~390mm^3) and inferior temporal gyrus (~420mm^3). Also, a part of the transverse temporal gyrus (~190mm^3, Heschl) was affected. In ventromedial occipital and temporal regions, we found effects in left fusiform gyrus and several left hippocampal regions (subiculum, entorhinal cortex) (~730mm^3). Slightly weaker effects were observed for other hippocampal (cornu ammonis, subiculum, fascia dentata) and amygdala clusters (laterobasal nucleus, superficial section) in left temporal regions (~570mm^3) as well as for the superior temporal gyrus (~230mm^3). More

pronounced effects were noted in homologous regions of the right hemisphere (~1540mm^3). In the parietal lobe, 2 clusters are located in the left postcentral gyrus (~930mm^3) and parietal regions containing the left angular gyrus (~1050mm^3) and parts of superior and inferior parietal lobules (~330mm^3). Even though weaker as in the left hemisphere, significant treatment effects were detected also in the right postcentral gyrus (~340mm^3). Occipital regions, comprising superior (~260mm^3) and middle gyrus (~370mm^3), as well as the left cuneus (~1200mm^3), calcarine sulcus and lingual gyrus (~760mm^3) showed significant EPO effects (Supplementary Table 2).

To further increase the probability of detecting true regional changes in GMD upon treatment, particularly in light of the small patient sample size, we chose a more conservative procedure: We calculated the **spatial intersection of the 2 statistical maps, ANCOVA and vwLDA** (Table 2, Figure 1). This intersection uncovers the regions with methodologically independent findings for the treatment effect and extends over an area of about 1400mm^3. Thereby, ANCOVA and vwLDA show a mean overlap of about 19% of their volume (Supplementary Table 3). Joint effects were found in left medial ventral temporal lobe: The first cluster (~290mm^3) covers entorhinal cortex and hippocampal subiculum. The second cluster (~200mm^3) contains hippocampal subregions cornu ammonis, subiculum, fascia dentata as well as a superficial section and the laterobasal nucleus of amygdala. Great overlap (~290mm^3) between ANCOVA and vwLDA results was found in inferior frontal cortex within Broca's area (BA45). Also in frontal lobe about

240mm^3 of right ventral striatal areas with nucleus accumbens belong to the spatial intersection. Further overlap (~240mm^3) was detected in left sided inferior parietal cortex comprising supramarginal gyrus and a part of parietal operculum (OP1). Finally, a focal joint effect was found in the posterior part of the left middle temporal gyrus (~140mm^3).

EPO induced reduction of gray matter loss in specific brain areas is associated with cognitive but not psychopathological improvement

In order to further elucidate the clinical significance of these VBM findings, we explored a potential relationship between protection of GMD and increase in cognitive performance. **ANCOVA with age as covariate** had revealed a highly significant improvement of EPO as compared to placebo patients in attention/memory functions from baseline to the 12-week treatment time point, even though an improvement was also measurable in the placebo group[15]. In further exploratory analyses on the MRI subgroup of patients (N=32), the sum score of the neuropsychological tests figure recall, digit span and coding showed the strongest age-corrected interaction TREATMENT*TIME (p=0.003) which was essentially unaffected by introducing ΔHb or ΔHct as further covariates (interaction TREATMENT*TIME p=0.018 and p=0.016, respectively). Therefore, we computed an additional **region of interest based LDA (rbLDA)** to investigate the relationship between this cognitive sum score (CSS) and changes in GMD. For this purpose, GMD difference in all 6 voxels with the maximal joint effect between

ANCOVA and vwLDA were z-scaled for each patient [z(ΔGMD)] (Table 2). In addition, the sum score of the z-scaled longitudinal differences in the 3 neuropsychological tests was calculated [Σz(ΔCSS)] (Table 2). The rbLDA, based on z(ΔGMD) and Σz(ΔCSS), yielded highly significant results in goodness of classification for all 6 clusters (Table 2, Figure 1).

Similar to cognitive readouts, all schizophrenic patients, independent of the treatment group, improved over the 12 weeks of study in psychopathology scores (PANSS). In contrast to cognition, however, showing a significantly better outcome upon EPO, PANSS scores improved in both placebo and EPO patients to a comparable degree[15]. Accordingly, there was no association of GMD in any of the brain regions of interest with positive, negative and general psychopathological symptoms of schizophrenia in either treatment group (data not shown). This is in distinction to the clear relation between GMD and cognition.

Discussion

Collectively, these data suggest that progressive loss of cortical GMD in discrete brain regions of a highly homogeneous cohort of chronic schizophrenic patients is significantly reduced during EPO treatment over a period as short as 12 weeks. Clear interactions between TREATMENT*TIME were found in cortical and subcortical regions, typically affected in schizophrenia[24]. Protection of GMD in

cortical areas was associated with better cognitive performance. Thus, provided that these results can be consolidated in a larger clinical trial, perhaps extending now to a patient population to be recruited with less strict eligibility criteria, EPO would be the first hopeful compound for prevention of cortical GMD loss and improvement of neurocognition.

Certain brain regions deserve particular attention in this study. These are the regions that displayed the most prominent overlap between ANCOVA and vwLDA, and where significant relationships between cognitive and GMD changes were detected by rbLDA. In mesolimbic structures, hippocampus and amygdala, known to undergo volume reduction[24-27] and to be linked to attention and memory deficits in schizophrenia[28-35], EPO prevented GMD loss as shown by ANCOVA and vwLDA. An association of GMD changes and cognition was documented by rbLDA, with EPO patients having a clearly better outcome. Similarly, the fusiform gyrus, found to be reduced in volume in chronic schizophrenia[36-38] benefited from EPO treatment.

Also the inferior frontal gyrus, a brain area involved in semantic processing and integration[39, 40], has previously been found to undergo GMD loss in schizophrenia[41], and showed protection by EPO in the present study. Another area with remarkable overlap of EPO effects in both ANCOVA and vwLDA was the left middle temporal gyrus. The GMD alterations found here were again correlated with cognition according to rbLDA. This brain area is engaged in auditory and language processing, visual perception and multimodal sensory integration[36, 42-44]. Reduced

GMD volumes in temporal lobe have also been associated with auditory hallucinations[45]. Thus, EPO prevents GMD reductions in temporal areas consistently found associated with hallucinations and delusions in schizophrenia. To turn this EPO effect into clinical benefit in a chronic schizophrenic population with long-term antipsychotic pretreatment and low positive scores at study entry (as required inclusion criterion), however, may take more than 3 months. Along these lines, there was no difference in positive or negative symptom scoring nor in general psychopathology between EPO and placebo treated patients despite improvement in cognition upon EPO.

The inferior parietal cortex has been implicated in sensory integration, body image, concept of self, and executive function[46]. Schizophrenic patients show reduced GMD in the left inferior parietal lobule[47]. Again, this area was protected by EPO treatment and protection was associated with improved cognition. In the right nucleus accumbens, known to be associated with motivation/reward and to dysfunction in schizophrenia[48], GMD protection and cognitive amelioration were also interrelated in our patient population.

An interesting observation is the lateralization of the morphological effects: Whereas only the nucleus accumbens showed EPO-mediated prevention of GMD loss on the right hemisphere, all other regions with EPO effects, hippocampus, amygdala, fusiform gyrus, middle temporal gyrus, inferior frontal gyrus, and inferior parietal cortex exhibited a prominent effect on the left hemisphere. The unequal distribution of GMD loss is consistent with earlier reports on selective cortical

thinning[24] including work comparing effects of antipsychotics[4, 49]. The basis for the lateralized preference of EPO-mediated GMD protection is still unclear but likely indicates areas with most progressive neurodegeneration inherent to the disease process.

Whereas it deems logical that acute loss of GMD might lead to negative consequences with respect to brain function and, accordingly, prevention of this loss should maintain or improve function, this association has still not been proven by the various studies investigating effects of antipsychotics on brain dimensions and functions[e.g. 3, 4]. In fact, during the time of most progressive GMD loss in acute first episode schizophrenia, improvement of clinical readouts, independent of the type of antipsychotic applied, can be observed[4]. This seemingly contradictory finding may change upon chronicity of an illness. In an acute disease state, the cellular / molecular underpinnings of rapid brain matter reduction most likely differ from those contributing to the slowly progressing brain atrophy in a more chronic condition. In the present study, reduction of GMD loss and associated improvement of cognitive performance have been observed upon neuroprotective treatment with EPO in chronic schizophrenic patients. A likewise effectiveness of EPO treatment in acute disease states, e.g. first episode schizophrenia, still needs to be demonstrated.

Even though in the present study, prevention of GMD loss in discrete brain areas might explain the improved cognitive performance of EPO treated chronic schizophrenic subjects, the cellular mechanisms involved remain to be determined

which, however, is impossible in humans. In rodents, EPO is not only neuroprotective[9, 10]. EPO also improves neuroplasticity, synapse formation and neuronal process outgrowth[13, 14, 50], all mechanisms potentially important for higher cortical functions, but with unclear relationship to the halt of brain atrophy. Since an increase in the number of microglia in schizophrenic brains might add to the gradual loss of axons and synapses through synaptic stripping[51], a neuroprotective effect of EPO via prevention of microgliosis and injury-related cortical tissue loss, as recently demonstrated in mice[11, 52] could play a role in this context. A potential contribution of the EPO induced increase in hemoglobin / hematocrit (and thus increased tissue oxygenation) to cognitive improvement / protection of GMD cannot be entirely excluded at this point but seems unlikely in light of the following points: (1) No influence of blood parameters was found upon their addition as covariates to ANCOVA in the present study. (2) EPO is known to pass an intact blood-brain-barrier in schizophrenic patients and to act directly on neural cells that express EPO receptor[8, 9]. (3) Non-hematopoietic EPO analogues show effects on the brain comparable to those of EPO[53].

Taken together, the observations that EPO is the first compound promising to prevent progression of brain atrophy and to improve cognitive performance in humans should encourage further basic and clinical research, including prevention strategies in first episode schizophrenia.

Acknowledgements

We would like to express our gratitude to Ruth Schubert, Charité-University Medicine Berlin, Germany, for her ideas regarding the statistical data analysis. This study has been supported by the Max-Planck-Society, the DFG Research Center for Molecular Physiology of the Brain (CMPB) as well as by private donations.

Conflict of interest

HE holds a user patent for the treatment of schizophrenia with EPO.

Supplementary information

Supplementary information (3 Tables, 1 Figure) is available at *Molecular Psychiatry*'s website.

References

1 Thompson PM, Vidal C, Giedd JN, Gochman P, Blumenthal J, Nicolson R, et al. Mapping adolescent brain change reveals dynamic wave of accelerated gray matter loss in very early-onset schizophrenia. *Proc Natl Acad Sci U S A*. 2001;98:11650-11655.

2 Hulshoff Pol HE, Kahn RS. What happens after the first episode? A review of progressive brain changes in chronically ill patients with schizophrenia. *Schizophr Bull*. 2008;34:354-366.

3 Crespo-Facorro B, Roiz-Santianez R, Perez-Iglesias R, Pelayo-Teran JM, Rodriguez-Sanchez JM, Tordesillas-Gutierrez D, et al. Effect of antipsychotic drugs on brain morphometry. A randomized controlled one-year follow-up study of haloperidol, risperidone and olanzapine. *Prog Neuropsychopharmacol Biol Psychiatry*. 2008;32:1936-1943.

4 Thompson PM, Bartzokis G, Hayashi KM, Klunder AD, Lu PH, Edwards N, et al. Time-lapse mapping of cortical changes in schizophrenia with different treatments. *Cereb Cortex*. 2009;19:1107-1123.

5 Goldberg TE, Goldman RS, Burdick KE, Malhotra AK, Lencz T, Patel RC, et al. Cognitive improvement after treatment with second-generation antipsychotic medications in first-episode schizophrenia: is it a practice effect? *Arch Gen Psychiatry*. 2007;64:1115-1122.

6 Keefe RS, Mohs RC, Bilder RM, Harvey PD, Green MF, Meltzer HY, et al. Neurocognitive assessment in the Clinical Antipsychotic Trials of Intervention Effectiveness (CATIE) project schizophrenia trial: development, methodology, and rationale. *Schizophr Bull*. 2003;29:45-55.

7 Carpenter WT, Gold JM. Another view of therapy for cognition in schizophrenia. *Biol Psychiatry*. 2002;51:969-971.

8 Ehrenreich H, Degner D, Meller J, Brines M, Béhé M, Hasselblatt M, et al. Erythropoietin: a candidate compound for neuroprotection in schizophrenia. *Mol Psychiatry*. 2004;9:42-54.

9 Brines M, Cerami A. Emerging biological roles for erythropoietin in the nervous system. *Nat Rev Neurosci*. 2005;6:484-494.

10 Sirén AL, Fasshauer T, Bartels C, Ehrenreich H. Therapeutic Potential of Erythropoietin and its Structural or Functional Variants in the Nervous System. *Neurotherapeutics*. 2009;6:108-127.

11 Sirén AL, Radyushkin K, Boretius S, Kämmer D, Riechers C-C, Natt O, et al. Global brain atrophy after unilateral parietal lesion and its prevention by erythropoietin. *Brain*. 2006;129:480-489.

12 Taguchi A, Wen Z, Myojin K, Yoshihara T, Nakagomi T, Nakayama D, et al. Granulocyte colony-stimulating factor has a negative effect on stroke outcome in a murine model. *European Journal of Neuroscience*. 2007;26:126-133.

13 El-Kordi A, Radyushkin K, Ehrenreich H. Erythropoietin improves operant conditioning and stability of cognitive performance in mice. *BMC Biology*. 2009;7:37.

14 Adamcio B, Sargin D, Stradomska A, Medrihan L, Gertler C, Theis F, et al. Erythropoietin enhances hippocampal long-term potentiation and memory. *BMC Biol*. 2008;6:37.

15 Ehrenreich H, Hinze-Selch D, Stawicki S, Aust C, Knolle-Veentjer S, Wilms S, et al. Improvement of cognitive functions in chronic schizophrenic patients by recombinant human erythropoietin. *Mol Psychiatry*. 2007;12:206-220.

16 Randolph C. *RBANS Manual - Repeatable Battery for the Assessment of Neuropsychological Status*. TX: Psychological Corporation: Harcourt; 1998.

17 Kay SR, Fiszbein A, Opler LA. The positive and negative syndrome scale (PANSS) for schizophrenia. *Schizophr Bull*. 1987;13:261-276.

18 Wetzel SG, Johnson G, Tan AG, Cha S, Knopp EA, Lee VS, et al. Three-dimensional, T1-weighted gradient-echo imaging of the brain with a volumetric interpolated examination. *AJNR Am J Neuroradiol*. 2002;23:995-1002.

19 Shuter B, Yeh IB, Graham S, Au C, Wang SC. Reproducibility of brain tissue volumes in longitudinal studies: effects of changes in signal-to-noise ratio and scanner software. *Neuroimage*. 2008;41:371-379.

20 Good CD, Johnsrude IS, Ashburner J, Henson RN, Friston KJ, Frackowiak RS. A voxel-based morphometric study of ageing in 465 normal adult human brains. *Neuroimage*. 2001;14:21-36.

21 Ashburner J, Friston KJ. Voxel-based morphometry-the methods. *Neuroimage*. 2000;11:805-821.

22 Eickhoff SB, Stephan KE, Mohlberg H, Grefkes C, Fink GR, Amunts K, et al. A new SPM toolbox for combining probabilistic cytoarchitectonic maps and functional imaging data. *Neuroimage*. 2005;25:1325-1335.

23 Krzanowski WJ. *Principles of Multivariate Analysis*. Oxford: Oxford University Press; 1988.

24 Glahn DC, Laird AR, Ellison-Wright I, Thelen SM, Robinson JL, Lancaster JL, et al. Meta-analysis of gray matter anomalies in schizophrenia: application of anatomic likelihood estimation and network analysis. *Biol Psychiatry*. 2008;64:774-781.

25 Ellison-Wright I, Glahn DC, Laird AR, Thelen SM, Bullmore E. The anatomy of first-episode and chronic schizophrenia: an anatomical likelihood estimation meta-analysis. *Am J Psychiatry*. 2008;165:1015-1023.

26 Baiano M, Perlini C, Rambaldelli G, Cerini R, Dusi N, Bellani M, et al. Decreased entorhinal cortex volumes in schizophrenia. *Schizophr Res*. 2008;102:171-180.

27 Sim K, DeWitt I, Ditman T, Zalesak M, Greenhouse I, Goff D, et al. Hippocampal and parahippocampal volumes in schizophrenia: a structural MRI study. *Schizophr Bull*. 2006;32:332-340.

28 Killgore WD, Rosso IM, Gruber SA, Yurgelun-Todd DA. Amygdala volume and verbal memory performance in schizophrenia and bipolar disorder. *Cogn Behav Neurol*. 2009;22:28-37.

29 Carter CS, Mintun M, Nichols T, Cohen JD. Anterior cingulate gyrus dysfunction and selective attention deficits in schizophrenia: [15O]H2O PET study during single-trial Stroop task performance. *Am J Psychiatry*. 1997;154:1670-1675.

30 Sanfilipo M, Lafargue T, Rusinek H, Arena L, Loneragan C, Lautin A, et al. Cognitive performance in schizophrenia: relationship to regional brain volumes and psychiatric symptoms. *Psychiatry Res*. 2002;116:1-23.

31 Garver DL, Holcomb JA, Christensen JD. Cerebral cortical gray expansion associated with two second-generation antipsychotics. *Biol Psychiatry*. 2005;58:62-66.

32 Rametti G, Segarra N, Junque C, Bargallo N, Caldu X, Ibarretxe N, et al. Left posterior hippocampal density reduction using VBM and stereological MRI procedures in schizophrenia. *Schizophr Res*. 2007;96:62-71.

33 Otsuka Y, Osaka N, Osaka M. Functional asymmetry of superior parietal lobule for working memory in the elderly. *Neuroreport*. 2008;19:1355-1359.

34 Wolf RC, Höse A, Frasch K, Walter H, Vasic N. Volumetric abnormalities associated with cognitive deficits in patients with schizophrenia. *European Psychiatry*. 2008;23:541-548.

35 Schirmer TN, Dorflinger JM, Marlow-O'Connor M, Pendergrass JC, Hartzell A, All SD, et al. FMRI indices of auditory attention in schizophrenia. *Prog Neuropsychopharmacol Biol Psychiatry*. 2009;33:25-32.

36 Onitsuka T, Shenton ME, Kasai K, Nestor PG, Toner SK, Kikinis R, et al. Fusiform gyrus volume reduction and facial recognition in chronic schizophrenia. *Arch Gen Psychiatry*. 2003;60:349-355.

37 Bleich-Cohen M, Strous RD, Even R, Rotshtein P, Yovel G, Iancu I, et al. Diminished neural sensitivity to irregular facial expression in first-episode schizophrenia. *Hum Brain Mapp*. 2009;30:2606-2616.

38 O'Daly OG, Frangou S, Chitnis X, Shergill SS. Brain structural changes in schizophrenia patients with persistent hallucinations. *Psychiatry Res*. 2007;156:15-21.

39 Jeong B, Wible CG, Hashimoto RI, Kubicki M. Functional and anatomical connectivity abnormalities in left inferior frontal gyrus in schizophrenia. *Hum Brain Mapp*. 2009.

40 Zhu Z, Zhang JX, Wang S, Xiao Z, Huang J, Chen HC. Involvement of left inferior frontal gyrus in sentence-level semantic integration. *Neuroimage*. 2009;47:756-763.

41 Ellison-Wright I, Glahn DC, Laird AR, Thelen SM, Bullmore E. The Anatomy of First-Episode and Chronic Schizophrenia: An Anatomical Likelihood Estimation Meta-Analysis. *Am J Psychiatry*. 2008;165:1015-1023.

42 Hickok G, Poeppel D. The cortical organization of speech processing. *Nat Rev Neurosci*. 2007;8:393-402.

43 Beeli G, Esslen M, Jancke L. Time Course of Neural Activity Correlated with Colored-Hearing Synesthesia. *Cereb Cortex*. 2007.

44 Onitsuka T, Shenton ME, Salisbury DF, Dickey CC, Kasai K, Toner SK, et al. Middle and inferior temporal gyrus gray matter volume abnormalities in chronic schizophrenia: an MRI study. *Am J Psychiatry*. 2004;161:1603-1611.

45 Allen P, Larøi F, McGuire PK, Aleman A. The hallucinating brain: A review of structural and functional neuroimaging studies of hallucinations. *Neuroscience & Biobehavioral Reviews*. 2008;32:175-191.

46 Torrey EF. Schizophrenia and the inferior parietal lobule. *Schizophr Res*. 2007;97:215-225.

47 Wolf RC, Hose A, Frasch K, Walter H, Vasic N. Volumetric abnormalities associated with cognitive deficits in patients with schizophrenia. *Eur Psychiatry*. 2008;23:541-548.

48 Juckel G, Schlagenhauf F, Koslowski M, Wustenberg T, Villringer A, Knutson B, et al. Dysfunction of ventral striatal reward prediction in schizophrenia. *Neuroimage*. 2006;29:409-416.

49 Lieberman JA, Tollefson GD, Charles C, Zipursky R, Sharma T, Kahn RS, et al. Antipsychotic drug effects on brain morphology in first-episode psychosis. *Arch Gen Psychiatry*. 2005;62:361-370.

50 Sakanaka M, Wen TC, Matsuda S, Masuda S, Morishita E, Nagao M, et al. In vivo evidence that erythropoietin protects neurons from ischemic damage. *Proc Natl Acad Sci U S A*. 1998;95:4635-4640.

51 Trapp BD, Wujek JR, Criste GA, Jalabi W, Yin X, Kidd GJ, et al. Evidence for synaptic stripping by cortical microglia. *Glia*. 2007;55:360-368.

52 Sargin D, Hassouna I, Sperling S, Siren AL, Ehrenreich H. Uncoupling of neurodegeneration and gliosis in a murine model of juvenile cortical lesion. *Glia*. 2009;57:693-702.

53 Leist M, Ghezzi P, Grasso G, Bianchi R, Villa P, Fratelli M, et al. Derivatives of erythropoietin that are tissue protective but not erythropoietic. *Science*. 2004;305:239-242.

Table 1: Patient characteristics at baseline

	EPO N=16 M (±s.d.)	Placebo N=16 M (±s.d.)	2 Sample t-test	
			$T_{(30)}$	p
Age (years)	38.8 (7.5)	43.8 (6.4)	**2.0**	**0.052**
Duration of disease	15.0 (8.1)	18.4 (5.6)	**1.4**	**0.173**
Years of education	12.3 (3.7)	13.0 (3.6)	**0.5**	**0.596**
MWT-B (raw data; scale range 0-37) *(premorbid intelligence estimate)*	26.3 (9.3)	29.5 (5.8)	**1.2**	**0.254**
PANSS Positive Scale (scale range 7-49)	14.4 (4.1)	15.5 (4.2)	**0.7**	**0.469**
PANSS Negative Scale (scale range 7-49)	29.6 (5.9)	27.4 (4.7)	**-1.2**	**0.255**
PANSS General Scale (scale range 16-112)	54.1 (10.0)	49.9 (4.8)	**-1.5**	**0.146**
Chlorpromazine equivalents	473.4 (346.0)	445.5 (455.2)	**-0.2**	**0.846**
	EPO N=16 n (%)	**Placebo N=16 n (%)**	**χ^2-test**	
			$\chi^2_{(30)}$	p
Unemployed	7 (43.8%)	7 (43.8%)	**0.0**	**1.000**
Patients without partnership	16 (100%)	14 (87.5%)	**2.1**	**0.144**
Patients with children	3 (18.8%)	2 (12.5%)	**0.2**	**0.626**
Antipsychotic medication 1st generation 2nd generation combination	8 (50.0%) 2 (12.5%) 6 (37.5%)	7 (43.8%) 6 (37.5%) 3 (18.8%)	**3.1**	**0.216**
Anticholinergic drugs	2 (12.5%)	4 (25.0%)	**0.8**	**0.365**
Patients with benzodiazepine treatment	4 (25.0%)	2 (12.5%)	**0.8**	**0.365**
Cigarette smoking non-smoker smoker ex-smoker	4 (25.0%) 11 (68.8%) 1 (6.2%)	2 (12.5%) 11 (68.8%) 3 (18.8%)	**1.7**	**0.435**
Right handed	14 (87.5%)	14 (87.5%)	**0.0**	**1.00**

Abbreviations: EPO - erythropoietin; M - mean; s.d. - standard deviation; MWT-B - Mehrfach-Wortschatz-Intelligenztest; PANSS - Positive and Negative Syndrome Scale; N - sample size; n - number of subjects

Table 2: Statistical results demonstrating regional GMD and cognitive changes over 12 weeks of EPO versus placebo treatment in a cohort of chronic schizophrenic men

	Anatomical region Cytoarchitectonic probability (P_C)	Intersection cluster size [mm^3]	MNI-coordinates [mm] ANCOVA *vwLDA*			ANCOVA		Post-hoc t-tests				vwLDA GMD (pre) versus GMD (post)			rbLDA Σz(ΔCSS) versus z(ΔGMD)		
								Paired Placebo (pre > post) *EPO (pre > post)*		2 Sample post (Placebo > EPO)							
			x	y	z	$F_{(1,59)}$	p	$T_{(15)}$	p	$T_{(30)}$	p	GoC [%]	$\chi^2_{(2)}$	p	GoC [%]	$\chi^2_{(2)}$	p
1	**Fusiform gyrus** (left) **Hippocampus** (left) EC: P_C=0.5 SUB: P_C=0.3	293	-32 *-36*	-16 *-16*	-32 *-34*	10.9	**.002**	1.6 *-1.0*	**.142** ***.338***	-2.4	**.020**	87	9.6	**.008**	66	8.7	**.013**
2	**Inferior frontal gyrus** (left) BA45: P_C=0.2	286	-47 *-45*	+26 *+23*	-8 *-9*	13.6	**.001**	1.9 *-1.3*	**.082** ***.229***	-3.2	**.004**	87	13.5	**.001**	72	11.5	**.003**
3	**Inferior parietal cortex** (left) PFop: P_C= 0.6 PF: P_C= 0.3 OP1: P_C= 0.3	242	-60 *-59*	-31 *-30*	+22 *+20*	11.8	**.001**	2.0 *-0.5*	**.064** ***.613***	-2.1	**.041**	78	9.3	**.010**	66	8.7	**.013**
4	**Nucleus accumbens** (right)	236	+9 *+6*	+10 *+9*	-11 *-10*	15.2	**.001**	2.3 *-0.6*	**.038** ***.562***	-3.5	**.001**	81	8.5	**.014**	72	9.3	**.009**
5	**Hippocampus** (left) CA: P_C=0.8 FD: P_C=0.7 SUB: P_c=0.4 **Amygdala** (left) LB: P_C=0.4 SF: P_C=0.2	196	-25 *-26*	-13 *-15*	-23 *-22*	10.7	**.002**	1.5 *-1.3*	**.144** ***.199***	-2.3	**.027**	81	9.0	**.011**	72	11.6	**.003**
6	**Middle temporal gyrus** (left)	139	-62 *-62*	-50 *-54*	+4 *+5*	10.2	**.002**	1.6 *-1.1*	**.132** ***.294***	-2.1	**.045**	78	8.9	**.012**	72	10.2	**.006**

Legend to Table 2:

Statistical results demonstrating GMD and cognitive changes over 12 weeks of EPO versus placebo treatment in a cohort of chronic schizophrenic men

Results of inference statistical tests within the intersection of brain regions showing a significant interaction TREATMENT*TIME for ANCOVA and a significant goodness of classifications (GoC) in the voxel-wise linear discriminant analysis (vwLDA) are presented. ANCOVA and vwLDA results include correction for age, MR-scanner and study site. The intersection contains all voxels which pass a statistical threshold $p<0.005$ (uncorrected for multiple comparisons, minimum cluster size $100mm^3$, adjusted for non-isotropic smoothness). The coordinates of the voxel with the maximal joint effect within the cluster are given in millimeters according to the stereotactical reference system defined by the brain template from Montreal Neurological Institute (MNI). Notably, dependent on the maximum effects obtained with the respective statistical procedure, MNI coordinates differ slightly (compare Figure 1). If available, the cytoarchitectonic probability (P_C) for anatomical structures within the current cluster is specified. The results for the post-hoc paired t-tests of within group differences are displayed for the placebo group in regular letters, for the EPO group (underneath) in italic letters. The last 3 columns display the results for region of interest based LDA (rbLDA). Information on brain regions and cytoarchitectonic probability is derived from [22].

Abbreviations: EC – entorhinal cortex; SUB – subiculum; BA45 – Brodmann area 45; PFop – rostroventral part of inferior parietal cortex / supramarginal gyrus; PF – caudal part of inferior parietal cortex / supramarginal gyrus; OP1 – parietal operculum; CA – cornu ammonis; FD – fascia dentata; LB – laterobasal nucleus; SF – superficial section; GMD - gray matter density; CSS - cognitive sum score.

Legend to Figure 1

Illustration of VBM and neuropsychological findings in a cohort of chronic schizophrenic men treated over 12 weeks with weekly high-dose EPO (N=16) versus placebo (N=16). *Compare Table 2.*

Panel A: **Gray matter regions (1-6) with treatment effects:** Significant effects ($p<0.005$; uncorrected for multiple comparisons, minimum cluster size $100mm^3$, adjusted for non-isotropic smoothness) for the interaction TREATMENT*TIME (ANCOVA, brown), the voxel-wise linear discriminant analysis (vwLDA, blue) and the intersection of both maps (ANCOVA$\cap$vwLDA, yellow), overlaid to coronal sections of the mean T1-weighted MRI of the whole sample (N=32) are shown. As insets, respective transversal and sagittal sections are displayed. The crosshair highlights the cluster from which the data for panels B, C, and D were taken. L, left; R, right; A, anterior; P, posterior.

Panel B: **Box plots display the group data for the peak effect obtained in ANCOVA** within the corresponding cluster and results of post-hoc 2-sided t-tests (paired $T_{(15)}$ within group, 2 sample $T_{(30)}$ between groups). The horizontal lines of the boxes mark the lower quartile, median and upper quartile values. Whiskers extend from each end of the box to the values within 1.5 times the interquartile range from the ends of the box. Notches display the variability of the median between samples. The width of a notch is computed so that box plots whose notches do not overlap have different medians at the 5% significance level. In addition, single subject data are displayed as open squares (placebo group, gray)

or filled circles (EPO group, black). Data were adjusted for the group specific median of GMD in the first MRI.

Panel C: **Results for voxel-wise linear discriminant analysis (vwLDA)** are shown as 2-dimensional scatter plots for the GMD changes over the study period. The pre-treatment GMD at the mentioned stereotactic position serves as x- and the post-treatment GMD as y-coordinate. The dashed black line denotes the stable state. Each deviation of the displayed open squares (placebo group, gray) or filled circles (EPO group, black) from this line indicates GMD decrease or increase, respectively. The linear discrimination function, showing the maximum separation between data from the placebo and the EPO group is displayed as solid black line.

Panel D: **Results for region of interest based linear discriminant analysis (rbLDA)** shown as 2-dimensional scatter plots for the relation between z-scaled differences in GMD [z(ΔGMD)] and sum of z-scaled differences for selected RBANS subscales, i.e. cognitive sum score of figure recall, digit span and coding [Σz(ΔCSS)] over the entire study period. The Σz(ΔCSS) serves as x- and the z(ΔGMD) at the mentioned stereotactic position as y-coordinate. The linear discrimination function, showing the maximum separation between data from the placebo and the EPO group is displayed as solid black line.

Wüstenberg et al. Figure 1 - part 1

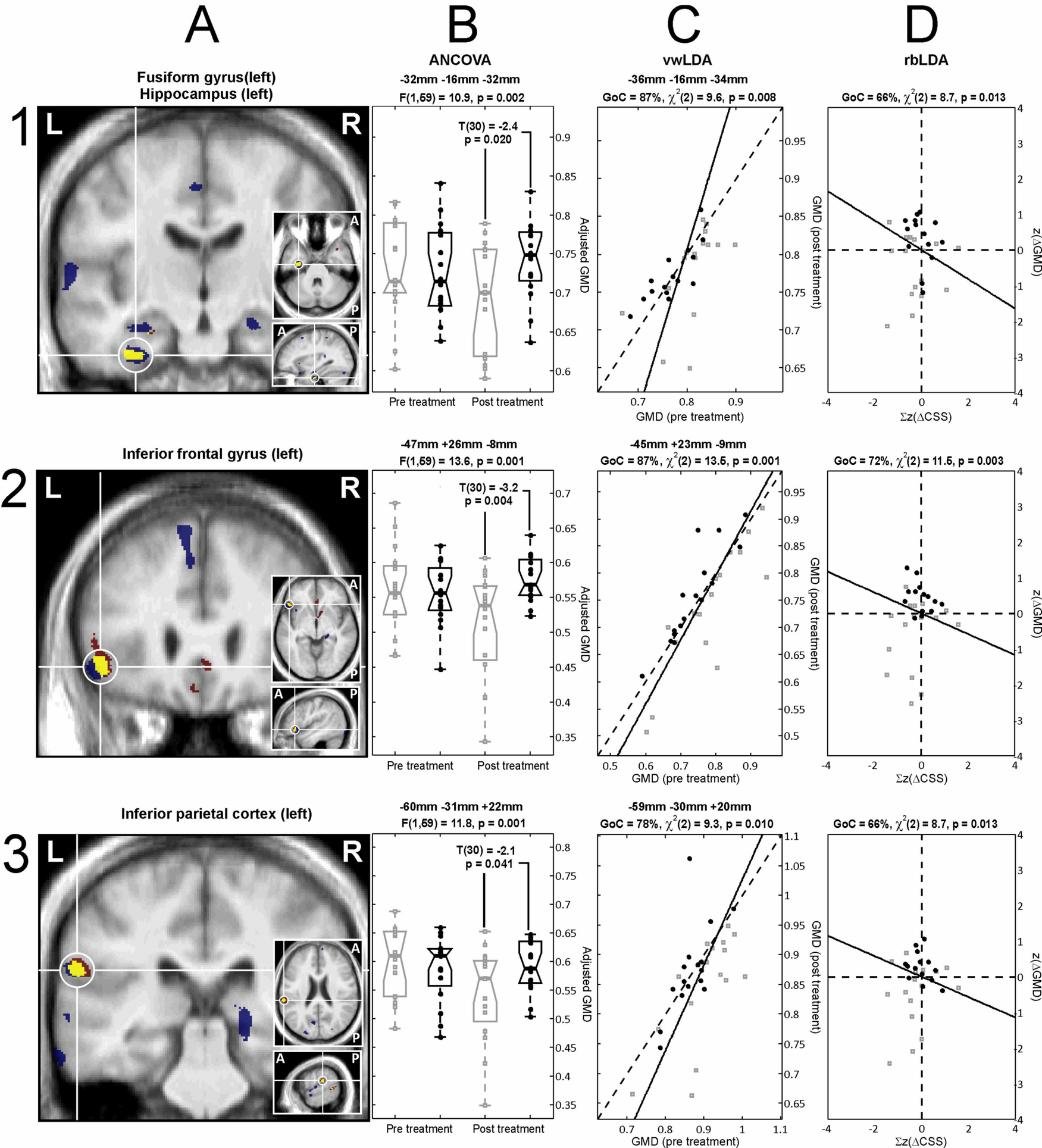
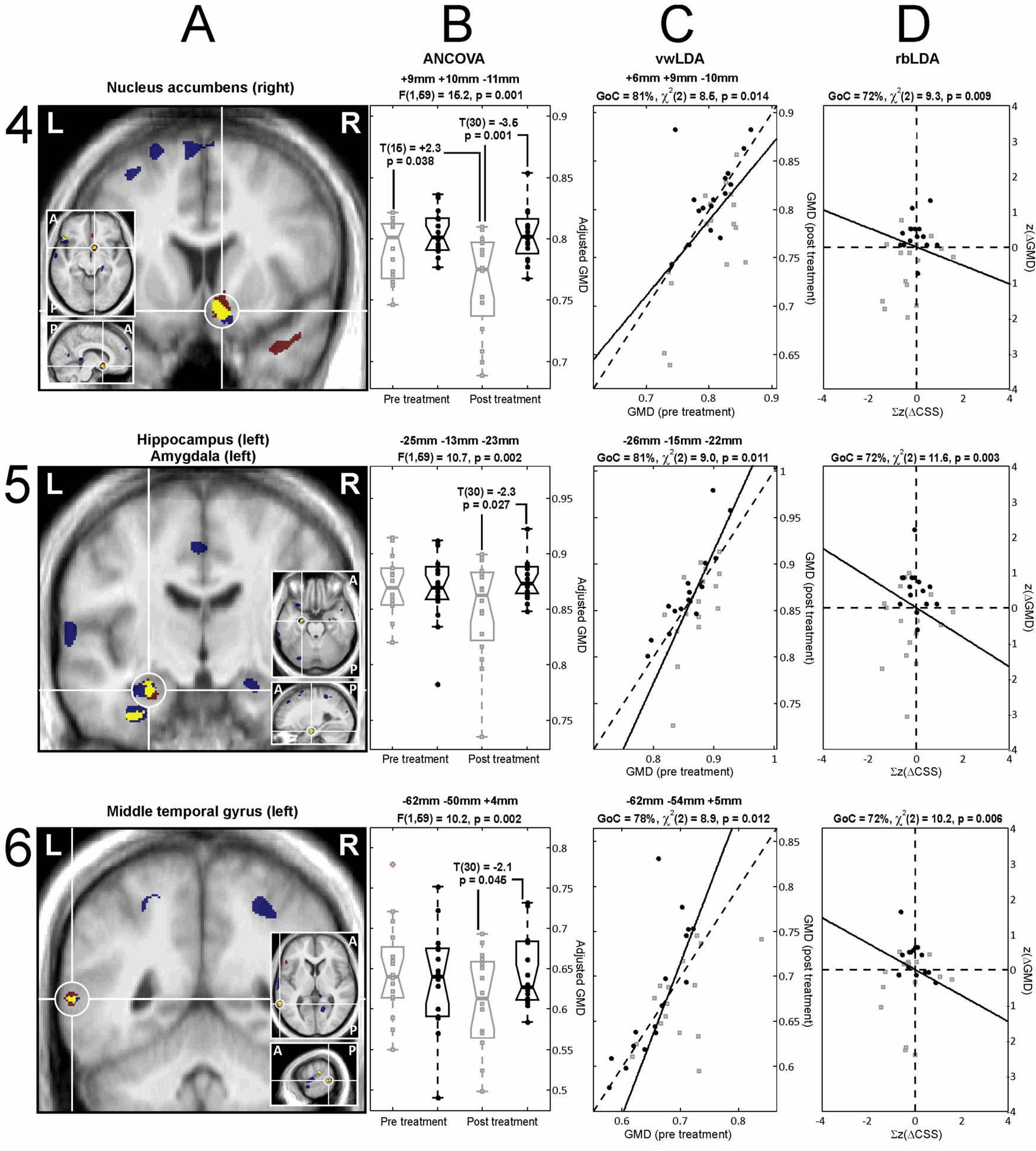
Wüstenberg et al. Figure 1 - part 2