



HAL
open science

Diagnosis and management of primary breast sarcoma

Sammy Al-Benna, Kerstin Poggemann, Hans-Ulrich Steinau, Lars
Steinstraesser

► **To cite this version:**

Sammy Al-Benna, Kerstin Poggemann, Hans-Ulrich Steinau, Lars Steinstraesser. Diagnosis and management of primary breast sarcoma. *Breast Cancer Research and Treatment*, 2010, 122 (3), pp.619-626. 10.1007/s10549-010-0915-y . hal-00537243

HAL Id: hal-00537243

<https://hal.science/hal-00537243>

Submitted on 18 Nov 2010

HAL is a multi-disciplinary open access archive for the deposit and dissemination of scientific research documents, whether they are published or not. The documents may come from teaching and research institutions in France or abroad, or from public or private research centers.

L'archive ouverte pluridisciplinaire **HAL**, est destinée au dépôt et à la diffusion de documents scientifiques de niveau recherche, publiés ou non, émanant des établissements d'enseignement et de recherche français ou étrangers, des laboratoires publics ou privés.

Diagnosis and management of primary breast sarcoma

Sammy Al-Benna · Kerstin Poggemann ·
Hans-Ulrich Steinau · Lars Steinstraesser

Received: 12 November 2009 / Accepted: 21 April 2010 / Published online: 18 May 2010
© Springer Science+Business Media, LLC. 2010

Abstract Primary sarcoma of the breast is an extremely rare and heterogeneous disease. The rarity of this tumour limits most studies to small retrospective case reviews and case reports and has made clinicopathological study difficult. This article reviews the current literature on the diagnosis and management of breast sarcoma. The optimal treatment of breast sarcoma involves a multidisciplinary team prior to the initiation of treatment. Patients with tumours less than 5 cm that are easily resectable should undergo complete resection to the extent required to provide negative surgical margins. Negative surgical margins are more important for local recurrence and overall survival than the extent of surgical resection. Thus, neoadjuvant chemotherapy should be considered in order to shrink the tumour and help obtain negative surgical margins. Whether chemotherapy is indicated is primarily determined by tumour size. There is evidence that tumours larger than 5 cm are associated with an elevated risk of systemic failure and a poor prognosis. After surgical resection, patients with chemosensitive tumours should undergo additional adjuvant chemotherapy to treat micrometastatic disease. Radiation therapy should be used to improve local control in cases in which the tumour is larger than 5 cm and in cases with positive surgical margins. We propose to treat the patients according to the clinical practice guidelines in use for soft tissue sarcomas and address them to a reference centre for sarcoma. The appropriate treatment of breast sarcoma

requires a multidisciplinary team approach necessitating experienced sarcoma surgeons, pathologists, radiotherapists and medical oncologists. Treating rare tumours in the same place should permit us to standardise pathological data and to include patients into multicentric radiotherapy or chemotherapy protocols to improve overall survival.

Keywords Breast sarcoma · Surgery · Radiotherapy · Chemotherapy · Prognosis

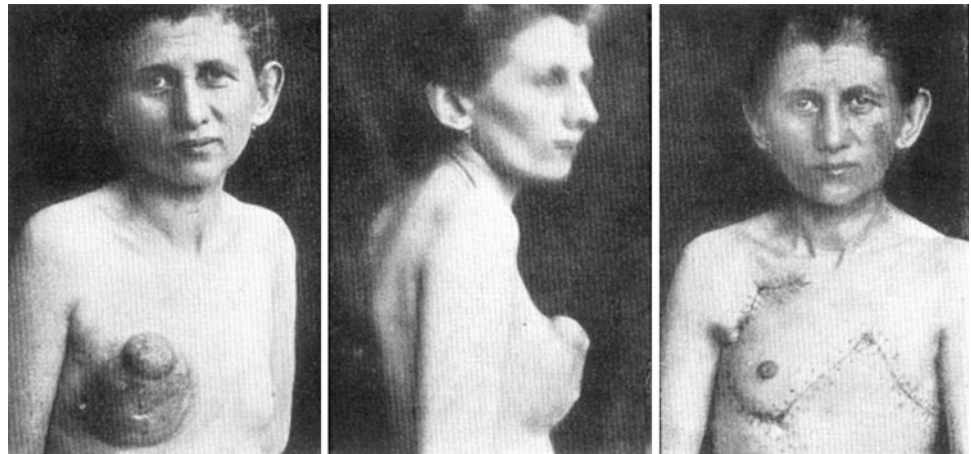
Introduction

The German ophthalmologist and surgeon Maximilian Josef von Chelius described a phylloides breast tumour in 1828 [1]. Johannes Peter Müller, an anatomist and the teacher of Rudolph Virchow, coined the term cystosarcoma phylloides in 1838 [2]. Müller chose the word ‘cystosarcoma’ because of the tumour’s cystic and gross fleshy appearance and added ‘phylloides’ as the Greek term for leaf to describe the lobulated and oval forms of the mass [2]. The first cases of metastatic phyllodes tumours were investigated in a series of 111 patients by Lee and Pack in 1931 [3]. In 1887, Schmidt mentioned 11 cases of angiosarcomas of the breast [4]. Most authors credit Schmidt with the first reported case of primary breast sarcoma. In 1912, Simon published photographs of a breast reconstruction with a local transposition flap after ablative treatment of a breast sarcoma [5] (Fig. 1).

Breast sarcoma is a rare type of cancer arising from the mesenchymal tissue of the breast. They represent <1% of all primary breast malignancies and <5% of all sarcomas [6–8]. The annual incidental rate is 44.8 new cases per ten million women [9]. There is still no consensus according to the exact definition of breast sarcoma. Some authors

S. Al-Benna (✉) · K. Poggemann · H.-U. Steinau ·
L. Steinstraesser
Operative Reference Centre for Soft Tissue Sarcoma,
BG University Hospital Bergmannsheil, Ruhr University
Bochum, Bürkle-de-la Camp-Platz 1, 44789 Bochum,
Nordrhein-Westfalen, Germany
e-mail: Sammy.Al-Benna@Ruhr-Uni-Bochum.de

Fig. 1 Simon's photographs of a breast reconstruction with a local transposition flap after ablative treatment of a breast sarcoma in 1912 [5]



excluded cystosarcoma phyllodes from their studies due to its epithelial components [6, 10–12] but others do not distinguish between other subtypes of breast sarcoma and cystosarcoma because of the similar survival and clinical course for these subtypes [7, 8, 13, 14]. Most published articles are limited to small retrospective case reviews and case reports, and this has made clinicopathological study difficult. A Medline search reveals that published clinical outcome series range from as few as 13 patients [10] to 103 patients [12], which may be too small to draw significant conclusions when compared to the many large breast carcinoma studies. Confavreux et al. proposed including all types of breast sarcoma to have a large number of cases and then compare the outcomes and results of three different groups: (1) phyllodes tumour (grade I and II), (2) primary breast sarcoma and malignant phyllodes tumour (grade III) and (3) angiosarcoma [15]. Their data revealed significant differences in the 3-year disease-free survival of, respectively, 57, 45 and 7%.

In contrast to breast carcinoma, which has risen in incidence over the last three decades in many old 'first' and 'second world countries', including a rise of over 50% in the United Kingdom [16], the annual rate of breast sarcoma has remained constant from 1973 to 1986 [9]. This may suggest that the aetiology of breast sarcoma does not depend on changes in population demographics and environmental factors or perhaps that there has simply been no great increase in diagnosis. The rarity of this pathology has led to a lack of consensus on the optimal treatment approach [17]. It has become more evident that a multi-disciplinary team approach that involves a spectrum of breast health care professionals is necessary to provide optimal care to patients [8]. This team should optimally include medical oncologists, breast radiologists, breast pathologists, surgical breast specialists, radiation oncologists, geneticists and primary care physicians. Treatment decisions have largely been empirical and based on information from retrospective reviews. There is no definitive

consensus regarding the treatment of breast sarcoma, and even if simple mastectomy without axillary dissection is still widely regarded as a gold standard, there are major variations in the extent of local therapy, ranging from wide local excision to radical mastectomy. However, the relatively poor prognosis associated with breast sarcoma has motivated many clinicians to treat patients aggressively.

The aim of this review is to provide an overview of the current literature on the diagnosis and management of breast sarcoma and include data from the last two decades on local and distant recurrence, and survival rates. A Medline and OvidSP literature search was conducted for the MESH terms 'breast' (MESH A01.236) and 'sarcoma' (MESH C04.557.450.795). All English language studies on soft tissue sarcoma of the breast were included.

Aetiology

The risks of developing breast sarcoma are largely unknown. Some authors showed a significant correlation between external beam radiation of the breast or chest wall and sarcoma [18–20]. Blanchard et al. demonstrated a larger percentage of angiosarcomas as a histopathological subtype post-irradiation therapy sarcoma when compared with other subtypes of sarcoma. The latent time interval between radiotherapy and breast sarcoma was 12 years and 8 months. For breast angiosarcoma this period of time was even shorter with only 8 years and 8 months [21]. Other studies had comparable results [22, 23]. Another proposed risk factor, especially for angiosarcomas, is a chronic lymphoedema of the breast or the arm [24]. In the future, the number of sarcomas may grow because of the increasing numbers of patients undergoing radiotherapy. The aetiology of cystosarcoma phyllodes is largely unknown, either. McDivitt et al. proposed that phyllodes tumours arise from pre-existing fibroadenomata [25]. People with hereditary diseases like Neurofibromatosis or

Li-Fraumeni-syndrome have also an increased risk of developing soft tissue sarcoma [26]. A work-related angiosarcoma can be developed after many years of contact with the carcinogenic agent vinyl chloride [27].

Clinical presentation

Breast sarcoma is mostly diagnosed in patients who are in their fifth or sixth decade of life, and our study of patients in major breast sarcomas series in the English literature gave a weighted mean of 50.0 years (Table 1) [6–8, 10–12, 14, 15, 21, 28–35]. Our study of patients in major breast sarcomas series in the English literature found that 98.5% occurred in women and 1.5% in men (Table 1) [6–8, 10–12, 14, 15, 21, 28–35]. It has been postulated that the menopausal status influences breast sarcoma development, but there is little evidence to support this [8, 12]. The typical patient with a breast sarcoma has a unilateral, well-defined, mobile and painless breast lump which often grows more rapidly than epithelial breast carcinoma [7, 36]. The mean tumour size diameter was between 4.8 and 5.6 cm (range: 0.8–40 cm) in most studies [8, 10, 12, 15]. McGregor et al. reported median tumour size of 3 cm [14], and Adem et al. had a mean tumour size of 10 cm for angiosarcomas [11]. Metastases from breast sarcoma commonly spread haematogenously, and typically to the

lungs, bones and liver [6–8, 14]. Lymph node metastases are rare [8, 15]. In most cases of lymph node metastasis, the histopathologic subtype is carcinosarcoma [8, 14]. Breast skin and the nipple areola complex are rarely involved by breast sarcomas, but angiosarcomas may be associated with a bluish discoloration of the skin overlying the lesion [6, 33, 37] (Fig. 2).

Diagnosis

Histological diagnosis

As mentioned previously, there is still no consensus as to the exact definition of breast sarcoma. Some authors excluded cystosarcoma phyllodes from their studies because of its epithelial components [6, 10–12]. Yet, there are those who did not distinguish between subtypes of breast sarcoma and cystosarcoma because of their similar survival and clinical course [7, 8, 13, 14]. Malignant phyllodes tumours consist of malignant mesenchymal cells and a benign epithelial component [38]. These lesions microscopically appear as epithelial lined cysts with a hypercellular stroma [39]. Basing a diagnosis on fine needle aspiration (FNA), therefore, is difficult and a diagnostic rate of 23% underscores the limited accuracy of this diagnostic method [37, 40]. As for soft tissue sarcomas in

Table 1 Age and sex of patients in major breast sarcomas series in the English literature

Study	Patients (n)	Age (years)	Age range (years)	Female (%)	Male (%)
Adem 2004 [11]	25	45 (mean)	24–81	100	0
Barrow 1999 [28]	59	45 (median)	16–78	100	0
Berg 1961 [29]	25	48 (average)	25–64	96	4
Blanchard 2003 [21]	55	52 (mean)	22–82	100	0
Bousquet 2007 [12]	103	55 (median)	13–86	100	0
Callery 1985 [30]	32	54 (median)	22–77	97	3
Christensen 1988 [31]	68	52 (mean)	17–86	99	1
Ciatto 1992 [60]	70	N/A	N/A	100	0
Confavreux 2006 [15]	70	50 (mean)	13–84	100	0
Fields 2008 [10]	13	50 (average)	32–72	100	0
Gutman 1994 [32]	60	48 (mean)	16–78	100	0
McGowan 2000 [8]	78	51 (median)	13–82	93	7
McGregor 1994 [14]	58	51 (median)	14–86	97	3
North 1998 [33]	25	55 (median)	N/A	100	0
Pandey 2004 [34]	19	39 (mean)	12–70	96	4
Pollard 1990 [6]	25	55 (average)	24–79	100	0
Smola 1993 [50]	8	N/A	N/A	88	12
Terrier 1989 [7]	33	44 (mean)	17–87	96	4
Zepek 2003 [35]	83	47 (median)	17–89	88	12
Weighted mean age		50.0 years	Total sex incidence rate	♀ 98.5%	♂ 1.5%

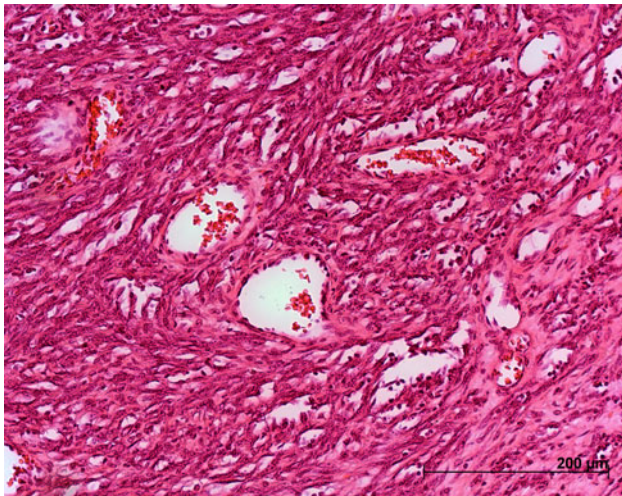


Fig. 2 Infiltrative growth of a breast angiosarcoma with spindle cells. Rudimentary lumen formations are seen (H&E stain)

other parts of the body, breast sarcomas consist of a heterogeneous group of several subtypes: angiosarcoma, malignant fibrous histiocytoma, stromal sarcoma, fibrosarcoma, liposarcoma, leiomyosarcoma, spindle-cell sarcoma and rhabdomyosarcoma. Angiosarcoma, malignant fibrous histiocytoma and stromal sarcoma subtypes tend to be the most common subtypes. McGowan et al. and McGregor et al. also included carcinosarcoma to their studies [8, 14]. Similar to phyllodes tumours, FNA for breast sarcoma provides poor diagnostic rates, and therefore, many authors consider that core biopsy, with its significant improvement of diagnosis rates, is the investigation of choice [17, 37, 39]. In many studies, tumour size [6, 10, 11, 28, 32, 35] and tumour grade [8, 12, 32, 35] are the main pathological prognostic factors, although these results are not universally repeated. This may be due to the small number of cases in many series. Cellular pleomorphism, mitotic numbers, stromal atypia and infiltrating borders have also been found to be prognostic factors [11, 12, 32].

Diagnostic imaging

Mammography in breast sarcoma is non-specific. It will usually demonstrate a nonspiculated dense mass [37, 41], in most cases without micro calcifications [41]. Therefore, the advantage of mammography to show micro calcifications is often not present. Ultrasound has been proposed to be better than mammography in diagnosis of breast sarcoma [17, 39]. On sonography, the majority of breast sarcomas appear hyperechoic with no shadowing [17, 39]. The ultrasound appearance of cystosarcoma phyllodes are often as prolapsed cysts in a solid tumour [42]. MRI may be helpful in indicating malignancy in breast sarcoma, as malignant tumours display rapid enhancement with ‘washout’ characteristics and lobules [43] (Fig. 3).

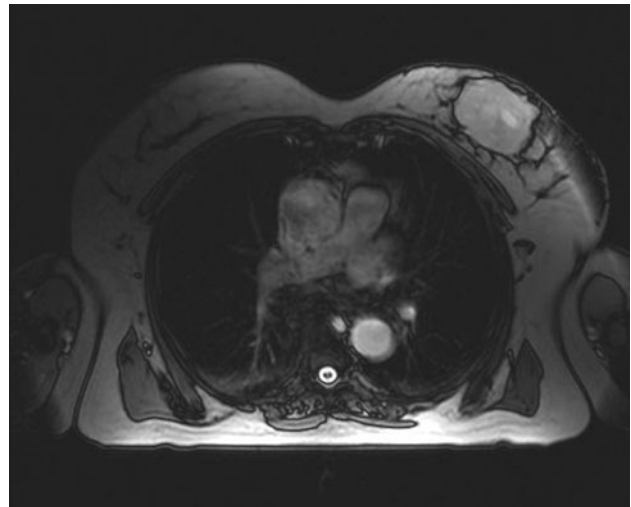


Fig. 3 Magnetic resonance imaging is highly sensitive in the detection of soft tissue sarcomas of the breast, although the specificity is somewhat lower. This breast angiosarcoma is very vascular and shows marked enhancement. Breast sarcoma has been described as having low signal intensity on T1-weighted images, and higher signal intensity on T2-weighted images. However, other have described higher signal intensity of T1-weighted images with relatively lower intensity in the central area of the tumour such as in this case

Immunohistochemistry

Progesterone and oestrogen receptor analysis of tumour tissue is performed for breast carcinoma. As phyllodes tumours have an epithelial component and their malignancy has been shown to depend on their stromal component, they were investigated similarly, but these hormone receptors were not been shown to be useful [44]. In 2005, Tan et al. investigated the role of the role of p53 and CD 117 in phyllodes tumours. p53 staining was used to underscore malignancy in these tumours and positive stromal immunoreactivity for CD 117 was correlated with tumour grade and recurrence [45]. Esposito et al. have also shown that the malignancy of phyllodes tumours correlate with CD 117 (also known as c-Kit positivity) [46].

Staging

The most commonly used staging system for breast sarcomas is the American Joint Committee on Cancer staging system for soft tissue sarcoma [47] (Table 2). Histological grade, tumour size, nodal involvement and distant metastasis contribute to this system. Breast carcinoma staging systems are not very useful for breast sarcoma as nodal metastasis is rare in soft tissue sarcomas [48]. Positron emission tomography scanning may be useful in staging, but its role has not yet been proven [49].

Table 2 Staging system for soft tissue sarcomas of the breast

Stage	Histological grade	Size	Location (relative to fascia)	Systemic/metastatic disease present
IA	Low	<5 cm	Superficial or deep	No
IB	Low	≥5 cm	Superficial	No
IIA	Low	≥5 cm	Deep	No
IIB	High	<5 cm	Superficial or deep	No
IIC	High	≥5 cm	Superficial	No
III	High	≥5 cm	Deep	No
IV	Any	Any	Any	Yes

Management

Surgery

There is general agreement that surgical ablation should always be the first modality of treatment for breast sarcoma. There has been much discussion over the years regarding the surgical treatment with the best outcome for the patients. The aim is excellent local control and for many years, mastectomy was regarded as gold standard. In contrast, recent studies have demonstrated no significant advantage to mastectomy in comparison to wide local excision [8, 10, 12, 14, 15]. For smaller localised breast sarcomas most authors recommend wide excision with a greater than 1 cm margin, and up to a 3 cm tumour-free cuff of normal tissue, as definitive primary therapy [39]. However, controversy exists whether wide local excision with negative margins is adequate or if adequate local control should be achieved by mastectomy. Older series suggest a higher rate of local recurrence with wide local excision compared to a simple mastectomy. Angiosarcomas have a high probability of local recurrence, as they have infiltrative cutaneous spiculae and for the mainstay of treatment both wide local excision with margins up to 3 cm or simple mastectomy have been proposed. However, the aesthetic outcome of large tumours is often worse with lumpectomy than with mastectomy and reconstruction [17]. In addition, a large tumour to breast size ratio may compromise sufficient excision margins [17]. Therefore, the surgical therapy of each patient should be individually tailored. The authors propose that in patients in whom adequate negative surgical margins can be achieved, that breast conserving surgery is indicated. Despite the aforementioned arguments for extent of surgery, the most important aim is to achieve complete surgical ablation as the margin of surgical resection has been found to have a prognostic importance [34]. Clear excision margin [8, 15, 22, 37, 50] and tumour size [10, 11, 32] are the two most important factors that determine mortality in patients with breast sarcoma who have had primary surgical ablation. A tumour size less than 5 cm is associated with a better overall survival [10, 32].

Lymph node metastasis in breast sarcoma is rare but when present, one should consider the diagnosis of a metaplastic carcinoma even in the presence of a pure spindle-cell neoplasm. Lymph node dissection should only be performed if the histological subtype is carcinosarcoma [8, 14]. Many authors exclude carcinosarcoma from their studies due to its resemblance to breast carcinoma [6, 7, 11, 22, 32, 50]. When lymph node involvement occurs in a patient with another subtype than carcinosarcoma, the patient commonly suffers from a disseminated, end-stage disease and treatment is palliative, so most investigators do not recommend lymph node dissection [17, 22, 39]. Elson et al. found out that up to 25% of the cases lymph nodes may be palpable, reflecting a reactive process [41]. Breast sarcomas, like other soft tissue sarcomas, commonly metastasize haematogenously. Sentinel lymph node biopsy for breast sarcoma has not yet been studied, but as nodal metastasis is rare and the most common route of metastasis is haematogenous, there may not be a potential benefit.

Radiotherapy

In contrast to surgical ablation, there is widespread disagreement for the benefits of radiotherapy. Whilst some authors [6, 12, 22, 33] did not find any benefit for adjuvant radiotherapy, McGowan et al. [8] and Johnstone et al. [51] demonstrated significant benefit for patients. In the McGowan et al. series, the cause-specific survival of the group, which received over 48 Gy radiation dose, was 91%, in comparison the group which received no or less than 48 Gy radiation dose had a cause-specific survival of only 50% [8]. Therefore, they recommended a post-operative irradiation of at least 60 Gy to the whole tumour bed [8]. Johnstone et al. showed that adjuvant irradiation of the breast improves the disease-free survival [51]. Certain studies saw a trend of benefit for irradiated patients and so recommended adjuvant radiotherapy for primary breast sarcomas, especially if the tumour is of larger size or high grade [28, 35, 52]. As angiosarcoma is a particularly aggressive form of breast sarcoma, Monroe et al.

recommend that angiosarcoma radiation portals should encompass a more generous margin than other sarcomas [53].

Chemotherapy

The role of chemotherapy for breast sarcoma remains unclear. Regrettably, many studies provide less than conclusive data. Gutman et al. showed evidence of increased disease-free survival and a trend in improved overall survival for patients who received adjuvant chemotherapy [32]. But in most studies the response rates of breast sarcoma to chemotherapy, especially neoadjuvant chemotherapy, were limited and the investigators hesitated to draw conclusions or mention recommendations [10, 12, 14, 15]. Only Zelek et al. advance the view that adjuvant chemotherapy should be provided for patients with high-grade tumours or with tumours measuring more than 5 cm [35]. With reference to soft tissue sarcomas studies, the most active chemotherapeutic agents are doxorubicin and ifosfamide [54, 55], which may be assumed for breast sarcoma as well. There is no evidence for neoadjuvant chemotherapy in the management of breast sarcoma. Soft tissue sarcomas are often minimally or not chemosensitive at all, with poor response rates ranging from 20 to 40% [56]. Local hyperthermia has been proposed as an effective option in the management of locally advanced, high risk and recurrent breast sarcoma [57, 58]. The evidence that this therapy proves effective is awaited but adding regional hyperthermia to chemotherapy has recently been demonstrated to be a new effective treatment strategy for patients with high-risk soft tissue sarcomas [59, 60].

Prognosis

The larger studies have demonstrated a 5-year disease-free survival ranging from 44 to 66% [7, 8, 11, 12, 14, 15, 35, 61] and a 5-year overall survival ranging from 49 to 67% [8, 10–12, 15, 35, 61]. This suggests that most patients, who are still alive after 5 years, are free of disease. On these lines, most detrimental events, such as local or distant recurrence and death, occur in the first few years after diagnosis [7, 8, 15]. The 10-year disease-free survival changes little compared to the 5-year disease-free survival and reveals that women who have been through 5 years without breast sarcoma recurrence tend to stay healthy [12, 35].

Discussion

The rarity of these breast sarcomas and their changing nomenclature have made them difficult to evaluate. There

appears to be no prognostic difference overall between cystosarcoma phyllodes and other breast sarcomas because of their similar survival and clinical course. As the outcome of these two groups is identical, they should be approached in similar manner. Similarly, it is doubtful whether the current fractionated nomenclature has any specific clinical value, whereas the histoprognostic grade should be taken into account for adjuvant therapy trials. They may present in a similar fashion to epithelial malignancy of the breast; yet, they are often refractory to diagnosis by conventional triple assessment.

Breast sarcomas are comparable to soft tissue sarcomas seen elsewhere. They present mainly as a lump and tumour size seems to be the most frequently reliable prognostic factor in many series, with 5 cm serving as a valuable cut point. Core biopsy produces a significant improvement in pre-operative diagnosis rates and is recommended in all patients in whom the possibility of breast sarcoma is considered. Excision biopsy should not be undertaken unless repeated attempts at pre-operative diagnosis are unsuccessful. In this, as in other respects, breast sarcoma is far more comparable to soft tissue sarcoma at other sites than to epithelial malignancy of the breast. The first-line treatment is surgical excision with adequate margins, with small survival advantages shown for post-operative radiotherapy. Local lymphatic spread is uncommon, and therefore, axillary node sampling or routine dissection cannot currently be recommended. Response rates to systemic therapies remain poor, reinforcing the need for accurate pre-operative diagnostic strategies and appropriate surgical management. Future directions are, therefore, likely to revolve around improving this area of patient care. Breast sarcomas are at high risk of recurrence and have poor prognosis.

In conclusion, the therapeutic management of breast sarcomas is a crucial problem because of their rarity and also of the specific treatment strategy that must be followed. The disease is usually diagnosed and initially treated by breast and gynaecological surgeons. However, breast sarcomas are totally different from epithelial breast cancers and require different management. They should be considered as sarcomas. We propose to treat the patients according to the clinical practice guidelines in use for soft tissue sarcomas and address them to a reference centre for sarcoma. The main direction is to address these patients to a sarcoma reference centre where a multidisciplinary team will coordinate local evaluation by MRI and distant evaluation by chest radiograph and chest tomodensitometry before proposing the best surgical strategy to achieve negative margins (R0). Furthermore, referring rare tumours to the same reference centres allows the standardisation of pathologic data and the inclusion of patients in multicentric protocols of radiotherapy or chemotherapy to improve overall survival.

References

1. Chelius M (1828) Teleangiectasie. *Heidelberger Klin Ann* 499:517
2. Müller J (1838) Über den feineren Bau und die Formen der krankhaften Geschwülste
3. Lee B, Pack G (1931) Giant intracanalicular myxoma: the so-called cystosarcoma phylloides mammae of Johannes Muller. *Am J Cancer* 93:250–268
4. Schmidt GB (1887) Ueber das angiosarkom der mamma. *Arch Klin Chir* 36:421–427
5. Simon W (1912) Myeloische Chloro-Leukämie (Chlorom) unter dem Bilde eines malignen Mammatumors. *Berl Klin Wochenschr* 49:893–897
6. Pollard MSG et al (1990) Breast sarcoma. A clinicopathologic review of 25 cases. *Cancer* 66(5):941–944
7. Terrier PH et al (1989) Primary breast sarcoma: a review of 33 cases with immunohistochemistry and prognostic factors. *Breast Cancer Res Treat* 13(1):39–48
8. McGowan TS et al (2000) An analysis of 78 breast sarcoma patients without distant metastases at presentation. *Int J Radiat Oncol Biol Phys* 46(2):383–390
9. May DS, Stroup NE (1991) The incidence of sarcomas of the breast among women in the United States, 1973–1986. *Plast Reconstr Surg* 87(1):193–194
10. Fields RC et al (2008) Treatment and outcomes of patients with primary breast sarcoma. *Am J Surg* 196(4):559–561
11. Adem C et al (2004) Primary breast sarcoma: clinicopathologic series from the Mayo Clinic and review of the literature. *Br J Cancer* 91(2):237–241
12. Bousquet G et al (2007) Outcome and prognostic factors in breast sarcoma: a multicenter study from the rare cancer network. *Radiother Oncol* 85:355–361
13. Lattes R (1978) Sarcomas of the breast. *Int J Radiat Oncol Biol Phys* 4(7–8):705–708
14. McGregor GI, Knowling MA, Este FA (1994) Sarcoma and cystosarcoma phylloides tumors of the breast: a retrospective review of 58 cases. *Am J Surg* 167(5):477–480
15. Confavreux C et al (2006) Sarcomas and malignant phylloides tumours of the breast—a retrospective study. *Eur J Cancer* 42(16):2715–2721
16. Turner NC, Jones AL (2008) Management of breast cancer—Part I. *BMJ* 337:107–110
17. Lum YW, Jacobs L (2008) Primary breast sarcoma. *Surg Clin N Am* 88:559–570
18. Karlsson P et al (1998) Soft tissue sarcoma after treatment for breast cancer—a Swedish population-based study. *Eur J Cancer* 34(13):2068–2075
19. Huang J, Mackillop WJ (2001) Increased risk of soft tissue sarcoma after radiotherapy in women with breast carcinoma. *Cancer* 92(1):172–180
20. Taghian A et al (1991) Long-term risk of sarcoma following radiation treatment for breast cancer. *Int J Radiat Oncol Biol Phys* 21(2):361–367
21. Blanchard DK et al (2002) Radiation-induced breast sarcoma. *Am J Surg* 184(4):356–358
22. Blanchard DK et al (2003) Primary nonphylloides breast sarcomas. *Am J Surg* 186(4):359–361
23. Brady MS et al (1994) Post-treatment sarcoma in breast cancer patients. *Ann Surg Oncol* 1(1):66–72
24. Stewart FW, Treves N (1948) Lymphangiosarcoma in postmastectomy lymphedema: report of six cases in elephantiasis chirurgica. *Cancer* 1:64–81
25. McDivitt RW, Urban JA, Farrow JH (1967) Cystosarcoma phylloides. *Johns Hopkins Med J* 120(1):33–45
26. Malkin D et al (1990) Germ line p53 mutations in a familial syndrome of breast cancer, sarcomas, and other neoplasms. *Science* 250(4985):1233–1238
27. Hollstein M et al (1994) p53 mutations at A:T base pairs in angiosarcomas of vinyl chloride-exposed factory workers. *Carcinogenesis* 15(1):1–3
28. Barrow BJ et al (1999) Role of radiotherapy in sarcoma of the breast—a retrospective review of the MD Anderson experience. *Radiother Oncol* 52(2):173–178
29. Berg JW (1961) Stromal sarcomas of the breast. A unified approach to connective tissue sarcomas other than cystosarcoma phylloides. *Cancer* 15(2):418–424
30. Callery CD, Rosen PP, Kinne DW (1985) Sarcoma of the breast. A study of 32 patients with reappraisal of classification and therapy. *Ann Surg* 201(4):527–532
31. Christensen L et al (1988) Sarcomas of the breast: a clinicopathological study of 67 patients with long term follow-up. *Eur J Surg Oncol* 14(3):241–247
32. Gutman H et al (1994) Sarcoma of the breast: implications for extent of therapy. The MD Anderson experience. *Surgery* 116(3):505–509
33. North JH et al (1998) Sarcoma of the breast: implications of the extent of local therapy. *Am Surg* 64(11):1059–1061
34. Pandey M et al (2004) Primary sarcoma of the breast. *J Surg Oncol* 87(3):121–125
35. Zelek L et al (2003) Prognostic factors in primary breast sarcomas: a series of patients with long-term follow-up. *J Clin Oncol* 21(13):2583–2588
36. McDivitt RW, Stewart FW, Berg JW (1968) Atlas of tumor pathology. Tumors of the breast. Armed Forces Institute of Pathology, Washington, DC
37. Shabahang M et al (2002) Surgical management of primary breast sarcoma. *Am Surg* 68(8):673–677
38. Ward RM, Evans HL (2006) Cystosarcoma phylloides. A clinicopathologic study of 26 cases. *Cancer* 58(10):2282–2289
39. Pencavel TD, Hayes A (2009) Breast sarcoma—a review of diagnosis and management. *Int J Surg* 7(1):20–23
40. Foxcroft LM, Evans EB, Porter AJ (2007) Difficulties in the preoperative diagnosis of phylloides tumours of the breast: a study of 84 cases. *Breast* 16(1):27–37
41. Elson BC et al (1992) Fibrosarcoma of the breast: mammographic findings in five cases. *Am J Roentgenol* 158(5):993–995
42. Liberman L et al (1996) Benign and malignant phylloides tumors: mammographic and sonographic findings. *Radiology* 198(1):121–124
43. Yang WT et al (2007) Mammary angiosarcomas: imaging findings in 24 patients. *Radiology* 242(3):725–734
44. Trent JC, Benjamin RS, Valero V (2001) Primary soft tissue sarcoma of the breast. *Curr Treat Options Oncol* 2(2):169–176
45. Tan PH (2005) Breast phylloides tumours—morphology and beyond. *Galloway Mem Lect* 34(11):671–677
46. Esposito NN et al (2006) Phylloides tumor: a clinicopathologic and immunohistochemical study of 30 cases. *Arch Pathol Lab Med* 130(10):1516–1520
47. Greene FL, Fritz AG, Balch CM (2002) AJCC cancer staging manual. Soft tissue sarcoma. Springer-Verlag, New York
48. Daigeler A et al (2009) Lymph node metastases in soft tissue sarcomas—a single center analysis of 1,597 patients. *Langenbecks Arch Surg* 394(2):321–329
49. Bakheet SM et al (1998) F-18 FDG whole-body positron emission tomography scan in primary breast sarcoma. *Clin Nucl Med* 23(9):604–608
50. Smola MG et al (1993) The impact of resection margins in the treatment of primary sarcomas of the breast. A clinicopathological

- study of 8 cases with review of literature. *Eur J Surg Oncol* 19(1):61–69
51. Johnstone PAS et al (1993) Primary soft tissue sarcomas of the breast: local-regional control with post-operative radiotherapy. *Int J Radiat Oncol Biol Phys* 27(3):671–675
 52. Moore MP, Kinne DW (1996) Breast sarcoma. *Surg Clin N Am* 76(2):383–392
 53. Monroe AT, Feigenberg SJ, Mendenhall NP (2003) Angiosarcoma after breast-conserving therapy. *Cancer* 97(8):1832–1840
 54. Patel SR et al (1998) Results of two consecutive trials of dose-intensified chemotherapy with doxorubicin and ifosfamide in patients with sarcomas. *Am J Clin Oncol* 21(3):317–321
 55. Patel SR et al (1997) High-dose ifosfamide in bone and soft tissue sarcomas: results of phase II and pilot studies—dose-response and schedule dependence. *J Clin Oncol* 15(6):2378–2384
 56. Brennan M, Casper E, Harrison L (2008) Soft tissue sarcoma. In: DeVita JV, Hellman S, Rosenberg S (eds) *Cancer: principles and practice of oncology*. Lippincott Williams and Wilkins, Philadelphia, pp 1731–1852
 57. Thalhammer M et al (2006) Hyperthermia as a therapeutic option in recurrent breast sarcoma. *Eur J Surg Oncol* 32(S1):64
 58. Issels RD et al (1990) Ifosfamide plus etoposide combined with regional hyperthermia in patients with locally advanced sarcomas: a phase II study. *J Clin Oncol* 8(11):1818–1829
 59. Issels RD (2008) Regional hyperthermia in high-risk soft tissue sarcomas. *Curr Opin Oncol* 20(4):438–443
 60. Issels RD et al (2010) Neo-adjuvant chemotherapy alone or with regional hyperthermia for localised high-risk soft-tissue sarcoma: a randomised phase 3 multicentre study. *Lancet Oncol*. doi: [10.1016/S1470-2045\(10\)70071-1](https://doi.org/10.1016/S1470-2045(10)70071-1)
 61. Ciatto S et al (1992) Sarcomas of the breast: a multicenter series of 70 cases. *Neoplasma* 39(6):375–379