



HAL
open science

Assessment of false-negative cases of breast MR imaging in women with a familial or genetic predisposition

Inge-Marie A. Obdeijn, Claudette E. Loo, Adriana J. Rijnsburger, Martin N.
J. M. Wasser, Elisabeth Bergers, Theo Kok, Jan G. M. Klijn, Carla Boetes

► **To cite this version:**

Inge-Marie A. Obdeijn, Claudette E. Loo, Adriana J. Rijnsburger, Martin N. J. M. Wasser, Elisabeth Bergers, et al.. Assessment of false-negative cases of breast MR imaging in women with a familial or genetic predisposition. *Breast Cancer Research and Treatment*, 2009, 119 (2), pp.399-407. 10.1007/s10549-009-0607-7 . hal-00535408

HAL Id: hal-00535408

<https://hal.science/hal-00535408>

Submitted on 11 Nov 2010

HAL is a multi-disciplinary open access archive for the deposit and dissemination of scientific research documents, whether they are published or not. The documents may come from teaching and research institutions in France or abroad, or from public or private research centers.

L'archive ouverte pluridisciplinaire **HAL**, est destinée au dépôt et à la diffusion de documents scientifiques de niveau recherche, publiés ou non, émanant des établissements d'enseignement et de recherche français ou étrangers, des laboratoires publics ou privés.

Assessment of false-negative cases of breast MR imaging in women with a familial or genetic predisposition

Inge-Marie A. Obdeijn · Claudette E. Loo · Adriana J. Rijnsburger ·
Martin N. J. M. Wasser · Elisabeth Bergers · Theo Kok ·
Jan G. M. Klijn · Carla Boetes

Received: 22 June 2009 / Accepted: 15 October 2009 / Published online: 30 October 2009
© Springer Science+Business Media, LLC. 2009

Abstract In order to assess the characteristics of malignant breast lesions those were not detected during screening by MR imaging. In the Dutch MRI screening study (MRISC), a non-randomized prospective multicenter study, women with high familial risk or a genetic predisposition for breast cancer were screened once a year by mammography and MRI and every 6 months with a clinical breast examination (CBE). The false-negative MR examinations were subject of this study and were retrospectively reviewed by two experienced radiologists. From November 1999 until March 2006, 2,157 women were eligible for study analyses. Ninety-seven malignant breast tumors were detected, including 19 DCIS (20%). In 22 patients with a malignant lesion, the MRI was assessed as BI-RADS 1 or 2. One patient was excluded because the examinations were not available for review. Forty-three percent (9/21) of the false-negative MR cases concerned pure ductal carcinoma in situ (DCIS) or DCIS with invasive foci, in eight of them no enhancement was seen at the review. In six

patients the features of malignancy were missed or misinterpreted. Small lesion size ($n = 3$), extensive diffuse contrast enhancement of the breast parenchyma ($n = 2$), and a technically inadequate examination ($n = 1$) were other causes of the missed diagnosis. A major part of the false-negative MR diagnoses concerned non-enhancing DCIS, underlining the necessity of screening not only with MRI but also with mammography. Improvement of MRI scanning protocols may increase the detection rate of DCIS. The missed and misinterpreted cases are reflecting the learning curve of a multicenter study.

Keywords Breast cancer · MRI · Screening · Hereditary

Introduction

Breast cancer is by far the most prevalent malignancy in women, with a high incidence especially in Europe and

I.-M. A. Obdeijn (✉)
Department of Radiology, Erasmus MC-Daniel den
Hoed Cancer Center, Rotterdam, The Netherlands
e-mail: a.obdeijn@erasmusmc.nl

C. E. Loo
Department of Radiology, Netherlands Cancer Institute,
Antoni van Leeuwenhoek Hospital, Amsterdam, The Netherlands

A. J. Rijnsburger · J. G. M. Klijn
Department of Medical Oncology, Family Cancer Clinic,
Erasmus MC-Daniel den Hoed Cancer Center, Rotterdam,
The Netherlands

M. N. J. M. Wasser
Department of Radiology, Leiden University Medical Center,
Leiden, The Netherlands

E. Bergers
Department of Radiology, VU University Medical Center,
Amsterdam, The Netherlands

T. Kok
Department of Radiology, Groningen University Medical
Center, Groningen, The Netherlands

C. Boetes
Department of Radiology, Radboud University Medical Center,
Nijmegen, The Netherlands

Present Address:

C. Boetes
Department of Radiology, Maastricht University Medical
Center, Maastricht, The Netherlands

North America. The cumulative lifetime risk of breast cancer for Dutch women is approximately 13% [1]. A positive family history for breast cancer or a germ line BRCA1 or BRCA2 mutation increases the risk of developing breast cancer considerably. The estimated life time risk for BRCA1/2 mutation carriers is 50–85% [2]. Options to reduce the risk of breast cancer related death are prophylactic surgery (including prophylactic mastectomy and/or bilateral salpingo-oophorectomy (PBSO)), chemoprevention, or intensive surveillance.

Women with a strong family history are more likely to develop breast cancer at young age. Because of higher breast density at younger ages, screening with mammography will be less effective. Mammographic sensitivity for breast cancer declines significantly with increasing breast density (in the large study of Kolb et al. [3] from 98 to 48% for the densest breasts). Apart from a higher breast density it appeared that, especially in BRCA1/2 mutation carriers, also a higher growth rate and aspecific mammographic characteristics of the tumors contribute to a lower sensitivity [4–7]. Because of the consistently high sensitivity of MRI of the breast in diagnostic settings, with values between 90 and 100% [8–10], the role of contrast-enhanced MRI of the breast in screening of high-risk women was investigated. The first results of screening high-risk women with MRI were promising: MRI detected cancers still occult at mammography and not yet clinical manifest [11–14].

The published results of multiple studies confirm the effectiveness of MRI in screening of women at high familial risk. In five prospective studies [15–19], 3,571 women were screened with contrast-enhanced MR imaging and mammography, and with ultrasound in three of five studies. The pooled sensitivity for mammography was 40%, in comparison to 81% for MRI [20]. The detected cancers in 168 patients were small: 49% \leq 10 mm diameter, and only 19% of invasive cancers were associated with lymph node involvement [20]. Similar figures were found in the review of Warner et al. [21] who evaluated 11 prospective non-randomized studies in which MRI and mammography were used to screen women at very high risk for breast cancer (not only women with high familial risk). In their meta-analysis, the sensitivity of mammography and MRI was 39 and 77%, respectively (at a cut-off value of BI-RADS \geq 3).

Despite the excellent contribution of contrast-enhanced MRI in screening of women at high familial risk, MRI depicts not all cancers. In the present study, we assess the characteristics of malignancies not detected by MR imaging in the Dutch MRI screening study (MRISC study) and try to identify possible sources of error.

Methods

In the Dutch MRISC study, a non-randomized prospective multicenter study, women with high familial risk or a genetic predisposition for breast cancer were screened once a year by mammography and MRI and every 6 months with a clinical breast examination [15].

The women were recruited from six centers with familial breast cancer clinics. At the start of the MRISC study in 1999, in five of the six centers there was experience with breast MR imaging in a diagnostic population and variable experience in a screening setting. In one center breast MR imaging started short time before beginning of the study. This center was coached intensively.

In all six centers dynamic contrast-enhanced MRI was performed on a 1.5 Tesla system. The MR units were, in five of the six centers, purchased from Siemens Medical Solutions (Erlangen, Germany) and in one center from Philips Medical Systems (Best, The Netherlands). All patients were investigated in prone position with the breasts pending in a dedicated double breast surface coil. Premenopausal women were scanned on the day 5–15 of the menstrual cycle. Before scanning venous access was established in a cubital vein through which a bolus of contrast material (0.1 mmol per kg bodyweight or 15 ml gadolinium chelate) was administered using an automated injector at 2 ml/s followed by 20 ml saline flush at the same injection rate. Gradient echo T1-weighted series were made before and five times after contrast administration. Subtraction images were obtained with the use of a software subtraction function. All MRI examinations were evaluated on a dedicated breast MRI workstation.

At the start of the study in 1999, a three dimensional fast low-angle shot (FLASH 3D) was used before and five times after contrast administration. The parameters of the dynamic series were: FOV 320 mm, transversal slices of 1.5 mm thickness, pixel size 1.67 mm \times 1.25 mm, scan time 90 s, 1 acquisition, TR = 8.1 ms, TE = 4.0 ms, flip angle 20°. During the study, the MR units were upgraded and scanning protocols improved. Mainly spatial resolution was improved while maintaining the dynamic series at time intervals of 90 s. At the beginning of the study all centers, except one, performed mammography on conventional units. Through the years the other five centers also proceeded to digital mammography. Standard oblique and craniocaudal projections were obtained with additional views if necessary.

Mammography and MR examination were scored according to the Breast Imaging Reporting and Data System (BI-RADS) [22] with independent readings. An imaging test with BI-RADS score 3 (“probably benign finding”), O (“need additional imaging evaluation”), 4

(“suspicious abnormality”), and 5 (“highly suggestive of malignancy”) was defined as positive, because in these cases additional examination was indicated. A BI-RADS score of 1 (“negative”) and 2 (“benign finding”) were defined as negative.

Participants were divided into three subgroups according to their estimated cumulative lifetime risk (CLTR) of developing breast cancer: carriers of the BRCA1 or BRCA2 or other mutations (50–85% CLTR), a high-risk group (30–50% CLTR) and a moderate-risk group (15–30% CLTR).

A screen-detected malignancy was found during a screening round by MR imaging, mammography, or CBE or any combination of these methods. For mammography and MRI, we calculated the sensitivity defined as the percentage of malignancies with a positive test result. The overall results of the main analysis of the MRSIC study (to be published separately) may show slightly different numbers due to minor differences in patient groups. Cancers detected in specimens from prophylactic mastectomy were excluded from analysis. An interval carcinoma was defined as a malignancy detected between two screening rounds. A false-negative MRI case was defined as a biopsy proven malignancy while the MRI examination, performed within 1 year prior to detection, was evaluated as negative (BI-RADS 1 or 2). The false-negative MR cases were subject of this study and were retrospectively evaluated. Review of the false-negative MRI examinations was done by two experienced radiologists reaching consensus. In the MRISC study, the MR examinations were evaluated blinded to the information of mammography. This review was done with all clinical and diagnostic information about location, size, and histology of the malignancy available to the two radiologists (IMO and CB or CL).

In case there was no lesion or suspicious enhancement visible in retrospect, the diagnostic quality of the MR examination was assessed as possible cause of a false-negative diagnosis. The radiologists assessed the diagnostic quality of the MRI by evaluating motion artefacts, inadequate infusion and timing of contrast material, and the degree of background enhancement.

In case malignancy could be identified in retrospect, it was scored as missed or misinterpreted. The lesion (an enhancing mass or non-mass like enhancement) at the MRI was evaluated on a dedicated MRI workstation. The reviewing radiologists performed assessment of lesion size, morphology, and enhancement kinetics.

Results

From November 1999 to March 2006, 2,157 women were eligible for study analyses, including 599 proven carriers of

a BRCA1 ($n = 422$) or BRCA2 ($n = 172$) mutation or PTEN/TP53 ($n = 5$), 1,069 women in the high-risk group and 489 in the moderate-risk group.

Ninety-seven malignant breast tumors were detected in 93 patients, including 19 DCIS (20%). Seventy-eight cancers were screen detected, 13 were interval cancers and six malignancies were found at prophylactic mastectomy. The latter six malignancies are excluded for analysis of sensitivity. The 93 patients however, did not all have a complete screening round previous to the detection of the malignancy. Clinical examination, MRI and/or mammography were not always all performed. Eighty-one of the 93 patients underwent mammography before the detection of breast cancer. In 36 cases, mammography demonstrated the malignancy: sensitivity 44% (36/81).

Seventy-six patients underwent a screening round with MRI examination before the detection of a malignancy. In 22 of the 76 patients, the MRI was assessed as BI-RADS 1 or 2. The overall sensitivity of MRI was 71% (54/76). The sensitivity for invasive carcinoma was 78% (49/63), for pure DCIS 39% (5/13). One patient was excluded from the review because the MR examinations were not available anymore. This concerned a small invasive focus with DCIS. Therefore, 21 patients from the MRISC study with a biopsy proven malignancy and a MR examination scored as BI-RADS 1 or 2, were included in this study.

Clinical and radiological data of malignancies occult on MRI, also at the review

Also in retrospect, no enhancing mass or non-mass like enhancement could be identified in 12 of the 21 MRI examinations (Table 1). Except for one inadequate examination (Table 1, case 12), the BI-RADS classification remained 1, also at the review. Eight of these cases, in which no explanation for the false-negative diagnosis was found, were non-palpable mammographically detected DCIS. Seven of them were pure DCIS, and one concerned DCIS with an invasive focus of 4 mm. Mean tumor size was 20 mm (range 7–50 mm) (Table 1, case 1–8).

The ninth case (Table 1, case 9) in which no explanation was found for not showing the lesion at the screening, concerned an interval carcinoma in a BRCA1 carrier, which became evident 10 months after imaging. It was a 12-mm invasive ductal adenocarcinoma, grade 3, probably with a high growth rate.

In one patient (Table 1, case 10) small size and extensive diffuse contrast enhancement of the breast parenchyma were probably reasons for false negativity. This woman underwent lumpectomy because of mastopathic complaints. In the lumpectomy specimen, accidentally a 5-mm grade 1 invasive ductal carcinoma was discovered at histological examination.

Table 1 Clinical and radiological data of 12 malignancies occult on MRI, also at the review

Risk category	Age at diagnosis	Histology	Tumor size PA	Palpable	XM review BIRADS	MR review: reason of FN diagnosis
1 CLTR 30–50%	45	DCIS grade 1	18 mm	No	0 → 4	None
2 CLTR 15–30%	48	DCIS grade 2	10 mm	No	0 → 4	None
3 CLTR 15–30%	60	DCIS grade 3	8 mm	No	4 → 4	None
4 CLTR 15–30%	31	DCIS grade 2	17 mm	No	4 → 4	None
5 BRCA1	42	DCIS grade 1	50 mm	No	4 → 4	None
6 BRCA2	36	DCIS grade 3	7 mm	No	4 → 4	None
7 BRCA1	32	DCIS grade 3	20 mm	No	4 → 4	None
8 BRCA2	35	Foci of IDC and DCIS grade 3	4 mm, and 28 mm	No	4 → 4	None
9 BRCA1	53	IDC, grade 3	12 mm	Yes, interval 10 months after screening	1 → 1	None
10 CLTR 30–50%	49	IDC, grade 1	5 mm	No, found with lumpectomy performed for mastopathy	2 → 2	Small size, intensive enhancement
11 CLTR 30–50%	36	IDC, grade 2	15 mm	Yes, interval 10 months after screening	na	Intensive enhancement
12 BRCA2	36	Two lesions IDC and DCIS grade 3	20 mm and 10 mm, size DCIS na	No	4 → 4	Inadequate examination BI-RADS 1 → 0

FN false negative, XM mammography, PA pathology, DCIS ductal carcinoma in situ, IDC invasive ductal adenocarcinoma, na not available, CLTR cumulative life time risk, → change of BI-RADS category from study to review

In a 36-year-old women with a CLTR of 30–50%, who presented with a palpable mass 10 months after screening, intensive diffuse enhancement of the breast parenchyma prevented the detection of the malignancy (Table 1, case 11). At the review no mass or suspicious contrast enhancing areas could be distinguished. Also, the mammography was re-evaluated as normal. A 15-mm invasive ductal carcinoma grade 2 was found.

In case 12 (Table 1), a multifocal invasive carcinoma with surrounding DCIS was not detected on the MR examination with serious motion artefacts. This inadequate MR examination should have been repeated. Mammography and ultrasound only revealed the largest invasive lesion. The additional surrounding DCIS was not visible on the mammogram.

Clinical and radiological data of malignancies visible at the review

In 9 of the 21 reviewed cases an abnormality was observed in retrospect, which changed the BI-RADS classification of the MRI (Table 2). Four times it was changed to BIRADS 3, once to BIRADS 4 and also four times into BI-RADS 5. Retrospectively in 8 cases, a mass was seen and in one case a non mass-like segmental enhancement.

– In three of these nine cases (Table 2, case 1–3) small round lesions, 4 or 5 mm diameter, with type 2 or 3 time–intensity curves could be distinguished. At the

review, the BI-RADS classification changed from 1 to 3. In these three patients the lesions became clinically evident as interval carcinoma. Two of the three patients were BRCA1 mutation carriers.

- In three patients (Table 2, case 4–6) an enhancing mass or area was described but incorrectly interpreted as benign lesions or benign enhancing breast tissue. At the review, the BI-RADS classification became 3, 4, and 5, respectively.
- In three other patients, a suspicious abnormality was missed (Table 2, case 7–9). The MR examination of one of them, a BRCA1 mutation carrier, showed a 9-mm round, well defined lesion however with rim enhancement and wash-out on the time–intensity curves. This lesion was classified as BI-RADS 5 at the review and became palpable during pregnancy as a 45-mm invasive ductal carcinoma, grade 3. The screening mammogram was again evaluated as normal (Table 2, case 7). Another BRCA1 mutation carrier presented 7 months after screening with an interval carcinoma. On her MR examination, a 15-mm BI-RADS 5 lesion was missed. The screening mammogram was not available for review (Table 2, case 8). The third missed lesion (Table 2, case 9) was a 10-mm lobulated mass with rim enhancement. Time–intensity curves showed a type 3 curve. The mass was evaluated as BI-RADS 5. It proved to be a 12-mm invasive ductal adenocarcinoma grade 2 with extensive DCIS, grade 2. The DCIS was occult on MR but visible on mammography.

Table 2 Clinical and radiological data of 9 malignancies, evaluated on MRI as normal in the study, but visible at the review

Risk Category	Age at diagnosis	Histology	Tumor size PA (mm)	Palpable	XM review BIRADS	MR review Morphology	Enhancement	MR review BIRADS	Reason FN MR diagnosis
1 BRCA1	40	IDC, grade 3	15	Yes interval 4 months after screening.	1 → 3	Lesion: mass margin: smooth shape: round size: 4 mm	Homogeneous curve: type 3	1 → 3	Small size
2 BRCA1	44	IDC, grade 3	12	Yes interval 8 months after screening	1 → 1	Lesion: mass margin: smooth shape: round size: 4 mm	Homogeneous curve: type 2	1 → 3	Small size
3 CLTR 30–50%	37	Two lesions IDC, grade 3 DCIS grade 3	13 and 7, na	Yes interval 3 months after screening	2 → 3	Lesion: mass margin: smooth shape: round size: 5 mm	Homogeneous curve: type 3	1 → 3	Small size
4 CLTR 15–30%	39	DCIS grade 2 and 3	50	No	3 → 3	Lesion: non mass-like, segmental size: 50 mm	Heterogeneous curve: type 1	2 → 4	Misinterpreted as benign enhancement
5 CLTR 30–50%	45	IDC, grade 1	8	No	3 → 3	Lesion: mass margin: irregular shape: lobulated size 11 mm	Rim Curve: type 3	2 → 5	Misinterpreted as lymph node
6 CLTR 30–50%	53	IDC, grade 1	15	No	4 → 4	Lesion: mass margin: smooth shape: round size: 15 mm	Heterogeneous curve: type 2	1 → 3	Misinterpreted as normal tissue
7 BRCA1	27	IDC grade 3	45	Yes, interval pregnancy 5 months after screening	1 → 1	Lesion: mass margin: smooth shape: round size: 9 mm	Rim Curve: type 3	1 → 5	Missed
8 BRCA1	31	IDC, grade na	30	Yes interval 7 months after screening	na	Lesion: mass margin: irregular shape: irregular size: 15 mm	Heterogeneous curve: type 3	1 → 5	Missed
9 CLTR 15–30%	45	IDC, grade 2, extensive DCIS grade 2	12	No	3 → 4	Lesion: mass margin: smooth shape: lobulated size: 10 mm	Rim Curve: type 3	1 → 5	Mass missed; DCIS occult on MR

FN false negative, XM mammography, IDC invasive ductal carcinoma, DCIS ductal carcinoma in situ, na not available, CLTR cumulative life time risk, PA pathology → change of BIRADS category from study to review, Curve 1 cumulative enhancement, Type 2 = plateau, Type 3 = washout

Discussion

Conform to our previous results and the results from other prospective studies [15–19], the sensitivity of contrast-enhanced MR imaging for breast cancer screening in women with a familial or genetic predisposition is significantly higher compared to the sensitivity of mammography. However, MRI demonstrated not all malignancies.

We reviewed the examinations of 21 of the 97 cancers in the MRISC study who were not detected with MRI. Eight of these 21 undetected cancers were pure DCIS. All but one were also at the review classified as BI-RADS 1 while no enhancing masses or foci or non mass-like enhancement could be discriminated on the MR examination. Also, one case of DCIS with an invasive focus was occult on MRI, in the study as well at the review. In the mid-term analysis of the MRISC study, the sensitivity for the detection of pure DCIS is 39% (5/13) for MR imaging and 73% (11/15) for mammography. Four of the five intraductal cases visualized by MR were mammographically occult. In our study, mammography and MRI were complimentary for the detection of DCIS, with a higher sensitivity for mammography. Pooling together the 40 cases of DCIS detected in the mid-term analysis of the MRISC study and of the Canadian, English, German, and Italian screening studies [16–19], MRI has a sensitivity of 60% (23/38) (two patients with DCIS did not undergo MR). The sensitivity of mammography for DCIS is 60% (24/40) while 10 of the 40 (25%) cases were detected only by mammography. In our opinion, therefore, it is too early to leave out mammography from ongoing screening programs and current guidelines for women at increased familial breast cancer risk. The MRI sensitivity for DCIS in the present study is conform to the MARIBS study [17], where two of the six DCIS were diagnosed with MR (sensitivity 33%), but lower than reported in the other screening studies. Warner et al. [16] detected four out of six DCIS with MRI (sensitivity 67%), while Kuhl et al. [18] diagnosed eight out of nine intraductal cancers with MRI (sensitivity 89%). In the study of Sardanelli et al. [19] all four cases of DCIS were diagnosed with MRI (sensitivity 100%). Remarkable results are obtained in a prospective observational study of Kuhl et al. [23] in which 92% of DCIS cases were diagnosed by MRI, and only 56% by mammography. The above mentioned study of Kuhl et al. has, however, a totally different study population: in the Dutch MRISC study only asymptomatic women with a familial risk of breast cancer (with 28% BRCA1/2 mutation carriers) were included while in the study of Kuhl et al. only eight (5%) women underwent MR as a screening examination for familial breast cancer. In contrast with the MRISC study, patients with an abnormal mammogram as well as patients with clinical symptoms or a history of previous breast

cancer were included. Furthermore, the study was conducted in a single center, with a high level of expertise in performing and reading breast MR examinations. These factors might have influenced the finding of a high sensitivity of MRI for DCIS. Schouten van der Velden et al. [24] evaluated the literature from 1995 till 2008 on this subject and found that in these 30 studies the detection rate of DCIS by MRI ranged from 38 to 100%. Consistent with the results of Kuhl et al. [23] also other studies achieved high sensitivities for the detection of DCIS with MRI [25–28]. However, also in these studies most of the patients underwent MR for evaluation of known or suspected breast cancer, sometimes clinically evident. In some studies also cases of DCIS with microinvasion were included. Although the improvement of MR technique through the years with emphasis on high spatial resolution will have improved the detection of DCIS, the results of these studies certainly reflect a patient selection.

The detection of DCIS on MRI depends on three factors: tumor neovascularization, scanning technique, and MR presentation and recognition. The growth of a solid tumor above a diameter of a few millimeters is dependent of formation of new vascular structures. This neovascularization, with an increased permeability of the microvessels and high vascular density, is the prerequisite for contrast agent pooling in and around malignant lesions. Also, DCIS is capable of inducing neovascularization. The process of angiogenesis is stimulated by growth factors such as vascular endothelial growth factor (VEGF) and platelet-derived endothelial growth factor/thymidine phosphorylase (PD-ECGF/TD) released into the stroma by tumor and immune cells [29, 30]. Vogl et al. [29] found PD-ECGF/TP to be present in all cases of DCIS, without a significant correlation with the DCIS subtype. In the study of Guidi et al. [30], in 84% of the cases of DCIS microvessel density was more prominent than in benign tissue. The degree of angiogenesis was variable and strongly related to the degree of vascular endothelial growth factor (VEGF) expression. High grade DCIS was more often associated with a strong VEGF expression than low grade lesions, which was also observed by Vogl et al. [29]. However, these differences in VEGF expression between low grade and high grade lesions were not statistically significant. The variable degree of angiogenesis in DCIS will explain partly why not all cases will be visible on MR. In our series the seven cases pure DCIS without enhancement concerned high grade as well as low grade lesions. Also, Santamaria et al. [31] observed that the nuclear grade of DCIS was not significantly related to the degree of enhancement or the time–intensity curve. Facius et al. [27], on the contrary, who evaluated retrospectively the MR characteristics of 74 cases of pure DCIS, found contrast enhancement similar to glandular tissue only in low grade DCIS. This is in

concordance with the results of Kuhl et al. [23] who found that the sensitivity of MRI increased with higher nuclear grade, detecting 98% of high grade DCIS and 85% of low and intermediate grade DCIS.

The detection of DCIS requires a high spatial resolution scanning technique, ideally with a submillimeter pixel size in each in-plane direction and a slice thickness of 1–3 mm [32, 33]. DCIS is confined to the ducts and the ducts are surrounded by normal tissue. Image voxels represent an average intensity of the components including the voxels. When larger voxels are used the “partial volume averaging effect” may prevent reliable detection the often smaller structures of DCIS. Most of the non-enhancing DCIS cases of the MRISC study concerned MRI examinations made in the beginning years of the study. Insufficient spatial resolution might have been an important factor of not depicting DCIS.

Could false-negative diagnoses have been avoided?

A technically inadequate examination prevented the right diagnosis in one patient (Table 1, case 12), which could have been avoided by repeating the examination.

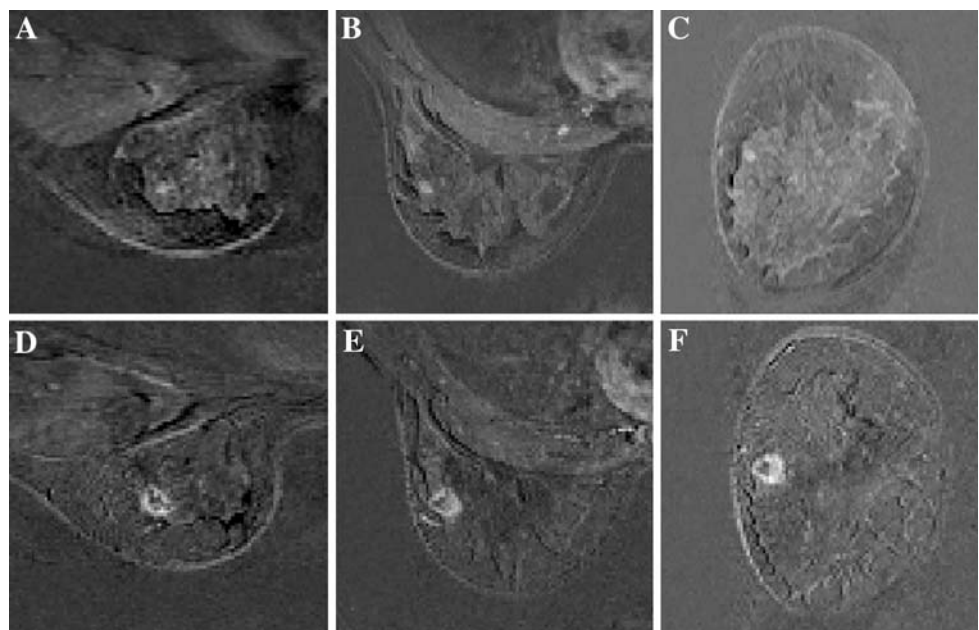
Although the MR examinations were planned preferably between day 5 and 15 of the menstrual cycle, intensive back ground contrast enhancement was seen regularly. By repeating the examination of all premenopausal patients with intensive contrast enhancement in accordance with the menstrual cycle, the chance of detecting the malignancy would have been higher (Table 1, case 10,11), although this will not be achievable.

Three false-negative MR diagnoses concerned small lesions with a type 2 or 3 curve in young high-risk patients (Table 2, case 1–3) who presented later with an interval carcinoma. These cases indicate that small lesions with a type 2 or 3 curve in young high-risk patients and especially in BRCA1 mutation carriers, with more rapidly growing tumors [34], cannot be neglected (Fig. 1). Short-interval follow-up consisting of second look ultrasound and/or MR examination has to be considered. However, this will negatively influence the false positive fraction and consequently increase additional work-up and number of biopsies.

Contrary to the MRISC study, in the MARIBS study [17] all MR as well as the mammographic examinations were double read. The effect of double reading of the MR examinations was evaluated in a population of screening examinations mixed with symptomatic cases [35]. The double reading policy achieved a higher sensitivity: 84% with single reading and 91% with double reading, but at costs of higher recall and biopsy rate. In our study, double reading probably could have prevented that five malignancies, evaluated at the review as BI-RADS 4 and 5 lesions, were not detected (Table 2, cases 4, 5, 7, 8, 9). An alternative to double reading would be computer-aided diagnosis (CAD). During this period of the MRISC study CAD was available in only one center.

In contrast with single center studies with only a few readers, the MRISC study is a multicenter study with a group of radiologists with varying levels of experience. The misinterpretation of the MR examination in three malignancies (Table 2, cases 4–6) as well as the three

Fig. 1 a–f Example of missed malignancy in a 40-year old BRCA 1 gene carrier due to small size at time of screening but visible at review. Shown are subtracted MR images of initial enhancement in sagittal (**a, d**), axial (**b, e**) and coronal (**c, f**) planes at time of screening (*upper row a–c*) and at time of diagnosis (*lower row d–f*). Four months after screening there is palpable malignancy of 15 mm showing as a irregular mass with rim-enhancement (**d, e, f**). Retrospectively a small (4 mm) mass with wash out is seen at the screening MRI (**a, b, c**)



missed carcinomas (Table 2, case 7–9) reflect the learning curve of a multi-center study.

Conclusion

More than 40% of the false-negative MR diagnoses involved pure DCIS and DCIS with invasive foci without enhancement and therefore a correct false-negative MR diagnosis, indicating a lower sensitivity of MRI for DCIS. In the MRISC study, mammography and MRI were complementary for the detection of DCIS, underlining the necessity of screening not only with MRI but also with mammography.

Other causes of a false-negative MR diagnosis were inadequate examination, small lesion size and extensive background enhancement (about 30%). In young high-risk patients, and especially in BRCA1 mutation carriers, short-term follow-up has to be considered for small lesions. The missed or misinterpreted cases, in about 30% the reason of a false-negative diagnosis, are reflecting the learning curve of a multicenter study.

References

- Kiemeny LA, Lemmers FA, Verhoeven RH, Aben KK, Honing C, de Nooijer J, Peeters PH, Visser O, Vlems FA (2008) The risk of cancer in the Netherlands. *Ned Tijdschr Geneesk* 152(41): 2233–2436
- Antoniou A, Pharoah PDP, Narod S, Risch HA, Eyfjord JE, Hopper JL (2003) Average risk of breast and ovarian cancer associated with BRCA1 or BRCA2 mutations detected in case series unselected for family history: a combined analysis of 22 studies. *Am J Hum Genet* 72:1117–1130
- Kolb TM, Lichy J, Newhouse JH (2002) Comparison of the performance of screening mammography, physical examination, and breast US and evaluation of factors that influence them: an analysis of 27,825 patient evaluation. *Radiology* 225(1):165–175
- Brekelmans CT, Seynave C, Bartels CC, Tilanus-Linthorst MM, Meijers-Heijboer EJ, Crepin CM, van Geel AA, Menke M, Verhoog LC, van den Ouweland A, Obdeijn IM, Klijn JG, Rotterdam committee for medical, genetic counselling (2001) Effectiveness of breast cancer surveillance in BRCA1/2 gene mutation carriers and women with high familial risk. *J Clin Oncol* 19(4):924–930
- Tilanus-Linthorst M, Verhoog L, Obdeijn IM, Bartels K, Menke-Pluymers M, Eggermont A, Klijn J, Meijers-Heijboer H, van der Kwast T, Brekelmans C (2002) A BRCA1/2 mutation, high breast density and prominent pushing margins of a tumor independently contribute to a frequent false-negative mammography. *Int J Cancer* 102:91–95
- Lakhani SR, Jacquemier J, Sloane JP, Guterson BA, Anderson TJ, van de Vijver MJ, Farid LM, Venter D, Antoniou A, Storf A, Smyth E, Steel M, Haites N, Scott RJ, Goldgar D, Neuhausen S, Daly PA et al (1998) Multifactorial analysis of differences between sporadic breast cancers and cancers involving BRCA1 and BRCA2 mutations. *J Natl Cancer Inst* 90:1138–1145
- Komenaka IK, Ditkoff B-A, Joseph K-A, Russo D, Chorochochurn P, Ward M, Horowitz E, El-Tamer MB, Schnabel FR (2004) The development of interval breast malignancies in patients with BRCA mutations. *Cancer* 100:2079–2083
- Harms SE, Flamig DP, Hesley KL, Meiches MD, Jensen RA, Evans WP, Savino DA, Wells RV (1993) MR imaging of the breast with rotating delivery of excitation off resonance: clinical experience with pathologic correlation. *Radiology* 187(2):493–501
- Heywang-Kobrunner SH (1994) Contrast-enhanced magnetic resonance imaging of the breast. *Invest Radiol* 29:94–104
- Orel SG, Schnall MD (2001) MR Imaging of the breast for the detection, diagnosis, and staging of breast cancer. *Radiology* 220:13–30
- Tilanus-Linthorst MMA, Obdeijn AIM, Bartels CCM, de Koning HJ, Oudkerk M (2000) First experiences in screening women at high risk for breast cancer with MR imaging. *Breast Cancer Res Treat* 63:53–60
- Kuhl CK, Schmützler RK, Leutner CC, Kempe A, Wardelmann E, Hocke A, Maringa M, Pfeifer U, Krebs D, Schild HH (2000) Breast imaging screening in 192 women proved or suspected to be carriers of a breast cancer susceptibility gene: preliminary results. *Radiology* 215:267–279
- Warner E, Plewes DB, Shumak RS, Catzavelos GC, Prospero Di LS, Yaffe MJ, Goel V, Ramsey E, Chart PL, Cole DCE, Taylor GA, Cutrara M, Samuels TH, Murphy JP, Narod SA (2001) Comparison of breast magnetic resonance imaging, mammography, and ultrasound for surveillance of women at high risk for hereditary breast cancer. *J Clin Oncol* 19:3524–3531
- Podo E, Sardanelli F, Canese R, D'Agnolo, Natali PG, Crecco M, Grandinetti ML, Musumeci R, Trecate G, Bergonzi S, De Simone T, Pasisni B, Manoukian S, Spatti GB, Vergnaghi D, Morassut S, Panizza P, Del Maschio A (2002) The Italian multi-center project on evaluation of MRI and other imaging modalities in early detection of breast cancer in subjects at high genetic risk. *J Exp Clin Cancer Res* 21(Suppl 3):115–124
- Kriege M, Brekelmans CTM, Boetes C, Besnard PE, Zonderland HM, Obdeijn IM, Manoliu RA, Kok T, Peterse H, Tilanus-linthorst MMA, Muller SA, Meijer S, Oosterwijk JC, Beex LVAM, Tollenaar RAEM, de Koning HJ, Rutgers EJT, Klijn JGM (2004) Efficacy of MRI and mammography for breast-cancer screening in women with a familial or genetic predisposition. *N Engl J Med* 351(5):427–437
- Warner E, Plewes DB, Hill KA, Causer PA, Zubovits JT, Jong RA, Cutrara MR, DeBoer G, Yaffe MJ, Messner SJ, Meschino WS, Piron CA, Narod SA (2004) Surveillance of BRCA1 and BRCA2 mutation carriers with magnetic resonance imaging, ultrasound, mammography, and clinical breast examination. *JAMA* 292:1317–1325
- MARIBS study group (2005) Screening with magnetic resonance imaging and mammography of a UK population at high familial risk of breast cancer; a prospective multicenter cohort study (MARIBS). *Lancet* 365:1769–1778
- Kuhl CK, Schradang S, Leutner CC, Morakkabati-Spitz N, Wardelmann E, Fimmers R, Kuhn, Schild HH (2005) Mammography, breast ultrasound, and magnetic resonance imaging for surveillance of women at high familial risk of breast cancer. *J Clin Oncol* 23:8469–8476
- Sardanelli F, Podo F, D'Agnolo G, Verdecchia A, Santaquilana M, Musumeci R, Trecate G, Manoukian S, Morassut S, de Giacomo C, Federico M, Cortesi L, Corcione S, Cirillo S, Marra V (2007) Multicenter comparative multimodality surveillance of women at genetic-familial high risk for breast cancer (HIBCRIT Study): interim results. *Radiology* 242:698–715
- Sardanelli F, Podo F (2007) Breast imaging in women at high risk of breast cancer. Is something changing in early breast cancer detection? *Eur Radiol* 17:873–887

21. Warner E, Messersmith H, Causer P, Eisen A, Shumal R, Plewes D (2008) Systematic review: using magnetic resonance imaging to screen women at high risk for breast cancer. *Ann Intern Med* 148:671–679
22. Breast Imaging Reporting and Data System (BI-RADS) (2003) Ultrasound, mammography and magnetic resonance atlas. American College of Radiology, Reston, VA
23. Kuhl CK, Schrading S, Bieling HB, Wardelmann E, Leutner CC, Koenig R, Kuhn W, Schild HH (2007) MRI for diagnosis of pure ductal carcinoma in situ: a prospective observational study. *Lancet* 370:485–492
24. Schouten van der Velden AP, Schlooz-Vries MS, Boetes C, Wobbes T (2009) Magnetic resonance imaging of ductal carcinoma in situ: what is its clinical application? A review. *Am J Surg* 198(2):262–269
25. Berg WA, Gutierrez L, NessAiver MS, Carter WB, Bhargavan M, Lewis RS, Ioffe OB (2004) Diagnostic accuracy of mammography, clinical examination, US, and MR Imaging in pre-operative assessment of breast cancer. *Radiology* 233:830–849
26. Menell JH, Morris EA, Dershaw DD, Abramson AF, Brogi E, Liberman L (2005) Determination of the presence and extent of pure ductal carcinoma in situ by mammography and magnetic resonance imaging. *Breast J* 6:382–390
27. Facius M, Renz DM, Neubauer H, Böttcher J, Gajda M, Camara O, Kaiser WA (2007) Characteristics of ductal carcinoma in situ in magnetic resonance imaging. *Clin Imaging* 3:394–400
28. Rosen EL, Smith-Foley SA, DeMartini WB, Eby PR, Peacock S, Lehman CD (2008) BI-RADS MRI enhancement characteristics of ductal carcinoma in situ. *Breast J* 13(6):545–550
29. Vogl G, Dietze O, Hauser-Kronberger C (2005) Angiogenic potential of ductal carcinoma in situ (DCIS) of human breast. *Histopathology* 47:617–624
30. Guidi AJ, Schnitt SJ, Fischer L, Tognazzi K, Harris JR, Dvorak HF, Brown LF (1997) Vascular permeability factor (Vascular endothelial growth factor) expression and angiogenesis in patients with ductal carcinoma in situ of the breast. *Cancer* 80(10):1945–1953
31. Santamaria G, Velasco M, Farrus B, Zanon G, Fernandez PL (2008) Pre-operative MRI of pure intraductal breast carcinoma: a valuable adjunct to mammography in assessing cancer extent. *Breast* 17:186–194
32. Rausch DR, Hendrick RE (2006) How to optimize clinical breast MR Imaging practices and techniques on your 1.5-Tesla system. *RadioGraphics* 26:1469–1484
33. Kuhl C (2007) The current status of breast MR Imaging. *Radiology* 244(2):356–378
34. Tilanus-Linthorst MM, Obdeijn IM, Hop WC, Causer PA, Leach MO, Warner E, Pointon L, Hill K, Klijn JG, Warren RM, Gilbert FJ (2007) BRCA1 mutation and young age predict fast breast cancer growth in the Dutch, United Kingdom, and Canadian magnetic resonance imaging screening trials. *Clin Cancer Res* 13(24):7357–7362
35. Warren RM, Pointon L, Thompson D, Hoff R, Gilbert FJ, Padhani A, Easton D, Lakhani SR, Leach MO, UK Magnetic Resonance Imaging in breast screening (MARIBS) Group (2005) Reading protocol for dynamic contrast-enhanced MR images of the breast: sensitivity and specificity analysis. *Radiology* 236(3):779–788