



**HAL**  
open science

## **Resolution of invasive fungal sinusitis in immunocompromised patients: neutrophil count is crucial beside a combined medical and surgical approach**

Patrizia Zappasodi, Marianna Rossi, Carlo Castagnola, Fabio Pagella, Elina Matti, Caterina Cavanna, Alessandro Corso, Maurizio Bonfichi, Mario Lazzarino

### ► To cite this version:

Patrizia Zappasodi, Marianna Rossi, Carlo Castagnola, Fabio Pagella, Elina Matti, et al.. Resolution of invasive fungal sinusitis in immunocompromised patients: neutrophil count is crucial beside a combined medical and surgical approach. *Annals of Hematology*, 2009, 89 (7), pp.737-739. 10.1007/s00277-009-0854-z . hal-00535101

**HAL Id: hal-00535101**

**<https://hal.science/hal-00535101>**

Submitted on 11 Nov 2010

**HAL** is a multi-disciplinary open access archive for the deposit and dissemination of scientific research documents, whether they are published or not. The documents may come from teaching and research institutions in France or abroad, or from public or private research centers.

L'archive ouverte pluridisciplinaire **HAL**, est destinée au dépôt et à la diffusion de documents scientifiques de niveau recherche, publiés ou non, émanant des établissements d'enseignement et de recherche français ou étrangers, des laboratoires publics ou privés.

## Resolution of invasive fungal sinusitis in immunocompromised patients: neutrophil count is crucial beside a combined medical and surgical approach

Patrizia Zappasodi · Marianna Rossi · Carlo Castagnola · Fabio Pagella ·  
Elina Matti · Caterina Cavanna · Alessandro Corso · Maurizio Bonfichi ·  
Mario Lazzarino

Received: 30 July 2009 / Accepted: 19 October 2009 / Published online: 7 November 2009  
© Springer-Verlag 2009

Dear Editor,

Invasive fungal sinusitis is a rare, severe infection, typically occurring in immunocompromised patients who have impaired neutrophil function or who have received long-term immunosuppressive therapy [1]. Haematological patients and among them, those affected by acute leukaemia and myelodysplastic syndrome are at higher risk [2]. The occurrence of this complication often compromises the therapeutic programme for the underlying haematological condition, necessitating a delay or cessation of chemotherapy with a subsequent high risk of relapse or progression. The acute fulminant form is characterised by its speed of evolution and is associated with a high mortality rate that reaches 100% in cases of intracranial mycotic dissemination [3]. The clinical onset is generally subtle and insidious; facial swelling or pain with or without fever must be promptly considered as possible signs of invasive sinusitis. Computed tomography (CT) evidence of pronounced thickening of the mucosa of the nasal cavity strongly suggests the

diagnosis, which can be confirmed by identification of the pathogenic fungus in sinus tissues. Surgical debridement of the affected sinus is a necessary diagnostic and therapeutic procedure and must be combined with systemic antifungal therapy. The fungi most frequently involved are *Aspergillus* and *Zygomycetes*. Prognosis is related to various factors, such as the speed of diagnosis and treatment, the type of fungal infection [3], dissemination to the central nervous system, and complete neutrophil recovery [4]. The scarce information in the literature on invasive fungal sinusitis in immunocompromised patients highlights the importance and efficacy of a combined surgical and medical approach [5]. However, the factors with a major role in the evolution of the infection have not been discussed.

We describe here seven cases of invasive fungal sinusitis, observed at our institution between November 2006 and December 2008, in patients affected by acute leukaemia (five patients with acute myeloid leukaemia and two with acute lymphoblastic leukaemia). These seven cases occurred among a total of 130 patients with acute leukaemia newly diagnosed in the same period. Table 1 summarises the characteristics of these seven patients and their infections. In all cases, the infection developed while the patients were severely neutropenic (neutrophil count < 500/mm<sup>3</sup>); the neutropenia was chemotherapy-related in six patients, while in one case of acute leukaemic transformation of a myelodysplastic syndrome, it was an expression of the patient's haematological disease. This last patient had never been treated before; two out of the other six patients had received only induction chemotherapy, while the other four patients had a prior history of more chemotherapy (1–8 lines of chemotherapy). Facial pain with or without facial swelling was the initial symptom in all cases, associated with fever in six out of the seven patients. CT scanning, which

---

P. Zappasodi (✉) · M. Rossi · C. Castagnola · A. Corso ·  
M. Bonfichi · M. Lazzarino  
Division of Haematology,  
Foundation IRCCS Policlinico San Matteo, University of Pavia,  
27100 Pavia, Italy  
e-mail: p.zappasodi@smatteo.pv.it

F. Pagella · E. Matti  
Department of Otorhinolaryngology,  
Foundation IRCCS Policlinico San Matteo, University of Pavia,  
Pavia, Italy

C. Cavanna  
Virology and Microbiology Laboratory,  
Department of Diagnostic Medicine and Services,  
Foundation IRCCS Policlinico San Matteo, University of Pavia,  
Pavia, Italy

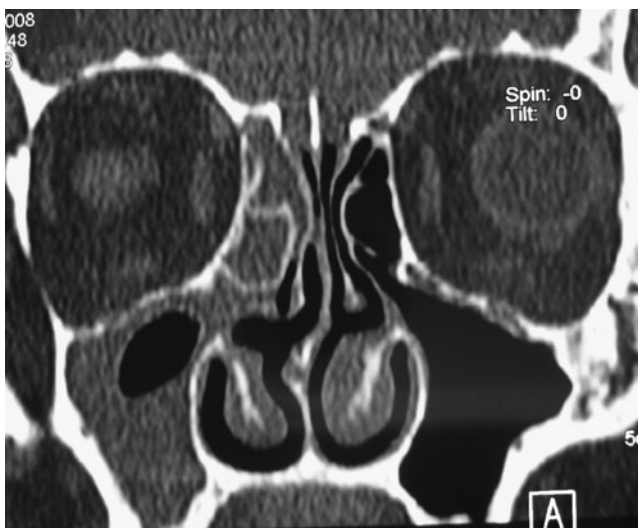
**Table 1** Characteristics of the patients and their infections

Patients (identified by their initials)	NFIH	LM	SL	ZF	BG	PD	MMR
Age (years)	33	56	19	65	67	68	62
Diagnosis	B-ALL	AML	B-ALL	AML-MDS	AML	AML	AML
Phase of disease	Relapse	Onset	Relapse	Onset	Refractory	Onset	Relapse
Symptoms and signs	Facial pain and swelling; fever	Unilateral nasal swelling and pain; fever	Facial pain and swelling; fever	Facial pain and swelling; fever	Eyelid oedema with pain; fever	Facial pain and swelling	Facial pain and swelling; fever
Duration of neutropenia (days) <sup>a</sup>	35	30	51	>90	60	90	17
Previous lines of chemotherapy (n)	2	1	8	0	1	1	3
Fungal species	Aspergillus flavus	Aspergillus flavus	Aspergillus flavus	Aspergillus niger	Aspergillus flavus	Mucor+ Fusarium	Mucor
Galactomannan antigen	Positive	Positive	Negative	Negative	Positive	ND	Negative
Antifungal therapy	AmBlipo/Vor	AmBlipo/Vor	AmBlipo/Vor	Vor	AmBlipo/Vor	Itra/AmBlipo	AmBlipo/Pos
G-CSF therapy	Yes	No	No	Yes	No	Yes	No
Surgical debridement	Yes	Yes	No	Yes	Yes	Yes	No

*B-ALL* B cell acute lymphocytic leukaemia, *AML* acute myeloid leukaemia, *MDS* myelodysplastic syndrome, *AmBlipo* liposomal amphotericin B, *Vor* voriconazole, *Pos* posaconazole, *Itra* itraconazole, *ND* not done, *G-CSF* granulocyte colony-stimulating factor

<sup>a</sup> Neutropenia < 500/mm<sup>3</sup>

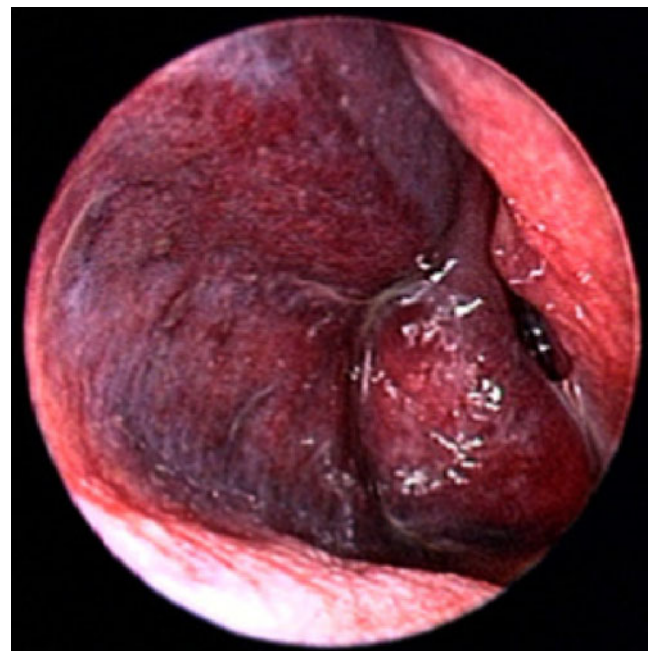
were performed in an average of 2 days (range, 1–6 days) after the occurrence of the symptoms, revealed, in all cases, unilateral paranasal sinus involvement with opacification and hyperplastic mucosa. Figure 1 shows an exemplary CT scan of the paranasal sinuses, revealing hyperplasia of the right maxillary and ethmoidal mucosa. In two cases, osteolysis of the maxillary and ethmoidal walls was present, and in one case, the CT scan revealed necrotic lesions of the hard palate and turbinates. Prompt endoscopic evaluation confirmed the radiological suspicion of an invasive sinus infection by the finding of friable and ischaemic or necrotic



**Fig. 1** Coronal computer tomography scan of the paranasal sinuses revealing hyperplasia of the right maxillary and ethmoidal mucosa

sinus mucosa. Figure 2 shows an endoscopic view of the right nasal fossa through a 0° angled scope; the middle turbinate and mucosa of the lateral wall have a necrotic appearance.

Microbiological analysis of biopsy specimens revealed the presence of *Aspergillus* in five cases, *Mucor* in one, and



**Fig. 2** Endoscopic view of the right nasal fossa through a 0° angled scope: necrotic appearance of the middle turbinate and mucosa of the lateral wall

both *Mucor* and *Fusarium* in one. Galactomannan antigen was detected in three patients, and concomitant mycotic lung nodules were found by thoracic CT in three patients. Five out of the seven patients underwent surgical endoscopic debridement of necrotic tissues; no haemorrhagic complications occurred despite severe thrombocytopenia. Four patients promptly started treatment with liposomal amphotericin B (AmBlipo) and were given systemic voriconazole as recommended after *Aspergillus* had been identified [6]. One patient received voriconazole as first-line therapy, another was treated first with itraconazole and then, because of progression, with AmBlipo, and the remaining patient received posaconazole because of persistent fever despite treatment with AmBlipo. Among the five patients treated with combined medical and surgical therapy, two died of progressive infection, 18 and 44 days after the diagnosis, in a phase of persistent neutropenia; while, in the other three patients, the mycosis improved substantially after complete neutrophil recovery, and CT scans performed after 30–45 days documented resolution of the radiological signs of infection. Of the two patients treated only with systemic antifungal therapy, one died 16 days after diagnosis in a phase of blastic evolution of acute leukaemia, while the other case recovered, although the mucormycosis had extended to the cavernous sinus causing occlusion of the carotid artery with consequent ischaemic cerebral lesions responsible for hemiplegia. This patient received AmBlipo followed by posaconazole and although no surgical treatment was performed, a clinical improvement was observed when the neutrophil count increased, heralding complete remission of the acute leukaemia.

Unlike the patients described by Vener et al. [5], our cases were all neutropenic at the onset of infection and mycosis resolved only in those in whom neutrophils reappeared, suggesting that medical and surgical efforts are useful and necessary, but not sufficient if the underlying leukocyte impairment persists. Neutrophil transfusions could represent a therapeutic option in these cases in order to support treatment before haematological recovery [7], but are still a complex procedure without clear and documented advantages in patients with long-lasting neutropenia.

In conclusion, our experience in severely neutropenic patients confirms the following: (a) the importance of careful and swift recognition of initial signs of sinusitis followed by a prompt otorhinolaryngoiatric intervention to confirm the diagnostic suspicion and to remove infected tissues; (b) that surgery is effective and safe also in thrombocytopenic patients; and (c) that the recovery of a normal neutrophil count is essential for a positive evolution of the infection and therefore, represents a crucial prognostic factor.

The authors do not have any commercial or other associations that might pose a conflict of interest in connexion with the submitted paper.

## References

1. Epstein VA, Kern RC (2008) Invasive fungal sinusitis and complications of rhinosinusitis. *Otolaryngol Clin N Am* 41:497–524
2. Muhlemann K, Wenger C, Zenhausem R, Tauber MG (2005) Risk factors for invasive aspergillosis in neutropenic patients with hematologic malignancies. *Leukemia* 19:545–550
3. Parikh SL, Venkatraman G, Del Gaudio JM (2004) Invasive fungal sinusitis: a 15 year review from a single institution. *Am J Rhinol* 18:75–81
4. Rodriguez TE, Falkowski NR, Harkema JR, Huffnagle GB (2007) Role of neutrophils in preventing and resolving acute fungal sinusitis. *Infect Immun* 75:5663–5668
5. Vener C, Carrabba M, Fracchiolla NS, Costa A, Fabio G, Hu C, Sina C, Guastella C, Pignataro L, Lambertenghi Delilieri G (2007) Invasive fungal sinusitis: an effective combined treatment in five haematological patients. *Leuk Lymphoma* 48:1577–1586
6. Herbrecht R, Denning DW, Patterson TF, Herbrecht R, Denning DW, Patterson TF, Bennett JE, Greene RE, Oestmann JW, Kern WV, Marr KA, Ribaud P, Lortholary O, Sylvester R, Rubin RH, Wingard JR, Stark P, Durand C, Caillot D, Thiel E, Chandrasekar PH, Hodges MR, Schlamm HT, Troke PF, de Pauw B, Invasive Fungal Infections Group of the European Organisation for Research and Treatment of Cancer and the Global Aspergillus Study Group (2002) Voriconazole versus amphotericin B for primary therapy of invasive aspergillosis. *N Engl J Med* 347:408–415
7. Aki ZS, Sucak GT, Yegin ZA, Guzel O, Erbas G, Senol E (2008) Hematopoietic stem cell transplantation in patients with active fungal infection: not a contraindication for transplantation. *Trans Proc* 40:1579–1585