



**HAL**  
open science

## Successful treatment of MDS with lenalidomide, complicated by transient autoimmune hemolysis

Wan-Ling Sun, Leonhard Köck, Alois Walder, Martin Erdel, Susanne  
Kilga-Nogler, Harald Schennach, Michael Fiegl

► **To cite this version:**

Wan-Ling Sun, Leonhard Köck, Alois Walder, Martin Erdel, Susanne Kilga-Nogler, et al.. Successful treatment of MDS with lenalidomide, complicated by transient autoimmune hemolysis. *Annals of Hematology*, 2009, 89 (3), pp.327-329. 10.1007/s00277-009-0802-y . hal-00535083

**HAL Id: hal-00535083**

**<https://hal.science/hal-00535083>**

Submitted on 11 Nov 2010

**HAL** is a multi-disciplinary open access archive for the deposit and dissemination of scientific research documents, whether they are published or not. The documents may come from teaching and research institutions in France or abroad, or from public or private research centers.

L'archive ouverte pluridisciplinaire **HAL**, est destinée au dépôt et à la diffusion de documents scientifiques de niveau recherche, publiés ou non, émanant des établissements d'enseignement et de recherche français ou étrangers, des laboratoires publics ou privés.

## Successful treatment of MDS with lenalidomide, complicated by transient autoimmune hemolysis

Wan-Ling Sun · Leonhard Köck · Alois Walder ·  
Martin Erdel · Susanne Kilga-Nogler ·  
Harald Schennach · Michael Fiegl

Received: 16 July 2009 / Accepted: 27 July 2009 / Published online: 12 August 2009  
© Springer-Verlag 2009

Dear Editor,

A 64-year-old woman was diagnosed in February 2003 with myelodysplastic syndrome (MDS; refractory cytopenia with multilineage dysplasia (RCMD)[1]), with chromosomal deletions 5q and 20q. Despite erythropoietin, the patient was transfusion dependent since May 2005. The first positive direct antiglobulin test (DAT) available was in January 2005. In the indirect antiglobulin test (IAT), autoantibodies against Rh antigens with different specificities such as f (ce), e, C, and even D were detected. In March 2006, subclinical hemolysis with elevation of lactate dehydrogenase (LDH) and decrease of haptoglobin were registered, which resolved itself without specific therapy. With the increasing frequency of transfusions, irregular

alloantibodies developed, directed against the Kell antigen Kpa. Coombs-reactive autoantibodies were detectable; the DAT became strongly positive. As it became difficult to find compatible red cell packs, lenalidomide was initiated in June 2006 despite two previous thrombo-embolic events, with anemia of 57 g/L hemoglobin (Fig. 1). The patient received 10 mg of lenalidomide daily for 21 days every 4 weeks, supplemented by low-molecular weight heparin [2]. Complicating the course, clinical and laboratory signs of hemolytic anemia appeared on day 20 of lenalidomide, with marked increase of bilirubin and LDH levels (Fig. 1) and depletion of haptoglobin. Both DAT and IAT were positive. Thus, warm autoimmune hemolytic anemia (AIHA) was diagnosed and high-dose methylprednisolone and immunoglobulin were administered. Lenalidomide was interrupted, but reinitiated on day 29 due to the urgency of response needed. Fortunately, hemolytic activity tapered off within a week, without relapse thereafter.

As expected, neutrophils and platelets declined gradually in the first weeks of lenalidomide (Fig. 1), potentially being indicative of subsequent response [3]. Indeed, on the 30th day after start of lenalidomide, the last transfusion was needed. Later, with hemoglobin levels >140 g/L, lenalidomide was reduced to a maintenance dose of 5 mg every other day. Assessed by the recent MDS criteria [4], both hematologic and cytogenetic responses were complete (March 2008). The therapy was continued until February 2008, thereafter, lenalidomide was withdrawn due to patient's wish. In October 2008, pancytopenia and need for transfusion reappeared. The aberrant karyotype, stable in four evaluations before start of lenalidomide, changed to a complex pattern with deletions 5q and 20q, monosomy 3, and translocations t(X;12), t(3;22), and t(17;21). Transformation to secondary acute leukemia was diagnosed (Fig. 1). In March 2009, the patient died from septicemia.

---

W.-L. Sun

Department of Hematology,  
Xuanwu Hospital Capital Medical University,  
Beijing, China

L. Köck · A. Walder

Department of Internal Medicine, County Hospital of Lienz,  
Lienz, Austria

M. Erdel

Department of Human Genetics/Cytogenetics,  
Medical University of Innsbruck,  
Innsbruck, Austria

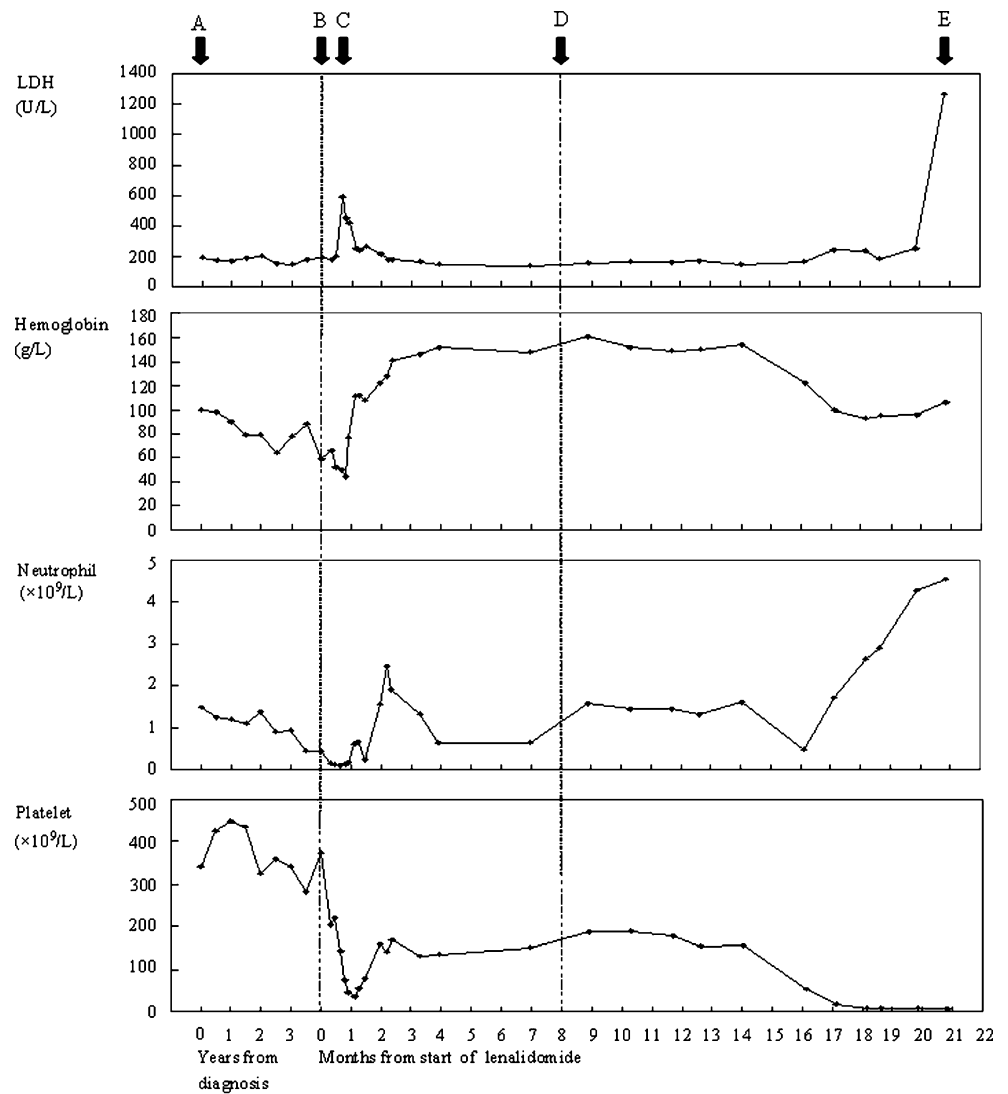
S. Kilga-Nogler · H. Schennach

Institute of Transfusion Medicine, Central Hospital of Innsbruck,  
Innsbruck, Austria

M. Fiegl (✉)

Department of Internal Medicine V, Division of Hematology  
and Oncology, Medical University of Innsbruck,  
Anichstrasse 35,  
6020 Innsbruck, Austria  
e-mail: michael.fiegl@i-med.ac.at

**Fig. 1** Time evolution of the main parameters from the diagnosis



Note: A: Diagnosis;  
 B: Start of lenalidomide;  
 C: Hemolysis;  
 D: Stop of lenalidomide;  
 E: Death.

Lenalidomide, a novel immunomodulatory drug, was administered successfully in this del(5q) MDS. However, at beginning of lenalidomide, overt hemolysis occurred, which is uncommon in MDS [5, 6]. Generally, autoantibodies can be detected in 20% to 35% of MDS patients, and DAT is positive in a minority (less than 10%) [7, 8].

Until now, lenalidomide-associated AIHA was observed in one MDS and lymphoma patient each [9, 10]. Thus, our case is the second report on AIHA in MDS during lenalidomide therapy. Lenalidomide-triggered AIHA does indeed seem to represent a clinically relevant side effect. It may be speculated that lenalidomide contributed to exacerbation into manifest hemolysis by inducing effector mechanisms, which by themselves used the preformed autoantibodies for action.

## References

- Vardiman JW, Harris NL, Brunning RD (2002) The World Health Organization (WHO) classification of the myeloid neoplasms. *Blood* 100:2292–2302
- Giagounidis A, Fenaux P, Mufti GJ et al (2008) Practical recommendations on the use of lenalidomide in the management of myelodysplastic syndromes. *Ann Hematol* 87:345–352
- Sekeres MA, Maciejewski JP, Giagounidis AA et al (2008) Relationship of treatment-related cytopenias and response to lenalidomide in patients with lower-risk myelodysplastic syndromes. *J Clin Oncol* 26:5943–5949
- Cheson BD, Bennett JM, Kantarjian H et al (2000) Report of an international working group to standardize response criteria for myelodysplastic syndromes. *Blood* 96:3671–3674

5. Lin JT, Wang WS, Yen CC et al (2002) Myelodysplastic syndrome complicated by autoimmune hemolytic anemia: remission of refractory anemia following mycophenolate mofetil. *Ann Hematol* 81:723–725
6. Giagounidis AA, Haase S, Germing U et al (2005) Autoimmune disorders in two patients with myelodysplastic syndrome and 5q deletion. *Acta Haematol* 113:146–149
7. Novaretti MC, Soplete CR, Velloso ER et al (2001) Immunohematological findings in myelodysplastic syndrome. *Acta Haematol* 105:1–6
8. Mufti GJ, Figs A, Hamblin TJ et al (1986) Immunological abnormalities in myelodysplastic syndromes. I. Serum immunoglobulins and autoantibodies. *Br J Haematol* 63:143–147
9. List A, Kurtin S, Roe DJ et al (2005) Efficacy of lenalidomide in myelodysplastic syndromes. *N Engl J Med* 352:549–557
10. Darabi K, Kantamnei S, Wiernik PH (2006) Lenalidomide-induced warm autoimmune hemolytic anemia. *J Clin Oncol* 24:e59