HAL
open science

Toxic non-resorptive internal hydrocephalus as a result of haemorrhagic ventriculitis during induction chemotherapy of Bcr-Abl positive acute lymphoblastic leukaemia

Kalina Ramadanova, Hansjörg Hoff, Nicola Gökbuget, Ulrike Reuner, Susanne Hamann, Gerhard Ehninger, Markus Schaich

To cite this version:

Kalina Ramadanova, Hansjörg Hoff, Nicola Gökbuget, Ulrike Reuner, Susanne Hamann, et al.. Toxic non-resorptive internal hydrocephalus as a result of haemorrhagic ventriculitis during induction chemotherapy of Bcr-Abl positive acute lymphoblastic leukaemia. Annals of Hematology, 2009, 89 (2), pp.221-223. 10.1007/s00277-009-0781-z . hal-00535072

HAL Id: hal-00535072

https://hal.science/hal-00535072v1

Submitted on 11 Nov 2010

HAL is a multi-disciplinary open access archive for the deposit and dissemination of scientific research documents, whether they are published or not. The documents may come from teaching and research institutions in France or abroad, or from public or private research centers.

L'archive ouverte pluridisciplinaire **HAL**, est destinée au dépôt et à la diffusion de documents scientifiques de niveau recherche, publiés ou non, émanant des établissements d'enseignement et de recherche français ou étrangers, des laboratoires publics ou privés.

Ann Hematol (2010) 89:221–223
DOI 10.1007/s00277-009-0781-z

LETTER TO THE EDITOR

Toxic non-resorptive internal hydrocephalus as a result of haemorrhagic ventriculitis during induction chemotherapy of Bcr-Abl positive acute lymphoblastic leukaemia

Kalina Ramadanova · Hansjörg Hoff · Nicola Gökbuget · Ulrike Reuner · Susanne Hamann · Gerhard Ehninger · Markus Schaich

Received: 25 May 2009 / Accepted: 20 June 2009 / Published online: 3 July 2009
© Springer-Verlag 2009

Dear Editor,

Non-resorptive hydrocephalus results from disturbed reabsorption of cerebrospinal fluid (CSF) caused by damage to the absorptive tissue. The most common causes in adults are infections of the central nervous system (CNS) and haemorrhages as a consequence of intracerebral bleeding or craniocerebral injury. On accumulation of CSF, the ventricles expand and may cause an increase in intracranial pressure, which can damage the surrounding brain tissue. In non-resorptive hydrocephalus, decreased mental activity appears, including lethargy, apathy, impaired memory, and speech problems. Urinary and bowel incontinence can also occur.

In this report, we describe the unusual case of a young patient with Bcr-Abl positive acute lymphoblastic leukaemia (common B-ALL), who developed a non-resorptive hydrocephalus as a result of haemorrhagic ventriculitis during induction chemotherapy.

In August 2008, a 20-year-old woman was admitted to our hospital with recurrent infections. A comprehensive laboratory workup revealed a hyperleukocytosis of 50×10^9/l as well as a severe anaemia of 5.81 g/dL (3.6 mmol/l) and thrombopenia of 14×10^9/l. Differential blood count showed low numbers of granulocytes and lymphocytes accompanied by 61% blast cells. Bone marrow examination confirmed the diagnosis of an ALL (common B-ALL) with aberrant expression of CD13 and CD33. The ALL was classified as a very high-risk type, as molecular and cytogenetic analysis were positive for the Bcr-Abl fusion transcript and translocation t(9;22), respectively. No additional cytogenetic aberrations were found.

The patient was treated within the German Multicenter Adult ALL (GMALL 2003) therapy study and received induction treatment in accordance with the study protocol including prophylactic radiation of the brain and intrathecal chemotherapy parallel to the systemic chemotherapy. In addition, the patient received Imatinib, which inhibits Bcr-Abl tyrosine kinase activity, at 400 mg per day, starting on day 6 of the first induction chemotherapy.

There were no therapy-related complications seen through the first induction therapy. In October 2008, during the second induction therapy on day 8 of radiation therapy, the patient abruptly became somnolent and, afterwards, had a series of generalised epileptic seizures. Until then, the patient had received 1,670 mg cyclophosphamide on day 1,

K. Ramadanova (✉) · S. Hamann · G. Ehninger · M. Schaich
Department of Internal Medicine I,
University Hospital Carl Gustav Carus Dresden,
Dresden University of Technology,
Fetscherstr. 74,
01307 Dresden, Germany
e-mail: Kalina.Ramadanova@uniklinikum-dresden.de

H. Hoff
Department of Neuroradiology,
University Hospital Carl Gustav Carus Dresden,
Dresden University of Technology,
Fetscherstr. 74,
01307 Dresden, Germany

N. Gökbuget
Department of Internal Medicine II,
University Hospital Johann-Wolfgang Goethe,
Theodor-Stern Kai 7,
60590 Frankfurt/Main, Germany

U. Reuner
Department of Neurology,
University Hospital Carl Gustav Carus Dresden,
Dresden University of Technology,
Fetscherstr. 74,
01307 Dresden, Germany

125 mg cytarabine on days 3–6 and 10–11, 100 mg 6-mercaptopurine on days 1–11 of second induction therapy, 16 Gy of radiation therapy, and intrathecal application of 15 mg methotrexate (on days 3 and 11). Thereafter, intrathecal chemotherapy and cranial radiation were definitely stopped. In comparison to a previous 4-week-old normal computed tomography image (Fig. 1), magnetic resonance imaging of the brain and brainstem now revealed an increasing lateral ventricular volume, due to a circulatory disturbance of the CSF (Fig. 2). The third ventricle was slightly affected by volume increase. Consecutively, external CSF spaces were narrowed.

In addition, exiguous fluid levels were observed in the posterior horns of the lateral ventricles, which corresponded to blood accumulation. Increased CSF flow in the third and fourth ventricles as a consequence of dysfunctional CSF reabsorption was manifest. Dilated cortical vessels suggested a toxic impairment of the brain. Manifestations of lymphoma, sinus thrombosis, or major bleeding were excluded. Emergency intervention included insertion of an external ventricular drain. Several efforts to remove the drain resulted in somnolence and epileptic seizures, so that a permanent ventriculoperitoneal shunt was inserted by trepanation. Analyses of the CSF remained without detection of malignancy or infections.

Further observation and neuropsychological examination of the patient revealed a severe limitation of the short-term and long-term memory as well as distinctive difficulties in memory consolidation and learning. Compared to the previous status, fiddling and infantile behaviour was conspicuous.

Fig. 1 Computed tomography without contrast of the frontobasal and temporal brain and cerebellum. Normal image of the brain with a small ventricle system, especially in the temporal horn (*arrow*)

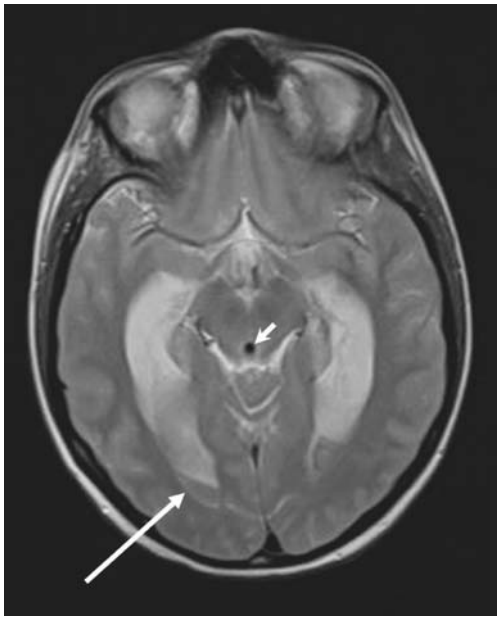

Fig. 2 T2-weighted magnetic resonance imaging (MRI), axial plane of the temporal lobes of the brain, done 4 weeks after computed tomography (Fig. 1). MRI shows a widened ventricle system with wide temporal horn and sedimentation of blood in the posterior horn (*long arrow*) and low signal in the cerebral aqueduct (*short arrow*). The outer cerebrospinal fluid spaces are narrowed

Nevertheless, due to her good general condition and complete haematological remission, the second induction therapy and also the first consolidation therapy could be completed without giving intrathecal prophylactic chemotherapy again. In addition, the medication with Imatinib was ceased because of potential adverse effects on the CNS.

After first consolidation, the patient is still in complete haematologic remission and on the basis of a very high-risk disease, early allogenic stem cell transplantation is planned as second consolidation soon. Improvement of memory function could be achieved by intensive practicing.

CNS prophylaxis with intrathecal therapy and CNS radiation has significantly improved the outcome of patients with ALL [1]. Nevertheless, several authors have reported neurotoxicity and adverse effects on the CNS after the administration of intrathecal chemotherapy and/or cranial irradiation. Complications range from encephalopathy, seizures, and papilloedema to cauda equina syndrome, radiculopathy, and myelopathy [2, 3].

In our case, findings indicated haemorrhagic ventriculitis as a cause of non-resorptive hydrocephalus internus. We propose a multifactorial genesis, with intrathecal chemotherapy, radiation, and Imatinib treatment contributing to high cumulative CNS toxicity and non-infectious inflammation of the lateral ventricles.

Convulsion and increased intracranial pressure represent rare neurological adverse effects of Imatinib. Hydrocephalus has not been previously associated with Imatinib treatment.

Literature research revealed few reports of leucoencephalopathy associated with hydrocephalus after intrathecal chemotherapy or radiation. Most reports concerning chemotherapy-induced hydrocephalus correspond to long-term complications in children with ALL. Patients with solid tumours and cerebral metastases dominate in reports on adults. Contrary to our case after intrathecal chemotherapy, and also brain irradiation, hydrocephalus is usually a long-term complication, occurring several months after completion of therapy [4–6]. Fibrosis of arachnoid granulations inhibiting CSF reabsorption is proposed as a mechanism of radiation-induced hydrocephalus [6].

In view of the limited prognosis and long-term sequelae, subsequent trials should emphasise the pathogenesis and aetiology of non-resorptive hydrocephalus after CNS prophylaxis in ALL patients.

References

1. Gökbuget N, Hoelzer D (1998) Meningeosis leukaemica in adult acute lymphoblastic leukaemia. J Neurooncol 38(2–3):167–180
2. Jabbour E, O'Brien S, Kantarjian H, Garcia-Manero G, Ferrajoli A, Ravandi F, Cabanillas M, Thomas DA (2007) Neurologic complications associated with intrathecal liposomal cytarabine given prophylactically in combination with high-dose methotrexate and cytarabine to patients with acute lymphocytic leukaemia. Blood 109(8):3214–3218
3. Watterson J, Toogood I, Nieder M, Morse M, Frierdich S, Lee Y, Moertel CL, Priest JR (1994) Excessive spinal cord toxicity from intensive central nervous system-directed therapies. Cancer 74 (11):3034–3041
4. Tekkök IH, Carter DA, Robinson MG, Brinker R (1996) Reversal of CNS-prophylaxis-related leukoencephalopathy after CSF shunting: case histories of identical twins. Childs Nerv Syst 12(6):309–314
5. Thiessen B, DeAngelis LM (1998) Hydrocephalus in radiation leukoencephalopathy: results of ventriculoperitoneal shunting. Arch Neurol 55(5):705–710
6. Perrini P, Scollato A, Cioffi F, Mouchaty H, Conti R, Di Lorenzo N (2002) Radiation leukoencephalopathy associated with moderate hydrocephalus: intracranial pressure monitoring and results of ventriculoperitoneal shunting. Neurol Sci 23(5):237–241