



HAL
open science

Cutaneous involvement in multiple myeloma and bortezomib

A. Siniscalchi, S. Fratoni, G. Santeusanio, G. Poeta, P. Fabritiis, T. Caravita

► **To cite this version:**

A. Siniscalchi, S. Fratoni, G. Santeusanio, G. Poeta, P. Fabritiis, et al.. Cutaneous involvement in multiple myeloma and bortezomib. *Annals of Hematology*, 2009, 88 (11), pp.1137-1139. 10.1007/s00277-009-0717-7 . hal-00535041

HAL Id: hal-00535041

<https://hal.science/hal-00535041>

Submitted on 11 Nov 2010

HAL is a multi-disciplinary open access archive for the deposit and dissemination of scientific research documents, whether they are published or not. The documents may come from teaching and research institutions in France or abroad, or from public or private research centers.

L'archive ouverte pluridisciplinaire **HAL**, est destinée au dépôt et à la diffusion de documents scientifiques de niveau recherche, publiés ou non, émanant des établissements d'enseignement et de recherche français ou étrangers, des laboratoires publics ou privés.

Cutaneous involvement in multiple myeloma and bortezomib

A. Siniscalchi · S. Fratoni · G. Santeusanio ·
G. Del Poeta · P. de Fabritiis · T. Caravita

Received: 9 May 2008 / Accepted: 18 February 2009 / Published online: 4 March 2009
© Springer-Verlag 2009

Dear Editor,

Cutaneous involvement in multiple myeloma (MM) is uncommon. Generally, it occurs in the late stage of the disease and is considered a sign of poor prognosis. Its pathogenesis is not entirely clear. Changes in adhesion molecule expression, especially with regard to CD138 and CD56 antigens, could contribute to different plasma cell migration and homing [1]; therefore, a possible association between the malignant plasma cell immunophenotype and skin infiltration is debated. We report a case of skin lesions from an IgA MM patient who was successfully treated with bortezomib and dexamethasone.

On October 2004, a 69-year-old woman was admitted to our centre for a recent and fortuitous finding of a serum monoclonal protein. Laboratory and radiological tests showed the following data:

- IgA kappa (4.8 g/dl) monoclonal protein
- Urinary Bence-Jones protein positivity (kappa light chain=1 g/24 h)

- Clonal plasmacytosis (5%) both in bone marrow aspirate and trephine
- No lytic bone lesions
- A retromediastinal mass (3 cm in diameter) diagnosed as an extramedullary plasmacytoma
- Immunophenotype: CD38+, CD56+, CD138+, CD45–, CD19–, CD117+

A diagnosis of MM IgA kappa stage IIA, according to Durie and Salmon classification, was made. The patient received six monthly cycles of the melphalan, prednisone and thalidomide regimen [2], which resulted in a clinical complete response (CR) [3]. Therefore, she received a daily dose (100 mg) of thalidomide as maintenance therapy. On January 2006, this therapy was reduced (50 mg/day) for neurological toxicity (paresthesia grade 2 World Health Organisation) and, on June 2006, was interrupted for a Sjogren-like syndrome with an ocular dryness unresponsive to treatment.

On September 2006, the patient observed the growth of a nodular non-pruriginous skin lesion of up to 0.5 cm in diameter on her back. A biopsy revealed the infiltration of superficial and deep dermis with uniform plasmacytoid cells strongly positive for CD79a, CD138 antigens, presenting a kappa light chain restriction (Fig. 1).

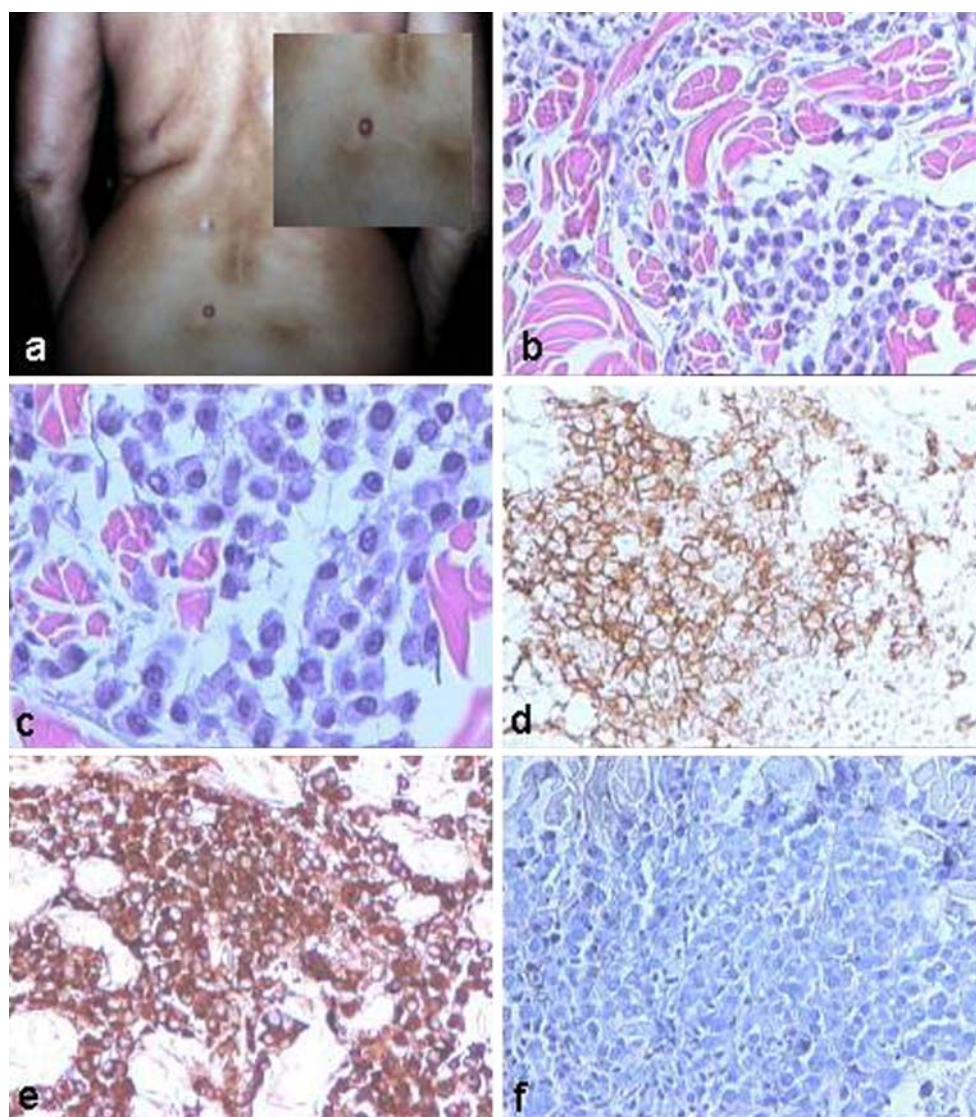
Restaging of the disease showed no evidence of monoclonal protein and normal serum immunoglobulin levels. Bone marrow aspirate and trephine revealed a normal cellular pattern with no morphological or immunophenotypic evidence of MM. Bone skeletal X-rays were negative. There were no other systemic signs of MM underlying the skin lesion. During the restaging, four new nodular lesions appeared in the same place of the first. Because of the older age and the previous treatment, the patient underwent a therapy including bortezomib (1.3 mg/m² on days 1, 4, 8, 11)

A. Siniscalchi · G. Del Poeta · P. de Fabritiis · T. Caravita
Department of Haematology, S. Eugenio Hospital,
Tor Vergata University,
Rome, Italy

S. Fratoni · G. Santeusanio
Department of Pathology, S. Eugenio Hospital,
Tor Vergata University,
Rome, Italy

A. Siniscalchi (✉)
Divisione di Ematologia, Ospedale S. Eugenio,
Università Tor Vergata,
P. le Umanesimo, 10,
00144 Rome, Italy
e-mail: s.agostina@libero.it

Fig. 1 Cutaneous lesions and morphological/immunohistochemical findings. Nodular, erythematous and non-pruriginous skin lesions were found on the patient's back before starting the therapy with bortezomib (a). Cutaneous biopsy showed a diffuse interstitial infiltrate by neoplastic plasma cells. Several large clusters of small and atypical plasma cells stained with haematoxylin–eosin were detected among dermal collagen fibres (b, c). Neoplastic plasma cells are highlighted by immunostaining with CD138 antibody (d) and showed clonal restriction for kappa Ig light chain antibody (e). Immunohistochemical staining for lambda light chain antibody was negative (f)



and dexamethasone (20 mg on days 1–4) every 21 days for four cycles. During the third and fourth cycle, bortezomib dosage was reduced to 25% and 50%, respectively, because of peripheral neuropathy (pain and paresthesias grade 3 National Cancer Institute). No other toxicity was observed. After two cycles, the cutaneous lesions disappeared. No maintenance therapy was performed. After 2 years, the patient remains in haematological and cutaneous CR. In this report, we describe a case of cutaneous plasma cell lesions in a patient previously treated with thalidomide. Avigdor et al. report another case of resistant MM treated with thalidomide that developed cutaneous plasmacytoma in the absence of systemic signs of disease and suggest a possible correlation between the biological modifications induced by thalidomide and an unusual more aggressive course of the disease [4].

The treatment of cutaneous plasmacytoma is still controversial. Bortezomib is a potent and selective proteasome inhibitor recently introduced in the treatment

of patients with relapsed/refractory MM. A significant activity of bortezomib in soft tissue plasmacytoma is reported [5], but there are no experiences in cutaneous plasmacytoma. In conclusion, bortezomib, in our case, revealed to be effective and manageable in the treatment of skin lesions from MM, suggesting its possible employment in cutaneous plasmacytoma.

References

- Alexandrescu DT, Koulova L, Wiernik PH (2005) Unusual cutaneous involvement during plasma cell leukemia phase in a multiple myeloma patient after treatment with thalidomide: a case report and a review of the literature. *Clin Exp Dermatol* 30:391–394. doi:10.1111/j.1365-2230.2005.01788.x
- Palumbo A, Bringhen S, Caravita T, Merla E, Capparella V, Callea V, Cangialosi C, Grasso M, Rossini F, Galli M, Catalano L, Zamagni E, Petrucci MT, De Stefano V, Ceccarelli M, Ambrosini MT, Avonto I,

- Falco P, Ciccone G, Liberati AM, Musto P, Boccadoro M, Italian Multiple Myeloma Network, GIMEMA (2006) Oral melphalan and prednisone chemotherapy plus thalidomide compared with melphalan and prednisone alone in elderly patients with multiple myeloma: randomised controlled trial. *Lancet* 367:825–831. doi:[10.1016/S0140-6736\(06\)68338-4](https://doi.org/10.1016/S0140-6736(06)68338-4)
3. Blade J, Samson D, Reece D, Apperley J, Bjorkstrand B, Gahrton G, Gertz M, Giralt S, Jagannath S, Vesole D (1998) Criteria for evaluating disease response and progression in patients with multiple myeloma treated by high-dose therapy and haemopoietic stem cell transplantation. *Br J Haematol* 102:1115–1123. doi:[10.1046/j.1365-2141.1998.00930.x](https://doi.org/10.1046/j.1365-2141.1998.00930.x)
 4. Avigdor A, Raanani P, Levi I, Hardan I, Ben-Bassat I (2001) Extramedullary progression despite a good response in the bone marrow in patients treated with thalidomide for multiple myeloma. *Leuk Lymphoma* 42:683–687. doi:[10.3109/10428190109099330](https://doi.org/10.3109/10428190109099330)
 5. Laura R, Cibeira MT, Uriburu C, Yantorno S, Salamero O, Blade J, Montserrat E (2006) Bortezomib: an effective agent in extramedullary disease in multiple myeloma. *Eur J Haematol* 76:405–408. doi:[10.1111/j.0902-4441.2005.t01-1-EJH2462.x](https://doi.org/10.1111/j.0902-4441.2005.t01-1-EJH2462.x)