



HAL
open science

Avian Mycobacteriosis in Companion Birds: 20-Year Survey

Giovanni Manarolla, Emmanouil Liandris, Giuliano Pisoni, Davide Sasserà,
Veterinary Biotechnology, Guido Grilli, Animal Science, Daniele Gallazzi,
Giuseppe Sironi, Paolo Moroni, et al.

► **To cite this version:**

Giovanni Manarolla, Emmanouil Liandris, Giuliano Pisoni, Davide Sasserà, Veterinary Biotechnology, et al..
Avian Mycobacteriosis in Companion Birds: 20-Year Survey. *Veterinary Microbiology*, 2009, 133 (4), pp.323.
<10.1016/j.vetmic.2008.07.017>. <hal-00532457>

HAL Id: hal-00532457

<https://hal.science/hal-00532457v1>

Submitted on 4 Nov 2010

HAL is a multi-disciplinary open access archive for the deposit and dissemination of scientific research documents, whether they are published or not. The documents may come from teaching and research institutions in France or abroad, or from public or private research centers.

L'archive ouverte pluridisciplinaire **HAL**, est destinée au dépôt et à la diffusion de documents scientifiques de niveau recherche, publiés ou non, émanant des établissements d'enseignement et de recherche français ou étrangers, des laboratoires publics ou privés.



HAL Authorization

Accepted Manuscript

Title: Avian Mycobacteriosis in Companion Birds: 20-Year Survey

Authors: Giovanni Manarolla, Emmanouil Liandris, Giuliano Pisoni, Davide Sasseria, Veterinary Biotechnology, Guido Grilli, Animal Science, Daniele Gallazzi, Giuseppe Sironi, Paolo Moroni, Renata Piccinini, Animal Science, Tiziana Rampin



PII: S0378-1135(08)00288-5
DOI: doi:10.1016/j.vetmic.2008.07.017
Reference: VETMIC 4105

To appear in: *VETMIC*

Received date: 22-1-2008
Revised date: 12-6-2008
Accepted date: 16-7-2008

Please cite this article as: Manarolla, G., Liandris, E., Pisoni, G., Sasseria, D., Biotechnology, V., Grilli, G., Science, A., Gallazzi, D., Sironi, G., Moroni, P., Piccinini, R., Science, A., Rampin, T., Avian Mycobacteriosis in Companion Birds: 20-Year Survey, *Veterinary Microbiology* (2007), doi:10.1016/j.vetmic.2008.07.017

This is a PDF file of an unedited manuscript that has been accepted for publication. As a service to our customers we are providing this early version of the manuscript. The manuscript will undergo copyediting, typesetting, and review of the resulting proof before it is published in its final form. Please note that during the production process errors may be discovered which could affect the content, and all legal disclaimers that apply to the journal pertain.

1 **Avian Mycobacteriosis in Companion Birds: 20-Year Survey**

2 Giovanni Manarolla,* DVM, PhD, Emmanouil Liandris,† DVM, PhD, Giuliano
3 Pisoni,* DVM, PhD, Davide Sassera,* MS Veterinary Biotechnology, PhD, Guido
4 Grilli,* MS Animal Science, PhD, Daniele Gallazzi,* DVM, Giuseppe Sironi,* DVM,
5 PhD, Paolo Moroni,* DVM, PhD, Renata Piccinini,* MS Animal Science, Tiziana
6 Rampin,* DVM

7
8 * Università degli Studi di Milano, Dipartimento di Patologia Animale, Igiene e
9 Sanità Pubblica Veterinaria, via Caloria 10, 20133 Milano, Italy

10 † Agricultural University of Athens (Greece), Department of Anatomy -
11 Physiology

12 Iera Odos 75, Athens 118 55, Greece

13
14 corresponding author: phone number 0039 02 50318104 Fax number 0039 02
15 50318106 email address: giovanni.manarolla@unimi.it

1 **Abstract**

2 The causative agents of avian mycobacteriosis in pet birds are rarely identified. The aim
3 of this study is to add information about the etiology of avian mycobacteriosis. The
4 identification of mycobacterium species in 27 cases of avian mycobacteriosis in pet
5 birds was investigated by Polymerase Chain Reaction and sequencing of a rRNA
6 hypervariable region. Avian mycobacteriosis appeared to be an infrequent diagnosis.
7 Interestingly, a few cases of avian mycobacteriosis were recorded in very young birds.
8 The most commonly affected species were the canary (*Serinus canarius*), the Eurasian
9 goldfinch (*Carduelis carduelis*) and the Red Siskin (*Spinus cucullatus*). All but one bird
10 were infected with *Mycobacterium genavense*. *Mycobacterium avium* was identified
11 only in one case.

1 **Keywords**

2 Mycobacteria

3 Birds

4 Avian mycobacteriosis

5 *Mycobacterium genavense*

6 PCR

Accepted Manuscript

1 **Introduction**

2 The causative agents of Avian Mycobacteriosis (AM) in pet birds are rarely
3 identified for lack of specific post mortem findings and for the difficulty in isolating
4 some mycobacterial species, usually referred to as non-culturable mycobacteria (Hoop
5 et al., 1996; Tell et al., 2003). Until a decade ago, most cases of AM were assumed to
6 be caused by *Mycobacterium avium-intracellulare* complex (MAI). More recently, the
7 use of molecular techniques for species identification brought to light the prominent
8 role of non culturable mycobacteria, primarily *Mycobacterium genavense* (MG), in
9 several cases of AM in pet birds (Tell et al., 2001). MG is a fastidious organism
10 classified as a non-pigmented, slow-growing mycobacterium (Runyon, 1959; Tortoli,
11 2003), first identified in a human patient with Acquired Immune Deficiency Syndrome
12 (AIDS) (Bottger, 1990; Bottger et al., 1992). This species has since been proven to be
13 pathogenic for numerous avian species (Hoop et al., 1993; Portaels et al., 1996; Hoop et
14 al., 1996; Holsboer Buogo et al., 1997; Manarolla et al., 2007) and a few mammalian
15 species as well (Kiehn et al., 1996; Steiger et al., 2003; Ludwig et al., 2007). The origin
16 of such infection in humans and animals remains obscure (Portaels et al., 1996). MG in
17 pet birds causes a disseminated disease with clinical and histopathological features
18 indistinguishable from AM caused by members of the MAI complex (Portaels et al.,
19 1996; Ramis et al., 1996; Schmidt et al., 2003). The route of infection depends on the
20 mycobacterial species. MAI appear to be ubiquitous in the environment, and they are
21 usually contracted by ingestion. As for MG, the frequent involvement of the gastro-
22 intestinal tract suggests an oral route of infection (Schmidt et al., 2003), though the
23 extensive invasion of the lungs reported in many cases suggest a possible airborne
24 source (Portaels et al., 1996; Manarolla et al., 2007).

1 The aim of this study was to determine retrospectively, via Polymerase Chain
2 Reaction (PCR) and sequencing, the mycobacterial species involved in AM cases
3 diagnosed in pet birds in our laboratory over an extended period of time.

4 **Materials and Methods**

5 **Case Selection:** Cases were accessed from January 1987 to September 2007. Of
6 1,961 cases, avian mycobacteriosis was diagnosed in 27 pet birds of varying species
7 from northern Italy. Specimens were presented as intact corpses for necropsy, or as
8 formalin-fixed tissues for histopathology. In all the cases in this study, the diagnosis
9 was based on microscopic findings suggestive of AM and confirmed by Ziehl-Neelsen
10 stain. The year of submission, the species and the affected organs are listed in Table 1.

11 Polymerase chain reaction and sequencing

12 **DNA extraction**

13 DNA was extracted from formalin-fixed, paraffin-embedded tissues. Three 5- μ m
14 sections from each of the sampled organs were collected in sterile 1.5 mL tubes and
15 dewaxed in 1 mL xylene (VWR BDH Prolabo, Milan, Italy) for 20 min, centrifuged at
16 1000 \times g for 3 min and washed twice with 100% ethanol (Merck KGaA, Darmstadt,
17 Germany). DNA was then extracted from the pellet using a DNA minikit (Qiagen,
18 Hilden, Germany) according to the manufacturer's instructions.

19 **PCR**

20 The identification of the mycobacterial species was based on the amplification
21 and sequence analysis of a hypervariable region of the 16S rRNA gene. For this
22 purpose, a semi-nested PCR was used. Primers used in the first round PCR were 246
23 (5'-AGAGTTTGATCCTGGCTCAG-3'; nucleotides 8 to 28 of the 16S rRNA gene of
24 *Escherichia coli*) and 247 (5'-TTTCACGAACAACGCGACAA-3'; nucleotide positions

1 609 to 590 of the *E. coli* 16S rRNA gene) (Hughes et al., 2000). For the second round
2 PCR primers used were p7 (5'-CATGCAAGTCGAACGGAA-3'; nucleotide positions
3 54 to 71 of the *E. coli* 16S rRNA gene) (Dumonceau et al., 1995) and 247.
4 Amplifications were carried out in 50 μ L PCR buffer (Eppendorf, Hamburg, Germany)
5 containing 1.5 mM MgCl₂, 20 pmol each primer, 200 μ M each dNTP and 1.25 U Taq
6 polymerase (Eppendorf). Incubation conditions for the first reaction consisted of an
7 initial incubation at 95°C for 3 min, followed by 35 cycles each of 95°C for 35 sec,
8 64°C for 30 sec and 72°C for 40 sec, then a final incubation at 72°C for 8 min.
9 Incubation conditions for the nested reaction consisted of an initial cycle of incubation
10 at 95°C for 3 min, followed by 30 cycles each of 95°C for 35 sec, 61°C for 35 sec and
11 72°C for 40 sec, then a final incubation at 72°C for 8 min. A 5 μ l sample of the PCR
12 products was electrophoresed in 2% agarose (Promega, Milan, Italy) and stained with
13 ethidium bromide (Euroclone, Milan, Italy). Negative controls consisting of the PCR
14 master mixture without genomic DNA and with DNA extracted from negative tissues
15 were included in all PCR amplifications.

16 **Sequencing and sequence analysis**

17 PCR products of the expected length (555bp) were purified from agarose gel
18 slices using a QIAquick PCR purification kit (Qiagen) and sequenced using an ABI
19 Prism 310 genetic analyser (Applied Biosystems, Foster City, California, USA). The
20 sequences were submitted to the GenBank database. The percentage of similarity with
21 reference sequences was evaluated by BLAST search in the NCBI website. The
22 accession numbers are listed in Table 1.

23 **Results**

1 The results are listed in Table 1. The birds enrolled in the survey were all pet
2 birds from northern Italy and belonged to 8 different avian species divided as follows: 9
3 canaries (*Serinus canarius*) (33.3%), 6 Eurasian goldfinches (*Carduelis carduelis*)
4 (22.2%), 5 red siskins (*Spinus cucullatus*) (18.5%), 2 Amazona albifrons (7%), 1
5 Amazona farinosa, 1 greenfinch (*Carduelis chloris*), 1 Neophema sp, 1 kakariki
6 (*Cyanoramphus novaezelandiae*), 1 hybrid *Carduelis carduelis* x *Serinus canarius* and 1
7 zebra finch (*Taenopygia guttata*) (3.7% each). Sixteen birds were from different
8 owners, whereas the other 11 belonged to 3 particular owners as indicated in Table 1. In
9 8 cases, the age of the bird was not available; 13 birds were adults older than 1 year and
10 6 birds were younger than 1 year. In 16 cases (59.3%), there was involvement of the
11 gastrointestinal tract. The respiratory tract was affected in 10 cases (37%). Two cases of
12 skin lesions were also included.

13 Twenty-six cases (92.9%) showed non-tubercloid lesions characterized by focal
14 or extensive sheets of mycobacteria-laden macrophages infiltrating the parenchyma of
15 different organs with variable amounts of necrosis and scattered accumulation of
16 lymphoid cells and heterophils. In these cases, the intracellular acid fast organisms was
17 particularly abundant (Figure 1). Case 2 and case 5 were characterized by typical
18 granulomas with a central necrotic area and a scarcity of mycobacteria surrounded by
19 macrophages and multinucleated giant cells. In cases 4 and 13, PCR did not amplify the
20 hypervariable region of the 16S rRNA gene. PCR and sequencing revealed that 23 cases
21 of AM were caused by MG and 1 case by *Mycobacterium avium*. The percentage of
22 similarity ranged from 99.4% to 100%. In case 7, sequencing of the PCR product gave
23 questionable results and was discarded.

24 **Discussion**

1 Between January 1987 and September 2007, AM was diagnosed histologically
2 in 27 of 1,961 pet birds (1.4%). This low number probably underestimates the actual
3 cases, since histological examination of dead birds for evident post mortal changes was
4 not frequently performed.

5 Moreover, some cases might have been overlooked for lack of gross lesions
6 suggestive of AM. Eight different avian species were represented in the survey, albeit
7 most cases were observed in canaries, Eurasian goldfinches and red siskins.
8 Identification of mycobacterial species by molecular techniques was unsuccessful in the
9 2 cases that yielded no amplification of the hypervariable region of the 16S rRNA gene.
10 As DNA extraction and PCR was repeated twice for these 2 cases, this result can
11 probably be attributed either to scarce quantity of mycobacterial DNA available in
12 paraffin-embedded tissues or to severe DNA damage sustained during processing
13 (Srinivasan et al., 2002).

14 MG was identified in 23 of 24 cases (95.8%), making it the most prevalent
15 mycobacterial species in this survey. Similar data have been previously observed in pet
16 and aviary birds (Portaels et al., 1996; Hoop et al., 1996; Holsboer Buogo et al., 1997).
17 MG was almost exclusively associated with the non-tuberculoid form of AM and our
18 results sustain that the tuberculoid form is rarely observed in AM of pet birds (Schmidt
19 et al., 2003). We observed typical granulomatous lesions only in cases 2 and 5. In both
20 cases, the granulomas affected the periocular region of two parrots. This lesion site has
21 been previously described in numerous avian species affected by AM (Tell et al., 2001).

22 It is worth noting that case 1 dated to 1989. This result revealed MG had
23 infected an avian host one year before its first identification in a human AIDS patient
24 (Bottger, 1990; Bottger et al., 1992). It is particularly noteworthy that MG was

1 identified in more birds from the same owners (Table 1). Although previous reports
2 supported a limited contagiousness of MG (Hoop et al., 1993; Manarolla et al., 2007), in
3 these cases we cannot exclude an animal-to-animal spread of the infection among
4 several birds kept in close contact.

5 *Mycobacterium avium* was identified only in case 20. This result sustains
6 previous European reports where this mycobacterial species is referred to as not
7 predominant in AM of pet birds (Portaels et al., 1996; Hoop et al., 1996; Holsboer
8 Buogo et al., 1997). On the contrary, *Mycobacterium avium* and *Mycobacterium*
9 *intracellulare* are commonly identified in aviaries at zoos (Schrenzel et al., 2008).
10 Further studies seem necessary to find out whether regional differences in speciation
11 exist.

12 Histological appearance of the lesions in this case overlapped the pathological
13 features found in most MG infections as previously reported (Hoop et al., 1993; Portaels
14 et al., 1996; Manarolla et al., 2007). In 10 cases (37%) there was involvement of the
15 respiratory tract. Given that the lung is an uncommon site for mycobacterial lesions in
16 birds, this finding was already observed in previous reports (Portaels et al., 1996;
17 Manarolla et al., 2007) and suggests that an airborne source of infection must be
18 considered in AM of pet birds. We can speculate that the routine cleaning procedures of
19 the cages where AM-infected birds live could aerosolise mycobacteria from infected
20 feces, which remain the principal source of shedding and infection for other birds (Tell
21 et al., 2001). Interestingly, 6 of the 19 birds of known age (31.6%) were younger than 1
22 year. This result confirms that, although AM is more frequently observed in adult birds
23 as a consequence of the chronic nature of the disease, it must be considered as a
24 possible diagnosis in juvenile birds that have died without specific findings. A vertical

1 route of transmission cannot be excluded, though it is believed to be unlikely (Tell et
2 al., 2001). Molecular identification is the most accurate approach for making an
3 etiological diagnosis because these micro-organisms are difficult to isolate.
4 Unfortunately, application of this technique to paraffin-embedded material in
5 retrospective studies can be unsuccessful.

6 The results of this survey suggest MG must be suspected over other
7 mycobacterial species as a possible culprit in cases of AM diagnosed histologically in
8 companion birds. The origin of such infections could not be identified, and it is also
9 uncertain whether immunosuppression plays a role in AM as it does in the human
10 counterpart. The environment is considered the natural reservoir of non tuberculous
11 mycobacteria (Bottger, 1994; Tortoli, 2004; Schrenzel et al., 2007). Nevertheless, it has
12 been hypothesized the birds to be the only identified potential reservoir for MG (Tortoli,
13 2003), and, though limited, the results of this survey sustain this hypothesis.
14 Consequently, further studies aimed at clarifying the epidemiological mechanisms that
15 MG uses to infect companion birds seem necessary.

16 MG is pathogenic for people immunocompromised by either HIV or by
17 iatrogenic immuno-suppression (Boian et al., 1997; Tortoli, 2004). AM is unlikely to
18 represent a significant risk for healthy humans. However, the potential for zoonotic
19 disease must be considered, especially if persons who are immunocompromised are in
20 contact with an infected bird (Bottger, 1994; Boian et al., 1997; Lennox, 2007)
21 Unfortunately, no data about the health status of the bird owners were available for this
22 survey; however, it might be investigated whether the anamnestic data of human
23 patients with MG infections include previous contact with companion birds.

1 **Acknowledgments**

2 This work was supported by grants from Regione Lombardia (Italy).

3 We thank Dr Enrico Tortoli for providing a *Mycobacterium genavense* strain
4 used as a positive control for PCR. The linguistic help of Dr Paul Boettcher was
5 highly appreciated.

Accepted Manuscript

1 **References**

- 2 1. Boian, M., Avaniss-Aghajani, E., Walker, R., Aronson, T., Tran, T., Glover, N.,
3 Berlin, O.G.W., Woods, L., Brunk, C., Li, J.L., Froman, S., Holtzman, A., 1997.
4 Identification of *Mycobacterium genavense* in intestinal tissue from a parakeet
5 using two polymerase chain reaction methods: Are pets a reservoir of infection
6 in AIDS patients? (Letter). *AIDS*.11, 255–226.
- 7 2. Bottger, E.C., 1990. Infection with a novel, unidentified mycobacterium. *N.*
8 *Engl. J. Med.* 323, 109-113.
- 9 3. Bottger, E.C., Teske, A., Kirschner, P., Bost, S., Chang, H.R., Beer, V.,
10 Hirschel, B., 1992. Disseminated "*Mycobacterium genavense*" infection in
11 patients with AIDS. *Lancet*. 340, 76-80.
- 12 4. Bottger, E.C., 1994. *Mycobacterium genavense*: an emerging pathogen. *Eur. J.*
13 *Clin. Microbiol. Infect. Dis.*13, 932-936.
- 14 5. Dumonceau, J. M., Fonteyne, P. A., Realini, L., van Gossum, A., van vVoren, J.
15 P., Portaels F., 1995. Species-specific *Mycobacterium genavense* DNA in
16 intestinal tissues of individuals not infected with Human Immunodeficiency
17 Virus. *J. Clin* 33, 2514-2515.
- 18 6. Holsboer Buogo, C., Bacciarini, L., Robert, N., Bodmer, T., Nicolet, T., 1997.
19 Vorkommen von *Mycobacterium genavense* bei Vögeln. *Schweiz. Arch.*
20 *Tierheilkd.* 139, 397-402.
- 21 7. Hoop, R.K., Bottger, E.C., Ossent, P., Salfinger, M., 1993. Mycobacteriosis Due
22 to *Mycobacterium genavense* in Six Pet Birds. *J. Clin. Microbiol.* 31, 990-993.

- 1 8. Hoop, R.K., Bottger, E., Pfyffer, G.E., 1996. Etiological agents of
2 mycobacterioses in pet birds between 1986 and 1995. *J. Clin. Microbiol.* 34,
3 991-992.
- 4 9. Hughes M. M. James G., Ball N., Scally M., Malik, R. Wigney D. I., Martin P.,
5 Chen S., Mitchell D., Love D. N., 2000. Identification by 16S rRNA gene
6 analyses of a potential novel Mycobacterial species as an etiological agent of
7 canine leproid granuloma syndrome. *J. clin. Microbiol.* 38, 953-959.
- 8 10. Kiehn, T.E., Hoefler, H., Bottger, E.C., Ross, R., Wong, M., Edwards, F.,
9 Antinoff, N., Armstrong, D., 1996. *Mycobacterium genavense* infections in pet
10 animals. *J. Clin. Microbiol.* 34, 1840-1842.
- 11 11. Lennox A.M., 2007. Mycobacteriosis in companion psittacine birds: A review.
12 *Journal of Avian Medicine and Surgery.* 21, 181-187.
- 13 12. Ludwig, E., Reischl, U., Janik, D., Hermanns, W. Granulomatous pneumonia
14 caused by *Mycobacterium genavense* in a dwarf rabbit (*Oryctolagus cuniculus*).
15 In: abstract of the 25th Annual Meeting of The European Society of Veterinary
16 Pathology , Munich, Germany; 2007 Aug 28th-Sept 1st; p.138. Munich,
17 Germany: The European Society of Veterinary Pathology.
- 18 13. Manarolla, G., Liandris, E., Pisoni, G., Moroni, P., Piccinini, R., Rampin, T.,
19 2007. *Mycobacterium genavense* and avian polyomavirus co-infection in a
20 European goldfinch (*Carduelis carduelis*). *Avian Pathol.* 36, 423-426.
- 21 14. Portaels, F., Realini, L., Bauwens, L., Hirschel, B., Meyers, W.M., de Meurichy,
22 W.,1996. Mycobacteriosis caused by *Mycobacterium genavense* in birds kept in
23 a zoo: 11-year survey. *J. Clin. Microbiol.* 34, 319-323.

- 1 15. Ramis., A., Ferrer, L., Aranaz, A., Liebana, E., Mateos, A., Dominguez, L.,
2 Pascual, C., Fdez-Garayazabal, J., Collins, M.D., 1996. *Mycobacterium*
3 *genavense* infection in canaries. Avian Dis. 40, 246-251.
- 4 16. Runyon, E.H., 1959. Anonymous mycobacteria in pulmonary disease. Med.
5 Clin. North Am. 43, 273-290.
- 6 17. Schmidt, R.E., Reavill, D.R., Phalen, D.N., 2003. Liver. In: Pathology of Pet
7 and Aviary Birds: Ames: Iowa State Press, pp. 70-77.
- 8 18. Schrenzel, M., Nicolas, M., Witte, C., Papendick, R., Tucker, T., Keener, L.,
9 Sutherland-Smith, M., Lamberski, N., Orndorff, D., Heckard, D., Witman, P.,
10 Mace, M., Rimlinger, D., Reed, S., Rideout, B., 2008. Molecular epidemiology
11 of *Mycobacterium avium* subsp. *avium* and *Mycobacterium intracellulare* in
12 captive birds. Vet. Microbiol. 126, 122-131.
- 13 19. Srinivasan, M., Sedmak, D., Jewell, S., 2002. Effect of Fixatives and Tissue
14 Processing on the Content and Integrity of Nucleic Acids. Am. J. Pathol. 161,
15 1961–1971.
- 16 20. Steiger, K., Ellenberger, C., Schüppel, K.F., Richter, E., Schmerbach, K.,
17 Krautwald-Junghanns, M.E., Wünnemann, K., Eulenberger, K., Schoon, H.A.,
18 2003. Ungewöhnliche Mykobakterien-Infektionen bei Haus- und Zootieren: eine
19 Kasuistik unter besonderer Berücksichtigung der Pathologie. Dtsch. Tierärztl.
20 Wochenschr. 110, 382-388
- 21 21. Tell, L.A., Woods, L., Cromie, R.L., 2001. Mycobacteriosis in birds. Rev. Sci.
22 Tech. Ser. Sci. Hum. (International Office of Epizootics). 20, 180-203.
- 23 22. Tell L.A., Foley J., Needham M.L., Walker R.L., 2003. Diagnosis of avian
24 mycobacteriosis: comparison of culture, acid-fast stains and polymerase chain

- 1 reaction for the identification of *Mycobacterium avium* in experimental
2 inoculated japanese quail (*Coturnix coturnix japonica*)." *Avian Dis.* 47, 444-452.
- 3 23. Tortoli, E., 2003. Impact of Genotypic Studies on Mycobacterial Taxonomy: the
4 New Mycobacteria of the 1990s. *Clin. Microbiol. Rev.*16, 319-354.
- 5 24. Tortoli, E., 2004. Clinical Features of Infections Caused by New
6 Nontuberculous Mycobacteria, Part I*. *Clin. Microbiol. Newsl.* 26, 89-95.

Accepted Manuscript

Table 1 – material and results of the survey

CASE	YEAR	AVIAN SPECIES	AGE	AFFECTED ORGANS	MYCOBACTERIAL SPECIES	% IDENTITY	SEQUENCE NUMBER
1	1989	<i>Spinus cucullatus</i>	n.a.	intestine	<i>M. genavense</i>	100%	EU742184
2	1993	<i>Amazona farinosa</i>	n.a.	eye (granuloma)	<i>M. genavense</i>	99.8%	EU742170
3	1994	<i>Serinus canarius</i>	1 year	spleen	<i>M. genavense</i>	100%	EU742179
4	1995	<i>Amazona albifrons</i>	adult	intestine	PCR negative	--	--
5	1995	<i>Neophema sp</i>	n.a.	eye (granuloma)	<i>M. genavense</i>	100%	EU742181
6	1996	<i>Spinus cucullatus</i> *	adult	intestine liver, spleen	<i>M. genavense</i>	100%	EU742185
7	1996	<i>Amazona albifrons</i>	n.a.	skin, duodenum	Unidentified bacterium	--	--
8	1996	<i>Serinus canarius</i>	n.a.	liver, spleen	<i>M. genavense</i>	100%	EU742172
9	2000	<i>Carduelis choris</i>	3 years	spleen, lung	<i>M. genavense</i>	100%	EU742174
10	2002	<i>Serinus canarius</i>	adult	lung	<i>M. genavense</i>	100%	EU742175
11	2003	<i>Spinus cucullatus</i> *	6 months	intestine	<i>M. genavense</i>	100%	EU742171
12	2003	<i>Serinus canarius</i> *	1 year	intestine	<i>M. genavense</i>	100%	EU742178
13	2004	<i>Spinus cucullatus</i> *	adult	intestine, liver, lung	PCR negative	--	--
14	2004	<i>Carduelis carduelis</i> §	n.a.	intestine, liver, gizzard, lung	<i>M. genavense</i>	99.4%	EU742189
15	2004	<i>Carduelis carduelis</i> § (color mutated)	n.a.	duodenum	<i>M. genavense</i>	100%	EU742183
16	2004	<i>Carduelis carduelis</i> §	3 years	intestine, spleen, liver	<i>M. genavense</i>	100%	EU742173
17	2004	<i>Carduelis carduelis</i> § (color mutated)	2 years	lung	<i>M. genavense</i>	100%	EU742180
18	2005	<i>Spinus cucullatus</i> *	n.a.	duodenum, liver	<i>M. genavense</i>	100%	EU742187
19	2005	<i>Carduelis carduelis</i>	8 years	lung, heart, cervical air sacs, aorta, adrenals, brain	<i>M. genavense</i>	99.8%	EU742176

20	2005	<i>Carduelis carduelis</i>	2 years	intestine, liver, spleen, lung	<i>M. avium</i>	100%	EU742166
21	2005	<i>Serinus canarius</i>	1.5 year	spleen	<i>M. genavense</i>	100%	EU742182
22	2005	Hybrid: <i>Carduelis carduelis</i> <i>x Serinus canarius</i>	1 year	intestine, liver, spleen, lung	<i>M. genavense</i>	100%	EU742177
23	2006	<i>Serinus canarius</i> [°]	adult	spleen	<i>M. genavense</i>	100%	EU742168
24	2007	<i>Serinus canarius</i> [°]	4 years	lung	<i>M. genavense</i>	100%	EU742188
25	2007	<i>Cyanoramphus novaezelandiae</i>	12 years	intestine, liver	<i>M. genavense</i>	100%	EU742167
26	2007	<i>Taeniopygia guttata</i>	1 year	gizzard, intestine, liver, spleen	<i>M. genavense</i>	100%	EU742169
27	2007	<i>Serinus canarius</i>	1 year	lung, air sacs	<i>M. genavense</i>	100%	EU742186

n.a. not available

§, *, ° identifying birds from a same owner

Figure 1

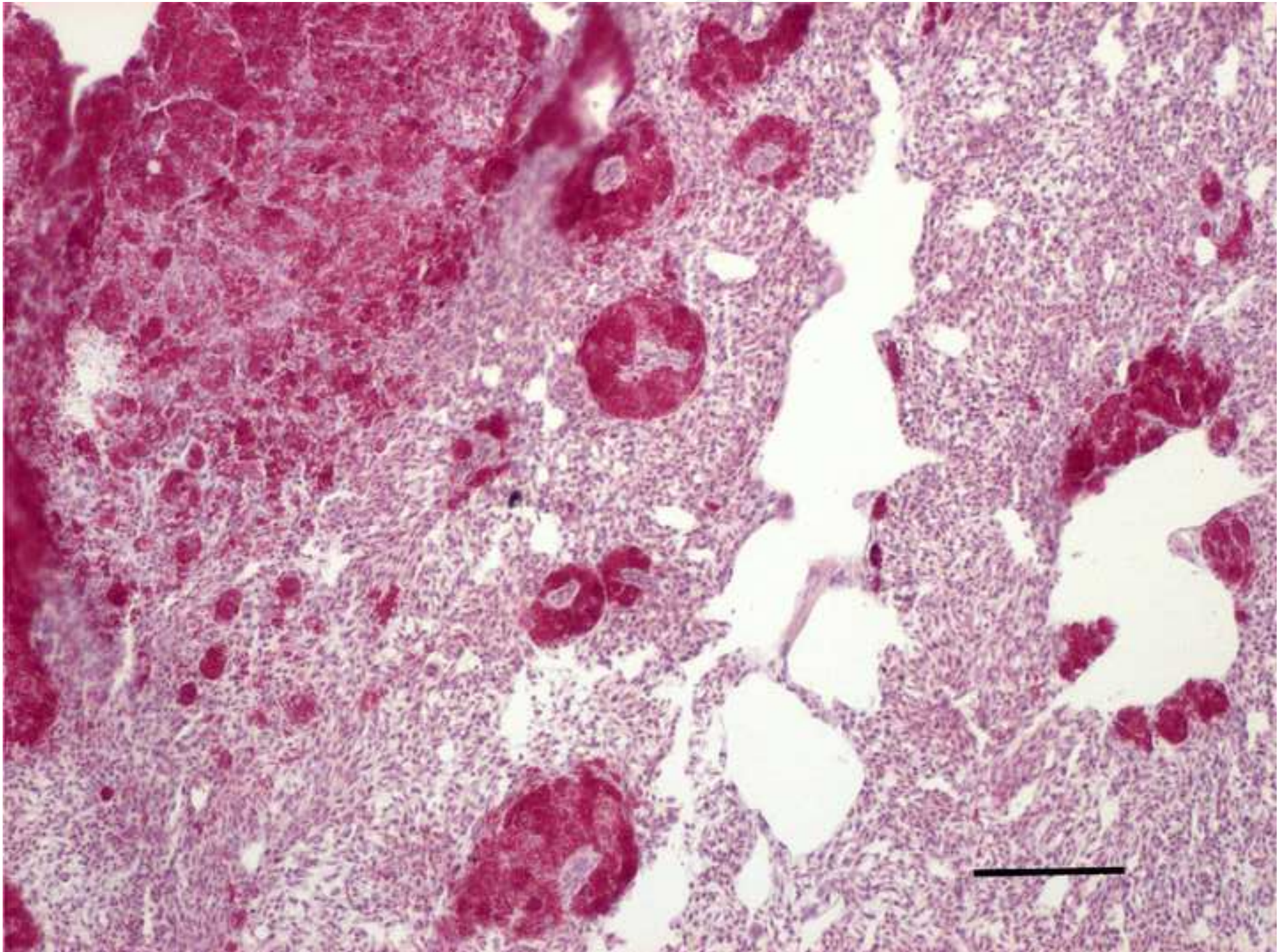


Figure 1 BW

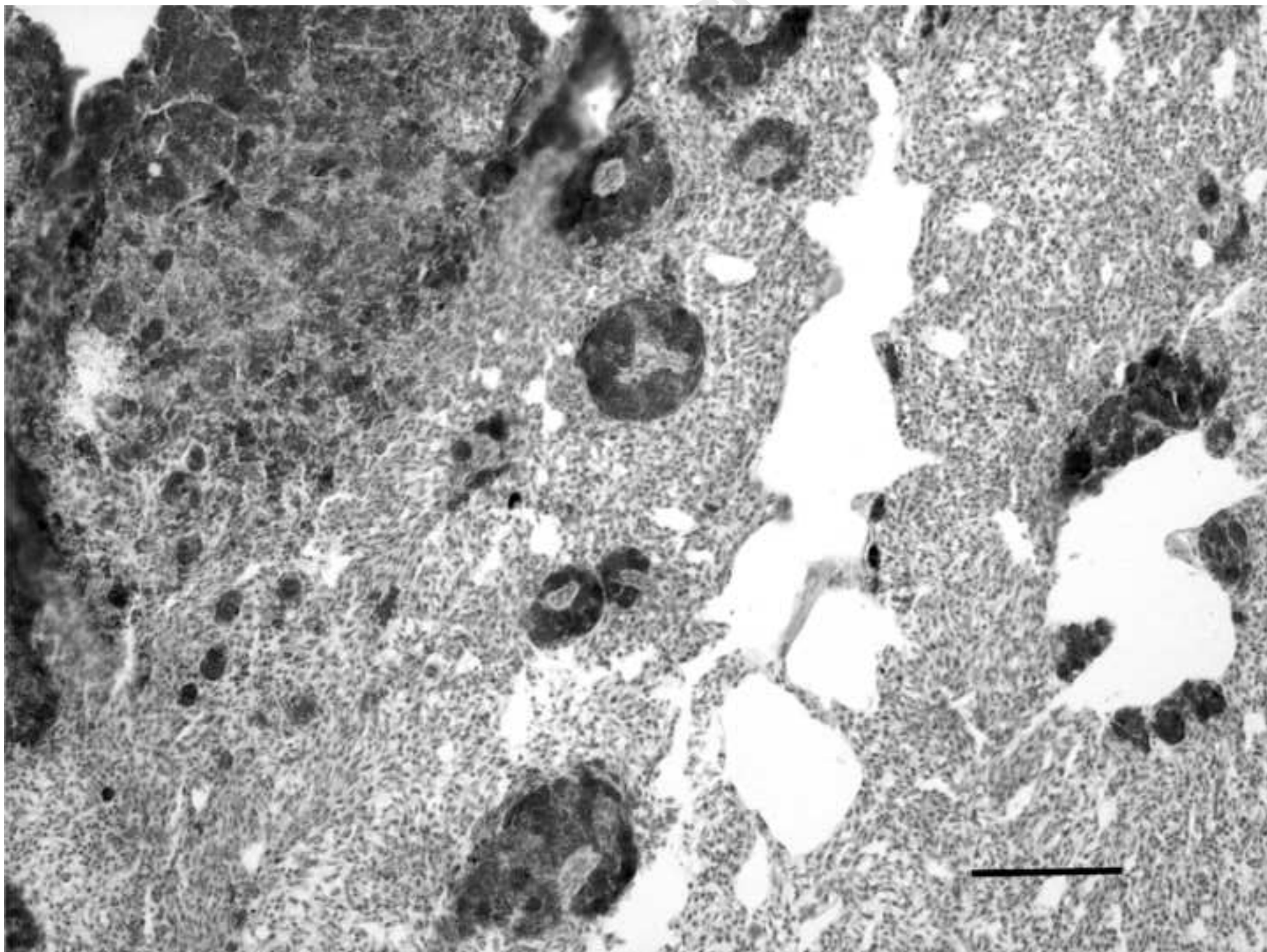


Figure 1. Section of lung of a European goldfinch showing multifocal lesions consisting of macrophagic aggregates with numerous intracytoplasmic acid fast bacilli. Ziehl-Neelsen stain. Bar = 150 μm .

Accepted Manuscript