



HAL
open science

West Nile virus in the endangered Spanish imperial eagle

Ursula Höfle, Juan M. Blanco, Elena Crespo, Victoria Naranjo, Miguel Angel Jiménez-Clavero, Azucena Sanchez, José de La Fuente, Christian Gortazar

► **To cite this version:**

Ursula Höfle, Juan M. Blanco, Elena Crespo, Victoria Naranjo, Miguel Angel Jiménez-Clavero, et al.. West Nile virus in the endangered Spanish imperial eagle. *Veterinary Microbiology*, 2008, 129 (1-2), pp.171. 10.1016/j.vetmic.2007.11.006 . hal-00532357

HAL Id: hal-00532357

<https://hal.science/hal-00532357>

Submitted on 4 Nov 2010

HAL is a multi-disciplinary open access archive for the deposit and dissemination of scientific research documents, whether they are published or not. The documents may come from teaching and research institutions in France or abroad, or from public or private research centers.

L'archive ouverte pluridisciplinaire **HAL**, est destinée au dépôt et à la diffusion de documents scientifiques de niveau recherche, publiés ou non, émanant des établissements d'enseignement et de recherche français ou étrangers, des laboratoires publics ou privés.

Accepted Manuscript

Title: West Nile virus in the endangered Spanish imperial eagle

Authors: Ursula Höfle, Juan M. Blanco, Elena Crespo, Victoria Naranjo, Miguel Angel Jiménez-Clavero, Azucena Sanchez, José de la Fuente, Christian Gortazar



PII: S0378-1135(07)00545-7
DOI: doi:10.1016/j.vetmic.2007.11.006
Reference: VETMIC 3881

To appear in: *VETMIC*

Received date: 13-7-2007
Revised date: 2-11-2007
Accepted date: 6-11-2007

Please cite this article as: Höfle, U., Blanco, J.M., Crespo, E., Naranjo, V., Jiménez-Clavero, M.A., Sanchez, A., de la Fuente, J., Gortazar, C., West Nile virus in the endangered Spanish imperial eagle, *Veterinary Microbiology* (2007), doi:10.1016/j.vetmic.2007.11.006

This is a PDF file of an unedited manuscript that has been accepted for publication. As a service to our customers we are providing this early version of the manuscript. The manuscript will undergo copyediting, typesetting, and review of the resulting proof before it is published in its final form. Please note that during the production process errors may be discovered which could affect the content, and all legal disclaimers that apply to the journal pertain.

1 **West Nile virus in the endangered Spanish imperial eagle**

2 Ursula Höfle ^{a,b}, Juan M. Blanco ^a, Elena Crespo ^a, Victoria Naranjo ^b, Miguel Angel

3 Jiménez-Clavero ^d, Azucena Sanchez ^c, José de la Fuente ^{b,e}, Christian Gortazar ^b

4

5 ^a Centro de Estudios de Rapaces Ibéricas CERI, 45671 Sevilleja de la Jara, Spain

6 ^b Instituto de Investigación en Recursos Cinegéticos IREC (CSIC-UCLM-JCCM),

7 Ronda de Toledo s/n, 13005 Ciudad Real, Spain

8 ^c Laboratorio Central de Veterinaria, Carretera de Algete km 8, 28110 Algete (Madrid),

9 Spain

10 ^d Centro de Investigación en Sanidad Animal CISA-INIA, Carretera Algete-El Casar

11 s/n, 28130 Valdeolmos (Madrid), Spain

12 ^e Department of Veterinary Pathobiology, Center for Veterinary Health Sciences,

13 Oklahoma State University, Stillwater, OK 74078, USA.

14 Corresponding author (and correspondence address):

15 Ursula Höfle, Instituto de Investigación en Recursos Cinegéticos IREC (CSIC-UCLM-

16 JCCM), Ronda de Toledo s/n, 13005 Ciudad Real, Spain. Tel.: 0034-926-295450, Fax:

17 0034-926-295451, e-mail: ursula.hoefle@hotmail.com and ursula.hofle@uclm.es

18

19

1 Abstract

2 The Spanish imperial eagle (*Aquila adalberti*) is considered the most endangered
3 European eagle. The species is an endemic resident in the Southwestern Iberian
4 Peninsula. We used RT-PCR, immunohistochemistry and seroneutralization to test
5 samples from 13 wild and 18 captive eagles. WNV was detected by RT-PCR in tissues
6 and/or oropharyngeal swabs of 8 of 10 (80%) imperial eagles analyzed, and both in
7 apparently clinically healthy birds, and in animals that died due to secondary infections
8 but had symptoms/lesions compatible with WNV. Immunohistochemistry detected
9 WNV antigen in Purkinje cells in the cerebellum, epithelial cells of the gizzard and
10 duodenum, perivascular inflammatory cells, and in Kupffer-cells and hepatocytes.
11 Serum antibodies against WNV were detected in a total of 5 out of 21 imperial eagles
12 (23.8 %), including free-living nestlings (2 out of 9 samples, 22.2%) and captive adult
13 eagles (3 out of 12 samples, 25%). Our results evidence WNV circulation among free-
14 living and captive Spanish imperial eagles in South-central Spain, a dry inland region
15 with no previous WNV evidence, throughout five consecutive years. They also indicate
16 the need for further research into this important zoonosis in order to better understand
17 its epidemiology in the Mediterranean ecosystem and in order to understand the role of
18 WNV in the population dynamics of the critically endangered Spanish imperial eagle.

19

20 Keywords: *Aquila adalberti*, emerging disease, resident, Spain, Spanish imperial eagle,
21 West Nile virus.

1 **Introduction**

2 *West Nile virus* (WNV) is an arthropod-borne virus of the genus *Flavivirus*,
3 familiy *Flaviviridae*, which belongs to the Japanese-Encephalitis virus complex. It is
4 known to cycle between mosquito and avian hosts in Africa, Southern and Eastern
5 Europe (Smithburn et al., 1940; Hubalek and Halouzka, 1999). The virus strain that was
6 introduced into North America in 1999, apart from causing serious illness and even
7 mortality in humans, leads to severe disease and mortality among local bird species,
8 especially corvids (Anderson et al., 1999; Lanciotti et al., 1999; Steele et al., 2000), and
9 has been shown to be responsible for the decline of some of these species (La Deau et
10 al., 2007). This contrasts with the little pathology historically observed in avian hosts in
11 Africa and Europe (Hubalek and Halouzka, 1999).

12 Since 1994, outbreaks of increasing severity among humans have also been
13 reported in Eastern and Southern Europe, Israel and Northern Africa, in addition to
14 reports on deaths of storks and geese, suggesting a change in the epidemiology of the
15 disease (Hubalek and Halouzka, 1999, Murgue et al., 2001; Malkinson et al., 2002;
16 Durand et al., 2004; Kramer et al., 2007). WNV was recently linked to disease and
17 mortality in a flock of captive geese and in a free-living raptor (a goshawk, *Accipiter*
18 *gentilis*) in Hungary, with human cases occurring in the same area (Bakonyi et al., 2006).
19 In contrast, information on WNV activity in Spain is scarce and, apart from detection of
20 antibodies in horses (Jiménez-Clavero et al., 2007), colonial waterbirds (Figuerola et al.,
21 2007a) and seroconversions in coots (Figuerola et al., 2007b) in Doñana National Park,
22 mostly related to humans (Lozano and Filipe 1998; Bofill et al., 2006; Kaptoul et al.,
23 2007).

24 The Spanish imperial eagle (*Aquila adalberti*) is listed as “endangered” by the
25 IUCN (International Union for the Conservation of Nature, BirdLife international,

1 2004), and is considered the most endangered eagle in Europe. The species is endemic
2 in the Southwestern Iberian Peninsula, and its recession has been attributed to human
3 pressure and the decline of its staple prey, the rabbit *Oryctolagus cuniculus* (Ferrer and
4 Negro, 2004). Only fragmented populations of the Spanish imperial eagle are left in
5 Southern and central Spain, with 185 breeding pairs counted in 2003 (Martinez-Cruz et
6 al., 2004). Here we report the detection of WNV in this endangered eagle and discuss
7 the importance of this finding in the context of future research on WNV in Southern
8 Europe and possible conservation implications.

9

10 **2. Material and methods**

11 2.1. Study site and sample collection.

12 The study area comprises the Montes de Toledo and Sierra de Morena Mountain
13 systems, both located in Castilla – La Mancha in South-central Spain (Figure 1). Two
14 captive breeding facilities exist in this area, in which non-releasable imperial eagles are
15 included as founders in an integrated captive breeding program. We analyzed tissue
16 samples or oral swabs from 10 imperial eagles (6 captive, 4 wild) for the presence of
17 WNV, and plasma samples from 21 imperial eagles (9 wild, 12 captive) for the presence
18 of antibodies against WNV. More precisely, the tissue samples and oropharyngeal
19 swabs analyzed in this study are from eagles that died in one of the breeding facilities
20 between 2001 and 2004 (n=3), samples from healthy captive eagles collected in 2003
21 (n=3), and samples from wild imperial eagles collected in the field between 2002 and
22 2005 (n=4). Wild imperial eagles included both, one healthy adult bird, and nestlings
23 that suffered and died from conditions caused by organisms mostly considered to be
24 secondary opportunistic pathogens (n=3). All plasma samples were collected from
25 apparently clinically healthy captive adult (n=12) or wild nestling eagles (n=9). Most

1 (n=7) of the healthy wild imperial eagle nestlings were sampled upon admission to a
2 rehabilitation centre for non-infectious reasons (trauma, sibling aggression, etc.), while
3 two nestlings were sampled in the field at radiotagging. All blood samples from
4 nestlings were taken between June and July 2003. The captive adult imperial eagles
5 were sampled during the yearly routine health check between September and December
6 2003.

7 Tissue samples were collected using sterile instruments during necropsy into RNase
8 and DNase free cryovials, and oropharyngeal swabs were collected using sterile cotton
9 swabs that were immediately transferred into a commercial transport medium for
10 viruses (Eurotubo, Deltalab S.A., Barcelona, Spain).

11 Blood samples were collected from the brachial vein using sterile syringes, and
12 transferred immediately to lithium-heparin coated sterile tubes. The samples were either
13 centrifuged shortly (10-15 min) after collection or kept refrigerated at 4° C until arrival
14 at the laboratory and centrifuged later (max. 5 hours). After centrifugation, plasma and
15 the cellular fraction were separated and stored frozen at -30° C until further analysis.

16 Prior to seroneutralization assays the plasma was inactivated at 56° C for 30 minutes.

17

18 2.2. Reverse transcription-polymerase chain reaction (RT-PCR) and sequence analysis.

19 Lung, heart, kidney, liver and/or brain tissue samples and the oral swabs were
20 analyzed by RT-PCR using primers and procedures published previously for the
21 presence of WNV and members of the genus flavivirus, respectively (Lanciotti et al.,
22 2000; Kuno et al., 1998). Total RNA was extracted using TRIZOL (Invitrogen life
23 technologies, Karlsruhe, Germany) or TriReagent (Sigma) according to manufacturer's
24 instructions. RT-PCR reactions were performed using the Access RT-PCR system
25 (Promega, Madison, WI, USA) and primers specific for West Nile virus (WN233 and

1 WN640c; Lanciotti et al., 2000) and flavivirus NS5 protein gene (cFD2 and MA; Kuno
2 et al., 1998). After RT, PCR was done using 10 pmol of each primer in a 50- μ l volume
3 (1.5 mM MgSO₄, 0.2 mM dNTP, 1X AMV/Tfl 5X reaction buffer, 5u *Tfl* DNA
4 polymerase) in an automated DNA thermal cycler (Eppendorf Mastercycler® personal,
5 Westbury, NY, USA) for 40 cycles of a denaturing step of 30 sec at 94° C, an annealing
6 for 60 sec at 55° C (WNV) or 53° C (flavivirus) and an extension step of 3 min at 68° C.
7 Negative control reactions were performed with the same procedures, but adding water
8 instead of RNA to monitor contamination of the RT-PCR. The program ended by
9 storing the reactions at 10° C. PCR products were electrophoresed on 1% agarose gels to
10 check the size of amplified fragments by comparison to a DNA molecular weight
11 marker (1 Kb DNA Ladder, Promega). Amplified fragments were resin purified
12 (Wizard, Promega) and cloned into the pGEM-T vector (Promega) for sequencing both
13 strands by double-stranded dye-termination cycle sequencing (Core Sequencing
14 Facility, Department of Biochemistry and Molecular Biology, Noble Research Center,
15 Oklahoma State University). At least five independent clones were sequenced for each
16 PCR. Multiple sequence alignment was performed using the program AlignX (Vector
17 NTI Suite V 5.5, InforMax, North Bethesda, MD, USA) with an engine based on the
18 Clustal W algorithm (Thompson et al., 1994). BLAST (Altschul et al., 1990) was used
19 to search the NCBI nr database to identify previously reported sequences with identity
20 to those obtained in the study described herein.

21

22 2.3. Serologic tests.

23 Neutralizing antibody titers to WNV were determined by a micro virus-neutralization
24 test (micro-VNT) in 96-well plates adapted from a previously described method
25 (Weintgartl *et al.*, 2003), as follows: serum samples were inactivated at 56° C for 30

1 minutes prior to analysis. Dilutions of test sera (25 μ l) were incubated with 100 TCID₅₀
2 of WNV strain E101 in the same volume (25 μ l) for 1 h at 37° C in Eagle's medium
3 (EMEM) supplemented with L-glutamine, 100 U/ml penicillin, 100 μ g/ml streptomycin;
4 this was followed by the addition of 50 μ l of a suspension (5×10^5 cells/ml) of Vero E6
5 cells to the same medium plus fetal calf serum to reach a final concentration of 5%. The
6 mixture was further incubated for 6-7 days at 37° C until cytopathic effects (cpe) were
7 observed in back-titration control wells with 10 TCID₅₀, to ensure completion of the
8 cpe in test wells containing 100 TCID₅₀ of virus. The screening of samples was
9 performed at 1/10 and 1/20 dilutions of tested sera (dilutions considered before the
10 addition of virus, that is, in a volume of 25 μ l). Samples yielding positive neutralization
11 (absence of cpe) at one or both of the dilutions tested were confirmed and further
12 titrated by analyzing serial serum dilutions from 1/10 to 1/1280. The neutralizing serum
13 titre was considered to be the highest value of the reciprocal serum dilution giving a
14 complete absence of cpe.

15

16 2.4. Immunohistochemistry

17 Immunohistochemistry was used on the tissues of six eagles applying a commercial
18 monoclonal antibody against the major envelope protein E of WNV/Kunjin virus (MAB
19 8150, Chemicon international inc., Temecula, CA, USA). The avidin–biotin–peroxidase
20 complex (ABC) method was used on paraffin-embedded tissue sections for
21 immunohistochemical staining. Briefly, sections were deparaffinized and hydrated, and
22 treated with proteinase K for 6 min at room temperature. Endogenous peroxidase
23 activity was inactivated by incubation with 3% hydrogen peroxide in methanol for 30
24 min at room temperature (20–25° C). After three 10 min rinses in phosphate-buffered
25 saline (PBS; pH 7.4), sections were incubated with 5% normal goat serum (Vector

1 Laboratories, Burlingame, CA) for 20 min at room temperature. The primary antibody
2 was applied on paraffin sections for 12 h at 4 °C at a dilution of 1:100 in PBS (pH 7.4).
3 After three 10 min rinses in PBS, sections were incubated with a biotinylated goat
4 antimouse IgG (Vector Laboratories) diluted 1:200 for 30 min at room temperature.
5 After three 10 min rinses in Tris-buffered saline (pH 7.6), an avidin-biotin complex
6 (Vector Laboratories) diluted 1:50 was applied for 30 min at room temperature.
7 Sections were incubated for 1 min with 3-30- diaminobenzidine tetrahydrochloride
8 diluted 0.035% in Tris-buffered saline (pH 7.6) containing 0.01% hydrogen peroxide as
9 chromogen (Vector Laboratories). All immunostained sections were counterstained with
10 Mayer's haematoxylin. The specific primary antibody was replaced by PBS and by
11 nonimmune mouse serum in negative control tissue sections.

12

13 2.5. Sequence accession numbers

14 The GenBank accession numbers for WNV V2 and flavivirus NS5 sequences are
15 EF152579-EF152581 and EF152582, respectively.

16

17 **Results**

18 WNV was detected by RT-PCR in 8 of 10 (80%) Imperial eagles analyzed, both
19 in apparently clinically healthy birds, and in animals that died due to secondary
20 infections but had symptoms/lesions compatible with WNV (Table 1). Positive samples
21 were found in almost six consecutive years (2001-2005), in summer as well as in winter
22 (Table 1, Figure 1). Also, the cases in which WNV was detected in birds from the field
23 were distributed across the study area (Figure 1). All Flavivirus NS5 sequences were
24 identical (Genbank accession number EF152582). In contrast, three different genotypes
25 were found for WNV V2 sequences (Genebank accession numbers EF152579-

1 EF152581). The analysis of WNV V2 sequences showed that Spanish imperial eagle
2 strains were close related to African and European strains (Table 2).

3 Using immunohistochemistry, WNV antigen was detected in a number of
4 different tissues. In the brain, mostly Purkinje cells in the cerebellum were found to
5 have viral antigen (Table 1, Figure 2), although antigen was also detected in neurons in
6 the brain stem and in one case in the cerebrum. WNV antigen was present in epithelial
7 cells of the gizzard and duodenum, in perivascular inflammatory cells in the liver
8 kidney and lung, and in one of the birds that had severe hemosiderosis in endothelial
9 and Kupffer-cells (Table 1, Figure 2).

10 Overall seroprevalence of antibodies against WNV in the Imperial eagles was
11 23.8 % (5 out of 21 samples). The number of individuals with antibodies against WNV
12 was similar between free-living nestlings (2 out of 9 samples, 22.2 %) and captive adult
13 eagles (3 out of 12 samples, 25 %). Low and significant antibody titers were detected in
14 both, nestling and adult birds (Table 3).

15

16 **Discussion**

17 Our results evidence WNV circulation among free-living and captive Spanish imperial
18 eagles in South-central Spain, a dry inland region with no previous WNV evidence. The
19 negative result of the Flavivirus RT-PCR in some West Nile virus positive cases could
20 be related to the age (some originated from 2001) and storage conditions (-20° C) of the
21 samples prior to analysis that may have led to degradation of the viral RNA. It may also
22 be due to the fact that the generic Flavivirus RT-PCR is less sensitive than the specific
23 RT-PCR used for the detection of WNV.

24 In Spain, WNV antibodies have been detected in fledglings of colonial waterbird
25 species that migrate to areas where WNV is known to circulate (Figuerola et al., 2007).

1 In addition, seroconversion has been demonstrated in a population of common coots
2 (*Fulica atra*) that has been monitored serologically since 2003 (Figuerola et al 2007b),
3 and horses in the same area show 8% prevalence of antibodies to this virus (Jiménez-
4 Clavero et al., 2007). These reports and a recent human case (Kaptoul et al., 2007), and
5 the detection of anti-WNV IgM and IgG in an individual in Catalonia (Bofill et al.,
6 2006) suggest at least temporary circulation of WNV in Spain. Our results render the
7 first evidence of viral antigen in a resident avian species. The detection of WNV in an
8 imperial eagle in central Spain in winter could be indicative of both, introduction by
9 migratory birds, and existence of endemic foci. The mild winters in Spain could, at least
10 in some regions, allow persistence of WNV in overwintering mosquitoes. In a study
11 based on the information on bird movements and the prevalence of WNV in the
12 Camargue region in France, Jourdain et al. (2007) proposed three models for the
13 epidemiology of WNV with relation to outbreaks among humans and horses in dry
14 areas close to the wetland. In two of the proposed scenarios, the introduction of WNV
15 from endemic areas in Eastern Europe, or local persistence with overwintering of WNV
16 would be a key feature. Our results indicate that WNV probably circulated throughout at
17 least six consecutive years in our study area. These results underline the urgent need for
18 further research into this important zoonosis in order to better understand its
19 epidemiology in the Mediterranean ecosystem.

20 WNV detection in juvenile and adult imperial eagles with clinical disease raises
21 questions about its potential involvement in the development of disease with primary
22 fatality or death due to secondary conditions. The detection of viral antigen in numerous
23 organs in association with degenerative lesions in the liver and central nervous system is
24 consistent with findings in North American raptors and owls (Nemeth et al., 2006;
25 Lopes et al., 2007) and points towards a certain implication of WNV in the pathogenesis

1 of the disease process. In nestlings, stress from sibling aggressive behaviour may have
2 favoured the development of disease conditions due to secondary pathogens by reducing
3 the defenses, and WNV may have contributed. Low population size and fragmentation
4 render the Spanish imperial eagle especially vulnerable to the threat of disease
5 (McCallum & Dobson, 2002; Martinez-Cruz et al., 2004). Hence, further research
6 should also elucidate the role of WNV in the population dynamics of the critically
7 endangered Spanish imperial eagle.

8

9 **Acknowledgements**

10 L. Romero (MAPA) kindly reviewed a first version of this manuscript. We gratefully
11 acknowledge the assistance of the central veterinary laboratory in Algete, Madrid
12 (MAPA) with the seroneutralization assays. This is a contribution to the agreement
13 between CSIC, OAPN-MMA, and SDGSA-MAPA on wildlife disease surveillance in
14 Spain, and to the Castilla – La Mancha network on wildlife diseases (REVISIA -
15 JCCM).

16

17 **References**

- 18 Altschul, S.F., Gish, W., Miller, W., Myers, E.W., Lipman, D.J., 1990. Basic local
19 alignment search tool. *J. Molecular Biol.* 215, 403-410.
- 20 Anderson, J.F., Andreadis, T.G., Wikel, S.K., Vossbrink, C.R., Tirrell, S., Wakem,
21 E.M., French, R.A., Van Kruiningen, H.J., 1999. Isolation of West Nile virus from
22 mosquitoes, crows and a Cooper's hawk in Connecticut. *Science* 286, 2331-2333.
- 23 Bakonyi, T., Ivanics, E., Erdelyi, K., Ursu, K., Ferenczi, E., Weissenbock, H., Nowotny,
24 N., 2006. Lineage 1 and 2 strains of encephalitic West Nile virus, central Europe.
25 *Emerg. Infect. Dis.* 12, 618-623.

- 1 Bofill, D., Domingo, C., Cardenosa, N., Zaragoza, J., de Ory, F., Minguell, S., Sanchez-
2 Seco, M.P., Domínguez, A., Tenorio, A., 2006. Human West Nile virus infection,
3 Catalonia, Spain. *Emerg. Infect. Dis.* 12, 1163-1164.
- 4 Durand, J.P. , Simon, F. , Tolou, H., 2004. West Nile virus: in France again, in humans
5 and horses. *Rev. Prat.* 54, 703-710.
- 6 Ferrer, M., Negro, J.J., 2004. The near extinction of two large European predators:
7 super specialists pay a price. *Conserv. Biol.* 18, 344-349.
- 8 Figuerola, J., Jiménez-Clavero, M.A., Rojo, G., Gómez-Tejedor, C., Soriguer, R., 2007.
9 Prevalence of West Nile virus neutralizing antibodies in colonial aquatic birds in
10 southern Spain. *Avian Pathol.* 36, 209-212.
- 11 Figuerola, J., Soriguer, R., Rojo, G., Gómez-Tejedor, C., Jiménez-Clavero, M.A. 2007.
12 Seroconversion in wild birds and local circulation of West Nile virus, Spain. *Emerg.*
13 *Infect. Dis.* (in press).
- 14 Hubalek, Z., Halouzka, J., 1999. West Nile Fever a re-emerging mosquito-borne viral
15 disease in Europe. *Emerg. Infect. Dis.* 5, 643-650.
- 16 Jiménez-Clavero, M.A., Gómez-Tejedor, C., Rojo, G., Soriguer, R., Figuerola, J., 2007.
17 Serosurvey of West Nile virus antibodies in equids and bovids in Spain. *Vet. Rec.* 161,
18 212.
- 19 Jourdain, E., Toussain, Y., Leblond, A., Bicout, D.J., Sabatier, P., Gauthier-Clerc, M.,
20 2007. Bird species potentially involved in introduction, amplification, and spread of
21 West Nile virus in a Mediterranean wetland, the Camargue (Southern France). *Vector*
22 *Borne Zoonotic Dis.* 7, 15-33.
- 23 LaDeau, S.L., Kilpatrick, A.M., Marra, P.P., 2007. West Nile virus emergence and
24 large-scale declines of North American bird populations. *Nature* 447, 710-713.

- 1 Kaptoul, D., Viladrich, P.F., Domingo, C., Niubo, J., Martinez-Yelamos, S., De Ory, F.,
2 Tenorio, A., 2007. West Nile virus in Spain: report of the first diagnosed case in a
3 human with aseptic meningitis. *Scand. J. Infect. Dis.* 39, 70-71.
- 4 Kramer, L.D., Li, J., Shi, P.Y., 2007. West Nile virus. *Lancet Neurol.* 6, 8171-8181.
- 5 Kuno, G., 1998. Universal diagnostic RT-PCR protocol for arboviruses. *J. Virol. Meth.*
6 72, 27-41.
- 7 Lanciotti, R.S., Roehrig, J.T., Deubel, V., Smith, J., Parker, M., Steele, K., Volpe, K.E.,
8 Crabtree, M.B., Scherret, J.H, May, R.A., MacKenzie, C.B., Cropp, B., Panigrahy, B.,
9 Ostlund, E., Schmitt, B., Malkinson, M., Banet, C., Weissman, J., Komar, J., Savage,
10 H.M., Stone, W., McNamara, T., Gubler, D.J., 1999. Origin of the West Nile Virus
11 responsible for an outbreak of encephalitis in the notheastern US. *Science* 286, 2333-
12 2337.
- 13 Lanciotti, R.S., Kerst, A.J., Nasci, R.S., Godsey, M.S., Mitchell, C.J., Savage, H.M.,
14 Komar, N., Panella, N.A., Allen, B.C., Volpe, K.E., Davis, B.S., Roehrig, J.T., 2000.
15 Rapid detection of West Nile virus from human clinical specimens, field-collected
16 mosquitoes, and avian samples by a TaqMan reverse transcriptase-PCR assay. *J. Clin.*
17 *Microbiol.* 38, 4066-4071.
- 18 Lopes, H., Redig, P., Glaser, A., Armien, A., Wunschmann, A., 2007. Clinical findings,
19 lesions, and viral antigen distribution in great gray owls (*Strix nebulosa*) and barred
20 owls (*Strix varia*) with spontaneous West Nile virus infection. *Avian Dis.* 51, 140-145.
- 21 Lozano, A., Filipe, A.R., 1998. Antibodies against the West Nile virus and other
22 arthropod-transmitted viruses in the Ebro Delta region (Article in Spanish). *Rev. Esp.*
23 *Salud Publica.* 72, 245-250.
- 24 McCallum, H. & Dobson, A., 2002. Disease, habitat fragmentation and conservation.
25 *Proc. Royal Soc. Lond. B.* 269, 2041-2049.

- 1 Malkinson, M., Banet, C., Weisman, Y., Pokamunski, S., King, R., Drouet, M.T.,
2 Deubel, V., 2002. Introduction of West Nile virus in the Middle East by migrating white
3 storks. *Emerg. Infect. Dis.* 8, 392-397.
- 4 Martinez-Cruz, B., Godoy, J.A., Negro, J.J., 2004. Population genetics after
5 fragmentation: the case of the endangered Spanish imperial eagle. *Mol. Ecol.* 13, 2243-
6 2455.
- 7 Murgue, B., Murri, S., Zientara, S., Durand, B., Durand, J.-P., Zeller, H., 2001. West
8 Nile outbreak in horses in southern France, 2000: The return after 35 years. *Emerg.*
9 *Infect. Dis.* 7, 692-696.
- 10 Nemeth, N., Gould, D., Bowen, R., Komar, N., 2006. Natural and experimental West
11 Nile virus infection in five raptor species. *J. Wildl. Dis.* 42, 1-13.
- 12 Smithburn, K.C., Huges, T.P., Burke, A.W., Paul, J.H., 1940. A neurotropic virus
13 isolated from the blood of a native of Uganda. *Am. J. Trop. Med.* 20, 471-492.
- 14 Steele, K.E., Linn, M.J., Schoepp, R.J., Komar, N., Geisbert, T.W., Manduca, R.M.,
15 Calle, P.P., Raphael, B.L., Clippinger, T.L., Larsen, T., Smith, J., Lanciotti, R.S.,
16 Panella, N.A., McNamara, T.S., 2000. Pathology of fatal West Nile virus infections in
17 native and exotic birds during the 1999 outbreak in New York city, New York. *Vet.*
18 *Pathol.* 37, 208-224.
- 19 Thompson, J.D., Higgins, D.G., Gibson, T.J., 1994. CLUSTAL W: improving the
20 sensitivity of progressive multiple sequence alignment through sequence weighting,
21 positions-specific gap penalties and weight matrix choice. *Nucleic Acid Research* 22,
22 4673-4680.

1 Table 1. Summary of Spanish imperial eagle samples analyzed and evidences of WNV
 2 infection

Ref. No.	Characteristics	Out come	Date	Samples for PCR	RT-PCR Results		Accession	Immuno histo-chemistry
					WNV	Flavi-virus		
NR 1262	Capt., adult female, hemolytic crisis	fatal	08/2001	pool	+	+	EF1525 80	Brain
NR 1456	Free-living nestling, trichomonosis, mycoplasma, dimorphic fungus	fatal	06/2002	brain	+	+	Ns	Brain, liver
NR 1458	Wild nestling, sibling agression, hepatitis, hemorrhagic enteritis,	fatal	06/2002	liver	+	+	Ns	brain, liver, lung, kidney
NR 1677	Capt. ad., heart failure	fatal	02/2003	brain	+	-	EF1525 81	Brain, duod., gizz.
NR 2161	Capt. ad., cardiac infarct	fatal	12/ 2004	Lung, heart brain	Heart +	All +	EF1525 79	Brain, kidney
NR 2058	Free-living nestling, feathering problems, <i>K. pneumoniae</i>	fatal	07/2004	kidney	+	-	Ns	Brain, kidney, liver
Houdini	Captive juvenile	Alive	12/2003	swab	-	-	-	Na
AA1/05	Healthy wild adult	Alive	01/2005	swab	+	-	Ns	Na
M34H	Healthy captive adult	Alive	09/2003	swab	-	-	-	Na
M40H	Healthy captive adult	Alive	10/2003	swab	+	-	Ns	Na

3 * Na = not analyzed. Ns= not sequenced.

1 Table 2. BLAST analysis of WNV V2 sequences from Spanish imperial eagle strains.
2

Accession	Country of origin	Score	E value	Identity ^a		
				WNV61 (EF152579)	WNV63 (EF152581)	WNV64 (EF152580)
M12294.2	Uganda	243	2e-61	99%	98%	95%
DQ116961.1	Hungary	237	8e-60	98%	97%	94%
AY532665.1	Uganda	237	8e-60	98%	97%	94%
DQ318019.1	Senegal	237	8e-60	98%	97%	94%
DQ318020.1	Central African Republic	231	4e-58	97%	97%	94%
AY688948.1	Israel	215	4e-53	95%	94%	91%

3
4 Sequences with highest BLAST score are shown. ^aNucleotide sequence identity is
5 shown for the three WNV strains obtained in this study. Genbank accession numbers
6 are shown in parenthesis.

1 Table 3. Summary of the antibody titers against WNV detected in free-living nestling
 2 and captive adult eagles in central Spain.

Status of Individuals	0	10	20	40	80	160	320	640	1280	>1280	Perce ntage ≥10
	Captive adults	9	1	1	--	--	--	--	--	--	1
Free-living nestlings	7	--	1	--	--	1	--	--	--	--	25
Total	16	1	2	--	--	1	--	--	--	1	23.8

3

Accepted Manuscript

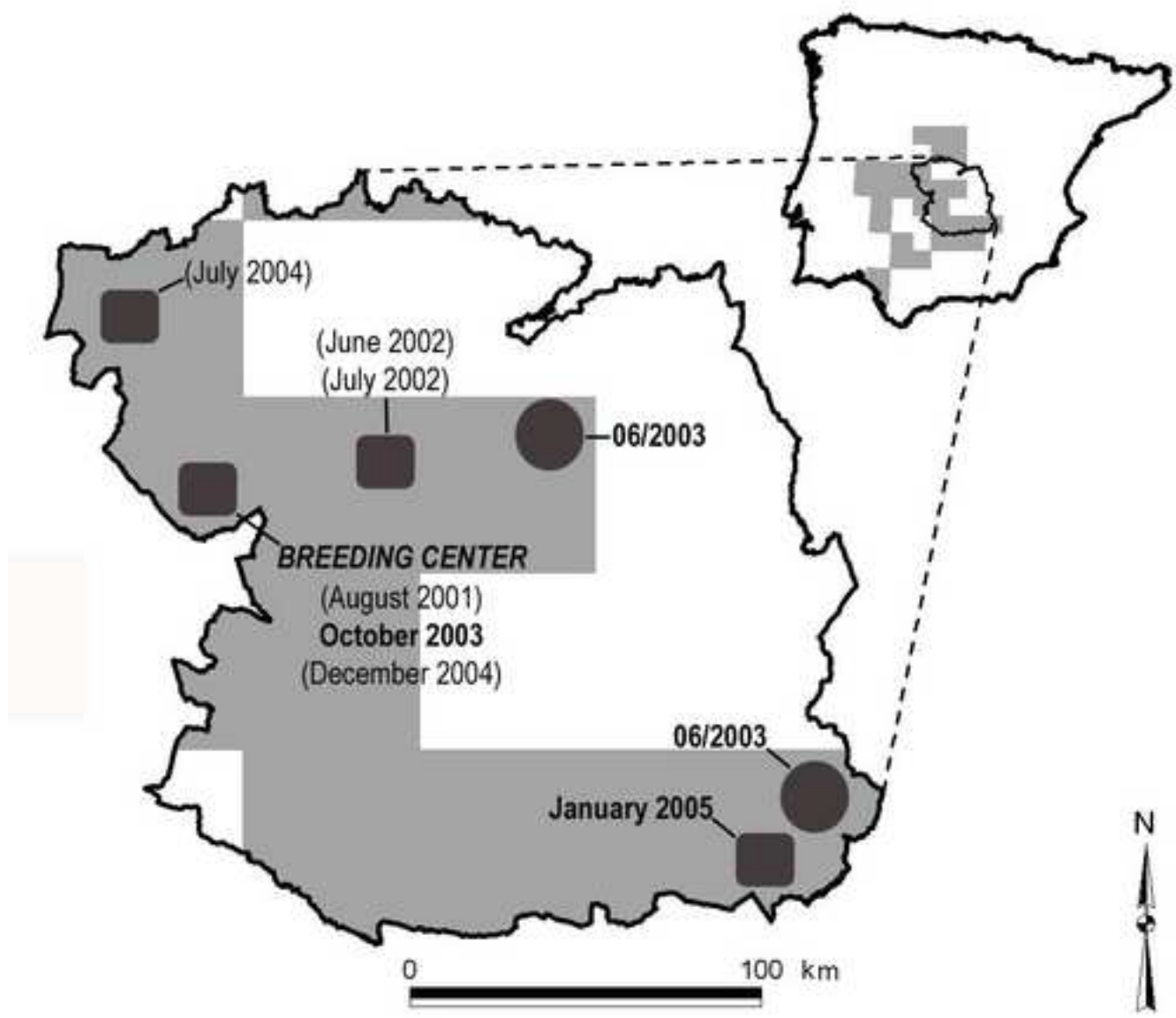
1 Figure 1. Study area, distribution of the Spanish imperial eagle and detection of WNV
2 antigen and antibodies in free-living and captive imperial eagles.
3 The distribution of the population of imperial eagles in the study area is
4 represented by shaded areas. Cases in which WNV antigen has been detected are
5 marked with squares, bold writing of the month and year of sampling indicates
6 live birds, in fatal cases the month and year are in brackets. Detection of
7 antibodies in nestlings from the field is marked with circles and the month is not
8 spelled out. WNV antigen was detected in live and dead imperial eagles in the
9 captive breeding center as well as antibodies.

Accepted Manuscript

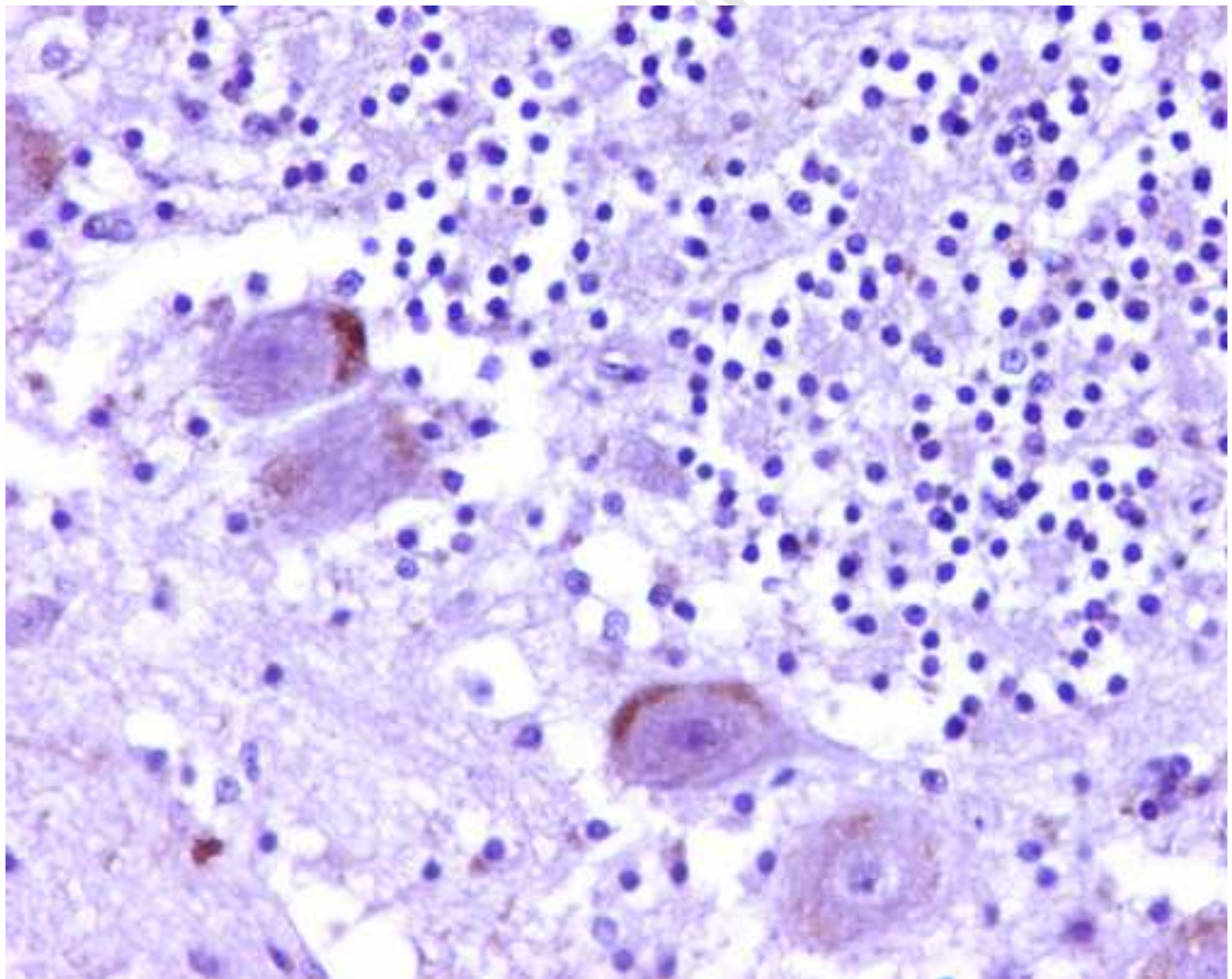
1 Figure 2. Detection of WNV antigen in Spanish imperial eagles by
2 immunohistochemistry (x400) a) Purkinje cells of the brain in an adult, b)
3 endothelial and Kupffer cells in the liver of a nestling (x400).

Accepted Manuscript

Manuscript



Manuscript



Manuscript

