



HAL
open science

The effect of intramuscular administration of colistin on the development and course of experimentally induced oedema disease in weaned piglets

Lucie Konstantinova, Jaroslav Hamrik, Pavel Kulich, Vladimir Kummer, Jarmila Maskova, Pavel Alexa

► To cite this version:

Lucie Konstantinova, Jaroslav Hamrik, Pavel Kulich, Vladimir Kummer, Jarmila Maskova, et al.. The effect of intramuscular administration of colistin on the development and course of experimentally induced oedema disease in weaned piglets. *Veterinary Microbiology*, 2008, 128 (1-2), pp.160. 10.1016/j.vetmic.2007.09.021 . hal-00532331

HAL Id: hal-00532331

<https://hal.science/hal-00532331>

Submitted on 4 Nov 2010

HAL is a multi-disciplinary open access archive for the deposit and dissemination of scientific research documents, whether they are published or not. The documents may come from teaching and research institutions in France or abroad, or from public or private research centers.

L'archive ouverte pluridisciplinaire **HAL**, est destinée au dépôt et à la diffusion de documents scientifiques de niveau recherche, publiés ou non, émanant des établissements d'enseignement et de recherche français ou étrangers, des laboratoires publics ou privés.

Accepted Manuscript

Title: The effect of intramuscular administration of colistin on the development and course of experimentally induced oedema disease in weaned piglets

Authors: Lucie Konstantinova, Jaroslav Hamrik, Pavel Kulich, Vladimir Kummer, Jarmila Maskova, Pavel Alexa



PII: S0378-1135(07)00481-6
DOI: doi:10.1016/j.vetmic.2007.09.021
Reference: VETMIC 3839

To appear in: *VETMIC*

Received date: 7-5-2007
Revised date: 27-9-2007
Accepted date: 28-9-2007

Please cite this article as: Konstantinova, L., Hamrik, J., Kulich, P., Kummer, V., Maskova, J., Alexa, P., The effect of intramuscular administration of colistin on the development and course of experimentally induced oedema disease in weaned piglets, *Veterinary Microbiology* (2007), doi:10.1016/j.vetmic.2007.09.021

This is a PDF file of an unedited manuscript that has been accepted for publication. As a service to our customers we are providing this early version of the manuscript. The manuscript will undergo copyediting, typesetting, and review of the resulting proof before it is published in its final form. Please note that during the production process errors may be discovered which could affect the content, and all legal disclaimers that apply to the journal pertain.

1 The effect of intramuscular administration of colistin on the development and course of
2 experimentally induced oedema disease in weaned piglets

3

4 Lucie Konstantinova, Jaroslav Hamrik, Pavel Kulich, Vladimir Kummer, Jarmila Maskova ,
5 Pavel Alexa*

6 Veterinary Research Institute, Hudcova 70, 621 00, Brno, Czech Republic

7 Tel.: +420 533 331 215

8 Fax: +420 541 211 229

9 E-mail: alexa@vri.cz

10 * Corresponding author

11

12

13 **Abstract**

14

15 Shiga-toxigenic *E. coli* (STEC) strains that produce Shiga toxin Stx2e cause oedema disease
16 in weaned piglets. The purpose of the present study was to investigate the impact of Stx2e
17 released in mesenteric lymph nodes on disease pathogenesis. Colistin and ampicillin were
18 intramuscularly administered to piglets of the experimental group simultaneously challenged
19 with STEC strain, type O139:F18ab, Stx2e+. Piglets of the control group were challenged
20 with STEC only. The strain was naturally resistant to ampicillin and susceptible to colistin.
21 After the challenge, colonisation of the intestines was observed in both antibiotic-treated
22 piglets and control piglets without antibiotic treatment. Histochemistry and scanning electron
23 microscopy revealed sporadic colonisation of the small intestine in the piglets. STEC was
24 detected in the mesenteric lymph nodes of untreated piglets. The clinical manifestations of
25 oedema disease were observed in both groups. In the antibiotic-treated group (11 piglets),

1 oedema disease developed in 10 piglets, 8 of which died or were euthanized *ante finem*. In the
2 untreated group (11 piglets), oedema disease developed in 5 piglets, 4 of which died or were
3 euthanized *ante finem*. We therefore propose that the STEC lysed by colistin suddenly
4 released the toxin from bacterial cells immediately after their passage through the intestinal
5 wall. That could explain a more severe course of oedema disease in the treated piglets. Even
6 though high amounts of STEC were present in the lymph nodes of untreated piglets, the toxin
7 was not released abruptly because the bacterial cells were not damaged.

8

9 Keywords: *Escherichia coli*, ED, STEC, colonising factors

10

11 **Introduction**

12 Oedema disease of swine is a toxæmia caused by shiga-toxigenic *E. coli* (STEC) colonising
13 the small intestine and producing exotoxin. The causative agent of oedema disease is
14 verotoxin Stx2e. Stx2e in pigs induces typical lesions, including fibrinoid necrosis of small
15 arteries, brain haemorrhages and, at higher doses, surface necroses in the colonic epithelium
16 as well as damage to kidney tissue (Gannon et al., 1989). Oedema in various parts of the
17 body can be found on autopsy.

18

19 *E. coli* strains causing oedema disease colonise the intestines of piglets (Bertschinger and
20 Gyles, 1994), and in some strains of STEC fimbrial antigen F18ab has been demonstrated
21 (Rippinger et al., 1995; Wittig et al., 1995). Wittig et al. (1995) proposed that strains
22 associated with oedema disease have the colonisation factor F18ab and adhere to the intestinal
23 mucous membrane. STEC strains without known colonisation factors in piglets suffering from
24 oedema disease have also been detected in other countries (Wittig et al., 1995; Osek, 1999;
25 Osek, 2000; Alexa et al., 2002; Frydendahl, 2002; Cheng et al., 2006).

1

2 Timoney (1957) suggested that only a small proportion of the toxin present in intestinal lumen
3 reaches the vascular system. The relatively long delay between colonisation of the intestine
4 and the appearance of clinical symptoms of the disease is viewed as indicative of a slow
5 passage of the toxin through the intestinal wall (Smith and Halls, 1968). Other than this, little
6 is known about the absorption of functionally active Stx from the intestine (Gyles, 1994).

7

8 STEC is frequently isolated in pure culture from swollen and oedematous lymph nodes but
9 not from other tissues or the blood of piglets suffering from oedema disease (Salajka and
10 Salajkova, 1987). We expected that STEC colonising the lymph nodes of piglets can produce
11 Shiga toxin there that is subsequently transported into the organs. We performed experiments
12 with the aim to prevent STEC multiplication and Stx2e production in the lymph nodes of
13 piglets without disturbing STEC colonisation of the intestines. For this purpose, we used
14 parenteral administration of colistin, which does not pass through the intestinal wall. We
15 supposed that its administration would not allow the toxin production by STEC that colonise
16 the lymph nodes and that the course of oedema disease in the treated piglets would be milder
17 than in untreated piglets. In contrast to our assumption, the antibiotic-treated piglets exhibited
18 more severe signs of oedema disease.

19

20 **Material and methods**

21

22 *E. coli* strain

23 *E. coli* strain 11313 (O139:F18, stx2e+) isolated from a weaned piglet that had died of
24 oedema disease was used for piglet infection. The strain was naturally susceptible to colistin
25 and resistant to ampicillin. The culture was grown in culture medium containing 12.5 g of

1 acid casein hydrolysate, 12.5 g of enzymatic casein hydrolysate (Imuna, Sarisske Michalany,
2 Slovak Republic) and 0.5 g of yeast extract (Oxoid) per 1 litre. The culture was incubated at
3 37°C with shaking for 16 h. A part of the culture for individual oral administration was
4 pelleted by centrifugation and mixed into a neutral sterile puree (wheat flour and semolina).
5 The paste contained 2×10^{10} CFU/ml.

6 7 Animals

8 Animal handling complied with the legal directives of the Czech Republic and with the
9 Institution's policy. Piglets from a conventional herd (22 animals in 2 experiments), weaned
10 at 28 days of age were used in the experiments. The piglets were fed a diet composed of
11 wheat, barley, soybean meal and fish meal (19.2% N substances, 3.5% fat, 3.7% fibre). The
12 groups of piglets were kept in pens separated by metal bars. Experimental group piglets were
13 administered Ampisur (Ceva Sante Animale) (colistin and ampicillin) in the recommended
14 dose of 25,000 IU/kg of live body weight. Control group piglets were not treated.

15
16 Detection of piglets' susceptibility to intestinal colonisation with *E. coli* having colonisation
17 factors F18

18 To distinguish between piglets resistant and susceptible to intestinal colonisation by *E. coli*
19 with F18 adhesins, PCR was used for detecting the point mutation (G→A) of the *FUT1* gene
20 (fucosyltransferase gene) in the nucleotide sequence at position 307 (Meijerink et al., 2000).

21 For this purpose, ear skin samples were collected from each piglet. DNA was isolated from
22 25 mg of each sample of piglet auricle using the DNA Tissue Kit (Qiagen). The quality of the
23 isolated DNA was tested by agarose gel electrophoresis and the modified allele-specific PCR
24 method of Lee et al. (2002) was used. The forward primer to both alleles was **D(f)** 5'-GCC-
25 GCC-ACC-TCT-GTC-TGA-CCT-TC-3' , and 2 reverse primers were **R(r)** 5' CGG-CCG

1 TTG-AGC TGC-GC 3' for resistant pigs and S(r) 5' CGG-CCG TTG-AGC TGC-GT-3' for
2 susceptible pigs. The PCR was performed in 20 µl volume using the PCR Master Mix Kit
3 (Qiagen) according to the manufacturer's instructions. Ten pmol of each primer and 100 ng of
4 DNA were added to each PCR reaction. One hundred ng of the examined DNA was added to
5 the PCR. The PCR procedure included initial denaturation at 94°C/2 min and 38 cycles with
6 incubations at 95°C/15 s, 65°C/20 s and 72°C/40 s. After the final extension (5 min at 72°C),
7 the samples were cooled to 4°C and analysed by electrophoresis on 1.5% agarose gel.

8

9 Challenge of piglets

10 Both the groups (treated and untreated) were challenged with STEC strain 11313. All piglets
11 were orally infected with an STEC culture in a dose of 2×10^{11} CFU on the day after
12 weaning. The diet for piglets was supplemented with STEC culture of the same dose on each
13 of the following 3 days. The clinical health status of the piglets was regularly monitored for 3
14 weeks after infection. Rectal swabs were collected every day for bacteriological examination.
15 Animals that died or were euthanized *ante finem* were examined by autopsy; their intestines,
16 mesenteric lymph-nodes, livers, spleens and kidneys were examined by culture. Samples of
17 posterior jejunum and ileum were collected from the euthanized piglets for histology and
18 scanning electron microscopy.

19

20 Microbiological examination

21 Rectal swabs from piglets or contents of jejunum and colon were diluted in PBS (pH 7.4) and
22 spread on blood agar containing 5% lamb blood and on MacConkey agar and cultured in an
23 incubator at 37 °C. After superficial burning and cutting, liver, spleen, kidney and mesenteric
24 lymph nodes obtained from the euthanized piglets were smeared onto 5% lamb blood and on
25 MacConkey agar. Ten randomly selected isolated colonies of *E. coli* from each swab were

1 examined and the percentages of haemolytic colonies were assessed. Haemolytic colonies
2 were inoculated onto a nutrient broth (Imuna Šarišské Michalany, Slovakia). After incubation
3 at 37°C for 16 h, intravital staining of cultures was performed by adding TTC (triphenyl-
4 tetrazolium-chloride) for 1 h and heating to 100°C, and then these were examined by
5 agglutination with antisera to O139 (Salajka et al., 1992). The percentage of the strain
6 administered and present in faeces was calculated according to the numbers of haemolytic
7 O139 type colonies in diluted culture on blood agar. Presence of the *stx2e* gene encoding the
8 Shiga toxin was confirmed by PCR (Alexa et al., 2000).

9

10

11

12 Histological and immunohistochemical examinations

13 Immediately after slaughter, samples of intestines were collected and fixed in 10% neutral
14 buffered formalin for 24 h. Paraffin sections 6 µm wide were mounted on silanised slides,
15 deparaffinised and rehydrated. For conventional histopathological examinations, the sections
16 were stained with haematoxylin-eosin.

17 Before immunohistochemical staining, heat induced antigen retrieval was performed in a
18 microwave at high power (750 W) for 15 min (3x5 min) in citrate buffer, pH 6.0. The activity
19 of endogenous peroxidase was blocked by 3% H₂O₂ for 15 min. Rabbit anti-O139 serum was
20 used for detecting *E. coli*, with incubation at room temperature for 60 min. For visualisation
21 of immunoreaction complexes, peroxidase conjugated affinity purified anti-rabbit IgG (code
22 611-903-002; Rockland, USA) was used according to the manufacturer's operating protocols.
23 Negative controls were obtained by replacement of primary antibody with a negative control
24 serum. As a chromogen, 0.03% DAB (3,3'-diaminobenzidine, Fluka Chemie AG, Buchs,

1 Switzerland) was used for 5 min at room temperature. The sections were counterstained with
2 haematoxylin.

3 Jejunum samples were examined by scanning electron microscopy after platinum palladium
4 metallisation using a Tesla BS300 scanning electron microscope.

5

6 Statistical analysis

7 The mean values and standard deviations were calculated for shedding of the challenge strain.

8 Morbidity and mortality due to oedema disease were evaluated by Fisher's test.

9

10

11

12 **Results**

13

14 By genotype PCR analysis, all piglets were found to be sensitive to the colonisation of
15 intestines with F18 positive *E. coli* (data not shown). After STEC infection, intensive
16 shedding of the challenge strain through faeces was noted in most piglets from both
17 antibiotic-treated and untreated groups. The percentages of the challenge *E. coli* strain shed
18 through faeces from antibiotic-treated piglets are presented in Fig. 1A. In the first experiment,
19 intensive shedding of the challenge strain in most of the antibiotic-treated piglets was
20 recorded on day 2 of infection, except for one piglet, in which the challenge strain prevailed
21 on day 4 of infection. In the second experiment, the challenge strain predominated in all the
22 antibiotic-treated piglets on day 1 of infection. In piglets that survived, shedding persisted up
23 to day 9 after the start of infection. In the untreated piglets (Fig. 1B) intensive shedding of the
24 challenge strain was observed in 3 and 4 piglets on days 1 and 2 of infection. With the
25 exception of one piglet, the challenge strain outnumbered the other *E. coli* types on day 4 of

1 infection. Shedding of the challenge strain by the survived piglets was below the detection
2 limit from day 10 after the start of infection.

3

4 In all euthanized (n=4) piglets from the antibiotic untreated group, STEC O139:F18ab,
5 Stx2e+ was detected by culture in mesenteric lymph nodes. Only one antibiotic-treated animal
6 was positive for STEC in mesenteric lymph nodes while the remaining (n=7) were negative.

7

8 The onset of clinical symptoms of oedema disease after infection and their duration in both
9 the experiments are summarised in Fig. 2. In the antibiotic-treated groups, clinical symptoms
10 of oedema disease were manifested in 10 piglets. Two of them had only moderate symptoms
11 of the disease and these spontaneously disappeared. In the remaining 8 piglets, a rapid course
12 of the disease was observed and the animals were euthanized *ante finem* within two days after
13 the onset of clinical symptoms. The early symptoms of the disease, especially characterised
14 by staggering, appeared on the third day after infection. Neural disorders rapidly impaired
15 piglets affected by oedema disease and a loss of coordination and weakness developed.
16 Oedema of the eyelids appeared in one piglet. Haemorrhagic diarrhoea manifested in one
17 piglet on day 3 after infection. The health status of 2 piglets from the antibiotic-treated group
18 remained good throughout the entire experiment. In the untreated groups, 5 piglets were
19 affected by oedema disease. Four of them were euthanized *ante finem*. Moderate symptoms
20 appeared in one piglet, which recovered 7 days later. In the antibiotic untreated groups, the
21 health status of 6 piglets remained good over the entire experimental period. The differences
22 in piglet mortality between groups were defined as $P=0.099$ and were non-significant;
23 significant differences were found in morbidity between antibiotic-treated and untreated
24 piglets ($P<0.05$).

25

1 Gross examination of euthanized piglets from both treated and untreated groups revealed
2 oedema of the subcutis, particularly of the eyelids and mesocolon. Fibrin fibres were found on
3 the peritoneum in some piglets. Symptoms of haemorrhagic enteritis and colitis were
4 observed in one piglet with haemorrhagic diarrhoea from the antibiotic-treated group.
5 Inflammatory infiltrate of the intestinal wall, local desquamation of epithelium and apical
6 destruction of villi were found in the same piglet by histology. In the other piglets,
7 histological examination revealed oedema and presence of increased amounts of infiltrate of
8 the intestinal wall (lymphoid cells and polymorphonuclears), which reached the surface
9 epithelium without alteration. Inflammatory lesions were not seen. No bacterial layers were
10 detected by immunohistochemistry on small intestine mucosa, with the exception of a single
11 piglet from the antibiotic-treated group affected by hemorrhagic enteritis, in which numerous
12 *E. coli* O139 bacteria were present as well as destroyed mucosal tissue. Regarding the
13 character of intestinal damage, it was not possible to unambiguously specify whether bacteria
14 were attached to mucosa, or were present in mucus and detritus. The scanning electron
15 microscopy examination of mucosa from euthanized piglets showed results similar to those of
16 the immunohistochemical examination. Mucosa of jejunum and ileum was free from *E. coli*
17 plaques in the majority of piglets. If bacteria were present on mucosa, they were rare. Areas of
18 adhered bacteria were found in the caudal jejunum of one piglet only.

19

20

21 **Discussion**

22

23 It is generally assumed that STEC colonise the small intestine and produce Shiga toxin Stx2e,
24 which is absorbed into the bloodstream and distributed to other tissues. However, both the
25 intestinal colonisation by STEC and the toxin transport across the gut epithelium into the

1 bloodstream pose several issues. Concerning the gut colonisation, except for a single animal,
2 we did not observe any epithelium colonisation using histology and scanning electron
3 microscopy. No bacteria were found associated with the epithelium. Even in the only animal,
4 in which we found an epithelium colonisation, this was considerably different from the way
5 of colonisation typical e.g. for the enterotoxigenic *E. coli*. The colonisation was limited to
6 isolated areas and bacteria were present mostly in mucus. No bacterial plaques were found on
7 the surface of epithelial cells.

8

9 The exact mechanism of Stx2e absorption into the blood vessels is not well understood.
10 Although the toxin was found to bind to the surface membranes of the microvilli of the
11 jejunum, ileum and colon, and receptors for Stx2e were found in the intestine of the pig, their
12 role in absorption of Stx2e is unclear because the intrainestinal inoculation of pigs with large
13 quantities of Stx2e did not result in oedema disease's development (Waddell et al., 1996).
14 Pathogenesis of oedema disease in pigs is still rather confusing and unclear.

15

16 Our results offer an alternative explanation for the pathogenesis of oedema disease in pigs.
17 Although we did not observe any significant adhesion to the epithelium, the STEC overgrew
18 other *E. coli* in the intestinal content because it was detected in faecal samples of both groups.
19 Due to the fact that the faecal shedding was essentially the same in both groups of animals,
20 this also confirmed that the parenterally administered colistin did not pass through the
21 intestinal barrier and therefore did not affect intrainestinal multiplication of the challenge
22 strain. In all antibiotic untreated piglets, colonisation of the mesenteric lymph nodes by the
23 challenge strain was observed. This may appear unexpected since STEC are non-invasive
24 extracellular bacteria and it is rather uncertain how the non-invasive *E. coli* could reach the
25 mesenteric lymph nodes. It remains unclear whether and how F18ab fimbriae may participate

1 in the passage of STEC through mucosa. Initially, we expected that the parenteral
2 administration of colistin might prevent multiplication of *E. coli* in the lymph nodes and
3 therefore also might prevent the clinical signs of the disease. However, the numbers of
4 diseased piglets in the antibiotic-treated group were higher, the course of the disease was
5 more severe and more animals died in comparison with the untreated group, despite the fact
6 that colistin was apparently efficient. A similar effect has been observed in human infections
7 caused by STEC O157:H7, where the course of the disease was more complicated under
8 antibiotic therapy (Carter et al., 1987; Ostroff et al., 1989). We therefore propose that the
9 STEC lysed by colistin suddenly released the toxin from bacterial cells immediately after
10 their passage through the intestinal wall, which would explain a more severe course of
11 oedema disease in the treated piglets. Even though high amounts of STEC were present in the
12 lymph nodes from untreated piglets, the toxin was not released as abruptly because the
13 bacterial cells were not damaged. Our results did not rule out the possibility that the Stx2e
14 toxin is transported through the intestinal wall directly from bacteria colonising the intestinal
15 tract. Nevertheless, we propose that there exists an additional route of Stx2e release to the
16 bloodstream from the bacteria transported through mucosa where they are subsequently lysed
17 either abruptly by the action of colistin or slowly by the activity of the host's immune system.
18 This allows the toxin to be released to the bloodstream and cause the clinical signs of oedema
19 disease.

20

21

22 **Acknowledgement**

23 The work was supported by grant MZe 0002716201 of the Ministry of Agriculture of the
24 Czech Republic. We thank Ludmila Faldikova for translation and Eloise Kok for critical

1 grammatical correction of the manuscript. Ivan Rychlik is acknowledged for critical reading
2 of the manuscript.

3

4

5

6 **References**

7

- 8 Alexa, P., Hamrik, J., Salajka, E., Stouracova, K., Rychlik, I., 2000. Differentiation of
9 verotoxigenic strains of *Escherichia coli* isolated from piglets and calves in the Czech
10 Republic. *Vet. Med. - Czech.* 45, 39–43.
- 11 Alexa, P., Stouracova, K., Hamrik, J., Salajka, E., 2002. Gene typing of the colonisation
12 factors F18 of *Escherichia coli* isolated from piglets suffering from post-weaning oedema
13 disease. *Vet. Med. - Czech.* 47, 132–136.
- 14 Bertschinger, H.U., Gyles, C.L., 1994. Oedema disease of pigs. In: Gyles, C.L. (Ed.),
15 *Escherichia coli* in domestic animals and humans. CAB International, Wallingford, pp. 193–
16 219.
- 17 Carter, A.O., Borczyk, A.A., Carlson, J.A.K., Harvey, B., Hockin, J.C., Karmali, M.A.,
18 Krishnan, C., Korn, D.A., Lior, H., 1987. A severe outbreak of *Escherichia coli* O157:H7 -
19 associated hemorrhagic colitis in a nursing home. *New Eng. J. Med.* 317, 1496–1500.
- 20 Cheng, D.R., Sun, H.C., Xu, J.S., Gao, S., 2006. PCR detection of virulence factor genes in
21 *Escherichia coli* isolates from weaned piglets with edema disease and/or diarrhea in China.
22 *Vet. Microbiol.* 115, 320–328.

- 1 Frydendahl, K., 2002. Prevalence of serogroups and virulence genes in *Escherichia coli*
2 associated with postweaning diarrhoea and edema disease in pigs and a comparison of
3 diagnostic approaches. *Vet. Microbiol.* 85, 169–182.
- 4 Gannon, V.P.J., Gyles, C.L., Wilcock, B.P., 1989. Effects of *Escherichia coli* shiga-like
5 toxins (verotoxins) in pigs. *Can. J. Vet. Res.* 53, 306–312.
- 6 Gyles, C.L., 1994. Verotoxins and other cytotoxins. In: Gyles, C.L. (Ed.), *Escherichia coli* in
7 domestic animals and humans. CAB International, Wallingford, pp 365–398.
- 8 Lee, S.H., Cho, K.K., Kang, S.K., Kim, C.W., Park, H.C., Choy, Y.H., Choi, Y.J., 2002.
9 Detection of pigs resistant to post-weaning diarrhoea, oedema disease and porcine stress
10 syndrome by allele-specific polymerase chain reaction. *Animal Genetics*, 33, 237–239.
- 11 Meijerink, E., Neuenschwander, S., Fries, R., Dinter, A., Bertschinger, H.U., Stranzinger, G.,
12 Vogeli, P., 2000. A DNA polymorphism influencing alpha(1,2)fucosyltransferase activity of
13 the pig FUT1 enzyme determines susceptibility of small intestinal epithelium to *Escherichia*
14 *coli* F18 adhesion. *Immunogenetics*, 52, 129–136.
- 15 Osek, J., 1999. Prevalence of virulence factors of *Escherichia coli* strains isolated from
16 diarrheic and healthy piglets after weaning. *Vet. Microbiol.* 68, 209–217.
- 17 Osek, J., 2000. Clonal analysis of *Escherichia coli* strains isolated from pigs with post-
18 weaning diarrhea by pulsed-field gel electrophoresis. *FEMS Microbiol. Lett.* 186, 327–331.
- 19 Ostroff, S.M., Kobayashi, J.M., Lewis, J.H., 1989. Infections with *Escherichia coli* O157:H7
20 in Washington State - the 1st year of statewide disease surveillance. *J. Am. Med. Assoc.* 262,
21 355–359.

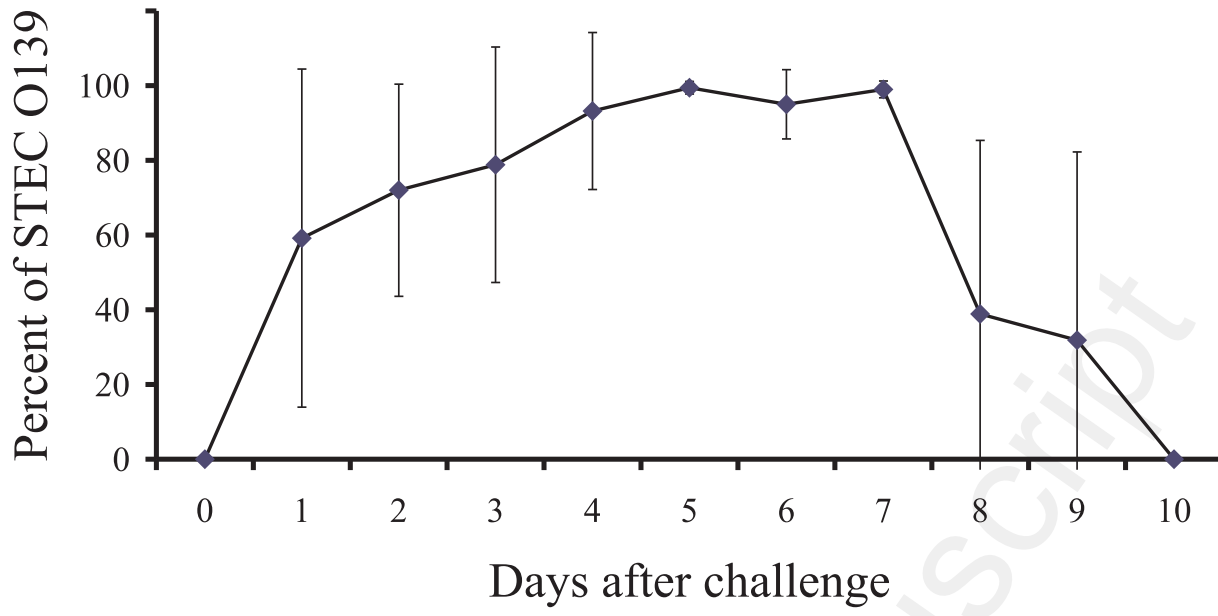
- 1 Rippinger, P., Bertschinger, H.U., Imberechts, H., Nagy, B., Sorg, I., Stamm, M., Wild, P.,
2 1995. Designations F18ab and F18ac for the related fimbrial type-F107, type-2134P and type-
3 8813 of *Escherichiacoli* isolated from porcine postweaning diarrhea and from edema disease.
4 Vet. Microbiol. 45, 281–295.
- 5 Salajka E. and Salajkova Z., 1987. Koliinfekce selat a telat. Ustav veterinarni osvety,
6 Pardubice, pp. 28–45.
- 7 Salajka, E., Salajkova, Z., Alexa, P., Hornich, M., 1992. Colonization factor different from
8 K88, K99, F41 and 987P in enterotoxigenic *Escherichia coli* strains isolated from
9 postweaning diarrhea in pigs. Vet. Microbiol. 32, 163–175.
- 10 Smith, H.W., Halls, S., 1968. The production of oedema disease and diarrhoea in weaned pigs
11 by the oral administration of *Escherichia coli*: factors that influence the course of the
12 experimental disease. J. Med. Microbiol. 1, 45–59.
- 13 Timoney, J.F., 1957. Oedema disease in swine. Vet. Rec. 69, 1160–1175.
- 14 Waddell, T.E., Lingwood, C.A., Gyles, C.L., 1996. Interaction of verotoxin 2e with pig
15 intestine. Infect. Immun. 64, 1714–1719.
- 16 Wittig, W., Klie, H., Gallien, P., Lehmann, S., Timm, M., Tschape, H., 1995. Prevalence of
17 the fimbrial antigens F18 and K88 and of enterotoxins and verotoxins among *Escherichia coli*
18 isolated from weaned pigs. J. Med. Microbiol. Virol. Parasitol. Infect. Dis. 283, 95–104.

1 Fig. 1: Percentage of STEC O139 in total amount of *E. coli* shedding through faeces from
2 piglets after challenge. The piglets were challenged on day 0 until day 3 with STEC
3 O139:F18ab, stx2e+ in a dose of 2×10^{11} CFU/day. A – antibiotic-treated group, B –
4 untreated group.

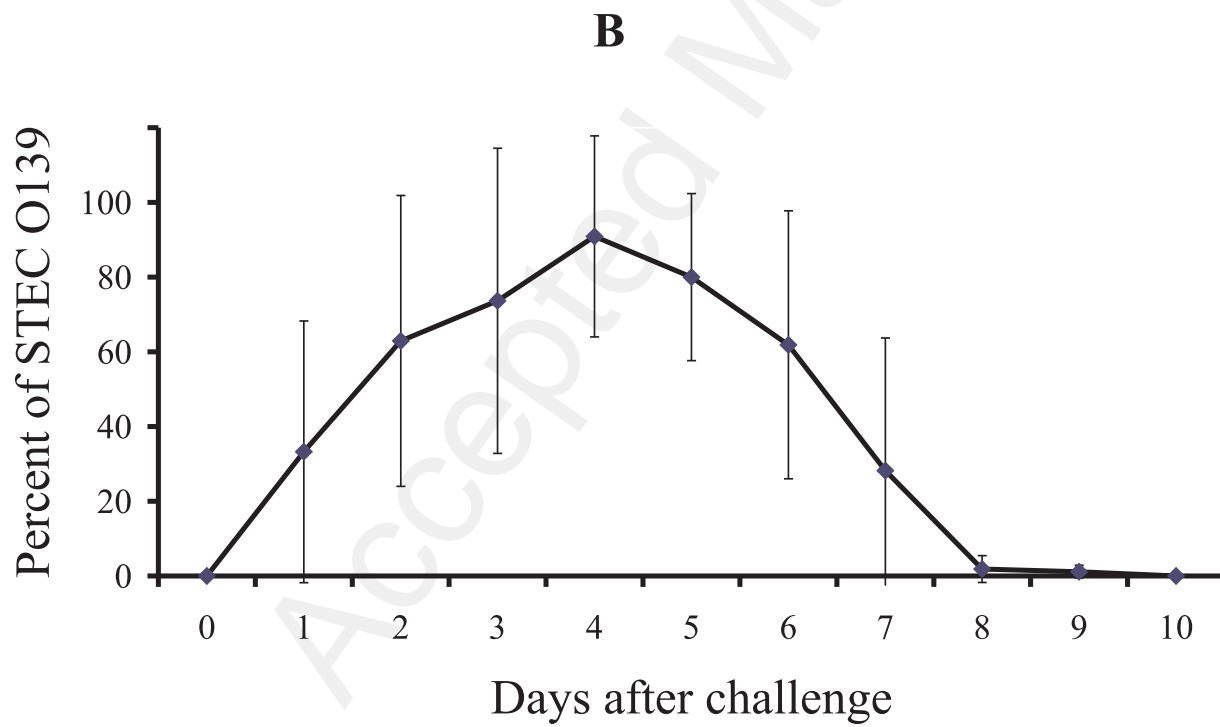
5

6 Fig. 2: Onset and duration of oedema disease in piglets after challenge. A – antibiotic-treated
7 group, B – untreated group. Only one and six piglets remained healthy during the trial in the
8 antibiotic-treated group and untreated group, respectively. Morbidity differences between
9 groups were $P < 0.05$, mortality differences $P > 0.05$.

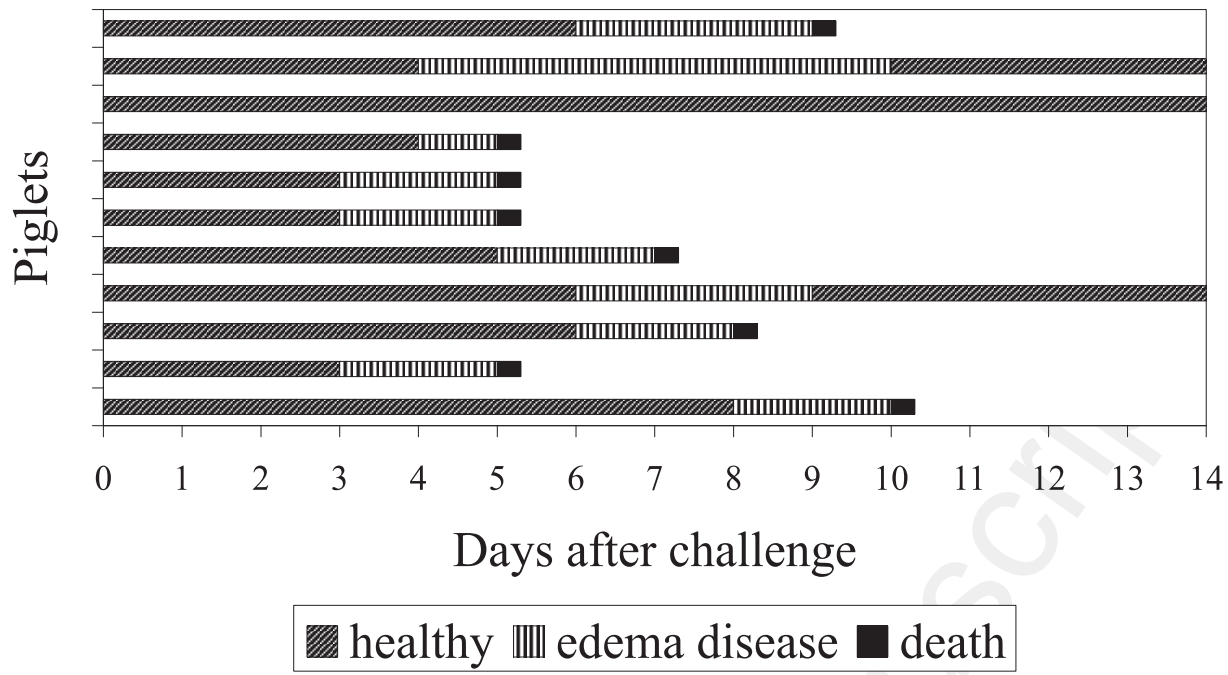
A



Accepted Manuscript



A



Accepted Manuscript

