



HAL
open science

Foot-and-mouth disease virus infection in young lambs: Pathogenesis and tissue tropism

Eoin Ryan, Jacquelyn Horsington, Stephanie Durand, Harriet Brooks, Soren Alexandersen, Joe Brownlie, Zhidong Zhang

► **To cite this version:**

Eoin Ryan, Jacquelyn Horsington, Stephanie Durand, Harriet Brooks, Soren Alexandersen, et al.. Foot-and-mouth disease virus infection in young lambs: Pathogenesis and tissue tropism. *Veterinary Microbiology*, 2008, 127 (3-4), pp.258. 10.1016/j.vetmic.2007.08.029 . hal-00532314

HAL Id: hal-00532314

<https://hal.science/hal-00532314>

Submitted on 4 Nov 2010

HAL is a multi-disciplinary open access archive for the deposit and dissemination of scientific research documents, whether they are published or not. The documents may come from teaching and research institutions in France or abroad, or from public or private research centers.

L'archive ouverte pluridisciplinaire **HAL**, est destinée au dépôt et à la diffusion de documents scientifiques de niveau recherche, publiés ou non, émanant des établissements d'enseignement et de recherche français ou étrangers, des laboratoires publics ou privés.

Accepted Manuscript

Title: Foot-and-mouth disease virus infection in young lambs:
Pathogenesis and tissue tropism

Authors: Eoin Ryan, Jacquelyn Horsington, Stephanie
Durand, Harriet Brooks, Soren Alexandersen, Joe Brownlie,
Zhidong Zhang



PII: S0378-1135(07)00432-4
DOI: doi:10.1016/j.vetmic.2007.08.029
Reference: VETMIC 3809

To appear in: *VETMIC*

Received date: 24-4-2007
Revised date: 23-8-2007
Accepted date: 24-8-2007

Please cite this article as: Ryan, E., Horsington, J., Durand, S., Brooks, H., Alexandersen, S., Brownlie, J., Zhang, Z., Foot-and-mouth disease virus infection in young lambs: Pathogenesis and tissue tropism, *Veterinary Microbiology* (2007), doi:10.1016/j.vetmic.2007.08.029

This is a PDF file of an unedited manuscript that has been accepted for publication. As a service to our customers we are providing this early version of the manuscript. The manuscript will undergo copyediting, typesetting, and review of the resulting proof before it is published in its final form. Please note that during the production process errors may be discovered which could affect the content, and all legal disclaimers that apply to the journal pertain.

1 **Foot-and-mouth disease virus infection in young lambs: pathogenesis and tissue**
2 **tropism**

3

4 Eoin Ryan^{a,b}, Jacquelyn Horsington^a, Stephanie Durand^a, Harriet Brooks^b, Soren
5 Alexandersen^c, Joe Brownlie^b, Zhidong Zhang^{a*}.

6

7 ^a Institute for Animal Health, Pirbright Laboratory, Ash Road, Pirbright, Woking,
8 GU24 0NF, UK.

9 ^b Royal Veterinary College, Hawkshead Lane, North Mymms, Hatfield, AL9 7TA,
10 UK.

11 ^c National Veterinary Institute, Danish Technical University, Lindholm, DK-4771
12 Kalvehave, Denmark

13

14 *Correspondence to Zhidong Zhang, Institute for Animal Health, Pirbright
15 Laboratory, Ash Road, Pirbright, Woking, GU24 0NF, UK.

16 Email Zhidong.Zhang@bbsrc.ac.uk; phone +44 (0)1483 231135; fax +44 (0)1483
17 232448.

18

19 **Abstract**

20

21 Foot-and-mouth disease (FMD) in adult sheep usually causes milder clinical signs
22 than in cattle or pigs, and is often subtle enough to go undiagnosed. In contrast, FMD
23 in lambs has been reported to cause high mortality during field outbreaks. In order to
24 investigate the pathogenesis of FMD in lambs, two groups, aged 10-14 days, were
25 infected with foot-and-mouth disease virus (FMDV) type O UKG. One group of
26 lambs (n=8) was inoculated with FMDV in the coronary band, while the other (n=4)
27 was infected by direct contact with FMDV-inoculated ewes. Daily serum samples and
28 temperature measurements were taken. Lambs were killed sequentially and tissue
29 samples taken for analysis. Using real-time RT-PCR, viral RNA levels in tissue
30 samples and serum were measured, and a novel strand-specific real-time RT-PCR
31 assay was used to quantify viral replication levels in tissues. Tissue sections were
32 examined for histopathological lesions, and *in situ* hybridisation (ISH) was used to
33 localise viral RNA within histological sections. The contact-infected lambs became
34 infected approximately 24 hours after the ewes were inoculated. Vesicular lesions
35 developed on the feet of all lambs and on the caudo-lateral part of the tongues of 6 of
36 the 8 inoculated lambs and 3 of the 4 contact-infected lambs. Although no lambs
37 developed severe clinical signs, one of the contact-infected lambs died acutely at 5
38 days post-exposure. Histological examination of the heart from this lamb showed
39 multi-focal areas of lymphocytic-plasmacytic myocarditis; similar lesions were also
40 observed in the hearts of three of the inoculated lambs. Using ISH, viral RNA was
41 localised within cardiac and skeletal muscle cells from the lamb which had died, and
42 also from vesicular lesions on the coronary band and tongue of inoculated lambs.

43 These results provide a detailed description of the pathogenesis of the disease in
44 lambs.

45 *Keywords:* foot-and-mouth disease virus; sheep; lamb; pathogenesis; *in situ*
46 hybridisation

47

48

Accepted Manuscript

49 **INTRODUCTION**

50

51 Foot-and-mouth disease (FMD) is a highly contagious acute vesicular disease of
52 cloven-hoofed animals. The aetiological agent, foot-and-mouth disease virus
53 (FMDV), is classified with the *Aphthovirus* genus as a member of the *Picornaviridae*
54 family (Belsham, 1993). FMD is an economically devastating disease, causing
55 significant production losses in infected domestic livestock. As a result, it is a major
56 hindrance to international trade in animals and animal products. The cost of an
57 outbreak can be enormous; the 2001 outbreak in the UK is estimated to have cost the
58 agricultural sector £3.1 billion, with similar losses to the tourism sector (Thompson *et*
59 *al.*, 2002).

60

61 Clinical signs are generally milder in sheep than in cattle or pigs. Viraemia may be
62 present for up to 3 days before the appearance of vesicular lesions (Alexandersen *et*
63 *al.*, 2003). During this time the sheep may be pyrexemic and distressed with lameness
64 spreading through the flock. Agalactia may occur in ewes. Vesicular lesions occur in
65 the interdigital cleft, along the coronary bands and on the bulb of the heels. Oral
66 lesions are less common but can occur on the dental pad, tongue and gums (Hughes *et*
67 *al.*, 2002). In pregnant sheep, transplacental infection of the foetal lamb may occur,
68 causing abortion (Ryan *et al.*, 2007).

69

70 Young lambs may die acutely following infection; associated clinical signs include
71 collapse, fever, tachycardia and marked abdominal respiration (Garcia-Mata *et al.*,
72 1954;1955; Geering, 1967; Pay, 1988). Deaths in lambs start to occur two to three
73 days after the appearance of clinical signs in the ewes, and are usually reported to be

74 the result of heart failure or starvation; post-mortem lesions include myocarditis,
75 septicaemia, abomasitis and enteritis (Littlejohn, 1970; Salyi 1939). Reported
76 mortality rates vary widely, from 4.7% in an outbreak in India (Panisup *et al.*, 1979)
77 to 94.5% in lambs of two to 25 days old in a Russian outbreak (Khankishiev *et al.*,
78 1958). Neonatal lamb deaths were reported in Dumfries during the 2001 outbreak in
79 the UK (Reid, 2002). A PanAsia type O virus strain was reported to have caused
80 large-scale lamb mortality in Iraq (Knowles and Samuel, 2003).

81

82 Mortality among FMD-infected calves and pigs has also been described. Death may
83 occur without vesicular lesions due to the peracute onset of FMD in these animals.
84 Pale foci of myocardial necrosis are seen in the ventricular wall and papillary muscle,
85 referred to as “tiger heart” due to striping effect (Jubb, 1993). Donaldson *et al.* (1984)
86 reported that the majority of piglets infected with an O₁ Lausanne strain died or
87 became moribund and were killed without developing vesicles. The deaths of the
88 piglets started before clinical disease was evident in the sows. Macroscopic “tiger
89 heart” lesions were not observed in any piglet hearts, although in all but one,
90 myocarditis was present on histopathological examination.

91

92 Despite the numerous reports of FMD-related deaths in lambs, there is little data
93 available on FMDV tropism or quantitative aspects of viral RNA kinetics in neonatal
94 lambs, which would help understand the reasons for this high mortality and the
95 influence of maternal infection on young lambs. In this study, viral distribution, tissue
96 tropism and associated pathology during the acute stages of FMD were investigated in
97 neonatal lambs experimentally infected with FMDV O UKG.

98

99 **MATERIALS AND METHODS**100 **Inoculum**

101 The FMDV strain used was O UKG 34/2001, isolated from a pig at Cheale Meats
102 Abattoir, Essex on 20 February 2001 (Alexandersen and Donaldson, 2002). The
103 inoculum was the second pig passage of original pig epithelial tissue suspension.

104 **Animal experiments**

105 Animals were housed in a category 4 bio-containment animal unit (Specified Animal
106 Pathogens Order, DEFRA 1998). Animal experimentation was carried out in
107 accordance with the UK Animals (Scientific Procedures) Act 1986 and associated
108 guidelines. Two separate experiments were carried out. The first involved inoculating
109 ewes and allowing their lambs to become infected by direct contact, simulating
110 natural infection in the field. In the second experiment, lambs were inoculated
111 directly.

112 **Experiment 1:** Ten lambs, 10-14 days old, and seven dams were used in this
113 experiment, with ewes numbered VM76 to VM82. Lambs were assigned the same
114 numbers as their dams, with the prefix LA for singletons or the first of a pair of twins,
115 and LB for the second of a pair of twins, i.e. LA76 to LB82. Two lambs and a ewe
116 were killed as negative controls before the inoculations were carried out. Eight lambs
117 were inoculated with $10^{5.9}$ FMDV O UKG 34/2001 in the coronary band. Two were
118 killed at 2, 4, 7, and 10 dpi, with the ewes being killed at the same timepoints as their
119 offspring.

120 **Experiment 2:** Five ewes, each with a lamb of 10-14 days, were used in this
121 experiment, with ewes numbered from VE37 to VE41. The lambs were assigned the
122 same numbers as their ewes, with the prefix L, i.e. L37 to L41. Negative control
123 samples of serum were taken from all animals and a ewe and lamb were killed as

124 negative controls prior to inoculation. Four ewes were inoculated by coronary band
125 inoculation with $10^{5.9}$ TCID₅₀ FMDV O UKG 34/2001. The ewes were housed in pens
126 in direct contact with their lambs. One ewe and her lamb were killed at two, three and
127 four days post-inoculation (dpi). The fourth infected lamb was found dead on the
128 morning of day five post-inoculation. The mother of this lamb was killed on day
129 seven.

130

131 **Sample collection**

132 Daily serum and nasal swab samples were collected from ewes and lambs and clinical
133 signs and temperatures recorded. At post-mortem examination, various tissue samples
134 were collected, as listed in Tables 1, 2, 4 and 5. Tissues collected from ewes included
135 cervical and mandibular lymph nodes (LN), heart, liver, mammary gland, soft palate,
136 spleen, tonsil, cotyledon, muscle (taken from lumbar area), tongue epithelium, uterus
137 wall and coronary band skin (from non-inoculated coronary band). Tissues collected
138 lambs included cervical and mandibular LNs, duodenal intestine, heart, kidney, liver,
139 caudal lung lobe, muscle (from lumbar area), skin from lateral hindleg, soft palate,
140 spleen, tongue, tonsil and coronary band skin (from non-inoculated coronary band). A
141 portion of each tissue was put in RNAlater (Ambion, UK) for RNA extraction, and
142 10% formalin (formol-FIXX, Shandon, UK) for histological examination and *in situ*
143 hybridisation as described below. Tissues were fixed in 10% formalin for less than 24
144 hours and then placed in 1% formalin, followed by embedding in paraffin wax.

145 **RNA extraction**

146 For automated RNA extraction from serum samples, 200 μ l of sample was mixed with
147 300 μ l MagNa Pure LC total nucleic acid lysis buffer (Roche, UK). Total nucleic

148 acids were extracted and eluted in 50 µl elution buffer by using the MagNa Pure LC
149 total nucleic acid isolation kit (Roche,UK) with an automated robotic workstation
150 (Roche), according to manufacturer's instructions, as described by Quan *et al.* (2004).
151 For tissue samples, 20 mg of tissue were homogenised by placing them in 700 µl of
152 tissue lysis buffer (Roche, UK) in Lysing Matrix D tubes (Q-Biogene, UK) and
153 shaking them at 6,500 revolutions per minute for 45 seconds three times in a FastPrep
154 FP120 homogenising machine (Q-Biogene, UK). RNA was extracted and eluted in 50
155 µl elution buffer by using the MagNa Pure LC RNA extraction kit III (Roche, UK)
156 with an automated robot as described above. Extracted RNA was stored at -80°C until
157 used.

158 **Real-time quantitative RT-PCR assay for detection of viral RNA.**

159 The level of viral RNA in tissue, serum and amniotic fluid samples was quantified by
160 real-time RT-PCR as described previously (Reid *et al.*, 2002), using a Taqman probe
161 specific for FMDV type O strain UKG 34/2001 as described previously (Quan *et al.*,
162 2004). PCR assays were performed on a Stratagene MX4000 machine. For the
163 generation of standard curves, a FMDV RNA standard was synthesized *in vitro* from
164 a plasmid containing a 500 base pair insert of the internal ribosomal entry site (IRES)
165 of FMDV O UKG 34/2001 (kindly provided by Dr G. Belsham, Institute for Animal
166 Health, UK) using a MEGAScrip™ T7 kit (Ambion, UK) as described previously
167 (Quan *et al.*, 2004).

168

169 **Detection of antibody in sera by ELISA**

170 A liquid-phase blocking ELISA was used to titrate levels of anti-FMDV antibodies in
171 serum samples, as described previously (Ferris *et al.*, 1990).

172

173 **Analysis of FMDV replication in tissues using strand specific real-time RT-PCR**

174 In order to analyse viral replication levels in tissue samples, a strand specific real-time
175 RT-PCR was used as previously described (Horsington and Zhang, 2007). A ratio of
176 positive to negative strands was calculated based on the quantification of levels of
177 positive and negative sense viral RNA transcripts in tissues. This ratio gives an
178 indication of the degree of viral replication in a sample, with a lower ratio indicating a
179 higher level of replication. Briefly, a tagged forward primer was designed containing
180 a 20 nucleotide ‘tag’ sequence unrelated to FMDV at the 5’ end with the rest of the
181 primer (20 bases) specific to the FMDV 3D negative strand. Similarly, a tagged
182 reverse primer was designed to target the FMDV 3D positive strand. cDNA was
183 produced using the Thermoscript (Invitrogen, UK) RT components. 6µl RNA was
184 combined with 1µl dNTPs, 0.3µl primer (Tag-3D7151F, 10µM or Tag-3D7251R,
185 10µM) and 4.7µl dH₂O, and heated to 75°C for 2 minutes. The reactions were then
186 placed on ice for 2 minutes. 4µl 5X cDNA synthesis buffer, 1µl 0.1M DTT, 1µl
187 RNaseOut, 0.5µl Thermoscript RT enzyme (all Invitrogen, UK) and 1.5 µl dH₂O was
188 combined and added to the samples. Reverse transcription was performed at 62°C for
189 35 minutes followed by 10 minutes at 95°C. Real-time quantitative PCR was
190 performed using TAG/3D7251R primers for the negative strand assay and
191 3D7151F/TAG primers for the positive strand assay and a FAM-TAMRA probe,
192 3D7196P, on the Stratagene 3005P real-time PCR machine (Stratagene, UK). 5µl
193 cDNA was combined with 12.5µl 2x Taqman Mastermix (Applied Biosystems, UK),
194 1µl each of the forward and reverse primer (10µM), 0.5µl probe (5µM) and dH₂O to
195 25µl. The program comprised of 2 minutes at 50°C, 10 minutes at 95°C, and 50 cycles
196 of 95°C for 15 seconds and 58°C for 1 minute. The standard curve was derived from

197 synthetic negative or positive strand FMDV transcripts from 1×10^8 to 1×10^1
198 copies/ μ l.

199 ***In situ* hybridisation**

200 **RNA probes and labelling**

201 A plasmid containing a part of the 3D region of FMDV type O UKG 34/2001 was
202 made and cells transfected with this plasmid kindly supplied by Nicholas Juleff,
203 Institute for Animal Health. The negative-sense RNA probe, complementary to the
204 positive-sense RNA of FMDV, generated from this plasmid was used on tissues from
205 experiment 1 (lambs LA76-LB82). A plasmid containing a part of the 3D region of
206 the FMDV type O Kaufbeuren strain genome (kindly provided by Dr G. Belsham,
207 Institute for Animal Health) was used to generate probe for use on tissues collected
208 from experiment 2 (lambs L37-L41). A plasmid containing part of the SVDV genome
209 was used to generate a control ISH probe.

210 The plasmids were linearised and then purified using phenol/chloroform extraction.
211 The RNA probes were synthesised from plasmid DNA and labelled with digoxenin
212 using a DIG RNA SP6/T7 labelling kit (Roche, UK) according to the manufacturer's
213 instructions.

214 **Hybridisation**

215 An mRNAlocatortm *In situ* hybridisation kit (Ambion, UK) was used to localise
216 FMDV in tissues. Sections (4 μ m) of the paraffin wax-embedded samples of fixed
217 tissues were applied to superfrost microscope slides (BDH, UK). They were incubated
218 at 56°C for 20 minutes to melt the paraffin, then put in xylene (BDH, UK) for 2x15
219 minutes at room temperature to dewax. The sections were put in 100% ethanol for

220 2x10 minutes, then 5 minutes each in 90%, 70% and 50% ethanol, followed by 5
221 minutes in phosphate buffered saline (PBS). Sections were immersed in 0.05%
222 proteinase K (70 U/ μ l) in PBS for 10 minutes at room temperature then rinsed in
223 nuclease-free water. Sections were then placed in a solution of 1.32% triethanolamine
224 and 0.5% HCl (Sigma, UK) in nuclease-free water for 3 minutes at room temperature,
225 followed by 10 minutes incubation in a solution of 1.32% triethanolamine, 0.5% HCl
226 and 0.24% acetic anhydride in nuclease-free water at room temperature. Slides were
227 washed for 5 minutes in PBS and placed in 100% ethanol for 5 minutes, then air
228 dried.

229
230 Hybridisation cover chambers (Sigma, UK) were applied to slides and overlaid with
231 40 μ l prehybridisation buffer, followed by incubation in a humid chamber at 60°C for
232 one hour. Hybridisation solution was prepared by adding 1 μ l of 100 ng/ μ l probe to
233 40 μ l of hybridisation buffer for each section. Each slide had two sections on it,
234 allowing one section to be overlaid with FMDV probe and the other with SVDV
235 probe as a negative control. Prehybridisation buffer was removed from the chambers,
236 then 40 μ l hybridisation solution added to each chamber. Slides were put on a hot
237 plate at 65°C for 5 minutes, then incubated in a humid chamber at 60°C overnight.

238
239 The following morning, coverslips were removed and sections were washed in 2x
240 saline-sodium citrate (SSC) for 30 minutes at 50°C, then 1x SSC for 30 minutes at
241 50°C. The slides were treated with 0.045% RNase A (450 U/ml) in 1x RNase
242 digestion buffer for 30 minutes at 37°C, then washed in 2x SSC for 30 minutes at
243 37°C. Slides were incubated in a blocking solution of 0.1% Triton X-100 (Sigma, UK)
244 and 2% normal sheep serum (Vector Laboratories, UK) in 100 mM Tris HCl (pH 7.5)

245 (BDH, UK) and 150 mM NaCl (BDH, UK) for 30 minutes at room temperature in a
246 humid chamber. Following this, sections were incubated for 1 hour at room
247 temperature in a humid chamber in an antibody solution of 0.1% anti-digoxenin
248 alkaline phosphatase sheep antibody (concentration 0.75 U/ μ l) (Roche, UK), 0.05%
249 Triton-X 100 and 1% normal sheep serum in 100 mM Tris HCl (pH 7.5) and 150 mM
250 NaCl.

251

252 Sections were then washed for 2x30 minutes in blocking solution with a gentle
253 shaker. They were incubated for 1 minute in a colouration buffer of 100mM Tris-HCl
254 (pH 9.5), 100 mM NaCl and 50 mM MgCl₂. A colour solution of 0.35% 5-bromo, 4-
255 chloro, 3-indolylphosphate (BCIP) (Boehringer Mannheim, Germany) and 0.45%
256 nitroblue tetrazolium (NBT) (Boehringer Mannheim, Germany) was added to the
257 colouration buffer and slides were incubated in this in a humid chamber for 1 hour. A
258 water wash stopped colouration. Slides were counterstained with methyl green
259 (Vektor Laboratories, Inc., USA) for 2 minutes 30 seconds at 60°C on heat block,
260 dipped in water, then mounted with Immumount (Thermoshandon Electron
261 Corporation, UK).

262

263 **RESULTS**

264

265 **Kinetics of viral RNA in ewes experimentally infected with FMDV**

266 All inoculated ewes developed signs of clinical signs of FMD within 1-2 dpi. The
267 kinetics of viral RNA in serum samples are shown in Fig. 1 with daily temperature
268 data. All inoculated ewes developed viraemia at 1 dpi (average 9.6 log₁₀ copies per
269 ml). Viral RNA levels then peaked at 2 dpi (average 10 log₁₀ copies per ml). The

270 tissue distribution of viral RNA in samples taken at post-mortem examination is
271 summarised in Table 1.

272

273 Ewes infected by direct contact with inoculated lambs developed viraemia from 2 to 3
274 days post inoculation of lambs, and this viraemia peaked at 3 dpi (average $7.5 \log_{10}$
275 copies per ml). Ewe VM76 (killed 2 dpi) did not develop viraemia, although viral
276 RNA was detected in four of the tissue samples from this sheep. Levels of viral RNA
277 in serum samples from these ewes are shown in Fig. 2, along with graphs of body
278 temperature illustrating pyrexia. The level of viral RNA in tissue samples collected at
279 post-mortem examination is summarised in Table 2.

280

281 **Clinical signs and gross lesions in lambs experimentally infected with FMDV**

282 All inoculated lambs had early-stage vesicles on the coronary band at 1 dpi. By the
283 following day, all had fully-developed pedal vesicles; one lamb (LB78) had lesions on
284 four feet, two had lesions only at the inoculation site (LA78 and LA81), while the
285 others had two lesions each on their coronary bands. By 3 dpi, all lambs had at least
286 three pedal lesions, and lamb LA80 had a lesion on its dental pad. Only lamb LA79
287 (killed at 2 dpi) had been lame. On day 4, most lesions had ruptured and were starting
288 to crust over; the following day, all lesions had begun to heal. By 7 dpi, the lesions on
289 the remaining four lambs had healed. At post-mortem examination, vesicles were
290 found on the lateral surfaces of the tongues at the level of the molars from one lamb at
291 2 dpi, and all lambs at 4 and 7 dpi. At 10 dpi, a healing lesion was seen on the lateral
292 tongue of one lamb. Daily temperature measurements for the lambs are shown in Fig.
293 3.

294

295 In lambs infected by direct contact, early lesions were observed in lambs from around
296 3 dpi. At post-mortem examination, lamb L40 (killed 3 dpi) had small vesicles on all
297 four feet, an erosive lesion on the lateral side of the tongue at the level of the molars,
298 and enlarged tonsils and cervical lymph nodes (CLN). Lamb L41 (killed 4 dpi) had
299 small vesicles on all four feet and a small erosion on the lateral surface of the tongue,
300 again at the level of the molars. It also had CLN enlargement. Lamb L38, which was
301 found dead on day 5, had vesicles on both fore-feet and three erosions on the tongue,
302 one on each lateral surface at the level of the molars and one on the dorsal surface of
303 the tongue. Daily temperature measurements for the lambs are shown in Fig. 4. It can
304 be seen that the three remaining lambs were pyrexia from 3 days after maternal
305 inoculation.

306

307 **Kinetics of viral RNA in lamb serum during the acute stage of FMD**

308 In inoculated lambs, levels of viral RNA in lamb serum samples, as measured by real-
309 time RT-PCR, are shown in Fig. 3. All lambs developed viraemia by 1 dpi. The
310 highest level was $10^{9.4}$ copies of viral RNA/ml serum, in lamb LA77 at 4 dpi. The
311 length of the viraemic period ranged from 2 days (lamb LA80) to 5 days (lamb
312 LB79).

313

314 In contact-infected lambs, viraemia was first detected at 2 dpi (Fig. 4) with serum
315 viral RNA levels peaking at 3 dpi. The levels of viral RNA detected in lamb serum at
316 2 dpi ranged from $10^{8.7}$ to $10^{10.4}$ copies per ml. The highest level measured was $10^{11.1}$
317 copies per ml, in lamb L38. By 4 dpi, no viral RNA was detected in the serum of lamb
318 L41, although no antibodies were detected in this serum sample. In contrast, lamb L38
319 still had a high level of viraemia at 4 dpi, with $10^{9.4}$ copies of viral RNA per ml.

320

321 **Antibody levels in serum from inoculated lambs**

322 Antibody titres detected in lamb serum from inoculated lambs are summarised in

323 Table 3. No antibodies were detected in serum from the contact-infected lambs.

324

325 **Distribution and quantification of viral RNA in lamb tissues**

326 The distribution of viral RNA in tissues from inoculated lambs is summarised in

327 Table 4. Viral RNA was detected in all tissues at 2 and 4 dpi. At 2 dpi, the highest

328 levels were found in the coronary band, tongue, skin, tonsil and CLN. At 4 dpi, there

329 was more variation between tissues, with the highest levels in the coronary band,

330 heart, CLN, mandibular lymph node (MLN), tongue, and tonsil. At 7 dpi, no viral

331 RNA was detected in the liver, and there was less in the other tissues than at earlier

332 timepoints. The tongue was the only exception to this, with an average of 10^{11}

333 copies/g. Other tissues with the most viral RNA at this timepoint were the coronary

334 band and the CLN. By 10 dpi, there was no viral RNA detectable in 7 tissue samples

335 from one lamb and 3 from the other. The tonsil, with an average of 10^{10} copies/g,

336 contained the highest amount of viral RNA.

337

338 In contact-infected lambs, levels of viral RNA detected in lamb tissues are

339 summarised in Table 5. Viral RNA was evenly distributed throughout tissues

340 collected at 2 dpi from L39, with the highest levels in the coronary band, tongue, soft

341 palate, CLN, MLN and tonsil. At 3 dpi (L40), the highest level of viral RNA was

342 found in the skin of the foot, followed by the tongue, CLN, MLN and soft palate. The

343 lamb (L41) killed at 4 dpi had cleared the viraemia by the time it was killed although

344 antibody titration by ELISA on its serum at 4 dpi was negative. Most of the tissue

345 samples contained low levels of viral RNA, and there was none detected in the heart.
346 Only the coronary band, tongue and tonsil contained 10^8 copies of viral RNA or more
347 per gram. This is in marked contrast to the lamb (L38) found dead at 5 dpi, which had
348 a significant viraemia on days 2, 3 and 4 and had high levels of viral RNA in many
349 tissue samples, particularly the heart and skeletal muscle, which each contained over
350 10^{10} copies of viral RNA per gram.

351

352 **Histopathology in the heart and muscle**

353 Cardiac histopathological lesions in infected lambs are shown in Fig. 5. Multiple foci
354 of myocardial abnormalities were observed in sections from lamb LA81 (directly
355 inoculated with FMDV) at 4 dpi, including pale and ruptured myocytes, disordered
356 myocytes, aggregations of lymphocytes and oedema (Figs. 5a, 5b). Similar lesions
357 were observed in heart muscle from lambs LA80 (killed 7 dpi) and LA78 (killed 10 dpi).
358 In sections of heart from the contact-infected lamb found dead on day five (L38) multi-focal
359 myocyte swelling, sometimes with hyalinisation, and focally marked perivascular
360 lymphocytic aggregation were described (Figs. 5c, 5d). No significant histological
361 abnormalities were recognised in sections of heart from the other contact-infected
362 lambs. In skeletal muscle sections from contact-infected lamb L38, disordered myocytes
363 with pale, foamy cytoplasm were recognised histologically.

365

366 **Localization of viral RNA in relation to histopathological lesions**

367 ISH was carried out on tissue sections to localise viral RNA in relation to
368 histopathological lesions. In heart sections from the contact-infected lamb found dead
369 on day five (L38), viral RNA was distributed throughout the myocardium in a diffuse

370 pattern, with positive signal found both in areas of cell swelling and in areas which
371 were unremarkable in H&E sections (Figs. 6a, 6b). The positive signal was found in
372 the cytoplasm of the cells. No positive signal was observed in heart sections from the
373 other contact-infected lambs. In addition, ISH on skeletal muscle sections from the
374 same lamb also showed viral RNA distributed throughout the sections in a multi-focal
375 array contrasting with the diffuse distribution seen in the myocardium (Figs. 6c, 6d).
376 No positive signal was found in the skeletal muscle sections from the other contact-
377 infected lambs. ISH was also performed on skin, tongue, soft palate, lymph nodes and
378 lung from all contact-infected lambs, but no positive signal was detected. Viral RNA
379 was also localised within vesicles in sections of tongue and coronary band from
380 inoculated lambs (Fig. 7). Positive signal can be seen within the lesions, deep to the
381 stratum corneum and in the detached epithelium of the coronary band lesion, and
382 diffusely throughout the two microvesicles in the stratum spinosum of the tongue.

383

384 **Analysis of viral replication levels in tissue samples using strand-specific real-** 385 **time RT-PCR assay**

386 Using strand-specific real-time RT-PCR, the ratios of positive to negative viral RNA
387 strands were calculated for each tissue sample from the lambs. Fig. 8(a) shows the
388 ratios for each tissue for each inoculated lamb, while Fig. 8(b) shows the ratios for
389 each tissue in contact-infected lambs. A lower ratio indicates active replication.
390 Where no ratio is shown, no negative strand viral RNA was detected, indicating little
391 or no replication was occurring in that tissue. Intermediate ratio levels are more
392 difficult to interpret, as negative viral RNA transcripts may be drained to some areas
393 via the lymphatic system or local circulation, without viral replication necessarily
394 taking place in these sites.

395

396 In the inoculated lambs at 2 dpi, negative strand viral RNA transcripts were detected
397 in most tissues. In the heart and muscle samples negative strand RNA was only
398 detected in samples from LA76, while negative strand RNA was only detected in the
399 liver in the sample from LA79; the ratio in these tissues was high. In all other tissues,
400 the ratio at 2 dpi was 100 or less. At 4 dpi, negative viral RNA strands were detected
401 in both lambs in the CB, CLN, MLN, spleen, tongue and tonsil, while negative
402 strands in the heart, kidney and skin were detected only in LA81. Only the intestine of
403 LA77 had detectable negative strand RNA. No replication was detected in the liver,
404 lung, muscle or soft palate at 4 dpi. At 7 dpi, negative viral RNA strands were
405 detected in the CB and tongue of both lambs, in the CLN of LA80 and in the kidney
406 and tonsil of LB79. Viral replication was not evident in other tissues at 7 dpi. At 10
407 dpi, negative viral RNA transcripts were detected in the tonsil of both lambs and the
408 soft palate of LB78 (Fig. 8a).

409

410 In the contact-infected lambs, only the CLN, MLN, tongue and tonsil had detectable
411 negative strand viral RNA at 2 days post maternal inoculation (lamb L39). The ratio
412 in the CLN was 11, while the other three ratios ranged from 416 to 1542. At 3 dpi, the
413 CB, tongue, CLN and MLN had detectable negative strand viral RNA, with the lowest
414 ratio in the tongue (ratio 33) (lamb L40). At 4 dpi, lamb L41 had detectable negative
415 strand viral RNA in the CB, tongue, tonsil and CLN, with the lowest ratio (45) in the
416 tongue. Lamb L38, found dead at 5 dpi, had detectable negative strand viral RNA in
417 every tissue except the liver and muscle. The ratios in the soft palate and tonsil were 7
418 and 6, respectively (Fig. 8b).

419 **DISCUSSION**

420

421 The experiments described here characterised the pathogenesis and development of
422 FMD in neonatal lambs infected with FMDV. The viral RNA levels in serum and in
423 tissues samples were quantified, and viral replication levels in various tissues was
424 analysed by a novel negative strand RT-PCR assay. Importantly, viral RNA was
425 localised in cardiac and skeletal muscle cells from a lamb which died of FMD,
426 confirming the tropism of the virus for these tissues. The results provide a detailed
427 description of the pathogenesis of the disease in lambs.

428

429 All four contact-infected lambs developed viraemia from 2 dpi. From this it can be
430 deduced that the lambs became infected with FMDV approximately 24 - 36 hours
431 after maternal inoculation. This allows time for the initial virus replication to occur in
432 the oropharynx, followed by dissemination to secondary sites of infection with
433 subsequent viraemia detectable at 2 dpi. Therefore, infecting lambs by contact with
434 inoculated ewes is likely to reflect the most common route of lamb infection in the
435 field during FMD outbreaks. Interestingly, the pattern of gross lesions on the tongue
436 in these lambs contrasts with that of older sheep and cattle, where lesions are more
437 common on the rostral tongue, gums and dental pad. It is thought that lesions are more
438 likely to develop at sites of trauma or intensive physical stress (Alexandersen *et al.*,
439 2003). When young lambs suckle the ewe, the sides of the tongue rub against the
440 molars whilst the dorsum of the tongue rubs against both the lower aspect of the teat
441 and the roof of the lamb's mouth. This may explain the difference in lesion
442 distribution. In the inoculated lambs, development of clinical signs appeared to be
443 more uniform than in the contact-infected lambs. Viraemia was present at 1 dpi in all

444 cases, with the level of viral RNA in serum ranging from $10^{6.6}$ to $10^{7.6}$ copies per ml.
445 The development of vesicles and onset of pyrexia was also similar in all inoculated
446 lambs. After 2 dpi, individual variation became apparent with the length of viraemia
447 varying from 2 days to 5 days. In inoculated lambs, lesions were observed on the
448 lateral aspects of the tongue at the levels of the molar teeth, as was observed in
449 contact-infected lambs. In contrast to contact infected lamb, however, no dorsal
450 tongue lesions were observed on any tongues from inoculated lambs. Furthermore, the
451 lingual lesions in contact-infected lambs appeared more severe than those in
452 inoculated lambs. This may be due to chance, but the route of infection may also have
453 influenced lesion location, as discussed above.

454

455 In investigating the kinetics of viraemia and viral RNA tissue distribution in lambs,
456 the results show that the acute-phase distribution of the virus is primarily to tissues
457 rich in epithelium such as the tongue and skin of the feet. Interestingly, the levels of
458 viral RNA found in tissue samples from inoculated lambs were generally much higher
459 than those in the contact-infected lambs. The highest level was in the coronary band at
460 2 dpi ($10^{13.43}$ copies/g) compared to a peak measurement of $10^{10.89}$ copies/g at 3 dpi in
461 contact-infected lambs. These higher concentrations of viral RNA are most likely to
462 be due to the coronary band inoculation of the lambs. The initial high infectious dose
463 administered was followed by local replication and dissemination to distant secondary
464 sites of replication, with accompanying viraemia.

465

466 The histological appearance of sections of heart from the contact-infected lamb found
467 dead on day five (L38) included multiple scattered foci of myocardiocyte swelling,
468 occasionally with hyalinisation, with perivascular mononuclear aggregation (Fig. 5).

469 The heart sections of the other contact-infected lambs had no significant histological
470 abnormalities. Histological abnormalities were evident in sections of the hearts of
471 inoculated lambs at 4 dpi (Fig. 5), and also at 7 and 10 dpi. In exploring if the
472 histological abnormalities observed in the heart is related to FMDV replication,
473 abundant viral RNA was detected by ISH in the heart and muscle of contact-infected
474 lamb L38, indicating that these tissues may act as sites of FMDV tropism in young
475 lambs. This is in agreement with similar work carried out in piglets (Donaldson *et al.*,
476 1984). It supports the theory that neonatal mortality following FMDV infection may
477 be due to viral replication in the heart, providing a plausible explanation for the
478 dramatic death rates often reported in young animals during an outbreak. In contrast
479 to the results from contact-infected lambs, no positive signal was detected in any
480 muscle or heart sections from inoculated lambs, despite histological evidence of
481 cardiac abnormalities. This may be due to the deterioration of viral RNA in tissue
482 samples during processing. Such deterioration may also be a factor in the lack of
483 positive signal in tissue sections from 7 and 10 dpi, but a more important explanatory
484 reason may be the presence of antibodies at these time-points.

485

486 The ratios of positive to negative strand viral RNA transcripts in tissue samples from
487 the lambs provided an indication of the levels of viral replication in those tissues.
488 Although a low ratio is likely to indicate viral replication in a tissue and a high or zero
489 ratio indicates little or no replication, interpretation of intermediate values is more
490 difficult. Negative strand viral RNA may be drained to a tissue (e.g. lymph node)
491 from other areas without replication necessarily occurring *in situ*. Nevertheless, this
492 novel technique provides a degree of insight into FMDV replication which has not
493 previously been available. The results in the inoculated lambs show that over time, the

494 number of sites of replication declined. Interestingly, by 10 dpi, the only tissues where
495 negative strand viral RNA transcripts were detected were the tonsil and soft palate.
496 The ratio in these tissues at 10 dpi was still quite low at around 100, indicating a
497 degree of replication comparable to that in the epithelial tissues at 2 and 4 dpi. The
498 tonsil has previously been identified as the site of FMDV persistence in sheep
499 (Burrows, 1968), although it has also been suggested that the close association of the
500 ovine tonsil with the overlying palatine epithelium could explain this (Alexandersen *et*
501 *al.*, 2003). Recent work in our laboratory has further supported this region as the site
502 of FMDV persistence in sheep (Horsington and Zhang, 2007). The low ratios found in
503 most tissues from inoculated lambs at 2 dpi show that, following inoculation with a
504 high dose of virus, negative strand viral RNA was detected at most sites in the body.
505 While replication might be expected at the recognised sites of viral replication such as
506 the coronary band, tongue, tonsil and soft palate, the low ratios in such tissues as the
507 kidney, intestine, heart, lung and spleen may indicate either viral replication at these
508 sites or negative strand viral RNA transported to these tissues via viraemic blood. In
509 the contact-infected group, viral replication occurred mainly in the epithelial tissues
510 and the CLN and MLN in the lambs killed at 2, 3 and 4 days after maternal
511 inoculation. This pattern is similar to that reported in other pathogenesis studies
512 (Burrows *et al.*, 1981), and is in contrast to the inoculated lambs, which had a wider
513 distribution of negative strand viral RNA.

514

515 The results from the ewes are also significant (Tables 1 and 2). This is the first report
516 we are aware of in which FMDV RNA loads in adult sheep tissues have been
517 quantified at various time-points after infection using real-time RT-PCR. Although
518 lambs are unlikely to infect ewes in the field (the reverse situation being more

519 probable), the data on transmission dynamics from inoculated lambs to in-contact
520 ewes provides a useful insight into the acute pathogenesis of FMD in sheep following
521 prolonged direct contact with infected cohorts. Viral RNA was first detected in two
522 ewes (VM78 and VM80) at 2 dpi. At 3 dpi, viraemia was detected in one more sheep,
523 while the remaining two became viraemic at 4 dpi. It is interesting that it took up to
524 four days for infection to be detected in some ewes, despite being in continuous direct
525 contact with their infected lambs. No viral RNA was detected in the serum of ewe
526 VM76, an unexpected result given the detection of viral RNA in four tissue samples.
527 It is likely that some viral RNA was present in the serum of this animal, but it may
528 have been below the limit of detection. Alternatively, the serum sample from 2 dpi
529 may have deteriorated during processing. By 10 dpi, the infection was waning and the
530 levels of viral RNA were lower, probably due to antibody clearance. In conclusion,
531 these studies of FMDV infection and replication *in vivo* provide a detailed description
532 of the patterns of virus load and distribution in lambs. It is clear that quantitative
533 analysis of viral load *in vivo* is a valuable tool in order to fully understand the
534 pathogenic steps of FMDV infection.

535

536 **Acknowledgements**

537 We would like to thank Yanmin Li, Pip Hamblin and Caroline Wright for performing
538 the antibody ELISAs and Nicholas Juleff for help with the ISH. We thank Colin
539 Randall, Bev Standish and Malcolm Turner for their assistance with and handling of
540 the animals. This work was funded by Defra, UK.

541 **References**

- 542 Alexandersen, S., Donaldson, A.I., 2002, Further studies to quantify the dose of
543 natural aerosols of foot-and-mouth disease virus for pigs. *Epidemiol. Infect.*
544 128, 313-323.
- 545 Alexandersen, S., Zhang, Z., Donaldson, A.I., Garland, A.J.M., 2003, The
546 pathogenesis and diagnosis of foot-and-mouth disease. *J. Comp. Pathol.* 129,
547 1-36.
- 548 Belsham, G.J., 1993, Distinctive features of foot-and-mouth disease virus, a member
549 of the picornavirus family; aspects of virus protein synthesis, protein
550 processing and structure. *Prog. Biophys. Mol. Biol.* 60, 241-260.
- 551 Burrows, R., 1968, The persistence of foot-and-mouth disease virus in sheep. *Journal*
552 *of Hygiene, Cambridge* 66, 633-640.
- 553 Burrows, R., Mann, J.A., Garland, A.J., Greig, A., Goodridge, D., 1981, The
554 pathogenesis of natural and simulated natural foot-and-mouth disease infection
555 in cattle. *J. Comp. Pathol.* 91, 599-609.
- 556 Donaldson, A.I., Ferris, N.P., Wells, G.A., 1984, Experimental foot-and-mouth
557 disease in fattening pigs, sows and piglets in relation to outbreaks in the field.
558 *Vet. Rec.* 115, 509-512.
- 559 Ferris, N.P., Kitching, R.P., Oxtoby, J.M., Philpot, R.M., Rendle, R., 1990, Use of
560 inactivated foot-and-mouth disease virus antigen in liquid-phase blocking
561 ELISA. *J. Virol. Methods* 29, 33-41.
- 562 Garcia-Mata,E., Federer,K.E., Pizzi,I., Aramburu,H. G., 1954, Pathogenicity of foot
563 and mouth disease virus in different species of unweaned animals. *Rev-Vet-*
564 *Milit.* 2, 205-206.
- 565 Garcia-Mata,E., Federer,K.E., Pizzi,I., Aramburu,H. G., 1955, Pathogenicity of foot
566 and mouth disease virus for new-born animals. *Gac-vet.* 17, 57-64.

567

568 Geering, W., G., 1967, Foot and mouth disease in sheep. *Aust. Vet. J.*

569 Horsington, J., Zhang, Z., 2007, Analysis of foot-and-mouth disease virus replication

570 using strand-specific quantitative RT-PCR. *J. Virol. Methods*, 144, 149-155.

571 Hughes, G.J., Mioulet, V., Kitching, R.P., Woolhouse, M.E., Alexandersen, S.,

572 Donaldson, A.I., 2002, Foot-and-mouth disease virus infection of sheep:

573 implications for diagnosis and control. *Vet. Rec.* 150, 724-727.

574 Jubb, K.V.F., Kennedy, P.C., Palmer, N., 1993, *Pathology of Domestic Animals*, Vol

575 2, 4th Edition. Academic Press, Inc., Page 143. London, 143 p.

576 Khankishiev, A., M., Gadshiev, K., S., Alekperov, Y., G., 1958, Foot and Mouth

577 Disease in New-Born Lambs. *Veterinariya, Moscow* 35, 59-60.

578 Knowles, N.J., Samuel, A.R., 2003, Molecular epidemiology of foot-and-mouth

579 disease virus. *Virus Res.* 91, 65-80.

580 Littlejohn, A., 1970, FMD in sheep - part 1. *State Veterinary Journal* 25, 3-12.

581 Panisup, A., S., Kalra D, S., Chauhan H. V, S., 1979, Investigation of an outbreak of

582 FMD in sheep. *Haryana Agricultural University Journal of Research* 9, 111-

583 114.

584 Pay, T.W., F., 1988, FMD in sheep and goats: a review. *FMD Bulletin* 26, 2-13.

585 Quan, M., Murphy, C.M., Zhang, Z., Alexandersen, S., 2004, Determinants of early

586 foot-and-mouth disease virus dynamics in pigs. *J. Comp. Pathol.* 131, 294-

587 307.

588 Reid, H.W., 2002, FMD in a parturient sheep flock. *Vet. Rec.* 150, 791.

589 Reid, S.M., Ferris, N.P., Hutchings, G.H., Zhang, Z.D., Belsham, G.J., Alexandersen,

590 S., 2002, Detection of all seven serotypes of foot-and-mouth disease virus by

591 real-time, fluorogenic reverse transcription polymerase chain reaction assay. J.
592 Virol. Methods 105, 67-80.

593 Ryan, E., Zhang, Z., Brooks, H.W., Horsington, J., Brownlie, J., 2007, Foot-and-
594 Mouth Disease Virus Crosses the Placenta and Causes Death in Fetal Lambs.
595 J. Comp. Pathol. In Press.

596 Salyi, G., 1939, Myocarditis in Foot and Mouth Disease of Young Lambs. Allatorv-
597 Lapok. 62,159-160.

598 Thompson, D., Muriel, P., Russell, D., Osborne, P., Bromley, A., Rowland, M.,
599 Creigh-Tyte, S., Brown, C., 2002, Economic costs of the foot and mouth
600 disease outbreak in the United Kingdom in 2001. Rev. Sci. Tech. Off. Int.
601 Epizoot. 21, 675-687.

602

603

604

1 **Table 1** Viral RNA in tissues from inoculated ewes.

dpi	Viral RNA load †				
	0	2	3	4	7
Ewe ID	VE37*	VE39	VE40	VE41	VE38
Cervical LN	0	7.6	5.41	7.44	4.67
Heart	0	5.81	0	2.73	2.28
Liver	0	7.09	6.77	0	0
Mammary gland	0	7.33	6.61	4.76	0
Mandibular LN	0	7.74	7.06	7.26	6.68
Muscle	0	7.08	4.21	5.65	5.44
Coronary band	0	9.05	8.7	7.02	7.83
Soft palate	0	8.27	7.18	7.93	5.7
Spleen	0	7.82	6.17	6.32	4.7
Tongue	0	8.2	7.71	7.15	5.67
Tonsil	0	8.68	8.0	8.65	6.69
Uterus	0	7.9	7.52	5.08	4.28

2
3 * uninfected ewe killed as a control and tissues collected for analysis.

4 † viral RNA loads in tissues were quantified by real-time RT-PCR and expressed as log₁₀ copy number
5 per g tissue

6 dpi: days post inoculation at the day the ewes were killed

7 LN: lymph node

8

9 **Table 2** Viral RNA in tissues from contact-infected ewes

dpi	Viral RNA load †						
	0	2	4	4	7	7	10
Ewe ID	VM82*	VM76	VM77	VM81	VM79	VM80	VM78
Cervical LN	0	7.19	11.46	9.68	10.15	8.23	7.86
Cotyledon	0	0	9.63	7.77	7.65	7.59	7.54
Heart	0	7.08	9.18	8.27	7.17	0	6.88
Liver	0	0	9.03	8.25	8.01	0	0
Mandibular LN	0	0	9.51	10.75	8.78	9.2	8.49
Muscle	0	0	8.78	7.9	8.43	7.48	6.31
Coronary band	0	0	8.77	10.45	9.57	11.2	8.79
Soft palate	0	0	8.39	9.67	9.53	8.15	7.25
Tongue	0	7.27	8.8	8.74	0	8.31	0
Tonsil	0	7.57	9.66	10.65	10.66	9.42	6.94

10

11 * uninfected ewe killed as a control and tissues collected for analysis.

12 † viral RNA loads in tissues were quantified by real-time RT-PCR and expressed as log₁₀ copy number

13 per g tissue

14 dpi: days post lamb inoculation at the day the ewes were killed

15 LN: lymph node

16

17
18
19**Table 3:** Serum antibody titres from inoculated lambs, measured by ELISA.

Lamb no.	Antibody titre										
	0 dpi	1 dpi	2 dpi	3 dpi	4 dpi	5 dpi	6 dpi	7 dpi	8 dpi	9 dpi	10 dpi
LA76	0	0	0								
LA79	0	0	0								
LA77	0	0	0	0	64						
LA81	0	0	0	0	0						
LB79	0	0	0	0	90	1448	724	1448			
LA80	0	0	0	0	90	256	362	1024			
LA78	0	0	0	0	0	1024	1024	724	1448	2896	1448
LB78	0	0	0	0	0	0	181	362	362	724	362

20

Accepted Manuscript

21 **Table 4** Viral RNA in tissues from inoculated lambs (expt. 1)

dpi	Viral RNA load †									
	0	0	2	2	4	4	7	7	10	10
Lamb ID	LA82*	LB82*	LA76	LA79	LA77	LA81	LB79	LA80	LA78	LB78
Coronary band	0	0	13.43	12.41	10.39	13.09	10.19	10.35	0	8.43
Cervical LN	0	0	11.25	9.85	9.77	9.59	7.79	9.52	8.18	9.12
Intestine	0	0	9.26	10.37	7.72	7.93	6.53	6.08	0	0
Heart	0	0	8.8	8.69	7.17	11.22	7.39	6.12	0	7.09
Kidney	0	0	9.91	9.73	8.0	7.94	7.35	7.07	0	0
Liver	0	0	8.93	8.56	6.23	7.42	0	0	0	6.04
Lung	0	0	10.58	10.4	7.15	8.19	6.45	6.08	0	3.83
Mandibular LN	0	0	9.97	10.02	9.52	10.28	8.45	7.51	8.66	8.55
Muscle	0	0	9.22	8.08	7.51	7.55	8.75	7.45	0	0
Skin	0	0	11.01	10.44	8.17	9.74	6.53	6.87	7.6	6.03
Soft palate	0	0	10.02	9.78	7.27	7.51	7.02	6.69	7.04	9.87
Spleen	0	0	9.93	9.61	9.1	9.27	7.46	7.41	7.88	8.12
Tongue	0	0	11.87	10.24	9.62	10.17	10.74	11.26	7.09	7.35
Tonsil	0	0	10.74	11.04	10.37	9.87	8.44	7.88	9.57	10.45

22

23 * uninfected lambs killed as controls and tissues collected for analysis.

24 † viral RNA loads in tissues were quantified by real-time RT-PCR and expressed as log₁₀ copy number

25 per g tissue

26 dpi: days post inoculation at the day the lambs were killed

27 LN: lymph node

28

29 **Table 5** Viral RNA loads in tissues from contact-infected lambs (expt. 2)

dpi	Viral RNA load †				
	0	2	3	4	5**
Lamb ID	L37*	L39	L40	L41	L38
Cervical LN	0	7.82	7.7	7.17	7.62
Heart	0	7.58	6.36	0	10.3
Liver	0	6.5	7.02	0	5.99
Mandibular LN	0	8.79	7.74	6.97	8.69
Muscle	0	6.78	6.81	4.39	10.48
Coronary band	0	8.41	10.89	8.87	8.92
Soft palate	0	7.53	7.82	7.04	7.3
Spleen	0	7.08	6.58	7.05	7.54
Tongue	0	7.31	8.27	8.06	8.72
Tonsil	0	8.5	7.2	8.22	7.72

30

31 * uninfected lamb killed as a control and tissues collected for analysis.

32

** lamb found dead at 5 dpi.

33

† viral RNA loads in tissues were quantified by real-time RT-PCR and expressed as log₁₀ copy number

34

per g tissue

35

dpi: days post maternal inoculation at the day the lambs were killed

36

LN: lymph node

37

38

39 **Figure 1:** Graphs showing FMDV RNA levels in serum samples and temperature
40 measurements from ewes inoculated with FMDV.

41

42 **Figure 2:** Graphs showing FMDV RNA levels in serum samples and temperature
43 measurements from ewes kept in direct contact with FMDV-inoculated lambs.

44

45 **Figure 3:** Graphs showing FMDV RNA levels in serum samples and temperature
46 measurements from lambs inoculated with FMDV.

47

48 **Figure 4:** Graphs showing FMDV RNA levels in serum samples and temperature
49 measurements from lambs kept in direct contact with FMDV-inoculated ewes.

50

51 **Figure 5:** Histological sections of heart stained with haematoxylin and eosin. (a) and
52 (b): Sections from lamb L38 (contact-infected, died 5 dpi) showing 40x and 63x
53 views of a focus of perivascular lymphocyte and plasma cell aggregation.

54 Myocardocytes are dispersed and disrupted. (c) Section from lamb LA81 (inoculated,
55 killed 4 dpi) showing 10x view of a poorly demarcated area plasmocytic-lymphocytic
56 aggregation within myocardium; (d) 40x view of area of mononuclear inflammation
57 with myocardocyte disruption, also from LA81. Foci dominated by myocardocyte
58 swelling sometimes with hyalinisation, but with less marked inflammatory cell
59 aggregation were also recognised (though are not shown in these photographs).

60

61 **Figure 6:** ISH performed on heart (a: 10x view, b: 63x view) and skeletal muscle (c:
62 10x view, d: 40x view) sections from lamb L38, (contact-infected, died 5 dpi).

63 Positive signal is diffusely distributed throughout the myocardium, while in the
64 muscle signal can be seen at several foci along multi-nucleated myocytes.

65

66 **Figure 7:** ISH performed on tongue and coronary band sections. **(a)** and **(b)**: Tongue
67 from lamb LA77 (inoculated, killed 4 dpi), 10x and 63x views respectively. **(c)**:

68 Tongue from lamb LA76 (inoculated, killed 2 dpi), 10x view; **(d)** coronary band from
69 LA76, 10x view. Positive signal can be seen diffusely distributed throughout the basal
70 zone of the tongue lesions, and in the subcorneal area of the coronary band lesion.

71

72 **Figure 8:** Graphs showing ratios of positive to negative strand viral RNA transcripts
73 in tissues from lambs. **(a)** Data from inoculated lambs; **(b)** data from contact-infected
74 lambs. A lower ratio indicates active replication. Where no ratio is shown for a
75 sample, no negative strand RNA was detected, indicating little or no viral replication.

76 CB: coronary band; CLN/MLN: cervical/mandibular lymph node.

77

78

79

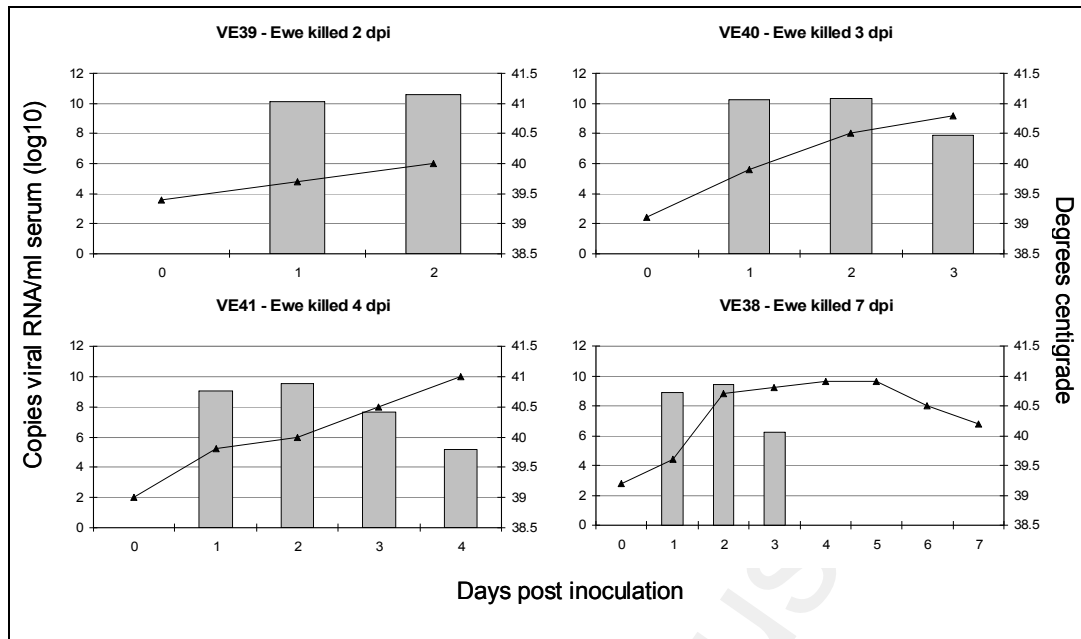


Figure 1: Graphs showing FMDV RNA levels in serum samples and temperature measurements from ewes inoculated with FMDV. FMDV RNA loads in serum samples are expressed as log₁₀ copy number per ml.

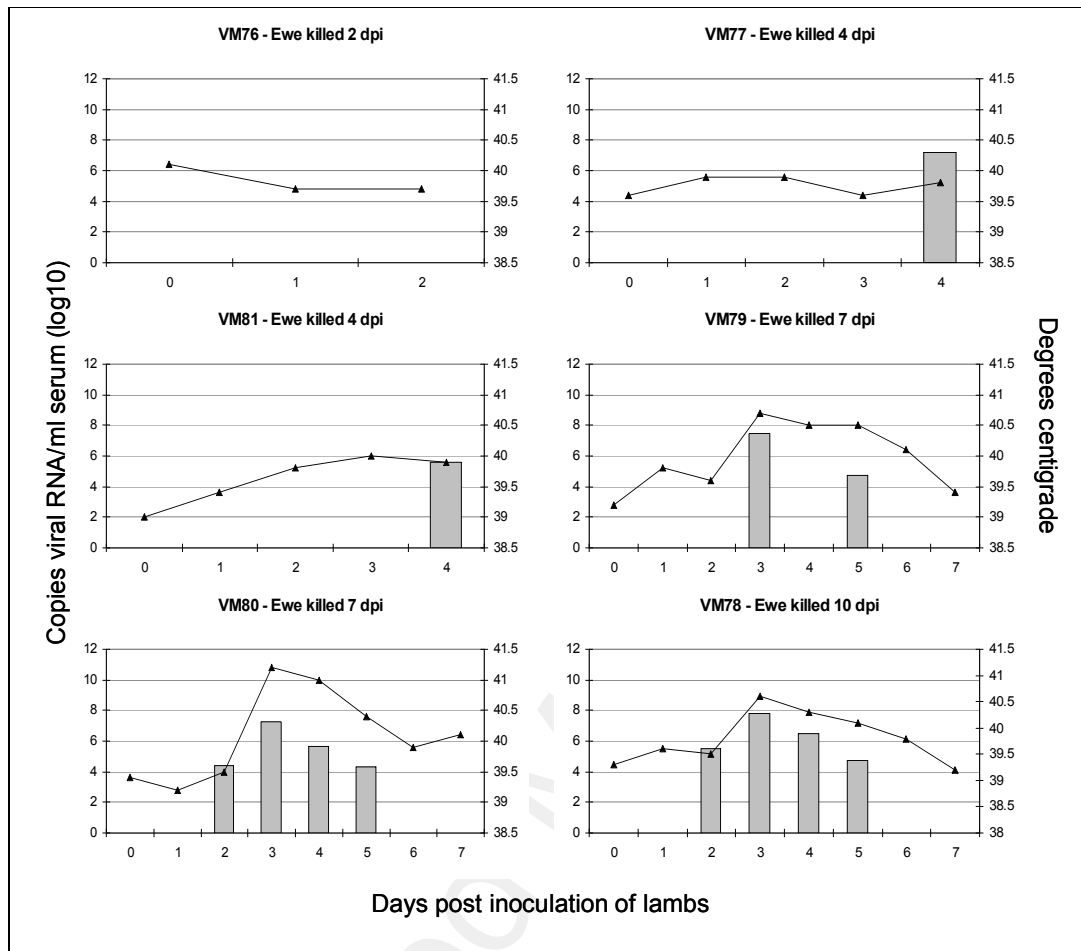


Figure 2: Graphs showing FMDV RNA levels in serum samples and temperature measurements from ewes kept in direct contact with FMDV-inoculated lambs. FMDV RNA loads in serum samples are expressed as log₁₀ copy number per ml

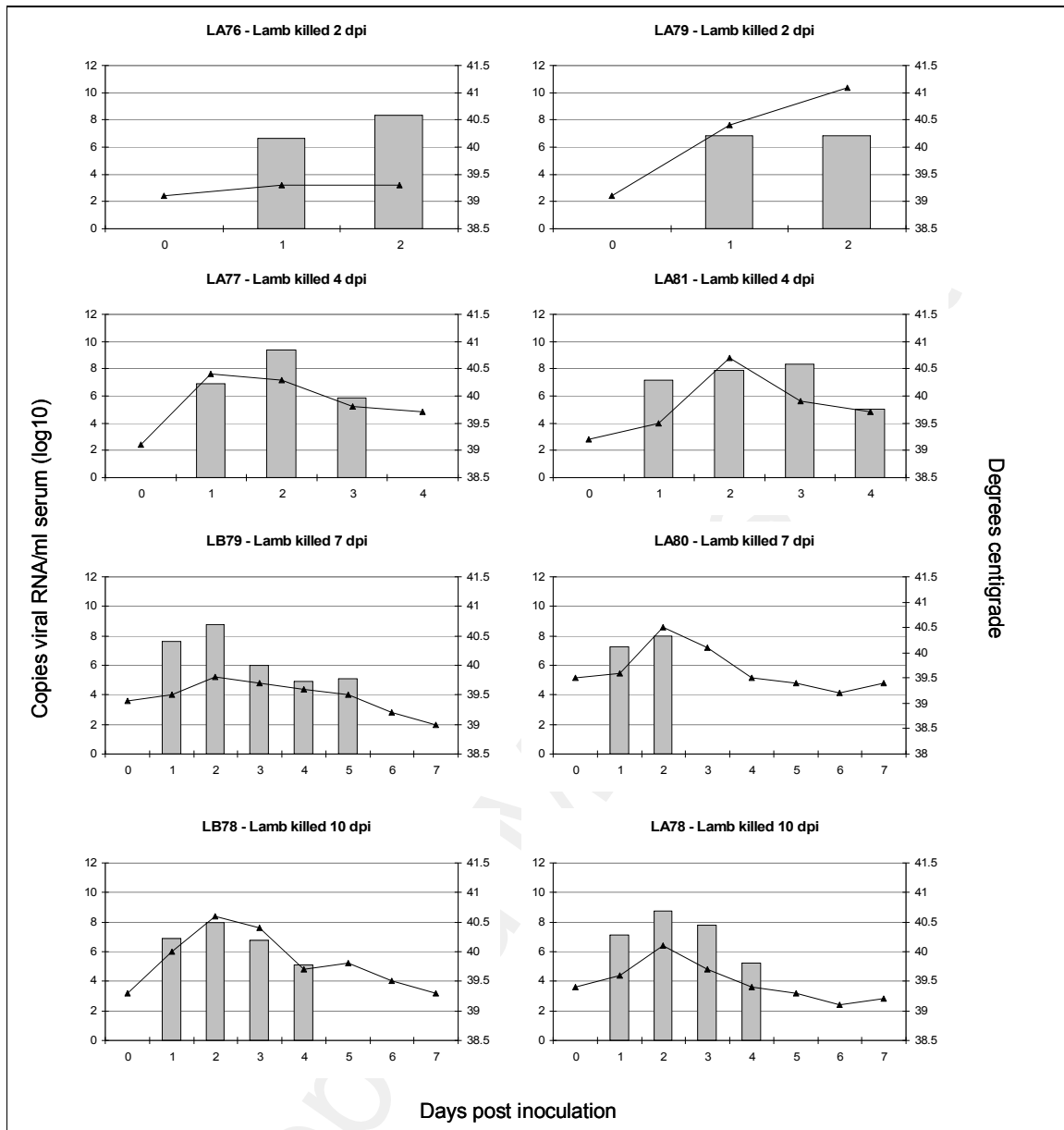


Figure 3: Graphs showing FMDV RNA levels in serum samples and temperature measurements from lambs inoculated with FMDV. FMDV RNA loads in serum samples are expressed as \log_{10} copy number per ml

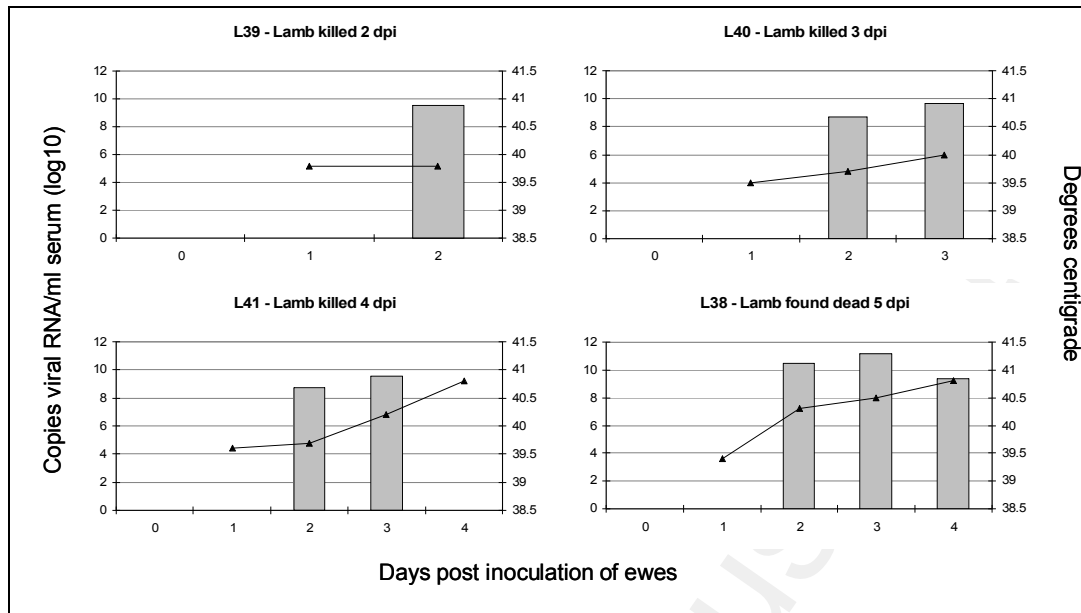


Figure 4: Graphs showing FMDV RNA levels in serum samples and temperature measurements from lambs kept in direct contact with FMDV-inoculated ewes. FMDV RNA loads in serum samples are expressed as log₁₀ copy number per ml

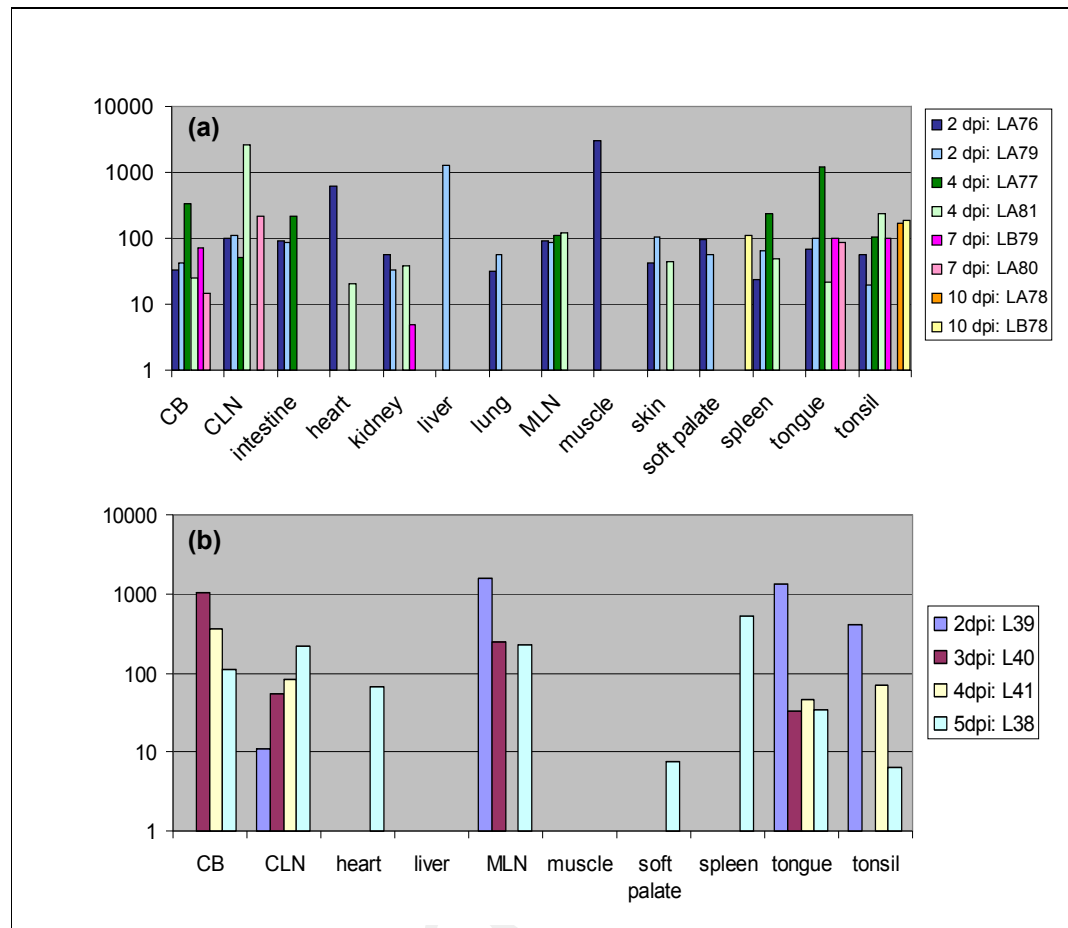
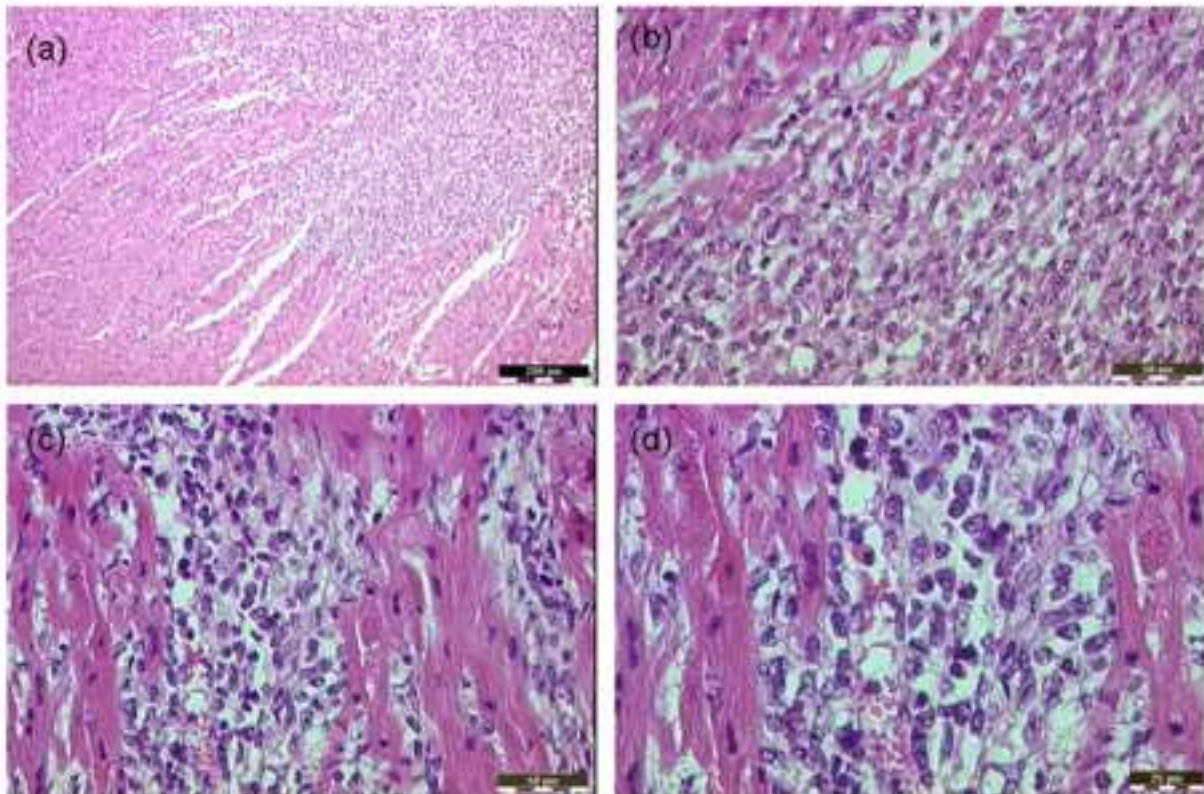
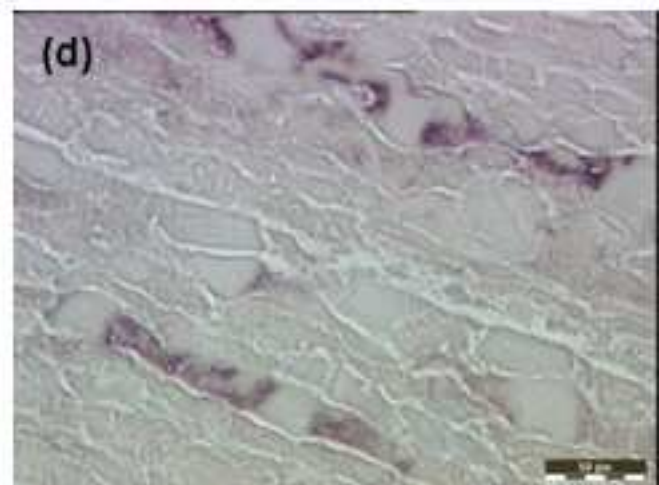
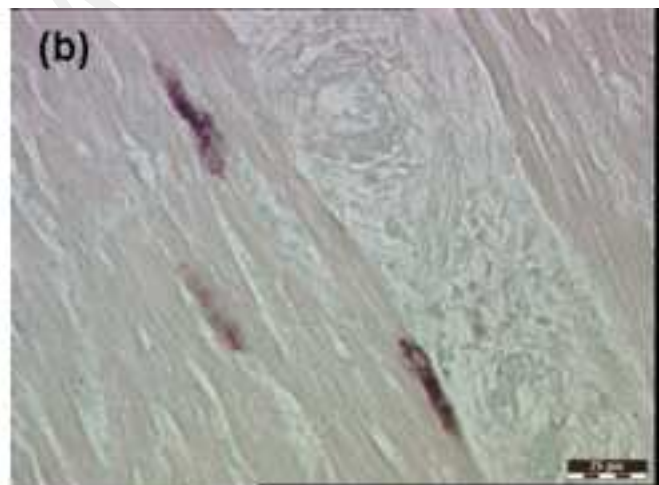



Figure 8: Graphs showing ratios of positive to negative strand viral RNA transcripts in tissues from lambs. **(a)** Data from inoculated lambs; **(b)** data from contact-infected lambs. A lower ratio indicates active replication. Where no ratio is shown for a sample, no negative strand RNA was detected, indicating little or no viral replication. CB: coronary band; CLN/MLN: cervical/mandibular lymph node.

Manuscript



Manuscript



Manuscript

