



HAL
open science

Malignant catarrhal fever-like lesions associated with ovine herpesvirus-2 infection in three goats

Björn Jacobsen, Kerstin Thies, Alexandra von Altrock, Christine Förster,
Matthias König, Wolfgang Baumgärtner

► **To cite this version:**

Björn Jacobsen, Kerstin Thies, Alexandra von Altrock, Christine Förster, Matthias König, et al..
Malignant catarrhal fever-like lesions associated with ovine herpesvirus-2 infection in three goats.
Veterinary Microbiology, 2007, 124 (3-4), pp.353. 10.1016/j.vetmic.2007.04.037 . hal-00532257

HAL Id: hal-00532257

<https://hal.science/hal-00532257>

Submitted on 4 Nov 2010

HAL is a multi-disciplinary open access archive for the deposit and dissemination of scientific research documents, whether they are published or not. The documents may come from teaching and research institutions in France or abroad, or from public or private research centers.

L'archive ouverte pluridisciplinaire **HAL**, est destinée au dépôt et à la diffusion de documents scientifiques de niveau recherche, publiés ou non, émanant des établissements d'enseignement et de recherche français ou étrangers, des laboratoires publics ou privés.

Accepted Manuscript

Title: Malignant catarrhal fever-like lesions associated with ovine herpesvirus-2 infection in three goats

Authors: Björn Jacobsen, Kerstin Thies, Alexandra von Altrock, Christine Förster, Matthias König, Wolfgang Baumgärtner



PII: S0378-1135(07)00219-2
DOI: doi:10.1016/j.vetmic.2007.04.037
Reference: VETMIC 3679

To appear in: *VETMIC*

Received date: 18-12-2006
Revised date: 16-4-2007
Accepted date: 25-4-2007

Please cite this article as: Jacobsen, B., Thies, K., von Altrock, A., Förster, C., König, M., Baumgärtner, W., Malignant catarrhal fever-like lesions associated with ovine herpesvirus-2 infection in three goats, *Veterinary Microbiology* (2007), doi:10.1016/j.vetmic.2007.04.037

This is a PDF file of an unedited manuscript that has been accepted for publication. As a service to our customers we are providing this early version of the manuscript. The manuscript will undergo copyediting, typesetting, and review of the resulting proof before it is published in its final form. Please note that during the production process errors may be discovered which could affect the content, and all legal disclaimers that apply to the journal pertain.

1 Malignant catarrhal fever-like lesions associated with ovine herpesvirus-2 infection in three
2 goats

3

4 Dr. Björn Jacobsen^a,

5 Dr. Kerstin Thies^b

6 Dr. Alexandra von Altröck^b

7 Christine Förster^c

8 Dr. Matthias König^c

9 Prof. Dr. Wolfgang Baumgärtner^a

10

11 ^aDepartment of Pathology, University of Veterinary Medicine Hannover, Bunteweg 17, D-
12 30559 Hannover, Germany

13 ^bClinic for Pigs, Small Ruminants, Forensic Medicine and Ambulatory Service, University of
14 Veterinary Medicine Hannover, Bischofsholer Damm 15, D-30173 Hannover, Germany

15 ^cInstitute of Virology, Faculty of Veterinary Medicine, Justus-Liebig-University Giessen,
16 Frankfurter Strasse 107, D-35392 Giessen, Germany

17

18 Corresponding author:

19 Prof. Dr. Wolfgang Baumgärtner, Ph.D.

20 Department of Pathology

21 University of Veterinary Medicine Hannover

22 Bunteweg 17

23 D-30559 Hannover

24 Tel: ++49-511-9538621

25 Fax: ++49-511-9538675

26 Email: wolfgang.baumgaertner@tiho-hannover.de

27 Abstract

28 This is the first description of malignant catarrhal fever-like lesions associated with
29 ovine herpesvirus-2 (OvHV-2) infection in goats with central nervous symptoms. The
30 diagnosis was based on typical histological lesions characterized by systemic
31 lymphohistiocytic and fibrinoid vasculitis and confirmed by polymerase chain reaction and
32 subsequent phylogenetic analysis of the detected OvHV-2 sequences.

33 Keywords

34 Ovine herpesvirus-2, Goats, Vasculitis, Malignant catarrhal fever

Accepted Manuscript

35 Introduction

36 Malignant catarrhal fever (MCF), a fatal lymphoproliferative disease of ruminant
37 species including domestic cattle and wild living ruminants, is caused by a group of closely
38 related gammaherpesviruses collectively referred to as malignant catarrhal fever viruses
39 (Callan and Van Metre, 2004). Epidemiologically, two primary forms of MCF in cattle have
40 been described with wildebeest-derived (WD)-MCF, caused by alcelaphine herpesvirus-1
41 (AlHV-1), primarily seen in Africa and the sheep-associated-MCF (SA-MCF) due to ovine
42 herpesvirus-2 (OvHV-2) in North America, Europe and Australia (Callan and Van Metre,
43 2004). In goats another gammaherpesvirus, termed caprine herpesvirus-2 (CpHV-2) was
44 identified (Li et al., 2001) causing MCF in white-tailed deer (Li et al., 2003) and in sika deer
45 (Keel et al., 2003) in the USA. MCF-like lesions or disease in goats have not been reported so
46 far. Interestingly, various ruminant species are susceptible to infection by MCF-viruses, but
47 only few develop characteristic lesions. This is also the case for goats, which can be infected
48 inapparently by OvHV-2 and CpHV-2 (Callan and Van Metre, 2004, Keel et al., 2003).

49 **Clinical signs similar to MCF have been observed in sheep under natural conditions, but**
50 **the conjunction with OvHV-2 was not confirmed by laboratory tests (Rae, 1994).**

51 Experimentally, MCF-like disease was induced in sheep after aerosol inoculation with OvHV-
52 2 (Li et al., 2005). MCF was also described in Barbary sheep (Yeruham et al., 2004) and pigs
53 (Loken et al., 1998) identifying OvHV-2 by PCR as the presumable causative agent.

54 Here we describe MCF-like lesions in goats with OvHV-2-infection as confirmed by
55 PCR and nucleic acid sequencing.

56 Results and discussion

57 Three female goats, two German Improved Fawn breed (No. 1, 3.5 years old; No. 2, 7
58 years old) and one dwarf goat (No. 3, 5 month old) originated from two different **flocks**
59 **consisting of three goats and five sheep, and three dwarf goats, respectively.** All three
60 animals showed fever and central nervous disorders including ataxia, tonic-clonic spasm,
61 disorientation and tremor of the head. Animal No. 3 displayed diarrhea and cloudy corneas in
62 both eyes. Goat No. 1 was euthanized by the local veterinary surgeon after 7 days of clinical
63 disease, goat No. 2 and No. 3 died after 22 and 23 days of illness, respectively. At necropsy,
64 the animals showed enlargement of lymph nodes, spleen and liver, pulmonary congestion and
65 multifocally distributed tiny white spots in liver and kidney. Goat No. 3 displayed, in
66 addition, an erosive, ulcerative esophagitis. Histopathology on hematoxylin and eosin stained
67 sections revealed a lymphohistiocytic vasculitis with fibrinoid necrosis of vessel walls in
68 several organs including lymph nodes, liver, kidney, brain, retina, and rete mirabile (Figure
69 1). Additionally, a granulomatous pneumonia due to parasites (No. 1), lymphohistiocytic
70 meningitis (No. 1), pericholangitis (No. 2) and a multifocal ulcerative lymphohistiocytic
71 esophagitis (No. 3) were observed.

72 Immunohistochemically, antigen for Borna disease virus, porcine herpesvirus-1,
73 *Toxoplasma gondii* and *Neospora caninum* were not detectable. By immunofluorescence
74 microscopy antigens of rabies and pestiviruses were not found.

75 **Samples from different organs (goat No. 1: brain, kidney; goat No. 2: brain,**
76 **cornea, lymph node, blood; goat No. 3: brain, mesenteric lymph node, spleen) were used**
77 **for two different PCR set ups.** Primers targeting the tegument region of OvHV-2 were taken
78 from the literature (Baxter et al., 1993). For the glycoprotein B region of OvHV-2 and CpHV-
79 2 primers were designed using the primer express software (ABI, Langen, Germany). The
80 primer pair designated GlycoF02 (5'TCYGCCAAGCGMATCG3') and GlycoR01
81 (5'ACCGTGCTCATGCGCTT3') amplified a 424bp fragment. **Upon gel electrophoresis all**

82 **samples showed DNA bands at the expected size. Positive controls for OvHV-2**
83 **originated from the brain of a cow that died after showing clinical signs of MCF and**
84 **peripheral blood lymphocytes from an inapparently infected goat for CpHV-2.** Obtained
85 reaction products were cloned and sequenced. Comparison to nucleotide sequences of the
86 glycoprotein B region of other herpesviruses retrieved from the gene bank revealed
87 similarities of 99.04-99.68% for OvHV-2 and 83.93% for CpHV-2, respectively. Based on the
88 DNA sequences of the glycoprotein B fragment including several other members of the
89 gammaherpesvirinae pair wise genetic distances were calculated using the Kimura 2-
90 parameter method (Kimura, 1980) and a phylogenetic tree was constructed applying the
91 neighbour-joining method (Felsenstein, 1985) from the PHYLIP software package
92 (University of Washington, Seattle, USA) (Figure 2). Phylogenetic analysis based on
93 amplicons from the tegument region led to the same results (data not shown).

94 Clinically, these animals showed central nervous disorders, increased body temperature,
95 pleocytosis and diarrhea. Similar signs have been described for cattle (Callan and Van Metre,
96 2004). Frequent clinical signs in bovine include persistent high fever and lymph node
97 enlargement, whereas the intestinal form characterized by diarrhea is less often observed in
98 this species (Callan and Van Metre, 2004). Neurological signs in bovine are less frequent and
99 typically appear in the terminal stages of the disease. Affected animals are lethargic and
100 appear obtunded (Callan and Van Metre, 2004). In the cerebrospinal fluid there is a marked
101 pleocytosis (Plowright, 1990). Though animal No. 3 displayed a cloudy cornea, characteristic
102 lesions of the “head-and-eye”-form described for cattle were not seen in these goats.
103 Macroscopically, all three goats showed enlargement of lymph nodes and visceral organs with
104 tiny white spots in liver and kidney. One animal displayed ulcerations and erosions of the
105 esophagus. Similar findings have been reported for MCF in cattle (Plowright, 1990).
106 Histopathologically, the animals showed lymphohistiocytic vasculitis with fibrinoid necrosis
107 in several organs. In cattle this regarded as almost pathognomonic for MCF (Callan and Van

108 Metre, 2004). Vasculitis in bovines, similar to the present cases, is segmental and irregular in
109 distribution, most readily seen in medium-sized arteries invariably accompanied by
110 perivascular and intramural infiltration of mononuclear cells (Plowright, 1990). Frequently,
111 there is fibrinoid degeneration of infiltrated mural tissues and smooth muscle elements of
112 vessel walls. Vascular lesions appear to have predilection sites including kidney, brain and the
113 rete mirabile of the hypophysis (Plowright, 1990). Until now, such disease pattern has not
114 been described in goats.

115 Though the pathology of MCF is well documented, the pathogenesis still is poorly
116 understood. Studies suggest a lymphoproliferative disorder involving the dysregulation of T-
117 lymphocytes (Callan and Van Metre, 2004). In addition, there is evidence that MCF presents
118 an immunopathological process (Plowright, 1990). The essential defect in MCF pathogenesis
119 appears to be an immune deregulation attributable to a dysfunction of Natural Killer cells and
120 uncontrolled proliferation of lymphoblastoid elements in many tissues (Plowright, 1990).
121 Whether MCF-lesions are due to a type III or Arthus-like hypersensitivity reaction is still
122 discussed controversially (Plowright, 1990). Most episodes of spontaneous SA-MCF in cattle
123 appear to be a sequel of close contact to infected sheep actively shedding the agent (Metzler,
124 1991). Goat No. 1 and No. 2 were kept together with sheep. Though, goat No. 3 was kept
125 together with sheep too, direct contact has been ruled out by the owner. However, there is
126 evidence that OvHV-2 transmission can occur over distances (Callan and Van Metre, 2004).

127 Confirmatory diagnosis was based on the histological demonstration of a generalized
128 lymphohistiocytic vasculitis in multiple organs, including the brain. Since members of the
129 gammaherpesvirinae in general cannot be propagated easily in cell culture, PCR represents
130 the method of choice to facilitate a direct diagnosis of viral infection. **Infections of goats**
131 **with both OvHV-2 and CpHV-2 have been reported (Li et al., 2001, Metzler, 1991).**
132 **However, data with regard to the prevalence of both agents in the goat population are**
133 **limited. On the other hand OvHV-2 and CpHV-2 are well known as agents of MCF in**

134 various ruminant species including cattle, deer and Barbary sheep (Li et al., 2003, Keel
135 et al., 2003, Yeruham et al., 2004, Plowright, 1990), however, MCF or MCF-like lesions
136 have not been described in goats so far. Unfortunately, data of the OvHV-2 status of the
137 sheep and unaffected goats from both flocks are not available. Experimental infections
138 demonstrated the crucial role of the viral dose with regard to disease development in
139 sheep and in cattle (Li et al., 2005, Taus et al., 2006). The latter studies suggested that a
140 high viral burden correlates with the development of clinical MCF and histological
141 lesions (Taus et al., 2006, Li et al., 2005). If a similar pathogenesis applies to OvHV-2
142 infection in goats remains to be investigated in further studies.

143 This is the first known description of MCF-like lesions in goats associated with an
144 infection with OvHV-2. Diagnosis of OvHV-2 was established by PCR and confirmed by
145 nucleotide sequencing. Phylogenetic analysis, based on two different regions of the genome,
146 identified the viruses detected in three infected goats as OvHV-2 that is clearly separated from
147 known caprine herpesviruses. Although the etiological role of the viruses found independently
148 in goats with signs of MCF was not formally established, it is likely that OvHV-2 was
149 responsible for disease induction and played an essential role in the pathogenesis of the
150 lesions. **However, further studies are required to establish a causal relationship between**
151 **the observed clinic, lesions and OvHV-2 infection.**

152 Acknowledgements

153 Bjoern Jacobsen was supported by a scholarship of the Friedrich-Ebert-Foundation,

154 Germany.

Accepted Manuscript

155 References

- 156 Baxter, S. I., Pow, I., Bridgen, A., Reid, H. W., 1993. PCR detection of the sheep-associated
157 agent of malignant catarrhal fever. *Arch Virol.* 132, 145-159.
- 158 Callan, R. J., Van Metre, D. C., 2004. Viral diseases of the ruminant nervous system. *Vet Clin*
159 *North Am Food Anim Pract.* 20, 327-362.
- 160 Felsenstein, J., 1985. Confidence limits on phylogenies: an approach using the bootstrap.
161 *Evolution* 39, 738-791.
- 162 Keel, M. K., Patterson, J. G., Noon, T. H., Bradley, G. A., Collins, J. K., 2003. Caprine
163 herpesvirus-2 in association with naturally occurring malignant catarrhal fever in captive
164 sika deer (*Cervus nippon*). *J Vet Diagn Invest.* 15, 179-183.
- 165 Kimura, M., 1980. A simple method for estimating evolutionary rates of base substitutions
166 through comparative studies of nucleotide sequences. *J Mol Evol.* 16, 111-120.
- 167 Li, H., Keller, J., Knowles, D. P., Crawford, T. B., 2001. Recognition of another member of
168 the malignant catarrhal fever virus group: an endemic gammaherpesvirus in domestic
169 goats. *J Gen Virol.* 82, 227-232.
- 170 Li, H., Wunschmann, A., Keller, J., Hall, D. G., Crawford, T. B., 2003. Caprine herpesvirus-
171 2-associated malignant catarrhal fever in white-tailed deer (*Odocoileus virginianus*). *J Vet*
172 *Diagn Invest.* 15, 46-49.
- 173 Li, H., O'Toole, D., Kim, O., Oaks, J. L., Crawford, T. B., 2005. Malignant catarrhal fever-
174 like disease in sheep after intranasal inoculation with ovine herpesvirus-2. *J Vet Diagn*
175 *Invest.* 17, 171-175.
- 176 Loken, T., Aleksandersen, M., Reid, H., Pow, I., 1998. Malignant catarrhal fever caused by
177 ovine herpesvirus-2 in pigs in Norway. *Vet Rec.* 143, 464-467.
- 178 Metzler, A. E., 1991. The malignant catarrhal fever complex. *Comp Immunol Microbiol*
179 *Infect Dis.* 14, 107-124.

- 180 Plowright, W., 1990. Malignant Catarrhal Fever Virus. In: Dinter, Z. and Morein, B. (Eds.),
181 Virus Infections of Ruminants. Elsevier Science Publishers B. V., Amsterdam, pp. 123-
182 150.
- 183 **Rae, C. A., 1994. Lymphocytic enteritis and systemic vasculitis in sheep. Can Vet J. 35,**
184 **622-625.**
- 185 **Taus, N. S, Oaks, J. L., Gailbreath, K., Traul, D. L., O'Toole, D., Li, H., 2006.**
186 **Experimental aerosol infection of cattle (*Bos taurus*) with ovine herpesvirus 2 using**
187 **nasal secretions from infected sheep. Vet Microbiol 116, 29-36.**
- 188 Yeruham, I., David, D., Brenner, J., Goshen, T., Perl, S., 2004. Malignant catarrhal fever in a
189 Barbary sheep (*Ammotragus lervia*). Vet Rec. 155, 463-465.

190 Figure captions

191 Figure 1:

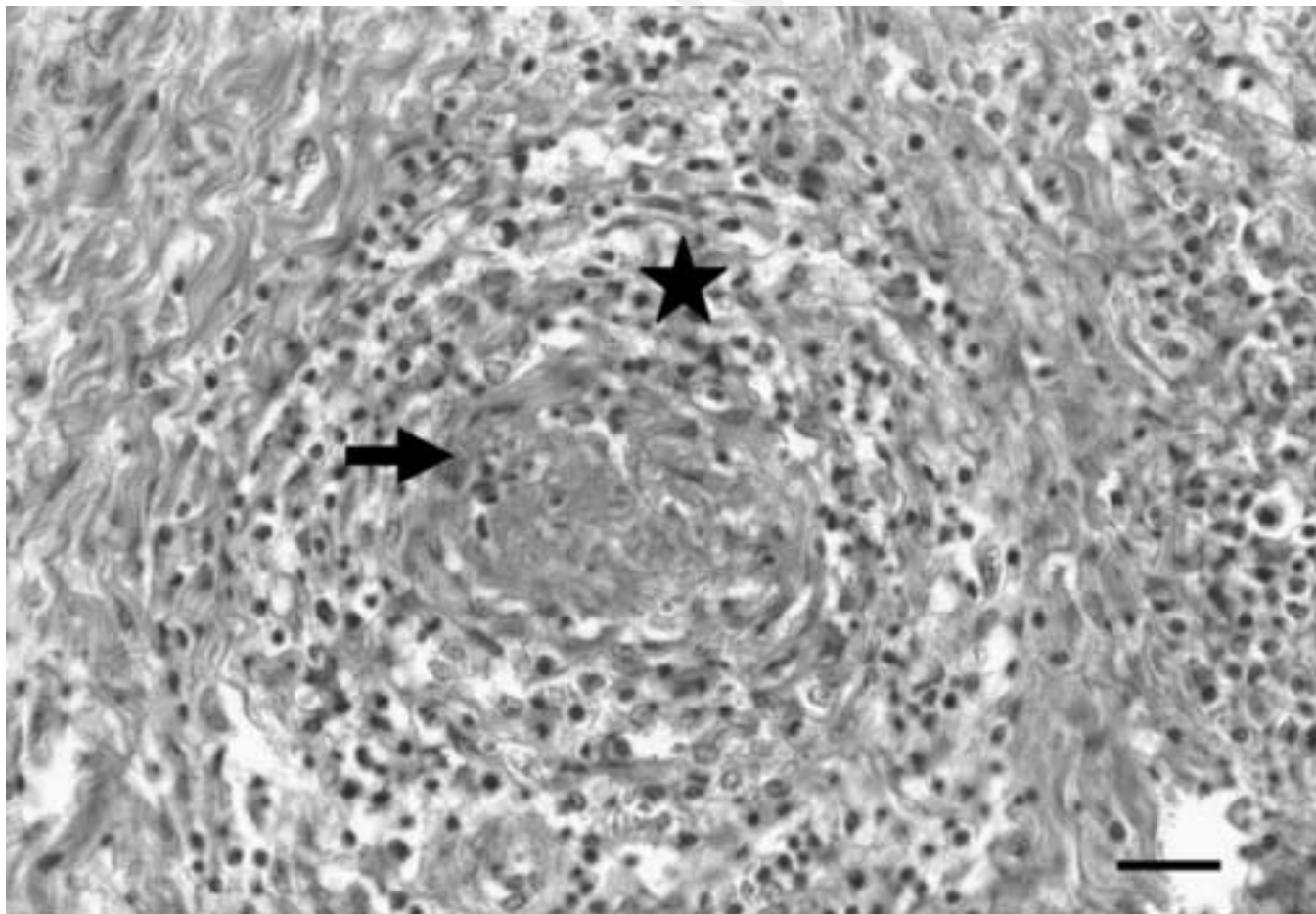
192 Lymphohistiocytic vasculitis (star) with fibrinoid necrosis (arrow) in a medium-sized artery,
193 kidney, hematoxylin and eosin. Bar 50µm.

194

195 Figure 2:

196 Phylogenetic analysis of the glycoprotein B sequence (315bp): The branch lengths are
197 proportionate to relative genetic distances. Statistical significance of the branches was
198 calculated by boot strap analysis using 1000 replicates. Boot strap values are indicated for
199 main branches. According to the phylogenetic analysis the newly identified sequences from
200 the three goats with clinical symptoms of malignant catarrhal fever (Goat No. 1, No. 2 and
201 No. 3) group together with ovine herpesvirus-2 (OvHV-2 I-V [AF327833, AF385442,
202 AF385439, AF385440, AF385441]; 99,04-99,68% similarity) and clearly separate from
203 caprine herpesvirus-2 (CpHV-2 [AF283477]; 83,93% similarity), alcelaphine herpesvirus-1
204 (AlHV-1 [AF005370]; 79,01-79,89% similarity) and other tested members of the
205 Gammaherpesvirinae (alcelaphine herpesvirus-2 (AlHV-2 [AY237369]), bovine
206 lymphotropic herpesvirus (BLHV I and II [AF327832, AY237373]), type 1 and 2 ruminant
207 rhadinovirus (Type 1 RRhV [AY237371]; Type 2 RRhV I and II [AY237367, AY237368]),
208 and malignant catarrhal fever virus in white-tailed deer (WTD-MCF [AY237370]).

Manuscript



Manuscript

