



HAL
open science

Automatic Inferior Vena Cava Segmentation for Hepatic Surgery Planning in Contrast-Enhanced CT Images

Francisco-Javier Sanchez-Castro, Lefevre Thierry, Benoît Mory, Roberto Ardon

► **To cite this version:**

Francisco-Javier Sanchez-Castro, Lefevre Thierry, Benoît Mory, Roberto Ardon. Automatic Inferior Vena Cava Segmentation for Hepatic Surgery Planning in Contrast-Enhanced CT Images. Computer Assisted Radiology and Surgery, 24th International Congress and Exhibition (CARS'2010), Jun 2010, Genève, Switzerland. pp.118 - 119, 10.1007/s11548-010-0442-7 . hal-00509434

HAL Id: hal-00509434

<https://hal.science/hal-00509434>

Submitted on 12 Aug 2011

HAL is a multi-disciplinary open access archive for the deposit and dissemination of scientific research documents, whether they are published or not. The documents may come from teaching and research institutions in France or abroad, or from public or private research centers.

L'archive ouverte pluridisciplinaire **HAL**, est destinée au dépôt et à la diffusion de documents scientifiques de niveau recherche, publiés ou non, émanant des établissements d'enseignement et de recherche français ou étrangers, des laboratoires publics ou privés.

Automatic Inferior Vena Cava Segmentation for Hepatic Surgery Planning in Contrast-Enhanced CT Images

Francisco-Javier Sanchez-Castro^a, Thierry Lefèvre^a, Benoit Mory^a, Roberto Ardon^a

^a *Philips Healthcare, Medisys, 92156 Suresnes, France*

Automatic Inferior Vena Cava Segmentation for Hepatic Surgery Planning in Contrast-Enhanced CT Images

Purpose

Primary liver cancer affects more than one million people worldwide and causes more than half million deaths every year. Surgical intervention is often the only possible cure. The surgery ranges from liver resection, where diseased tissue is removed, to full liver transplantation. In the context of hepatic clinical diagnosis, pre-operative planning and therapy, Computed Tomography (CT) imaging is used routinely. An accurate analysis of the acquired images is of capital importance for clinical decision-making procedures.

This analysis includes (among other) tasks such as:

- Liver segmentation and volumetry.
- Segmentation and classification of the hepatic vascular system in contrast-enhanced studies.
- Delineation of the liver segments following Couinaud's gold standard.

Nowadays, several image processing tools and algorithms, from manual to automatic, are available for the practitioners to deal with those tasks. In clinical practice, manual segmentation by radiology experts is difficult, highly time-consuming and subjective. With the huge increase of imaging studies to be treated, automatic methods are a necessary choice. However, the tradeoff between automation and the accuracy of such methods is a critical issue.

In this field, Inferior Vena Cava (IVC) segmentation plays a crucial role in each of the aforementioned tasks, in particular when unsupervised segmentation methods are applied (see Figure 1). First, the accuracy of liver volumetry is critical for liver donor transplantation, and considering the IVC as part of the liver significantly overestimates the volume of its parenchyma. Second, automatic hepatic vessel segmentation methods are frequently mixed up by the IVC which can easily be considered as part of the hepatic veins, hence needing manual correction. Finally, the IVC is an essential landmark for the definition of liver segments, following a Couinaud anatomical model.

Few attempts to automatically segment the IVC, differentiating it from the venous system inside the liver, have been carried out. Automatic IVC segmentation remains difficult given the anatomical inter-patient variability, the lack of well-defined boundaries with the liver parenchyma, the presence of nearby lesions and the effect of non-uniform HU values due to contrast injection. Consequently, existing approaches weakly perform under these adverse scenarios, and the problem remains unresolved up to now. To cope with the aforementioned difficulties, our contribution is twofold: (1) a model of the IVC as an implicit representation of a generalized cylinder and (2) a local region-based optimization criterion under dedicated anatomical constraints deduced from other anatomical structures to provide clinical practitioners with a fully automatic tool.

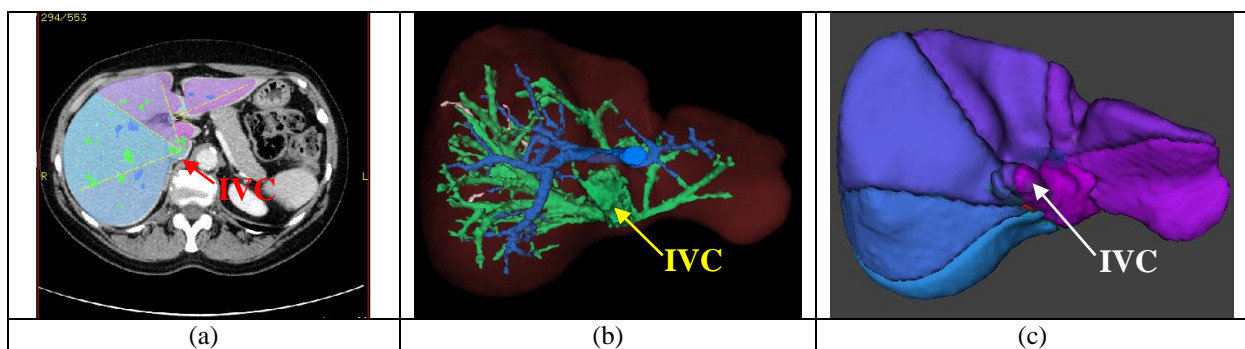


Figure 1. (a) Automatic 3D liver parenchyma segmentation and liver segments boundaries using the IVC as landmark. (b) Results of an automatic vessel segmentation method with automatic classification of Hepatic and Portal trees. Note that the IVC was segmented and wrongly classified as belonging to the Hepatic tree. (c) 3D liver segments. Note that the IVC disturbs automatic liver surface segmentation.

Methods

We consider automatic IVC segmentation as a two-phase separation problem of the foreground (IVC lumen) and background (neighboring structures, e.g. liver, kidneys, lungs, heart), where we model the foreground region as an implicit tubular model. Thus, the IVC is modeled by an open parameterized medial curve and the corresponding point-wise radii. We defined an implicit analytical representation of such generalized cylinder by integrating a smooth radial function centered at each point of the curve with continuously-varying scales. To perform the segmentation, an objective criterion is minimized. It is defined as the sum of a regularization term and two image-based homogeneity measures obtained from the IVC lumen and its background respectively. The regularization term is designed to match the IVC anatomy by penalizing both the length of the centerline and the variations of scales along it. The foreground homogeneity measure is designed to capture local variations along the IVC lumen mainly due to non-uniform contrast injection enhancement, while the background homogeneity measure captures the highly space-varying statistics of the surrounding tissues.

For a fully automatic and robust segmentation, special attention is paid to find an enclosing region of interest as well as to initialize our generalized cylinder model. Thus, we incorporate dedicated anatomical constraints from the knowledge of neighboring structures like the heart, liver, spine and aorta. Using Dijkstra's algorithm, our model is initially positioned by computing a minimal path that follows image information between two automatically located points. The first one is found inside the heart. The second one is obtained as the best response to a 2D circle detection filter applied on the last axial slice that intersects the liver in the neighborhood of the aorta. The initial diameters are set to an anatomical average of 25 mm.

Results

The automatic IVC segmentation method has been evaluated in a database of 20 3D portal venous phase contrast-enhanced CT images from different manufacturers, pixel size ranging from 0.68 to 0.78 mm and inter-slice distance of 2 mm. The results were evaluated by an expert radiologist. 16 cases were rated as satisfactory, 3 cases needed a minimal one-click user interaction in the initialization step (on the lower portion of the IVC) before being rated as satisfactory. One single case failed, due to hardly visible boundaries along the whole IVC path, unusual patient anatomy and poor image quality. Therefore, we reach a segmentation success rate of 80 % in a fully automatic mode and up to 95 % in the interactive mode.

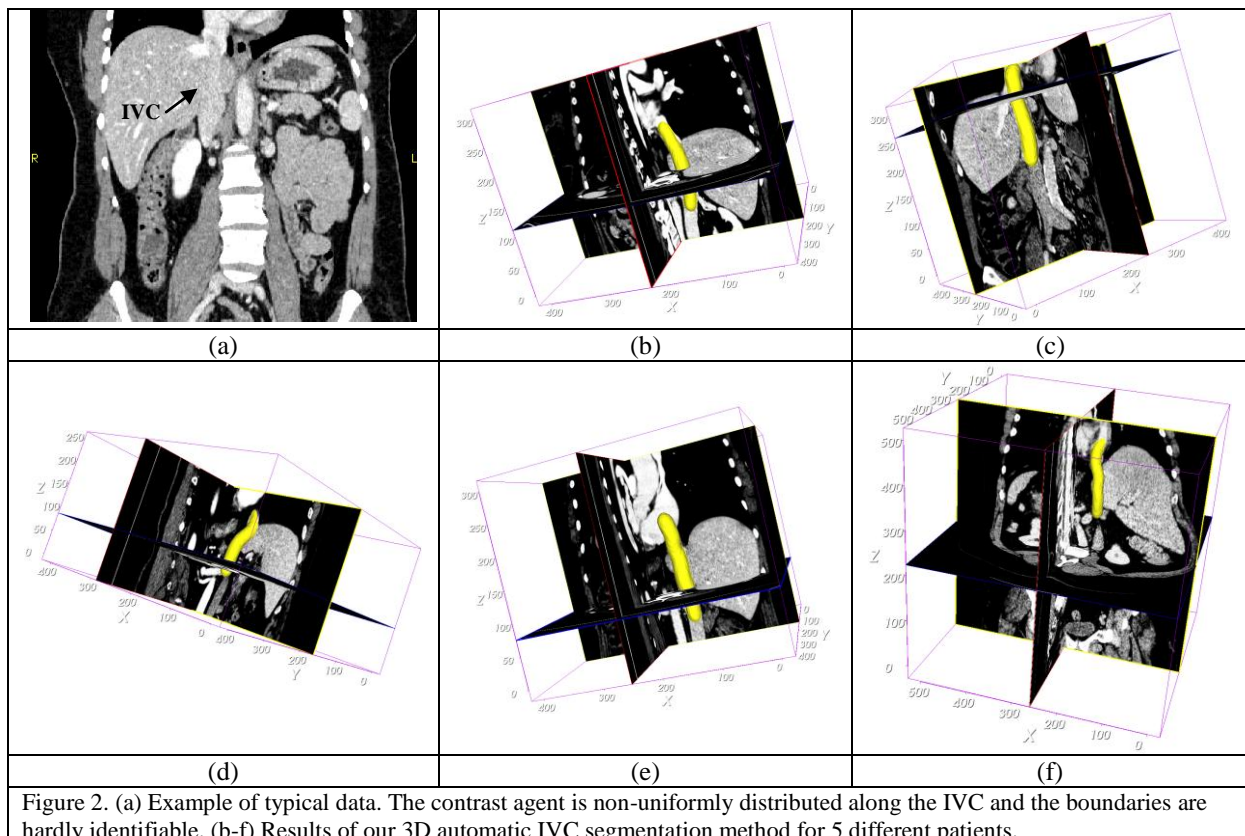


Figure 2. (a) Example of typical data. The contrast agent is non-uniformly distributed along the IVC and the boundaries are hardly identifiable. (b-f) Results of our 3D automatic IVC segmentation method for 5 different patients.

Conclusions

The results of our model-based variational IVC segmentation method with local region homogeneity criterion and dedicated anatomical constraints have already proven to be a useful clinical tool. The implicit vessel model has the capability to follow image evidence and extrapolate the surface where information is missing. IVC segmentation highly improves the automatic liver volumetry estimation (up to 5%). It also avoids classification and segmentation errors of the hepatic and portal vascular trees in unsupervised vessel segmentation approaches, which is a key contribution towards automatic landmark-based Couinaud liver segments delineation.