



**HAL**  
open science

## **Z-suture - A new knotless technique for transscleral suture fixation of intraocular implants**

Peter Szurman, Katrin Petermeier, Sabine Aisenbrey, Martin S Spitzer,  
Gesine B Jaissle

► **To cite this version:**

Peter Szurman, Katrin Petermeier, Sabine Aisenbrey, Martin S Spitzer, Gesine B Jaissle. Z-suture - A new knotless technique for transscleral suture fixation of intraocular implants. *British Journal of Ophthalmology*, 2010, 94 (2), pp.167. 10.1136/bjo.2009.162180 . hal-00509050

**HAL Id: hal-00509050**

**<https://hal.science/hal-00509050>**

Submitted on 10 Aug 2010

**HAL** is a multi-disciplinary open access archive for the deposit and dissemination of scientific research documents, whether they are published or not. The documents may come from teaching and research institutions in France or abroad, or from public or private research centers.

L'archive ouverte pluridisciplinaire **HAL**, est destinée au dépôt et à la diffusion de documents scientifiques de niveau recherche, publiés ou non, émanant des établissements d'enseignement et de recherche français ou étrangers, des laboratoires publics ou privés.

# **Z-suture - A new knotless technique for transscleral suture fixation of intraocular implants**

Peter Szurman<sup>1</sup>, MD, Katrin Petermeier<sup>1</sup>, MD, Sabine Aisenbrey<sup>1</sup>, MD, Martin S. Spitzer<sup>1</sup>. MD,  
Gesine B. Jaissle<sup>1</sup>, MD,

<sup>1</sup>University Eye Hospital, Center of Ophthalmology, Eberhard-Karls University, Tuebingen,  
Germany

Presented at the 24. Congress of the European Society of Cataract and Refractive Surgery  
(ESCRS), London, UK, 11/09/06

Presented at the annual Congress of the American Society of Cataract and Refractive Surgery  
(ASCRS), San Diego, CA, 04/29/07

Corresponding author: Dr. Peter Szurman, University Eye Hospital, Center of Ophthalmology,  
Eberhard-Karls University, Tuebingen, Germany, Phone +49-7071-2984915, Fax +49-7071-  
294674; Peter.Szurman@med.uni-tuebingen.de

## ***Licence for Publication***

*The Corresponding Author has the right to grant on behalf of all authors and does grant on behalf of all authors, an exclusive licence (or non-exclusive for government employees) on a worldwide basis to the BMJ Publishing Group Ltd and its Licensees to permit this article (if accepted) to be published in BJO and any other BMJ PGL products to exploit all subsidiary rights, as set out in our licence.*

***Competing Interest:*** None declared.

Word Count: 1025

Key Words: transscleral suturing, sulcus, intraocular lens, knotless, suture erosion

## **Abstract**

The presented Z-suture is a simple, rapid and safe knotless technique that facilitates transscleral suture fixation of various intraocular implants in the ciliary sulcus like sutured intraocular lenses, artificial iris prostheses, and iris diaphragms. As the knotless approach reliably avoids suture erosion, external fixation can be performed without any protecting scleral flaps or lamellar grooves. The needle is simply passed through the sulcus, and the emerging polypropylene suture is secured in the sclera using a zigzag shaped intrascleral suture (Z-suture). Each pass starts directly adjacent to the exiting site. Five passes are sufficient to reliably fix the suture resisting even maximum tractive forces. Once this procedure is done, the suture can be cut without any knot. By avoiding suture knots, and hence the necessity for intrascleral flaps, this knotless approach may help to reduce suture-related complications such as scleral atrophy, suture erosion and infections.

## Introduction

Transscleral suturing is a standard technique to fix various intraocular implants in the sulcus. Since the early 1990s, the ab-externo technique of Lewis<sup>1</sup> and the refined ab-interno technique of Smiddy et al.<sup>2</sup> are the basis for multiple variations in transscleral suturing. However, all techniques need a reliable external fixation in the sclera without direct knot exposure. Leaving a suture knot directly under the conjunctiva often leads to suture erosion and consecutively to an elevated risk for endophthalmitis (Fig. 1). Therefore, it is generally recommended to protect the knot, for example, by burrowing it under a scleral flap.<sup>3</sup> However, late atrophy of the scleral flap is often observed in the long-term and causes late suture erosion through the conjunctiva.<sup>4</sup> Alternative techniques by creating a scleral groove or a scleral pocket are less invasive, but share the same limitations.<sup>5-8</sup>

We present a completely knotless technique (Z-suture) that is fast, easy to perform and suitable for transscleral suture fixation of various intraocular implants regardless of the type of implant or the suturing technique used.

## Surgical technique

Various implants were placed in the sulcus and sutured transsclerally. Foldable IOLs (AF-1, Hoya, Frankfurt, Germany) were fixed using a modified ab-externo technique with a double-armed 10-0 polypropylene suture as described previously.<sup>9</sup> Other implants like the artificial iris prosthesis (HumanOptics, Mannheim, Germany), open iris diaphragm (PD1, Acri.Tec, Glienicke b.Berlin, Germany) and closed iris diaphragm (ID1, Acri.Tec) were fixed using the ab-interno technique with three single-armed looped 10-0 polypropylene sutures with a slip knot.<sup>10</sup>

All maneuvers finally resulted in two (IOL) or three (artificial iris prosthesis and iris diaphragms) sutures emerging from the outer sclera (Fig. 2A).

In all cases, external suturing was performed with a new knotless Z-suture technique: The external suturing was started with an intrascleral pass adjacent to the transscleral penetration site parallel to the limbus. This intrascleral pass was repeated in the respective opposite direction (Fig. 2B) finally resulting in a zigzag pattern with five indentations (Fig. 2C). Each pass (3-4mm) should start directly beneath the exiting site. With each pass the resistance force increased and, once the five zigzag passes were done, the suture was cut without any knot (Fig. 2D).

In order to evaluate the number of passes necessary for secure fixation of the suture within the sclera, an ex-vivo study was carried out using porcine eyes. According to the situation in humans a transscleral ab-interno pass with a consecutive Z-suture using 10-0 polypropylene was performed. After each pass the tractive forces necessary to mobilize the suture were measured with a Newton dynamometer (#314151, Leybold, Hürth, Germany).

## Results

The laboratory evaluation showed that the resistance to tractive forces increases with each pass of the Z-suture. Five suture passes were enough to resist a maximal tractive force of 0.41 Newton (mean  $0.37 \pm 0.03$  Newton). At this point the tractive forces exceeded the tensile strength and the suture ruptured. Hence, five passes reliably prevent mobilization of the suture (Tab. 1).

[Newton]	Test 1	Test 2	Test 3	Test 4	Test 5	Test 6	Median
Pass 1	0.03	0.04	0.03	0.01	0.04	0.03	0.03
Pass 2	0.08	0.06	0.08	0.04	0.09	0.06	0.07
Pass 3	0.16	0.08	0.18	0.11	0.17	0.24	0.17
Pass 4	0.23	0.21	0.31	0.22	0.32*	0.34	0.27
Pass 5	0.37*	0.38*	0.37*	0.39*		0.41*	0.38*

Table 1: Tractional forces necessary to pull back a Z-suture measured after each intrascleral pass. Resistance was measured with a Newton dynamometer. Asterisk indicates the maximum tractional force where the resistance of the Z-suture exceeds the tensile strength of the polypropylene suture resulting in suture rupture. Five passes reliably prevented suture mobilization; in one case (test 5) only four intrascleral passes were sufficient to resist traction.

This Z-suture technique with five passes has been used in 67 patients including 45 cases of sutured IOLs, 18 cases of iris prostheses and 4 cases of iris diaphragms. No complications were observed except a transient mild ciliary hemorrhage in three eyes. In all patients, the implant stayed firmly fixed within the sulcus even after a mean follow-up time of 22.4 months (range 6.1 - 38.1 months). At the final examination, the sutures were barely visible. No evidence of suture erosion, suture loosening, scleral atrophy or chronic inflammation was observed in any of these patients (Fig. 2). In all cases, the implants were smoothly positioned in the ciliary sulcus and showed a stable and centered position without any tilt or torque (Fig. 3).

## Discussion

The Z-suture offers a number of advantages over previous approaches to transscleral suturing. First, fixing the external suture to the sclera is rapid and easy to perform with minimal opening of the conjunctiva (3-4 mm). The second advantage is its universal applicability: The Z-suture can be used regardless of the type of implant (sutured IOL, closed and open iris diaphragms, artificial iris prostheses), the haptic design (with or without eyelets), the suturing technique (ab externo or ab interno), the fixation type (two-, three- or four-point fixation), the type of needle (straight or curved), the suture size (polypropylene 9.0 or 10.0) and the suture design (single- or double-armed). In all cases, the transscleral suture emerging from the sclera can be rapidly fixed within the sclera and then simply cut without any knot left behind.

More important, this technique is safe and reliable in firmly fixing the suture within the sclera. Five zigzag passes are sufficient to resist any traction from the implant as shown in the ex-vivo series. Although the results from porcine eyes cannot be directly transferred to human conditions, this strong fixation has been confirmed clinically in all cases. No loosening of the suture or dislocation of the implant has been observed in the long-term.

The main advantage is the knotless approach. By avoiding suture knots it may help to reduce complications such as scleral atrophy and suture erosion. Late suture erosion with knot exposure is a major problem in transscleral IOL suturing that may result in an increased incidence of endophthalmitis.<sup>4</sup> Hence, burying the suture knots under a scleral flap<sup>3</sup> or in a scleral groove<sup>5</sup> is generally recommended.<sup>5</sup> However, Solomon et al. found a 73% rate of suture erosion even through scleral flaps in the long-term, suggesting that this approach delays but does not prevent this complication.<sup>4</sup> Other techniques using corneal tissue or scleral patch graft often maintain a better protection of the knot, but are time-consuming and unreasonably invasive.<sup>11</sup>

In contrast, the Z-suture technique reliably secures the external suture in the sclera without any knot and thereby obviates the need for scleral flaps or grooves. No scleral atrophy or chronic inflammation was observed in the long term. The intrascleral Z-suture seems to be well-tolerated and is less invasive than scleral flaps or other lamellar techniques.

This technique neither influences general complications of transscleral suturing like cystoid macular edema, glaucoma, hemorrhage or late suture breakage nor contributes to the unsettled controversy about the value of suture fixation compared to alternative techniques.<sup>12</sup>

However, if sulcus-suturing of ocular implants is pursued, the Z-suture technique considerably facilitates the procedure and might avoid knot-related complications. Long-term results have to be awaited until the value of this technique can be finally judged.

In summary, the Z-suture is a simple and rapid technique for transscleral fixation of various sulcus implants that is applicable for a broad spectrum of surgical situations. It needs only little conjunctival opening, obviates the need for scleral flaps or grooves, and avoids suture-related complications due to the knotless approach.



## References

1. Lewis JS. Ab externo sulcus fixation. *Ophthalmic Surg* 1991; 22: 692-695
2. Smiddy WE, Sawusch MR, O'Brian TP, Scott DR, Huang SS. Implantation of scleral-fixed posterior chamber intraocular lenses. *J Cataract Refract Surg* 1990; 16: 691-696
3. Anand R, Bowman RW. Simplified technique for suturing dislocated posterior chamber intraocular lens to the ciliary sulcus. *Arch Ophthalmol* 1990; 108: 1205-1206
4. Solomon K, Gussler JR, Gussler C, Van Meter WS. Incidence and management of complications of transsclerally sutured posterior chamber lenses. *J Cataract Refract Surg* 1993; 19: 488-493
5. Friedberg MA, Berler DK. Scleral fixation of posterior chamber intraocular lenses combined with vitrectomy. *Ophthalmic Surg* 1992; 23: 17-21
6. Lewis JS. Sulcus fixation without flaps. *Ophthalmology* 1993; 100: 1346-1350
7. Baykara M, Avci R. Prevention of suture knot exposure in posterior chamber intraocular lens implantation by 4-point scleral fixation technique. *Ophthalmic Surg Lasers Imaging* 2004; 35: 379-382
8. Hoffman RS, Fine IH, Packer M. Scleral fixation without conjunctival dissection. *J Cataract Refract Surg* 2006; 32: 1907-1912
9. Szurman P, Petermeier K, Grisanti S, Jaissle GB, Bartz-Schmidt KU. A new small-incision technique for injector implantation of transsclerally sutured foldable lenses. *Ophthalmic Surg Lasers Imaging* 2007; 38:76-80
10. Thumann G, Kirchof B, Bartz-Schmidt KU, Jonescu-Cuypers C-P, Esser P, Konen W, Heimann K. The artificial iris diaphragm for vitreoretinal silicone oil surgery. *Retina* 1997; 17: 330-337
11. Bucci FAJ, Holland EJ, Lindstrom RL. Corneal autografts for external knots in transsclerally sutured posterior chamber lenses. *Am J Ophthalmol* 1991; 112: 353-354
12. Wagoner MD, Cox TA, Ariyasu RG, Jacobs DS, Karp CL. Intraocular lens implantation in the absence of capsular support. A report by the American Academy of Ophthalmology. *Ophthalmology* 2003; 110: 840-859

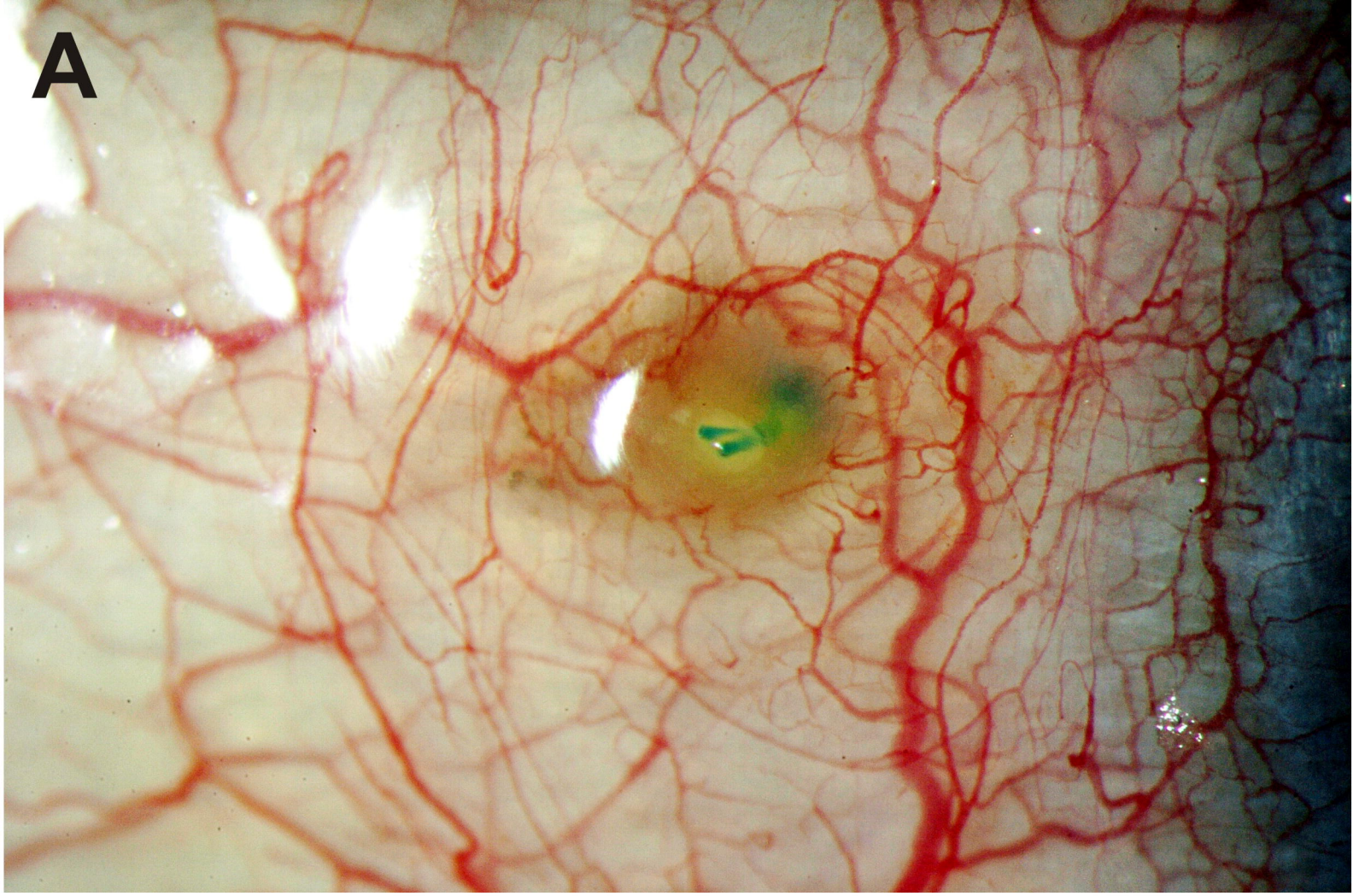
## Figures

Figure 1. Representative slit lamp photography after transscleral suture fixation of posterior chamber IOLs using a standard scleral flap technique (A) or the knotless Z-suture technique (B). A scleral flap does not reliably prevent suture erosion. Eight months after surgery the knot erodes through the atrophic scleral flap and the conjunctiva demonstrating the risk of late endophthalmitis (A). Fourteen months after using Z-suture technique the fixation is firm and shows no signs of scleral atrophy, suture erosion or chronic inflammation. The intrascleral polypropylene suture is barely visible under a quiescent conjunctiva (B).

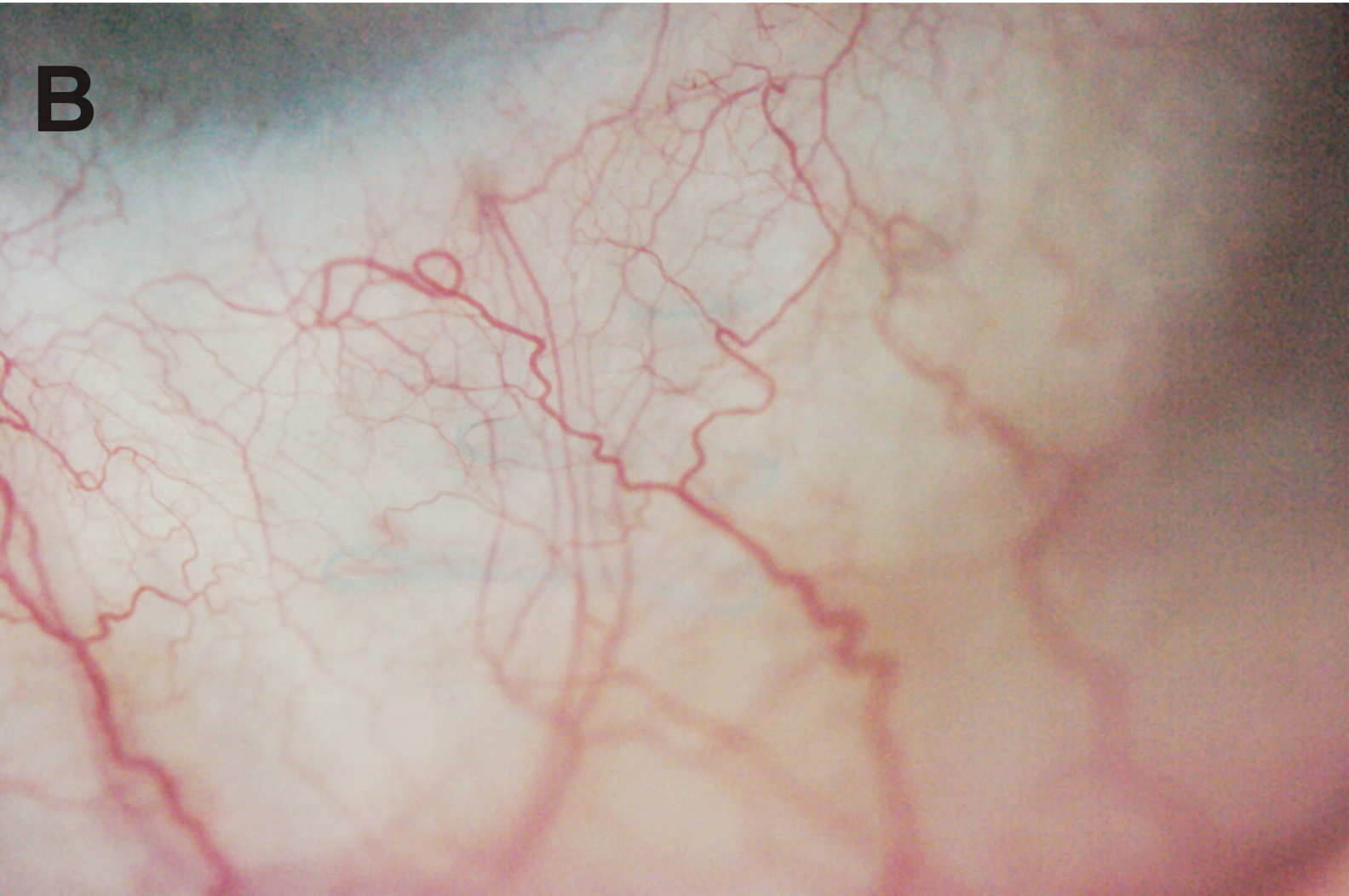Figure 2. Z-suture technique for external fixation of a transscleral polypropylene suture. After emerging from the sclera at about 1.3 mm distance from the limbus the needle is reintroduced for an intrascleral suture pass directly adjacent to the exiting site (A). To assure an acute angle and hence a firm adhesion the suture is introduced again close to the outlet and passed in the opposite direction (B). The maneuver is repeated five times resulting in a zigzag-shaped pattern with five suture passes (C). Finally, the suture is simply cut at the level of the sclera and left without any knot (D).

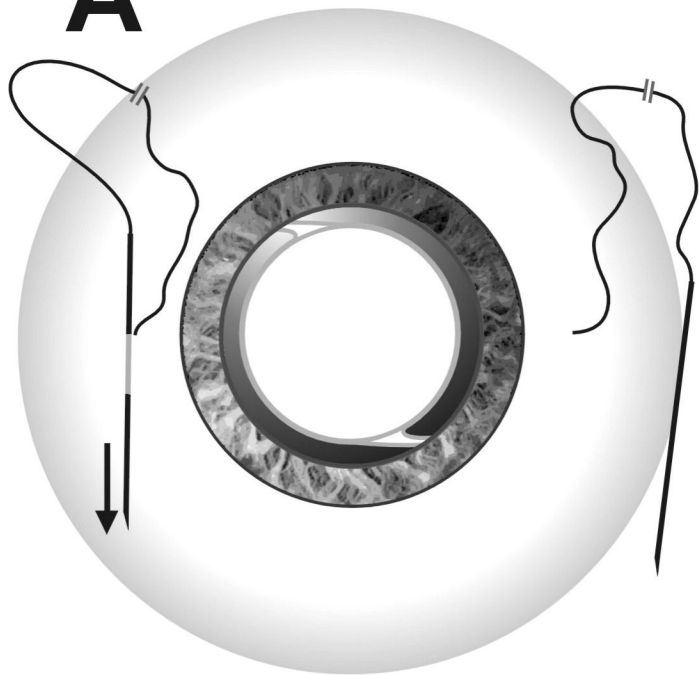
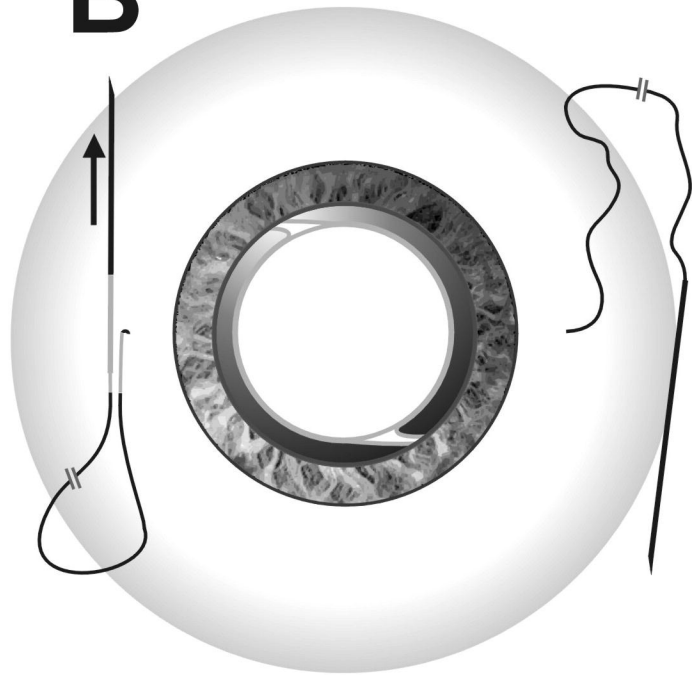
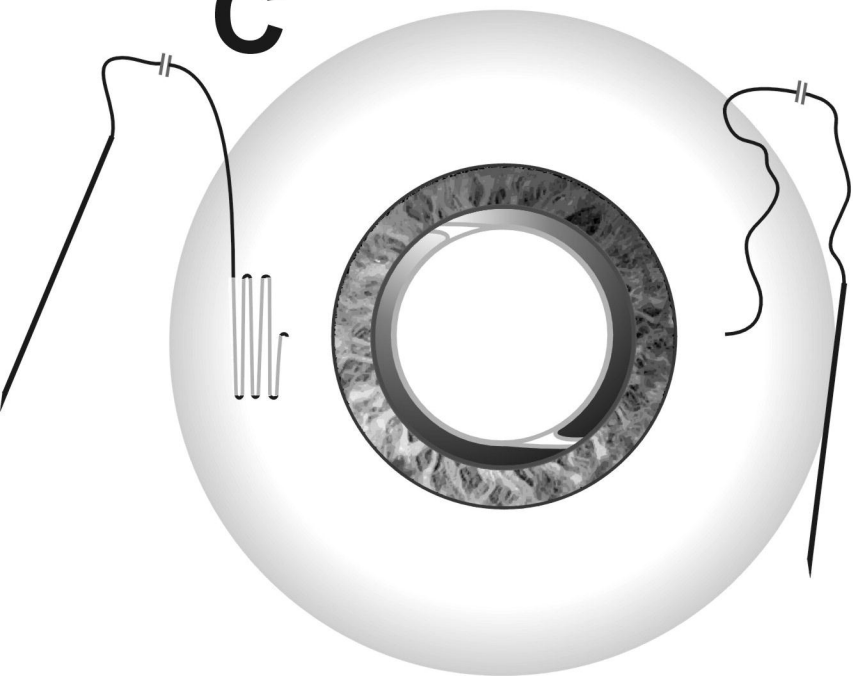
Figure 3. Representative slit lamp photography after transscleral suture fixation of a posterior chamber IOL (A), partial iris prosthesis (B) or open iris diaphragm (C) using knotless Z-suture technique. (A) Four months after iris reconstruction and transscleral sulcus-suturing of a foldable IOL the implant is well-centered and the intrascleral zigzag suture invisible. (B) Two weeks after partial iris replacement over 6 clock hours the artificial iris prosthesis is firmly fixed by three transscleral Z-sutures at the 12, 4 and 8 o'clock position. Besides the transscleral fixation two additional side-to-side sutures are used. (C) Three Z-sutures are also used for transscleral fixation of an open iris diaphragm that has been implanted in combination with revisional retinal surgery and silicone oil tamponade in relapsing proliferative vitreoretinopathy. Six months after surgery the implant is well-centered and the anterior chamber free of silicone oil. Note the temporal natural iris remnants, the lower artificial Ando-iridectomy and the artificial pupil safely retaining the silicone oil bubble.

**A**



**B**



**A****B****C****D**