



HAL
open science

Automatic nipple detection on breast MRI

Maxim Fradkin, Jean-Michel Rouet, Johannes Buurman

► **To cite this version:**

Maxim Fradkin, Jean-Michel Rouet, Johannes Buurman. Automatic nipple detection on breast MRI. Computer Assisted Radiology and Surgery, 24th International Congress and Exhibition (CARS'2010), Jun 2010, Genève, Switzerland. pp.368-369, 10.1007/s11548-010-0471-2 . hal-00508863

HAL Id: hal-00508863

<https://hal.science/hal-00508863>

Submitted on 6 Aug 2011

HAL is a multi-disciplinary open access archive for the deposit and dissemination of scientific research documents, whether they are published or not. The documents may come from teaching and research institutions in France or abroad, or from public or private research centers.

L'archive ouverte pluridisciplinaire **HAL**, est destinée au dépôt et à la diffusion de documents scientifiques de niveau recherche, publiés ou non, émanant des établissements d'enseignement et de recherche français ou étrangers, des laboratoires publics ou privés.

Automatic nipple detection on breast MRI

M. Fradkin¹, J-M. Rouet¹, H. Buurman²

¹Philips Healthcare, Suresnes, France

²Philips Healthcare, Best, Netherlands

Keywords: Breast MRI, Nipple detection, Blob detection, Hough transform

Purpose

Breast cancer is the most prevalent cancer among women and affects annually approximately one million women worldwide. MRI examinations are often done in complement to first-choice ones (Mammography, Ultrasound) to better assess the existence and malignancy of lesions and their follow-up. A standardized findings report, following the examination, must provide among others information several descriptors of lesion location, including nipple to lesion distance and so-called clock face and quadrant locations.

Reporting the lesion findings is a time consuming task in clinical routine, and there is a very strong interest in its automation. While automatic lesion detection on MRI has been extensively studied in the literature, it is not the case for nipple detection. Besides, automatically detecting the nipple locations in MR images is not an easy task because of: (a) large variability of breast shapes and anatomical variation of the nipple appearance and location on the breast surface; (b) large variety of acquisition protocols; (c) image acquisition focus on providing best image quality for the internal tissues and not near the skin surface.

A shape based detection approach (like searching for local bumps on the skin surface) might often be mislead since the breast surface is very likely to be compressed by the coil, not to mention flat and inverted nipples. We present a fully automatic nipple detection allowing to robustly localize the nipples on T1 contrast enhanced 3D MR images of the breast and overcoming the above stated issues.

Methods

The method starts with a skin surface segmentation based on adaptive thresholding. The essential feature of the method lies in the creation of a narrow-band projection image (PI) in the vicinity of the breast skin surface. The rationale behind this PI is based on the observation that the nipples are better detected from an analysis of the breast internal structures near the nipple, rather than a shape-based (surface bump) detection criterion. More precisely, due to the areola tissue and high ducts density in the nipple area, we observe a typical in-depth agglomeration of contrasted pixels in its vicinity, which are not present near the skin in other parts of the breast. Therefore, such a PI will reveal the nipple area as a brighter/darker region as the background (depending on the acquisition protocol).

A coarse scale localization of the nipple is performed on the PI using a blob detector. We apply a classical Hessian-based detector with a fixed scale, since the nipple size is known to vary from 5 to 15mm. The coarse location is used to delimit a region of interest (ROI) further used for finer nipple detection. A nipple generally has an elliptic shape in the PI, therefore we detect it as the location of the best fitted ellipse on the ROI edges. For that, we use a modified elliptic Hough Transform algorithm that takes into account the local edges strength and orientation.

Results

The method was validated against the “ground truth” provided by three experts on 29 datasets comprising 58 breasts. Three experts were asked to manually determine the position of the nipples on each dataset. Then, the “ground truth” was established as a mean location for each dataset. The inter-observer variability, calculated as variance around the mean, was less than 3mm.

We assumed that the automatic detection should be considered correct if its error is less than 1cm (typical requested reporting accuracy). The method overall mean accuracy was found to be $7.7\pm 11.6\text{mm}$. Apart of the mean error, an important evaluation criterion was the number of cases with the error under the nipple size limit (10mm). This “accurate detection” criterion was fulfilled in 79% of the cases with a mean error of 2.9mm, which is close to the inter-observer variability, while in 16% more of the cases the results were acceptable. Only in a very few cases (5%) the method produced completely wrong results for the following reasons: (a) inaccurate skin segmentation; (b) outliers (like a skin marker placed far away from the nipple but still on the skin surface), misleading the algorithm; (c) an important bias in the image gray levels due to magnetic field inhomogeneities. Figure 1 illustrate 2 examples of automatic nipple detection (blue dots) compared to the ground truth positions (red dots) on fat suppressed and non fat suppressed input images.

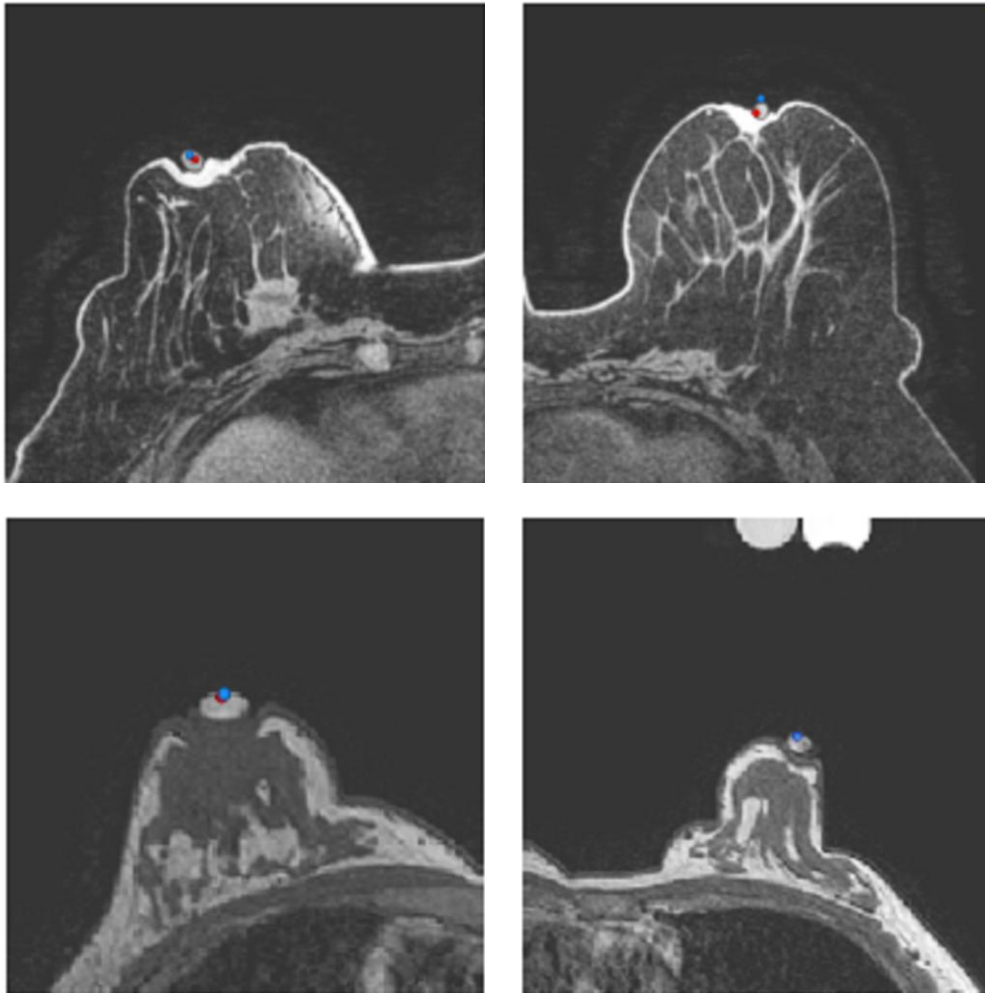


Fig. 1. Examples of nipple detection (blue) compared to expert decision (red) on two different exams. The two rows illustrate different patients, as well as different image acquisition protocols (fat suppressed vs. non fat suppressed) hence different image appearance.

Conclusions

We described a new automatic method for nipple detection. First, we generated a projection image from the T1-weighted image and previously segmented skin surface. Then we used in a coarse-to-fine

manner different variants of blob detectors coupled with Hough transform for accurate nipple localization. The method has been validated on 29 datasets using the expert-based "ground truth". The overall mean error was 7.7mm, while in 79% of the cases very accurate detection was obtained, with localization accuracy of 2.9mm. The method failed only in 5% of the cases; the failures are mainly related to the mis-detections due to inaccurate skin segmentation or skin markers placed away from the real nipple. In addition, poor localization accuracy can be expected when the nipple region is big and fuzzy.