



HAL
open science

Detection of pathological areas and estimation of viability parameters in late-enhancement cardiac MRI

Khaoula Elagouni, Cybèle Ciofolo-Veit, Benoît Mory, Gilion Hautvast, Marcel Breeuwer

► **To cite this version:**

Khaoula Elagouni, Cybèle Ciofolo-Veit, Benoît Mory, Gilion Hautvast, Marcel Breeuwer. Detection of pathological areas and estimation of viability parameters in late-enhancement cardiac MRI. Society of Cardiovascular Magnetic Resonance 13th Annual Scientific Sessions (SCMR 2010), Jan 2010, Phoenix, AZ, United States. pp.167, 10.1186/1532-429X-12-S1-P167 . hal-00508758

HAL Id: hal-00508758

<https://hal.science/hal-00508758>

Submitted on 5 Aug 2010

HAL is a multi-disciplinary open access archive for the deposit and dissemination of scientific research documents, whether they are published or not. The documents may come from teaching and research institutions in France or abroad, or from public or private research centers.

L'archive ouverte pluridisciplinaire **HAL**, est destinée au dépôt et à la diffusion de documents scientifiques de niveau recherche, publiés ou non, émanant des établissements d'enseignement et de recherche français ou étrangers, des laboratoires publics ou privés.

Detection of Pathological Areas and Estimation of Viability Parameters in Late-Enhancement Cardiac MRI

Khaoula Elagouni, Cybèle Ciofolo-Veit, Benoît Mory, Gilion Hautvast and Marcel Breeuwer

Introduction

Viability assessment is essential for therapy planning following a myocardial infarction. In particular, the proportion of viable myocardium is a major factor in determining whether a patient may benefit from revascularization [1]. By means of late-enhancement cardiac MR imaging (LECMR), it is now possible to visualize normal and non-viable areas with high spatial resolution.

Purpose

We propose a novel fully automatic method to detect and quantify pathological areas in late-enhancement cardiac MR images.

Method

The first step consists to analyse myocardium intensity with a specifically tailored Expectation-Maximization algorithm [2]. Estimated distributions of both normal and abnormal tissues are then exploited to generate a fuzzy map indicating, for every pixel, the membership degree to the abnormal tissue class. As false positives remain, we design a fast version of the region competition [3] algorithm to rapidly obtain well-defined regions corresponding to pathological areas and the membership values of all their pixels. In order to quantify these areas, we calculate the percentage of abnormal tissue and use normalized representations independent of myocardium shape and size to automatically compute the thickness of pathological regions.

Results

The method was tested on 11 short-axis LECMR volumes (100 slices) acquired in a multi-center study between 2004-2007 (Philips Intera scanner 1.5T, M FFE sequence, TE=1.1ms, TR=3.8ms, flip angle=15°). All slices are 256x256, spaced with 10mm and with pixel size around 1.5mm. An experienced operator used the interactive thresholding procedure available in the Philips ViewForum 4.3 Cardiac Package to locate pathological areas. To automatically detect these areas we used: (1) our method (see results in Figure 1), (2) thresholding at average normal myocardium value plus two standard deviations (SD) and (3) thresholding at average normal myocardium value plus three SD. Following segmentation, we quantified the volumetric fraction of pathologic areas and the distance between the damaged region and the epicardium. We compared the results obtained from the automatic segmentation to the results obtained from the manual segmentation (Figure 2). Our method gives the smallest error with respect to manual detections (detected tissue error=80ml \pm 126ml, distance error=12% of myocardium thickness) and always avoided false detections contrary to thresholding approaches.

Conclusion

We presented a fast and robust method for detecting and quantifying abnormal regions in short-axis LECMR images.

References

- [1] Marshall et. al., Circulation vol. 67, pp. 766-778, 1983
- [2] Dempster et. al., J. Roy. Stat. Soc., vol. 39, pp. 1-38, 1977
- [3] Zhu and Yuille, IEEE PAMI vol. 18, pp. 884-900, 1996

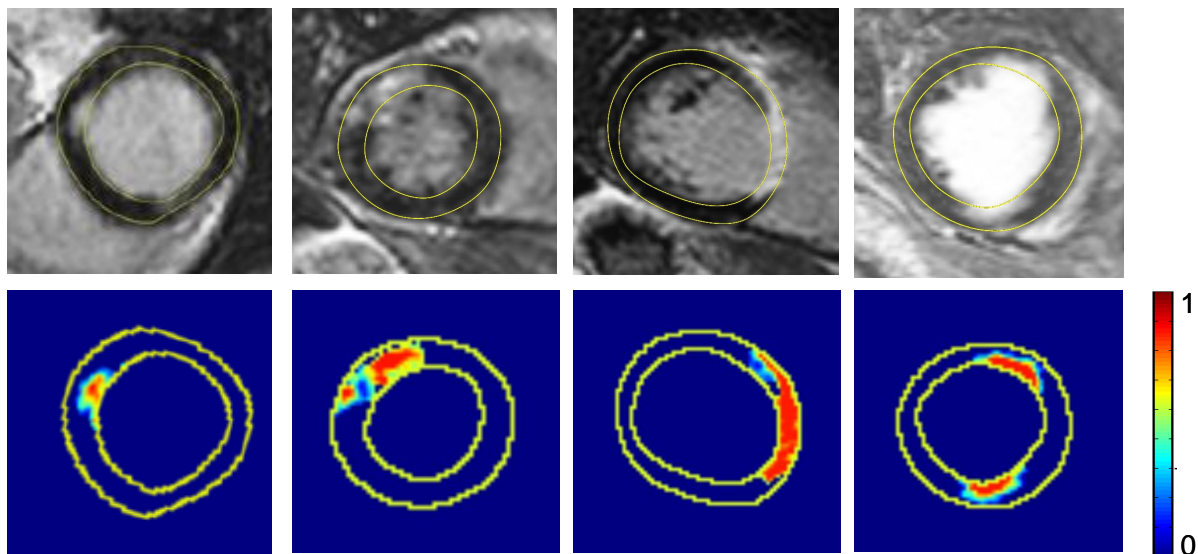


Figure 1: Detection of pathological areas. Normal regions appear in dark blue while other colors show the detected abnormal regions with their membership degree to the abnormal tissue class (from 0 - dark blue to 1 - red)

Measure	Our method	2SD threshold	3SD threshold
Volumetric error (% w.r.t heart volume)	3.6 ± 5.6	4.7 ± 6.1	4.6 ± 7.7
Epicardium distance error (% w.r.t. myocardium thickness)	12 ± 11	12 ± 10	14 ± 10

Figure 2: Error between automatic and manual detections. Column 1: our method; column 2: thresholding at average normal myocardium value plus two standard deviations (SD), column 3: thresholding at average normal myocardium value plus three SD.