



**HAL**  
open science

## The liver of wrasse - morphology and function as a mirror of point source chemical impact

Katja Broeg, Wiebke Kaiser, Sieglinde Bahns, Angela Koehler

### ► To cite this version:

Katja Broeg, Wiebke Kaiser, Sieglinde Bahns, Angela Koehler. The liver of wrasse - morphology and function as a mirror of point source chemical impact. *Marine Environmental Research*, 2008, 66 (1), pp.191. 10.1016/j.marenvres.2008.02.056 . hal-00501956

**HAL Id: hal-00501956**

**<https://hal.science/hal-00501956>**

Submitted on 13 Jul 2010

**HAL** is a multi-disciplinary open access archive for the deposit and dissemination of scientific research documents, whether they are published or not. The documents may come from teaching and research institutions in France or abroad, or from public or private research centers.

L'archive ouverte pluridisciplinaire **HAL**, est destinée au dépôt et à la diffusion de documents scientifiques de niveau recherche, publiés ou non, émanant des établissements d'enseignement et de recherche français ou étrangers, des laboratoires publics ou privés.

## Accepted Manuscript

The liver of wrasse - morphology and function as a mirror of point source chemical impact

Katja Broeg, Wiebke Kaiser, Sieglinde Bahns, Angela Koehler

PII: S0141-1136(08)00084-6

DOI: [10.1016/j.marenvres.2008.02.056](https://doi.org/10.1016/j.marenvres.2008.02.056)

Reference: MERE 3230

To appear in: *Marine Environmental Research*



Please cite this article as: Broeg, K., Kaiser, W., Bahns, S., Koehler, A., The liver of wrasse - morphology and function as a mirror of point source chemical impact, *Marine Environmental Research* (2008), doi: [10.1016/j.marenvres.2008.02.056](https://doi.org/10.1016/j.marenvres.2008.02.056)

This is a PDF file of an unedited manuscript that has been accepted for publication. As a service to our customers we are providing this early version of the manuscript. The manuscript will undergo copyediting, typesetting, and review of the resulting proof before it is published in its final form. Please note that during the production process errors may be discovered which could affect the content, and all legal disclaimers that apply to the journal pertain.

# The liver of wrasse - morphology and function as a mirror of point source chemical impact

**Katja Broeg \*, Wiebke Kaiser, Sieglinde Bahns, Angela Koehler**

*Alfred Wegener Institute for Polar and Marine Research, 27570 Bremerhaven, Germany*

## **Abstract**

Corkwing wrasse (*Symphodus melops* L.), a protogynous, non-migratory lipfish species, living close to rocky shores was chosen as an indicator species for the monitoring of biological effects of contaminants. Fish were caught by local fisherman at the Norwegian west coast in fjord sites within the framework of the EU BEEP project. The sites represented different point-source impacts of I. Copper (a former copper mine), II. Polycyclic aromatic hydrocarbons (PAHs, aluminium smelter discharge), III. formaldehyde plus PAHs (kelp-factory and influence of the aluminium smelter). Livers of wrasse were studied for histopathological alterations and compared to healthy livers of fish from a reference location. Besides liver morphology, different functional and metabolic parameters were measured to link pathological alterations to functional disorders. The integrity of the lysosomal compartment was tested by the assessment of lysosomal membrane stability (lys), and the accumulation of neutral lipids and lipofuscin. Activity and intracellular localisation of the NADPH-producing enzymes in the liver were assessed histochemically and measured by

computer-assisted image analysis. Histopathological alterations were most severe at the site impacted by formaldehyde and PAHs. These findings were associated with highest tumor prevalence, lowest membrane stabilities in hepatocytes and highest accumulation rates of lipofuscin in the liver. The activities of the NADPH-producing enzymes phosphogluconate dehydrogenase (PGDH) and glucose-6-phosphate dehydrogenase (G6PDH) were significantly lower compared to unimpacted reference fish. Histopathological alterations showed clear differences dependent on the input source. Potential links between specific contaminant impact and functional and morphological disorders are discussed.

*Keywords:* *Symphodus melops* L.; Wrasse; Histopathology; lysosomal membrane stability; PAH

\*Corresponding author: *Email address:* Katja.Broeg@awi.de (K. Broeg)

The integrity of liver of fish with respect to morphology and function, may serve as a direct and sensitive indicator for toxically-induced alterations reflecting the effects of anthropogenic impact on the health status of biological systems (Koehler, 1991; Hinton, 1994; Stentiford et al., 2003; Feist et al., 2004; Broeg et al., 2005). In the present multivariate study, a new indicator species, the corkwing wrasse (*Symphodus melops*) was tested for its potential to specify effects of clearly defined contaminant situations.

Livers were analysed for toxicopathic alterations by histopathology, lysosomal membrane stability (lys), storage disorders (neutral lipid accumulation), oxyradical reactions (lipofuscin formation), and by histochemistry of the main NADPH-producing enzymes, glucose-6-phosphate dehydrogenase (G6PDH) and phosphogluconate dehydrogenase

(PGDH). NADPH is needed for biosynthesis, during biotransformation, oxyradical scavenging and elimination of xenobiotics.

Fish from four locations were sampled in the EU-project BEEP at the west coast of Norway. These locations were characterized by various point-source impacts of copper, PAHs, and PAHs in combination with formaldehyde (Andersen, 2002). In addition, a reference location was sampled. Data were analysed using the multivariate *k*-means analysis which allowed the integrated assessment of toxically-induced alterations at an individual level.

Corkwing wrasse between 13 and 21 cm were caught with fyke nets, measured and weighed. Subsequently fish were killed and one central part of the liver was excised and quick-frozen in liquid nitrogen for analysis of lysosomal membrane stability (Moore et al., 2004), activity of G6PDH and PGDH (Köhler and Van Noorden, 1998) as well as neutral lipids (Bayliss, 1982) and Schmorl's lipofuscin (Moore et al., 2004). One adjacent liver piece of similar size was fixed in Baker's formalin and embedded in methacrylate. Sections were stained with Gills hematoxylin and eosin and Periodic Acid Schiff (PAS) for histopathology.

For the detailed quantification of the level of histopathological alterations, an evaluation sheet for wrasse liver was developed, based on the histopathological criteria developed for flatfish (Koehler, 2004; Feist et al., 2004). The diagnostic catalogue comprised 10 different categories of liver structures (liver tissue, liver cells, cell nucleus, cytoplasm of hepatocytes, bile ducts, pancreatic tissue, extracellular matrix, preneoplastic lesions, benign neoplasms, malignant neoplasms). Categories were graded according to the progressive stages of histopathological alterations to allow scoring of the observations. All measurements were carried out on each individual fish. Statistical analyses were performed using the STATISTICA software.

The data were analysed by the use of the multivariate *k*-means algorithm. This algorithm is a method to cluster objects based on their attributes into *k* partitions of greatest possible distinction. It is attempted to identify the centers of natural clusters in the data. Its main objective is to minimize total intra-cluster variance and maximise the between-cluster variance. Based on the present data of wrasse from each impact source in combination with the reference location two clusters were displayed.

The data showed one cluster of “healthy” wrasse which was characterised by high lysosomal membrane stability, low neutral lipid accumulation, low lipofuscin content, low histopathological alterations of liver tissue and bile ducts, and high G6PDH and PGDH activity (Fig. 1A, B, C cluster 1). The second cluster of “impacted” wrasse showed the following differences at the copper site (Fig. 1A: Significantly lower lysosomal membrane stability, significantly higher neutral lipid accumulation, and significantly decreased G6PDH and PGDH activity. Lipofuscin content as well as histopathological alterations of liver tissue were similar to the healthy cluster. At the metal location no preneoplastic and neoplastic lesions were observed. Wrasse from the PAH-impacted site showed the following effects (Fig. 1B cluster 2): Significantly lower lysosomal membrane stability and lower G6PDH activity, significantly enhanced histopathological alterations of liver tissue and bile ducts, significantly higher lipofuscin content, lower PGDH activity and higher neutral lipid accumulation. At the PAH-impacted location, 33% of the wrasse had preneoplastic and/or neoplastic liver lesions.

In wrasse caught at the site impacted with PAHs and formaldehyde (Fig. 1C cluster 2) all parameters differed significantly from the healthy wrasse cluster with the exception of neutral lipid accumulation. At this station 70 % of the wrasse had preneoplastic and/or neoplastic liver lesions.

The present study showed specific patterns of histopathological alterations and functional disorders at different impact situations. Even though wrasse from the copper site showed lower lysosomal membrane stability, lipid accumulation and enzyme activities, pathological alterations were minor compared to fish from the sites impacted by PAH and PAH/formaldehyde. In the same metal exposed individuals, glycogen content in the livers was significantly higher than in all other wrasse, suggesting a successful adaptation to chronic high copper concentrations by (hypothesis I) increased energy supply for active copper elimination transport, (hypothesis II) formation of glycogen/protein macromolecules as copper binding sites.

The most striking pathological alteration at the PAH and PAH/formaldehyde location concerned the bile ducts. In general, bile ducts were more frequent in wrasse from these locations and bile duct epithelial cell proliferation was a common feature, indicating the formation of additional elimination portals of PAH metabolites from the liver. Taking together, the significantly decreased G6PDH and PGDH activities, the high amounts of lipofuscin in the livers of these fish, and the high tumor prevalence, especially in the PAH/formaldehyde group, adaptative and compensatory capacities were obviously exhausted in these fish compared to metal exposed fish.

## References

- Andersen, O. K. (2002). BEEP WP4, Campaign 1, Norway 2001, Site Descriptions. Biological Effects of Environmental Pollution (BEEP) - EU Project Meeting, Athens, Greece.
- Bayliss, O.B. (1982). In: Bancroft, J.D., Stevens, A. (eds.) Theory and practice of histological techniques. Churchill-Livingstone, Edinburgh, UK, 217-241.

- Broeg, K., Westernhagen, H. V., Zander, S., Körting, W., and Koehler, A. (2005). *Marine Pollution Bulletin*, 50, 495-503.
- Feist, S., Lang, T., Stentiford, G. D., and Koehler, A. (2004). *ICES Techniques in Marine Environmental Sciences*, 38, 1-42.
- Hinton, D.E. (1994). *Aquatic Toxicology*, 24, 207-239.
- Koehler, A. (2004). *Aquatic Toxicology*, 70, 257-276.
- Koehler, A., and van Noorden, C.J.F. (1998). *Aquatic Toxicology*, 40, 233-252.
- Koehler, A. (1991). *Comparative Biochemistry and Physiology (C)*, 100, 123-127.
- Moore, M.N., Lowe, D., and Koehler, A. (2004). *ICES Techniques in Marine Environmental Sciences*, 36, 1-31.
- Stentiford, G.D., Longshaw, M., Lyons, B.P., Jones, G., Green, M., and Feist, S.W. (2003). *Marine Environmental Research*, 55, 137-159.

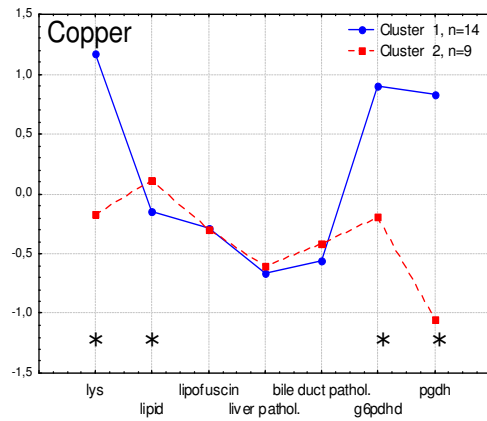


**Figure Caption:**

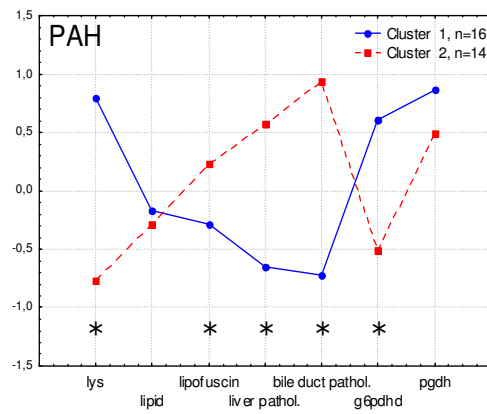
Fig. 1. Mean values of the *k*-means cluster analysis for a) copper and reference, b) PAH and reference, c) PAH/formaldehyde and reference. Asterisk= difference between the clusters is significant ( $p < 0.05$ ). lys= lysosomal membrane stability, lipid= neutral lipid accumulation.

Fig.1

1A



1B



1C

