



The limb-girdle muscular dystrophies-diagnostic strategies

Kate Bushby, Fiona Norwood, Volker Straub

► To cite this version:

Kate Bushby, Fiona Norwood, Volker Straub. The limb-girdle muscular dystrophies-diagnostic strategies. *Biochimica et Biophysica Acta - Molecular Basis of Disease*, 2007, 1772 (2), pp.238. 10.1016/j.bbadis.2006.09.009 . hal-00501525

HAL Id: hal-00501525

<https://hal.science/hal-00501525>

Submitted on 12 Jul 2010

HAL is a multi-disciplinary open access archive for the deposit and dissemination of scientific research documents, whether they are published or not. The documents may come from teaching and research institutions in France or abroad, or from public or private research centers.

L'archive ouverte pluridisciplinaire **HAL**, est destinée au dépôt et à la diffusion de documents scientifiques de niveau recherche, publiés ou non, émanant des établissements d'enseignement et de recherche français ou étrangers, des laboratoires publics ou privés.

Accepted Manuscript


The limb-girdle muscular dystrophies-diagnostic strategies

Kate Bushby, Fiona Norwood, Volker Straub

PII: S0925-4439(06)00194-3
DOI: doi: [10.1016/j.bbadis.2006.09.009](https://doi.org/10.1016/j.bbadis.2006.09.009)
Reference: BBADIS 62638

To appear in: *BBA - Molecular Basis of Disease*

Received date: 13 July 2006
Revised date: 27 September 2006
Accepted date: 27 September 2006



Please cite this article as: Kate Bushby, Fiona Norwood, Volker Straub, The limb-girdle muscular dystrophies-diagnostic strategies, *BBA - Molecular Basis of Disease* (2006), doi: [10.1016/j.bbadis.2006.09.009](https://doi.org/10.1016/j.bbadis.2006.09.009)

This is a PDF file of an unedited manuscript that has been accepted for publication. As a service to our customers we are providing this early version of the manuscript. The manuscript will undergo copyediting, typesetting, and review of the resulting proof before it is published in its final form. Please note that during the production process errors may be discovered which could affect the content, and all legal disclaimers that apply to the journal pertain.

The limb-girdle muscular dystrophies- diagnostic strategies.

Kate Bushby¹, Fiona Norwood², Volker Straub¹.

1. Institute of Human Genetics,
International Centre for Life,
Central Parkway,
Newcastle upon Tyne
NE1 3BZ

Kate.bushby@ncl.ac.uk

0191 241 8757

0191 241 8799

(Professor Bushby is corresponding author)

2. King's Regional Neuroscience Centre
9th Floor Ruskin Wing
King's College Hospital
Denmark Hill
London
SE5 9RS

Keywords: limb girdle muscular dystrophies, muscular dystrophy differential
diagnosis, muscular dystrophy management

Introduction

The limb-girdle muscular dystrophies are a group of disorders which were historically grouped together because of the shared clinical feature of predominant involvement of the “limb-girdle” (pelvic and shoulder) musculature. These clinical findings are not unique to the disorders within the “LGMD” classification- disorders such as Becker muscular dystrophy, late onset spinal muscular atrophy, myotonic dystrophy type 2, Bethlem myopathy and Pompe’s disease may all show overlapping clinical features, and rarer disorders such as congenital myasthenic syndromes may also need to be considered in the differential diagnosis. Conversely, the LGMD classification also contains genetically defined disorders where there is a broad heterogeneity of presentation and muscle involvement. This is particularly true for some of the dominant disorders in the LGMD classification, such as LGMD1A where myotilin mutations are associated also with the disorders known as the myofibrillar myopathies, LGMD1B where lamin A/C mutations can also cause a wide range of different diseases, and LGMD1C where the clinical presentation includes hyperCKaemia, rippling muscle disease, myalgia and distal myopathy.

The molecular basis of the diseases is also highly heterogeneous. The process of gene identification in LGMD has involved a combination of linkage and candidate gene analysis, resulting in a gene and protein based classification which includes three known genes causing an autosomal dominant LGMD [1] and eleven known genes causing autosomal recessive LGMD [2, 3] (see table 1). The genes and proteins causing the diseases in these groups show a huge range of localisation across the muscle fibre, from sarcolemma to nuclear envelope, with functions ranging from structural to enzymatic. As the current state of our understanding of the pathogenesis of many of these disease groups is dealt with elsewhere in this issue, this article will

concentrate on the diagnostic process by which these disorders can be defined. Such definition of a precise diagnosis is increasingly allowing directed management for these diseases by the ability to predict specific complications such as those of the cardiac or respiratory systems, and in the future will be the starting point for specific gene and protein based therapies.

History and examination

LGMD was first designated a disease group through the need to distinguish a set of patients with predominantly proximal muscle weakness and a dystrophic pattern on muscle biopsy from the more classically recognised “Duchenne/ Becker” and facioscapulohumeral muscular dystrophies, both of which groups are much more common than LGMD. The key hallmarks of disease remain the marked weakness of the pelvic and shoulder girdle muscles, but as the different disease entities within the group have become better defined based on their distinct genetic basis, accompanying clinical features may help to distinguish subtypes of LGMD. Particular features which need to be sought include muscle hypertrophy or atrophy, scapular winging, muscle rippling and contractures. While the history will in many cases be a relatively non-specific story of progressive proximal weakness, with onset at any age, there are some clues in the history of onset which can be very suggestive of a particular diagnosis. This is particularly the case in dysferlinopathy where the history of relatively sudden onset in the late teens, often with early inability to stand on tiptoe, and sometimes with sudden onset of calf pain and swelling may be almost pathognomonic for the diagnosis [4]. This group of patients in particular may be misdiagnosed as myositis, with the inappropriate use of steroids, to which the patients do not appear to be responsive. In some of the autosomal dominant types of LGMD the family history

may be particularly informative. For example, the presence in the index case or wider family of respiratory failure, dysarthria or cardiomyopathy may help to suggest LGMD1A [5]. History of arrhythmia or contractures can be suggestive of laminopathy or LGMD1B [6], while a history of muscle rippling or myalgia may be suggestive of LGMD1C [7] (see table 2).

Associated complications

Muscular dystrophies are often multisystem disorders. Recognition of the particular type of muscular dystrophy can help to assign a more precise risk of complications. Complications which may be life-threatening and where appropriate management may have a positive impact on length and quality of life include especially those affecting the cardiovascular and respiratory systems. These are present at different frequencies within the various disorders in the LGMD group. Cardiovascular complications may include the development of a progressive cardiomyopathy or arrhythmias, while respiratory complications may or may not have significant diaphragmatic weakness as a clear component of the problem. These complications need to be sought specifically and appropriate management instituted for any problems detected [8, 9] (see table 2).

The diagnostic process (see figure 1)

None of the different types of LGMD can be distinguished on basic muscle histology or electrophysiology, though electromyography may be useful in distinguishing this myopathic group of diseases from myotonic dystrophy type 2 (PROMM, DM2) which may be clinically similar, and the muscle biopsy may be crucial in distinguishing LGMD from Pompe's disease or other metabolic syndromes. The serum creatine kinase is variably elevated in the different disorders and this may serve as a useful

indicator to subdivide the different types of LGMD, though it is no more than a guide. As a rule of thumb, the autosomal recessive types of LGMD are typically associated with a much higher level of creatine kinase elevation than the dominant forms of LGMD, with the exception of LGMD1C. Diagnosis therefore relies on a combination of clinical assessment, specialised muscle immunoanalysis and genetic testing. In informative families, linkage analysis may be useful to identify the gene involved. Otherwise, protein analysis can be used to pinpoint the likely gene primarily involved, though often complex patterns of secondary protein involvement in addition to the primary defect can complicate this process. A wide range of antibodies needs to be applied and frequently both immunolabelling of a muscle biopsy sample needs to be supplemented by immunoblotting. This is summarised in table 3.

Combining information from the clinical and biopsy details therefore allows a diagnostic algorithm to be suggested and this is presented in figure 1. In part 1 of the algorithm the features which may suggest diagnosis of either LGMD2I or LGMD1B (neither of which can be definitively diagnosed by muscle biopsy) are described. Parts 2-4 describe the interpretation of the muscle biopsy findings together with clinical pointers which may lead to a suggestion of a genetic diagnosis which needs to be confirmed by testing.

Conclusions.

Achieving a precise diagnosis in all patients will become increasingly important as new specific therapies are developed. The LGMDs continue to present a complex challenge for diagnosis, but the recognition of the different subgroups within this broad and heterogeneous classification already allows better strategies for management and genetic counselling. As diagnostic testing begins to be

systematically applied in different countries, the epidemiology of these diseases can increasingly be understood, and a variable pattern of disease frequency can be discerned. Therefore the future development of diagnostic testing and indeed therapeutic studies will need to take these regional differences into account. Particularly striking is the predominance of LGMD2I due to the common C826A mutation in Northern Europe [10], compared to a relatively higher proportion of LGMD2A and LGMD2B cases in Southern Europe. A highly focussed approach to LGMD diagnostics is already improving management and is going to become increasingly important in the future.

Legends to tables and figures:

Table 1: The limb-girdle muscular dystrophies: classification of the entities for which the genetic basis is known.

Table 2. Key clinical features and complications of the limb girdle muscular dystrophies

Table 3. Diagnostic features: creatine kinase and muscle biopsy findings.

Figure 1 :

A diagnostic algorithm for achieving diagnosis in LGMD based on clinical, creatine kinase, muscle biopsy and molecular genetic testing. CK= creatine kinase, CK levels are given as a general guide to levels of CK likely at diagnosis, but this can vary from patient to patient and with disease progression. CK level A= normal or mild elevation (<10x normal) CK level B= moderate elevation (8- 40x normal) CK level C extreme elevation (>40x normal). Other abbreviations: ADEDMD- autosomal dominant Emery Dreifuss muscular dystrophy, EDMDX- X linked EmeryDreifuss muscular dystrophy, PIRCs: percussion induced repetitive contractions.

Table 1: The limb-girdle muscular dystrophies: classification of the entities for which the genetic basis is known.

Type of LGMD	Gene/ protein involved	Protein localisation/ function (if known)	Other phenotypes	References
LGMD1A	Myotilin	Sarcomeric localisation	Myofibrillar myopathy	[11, 12]
LGMD1B	Lamin A/C	Nuclear envelope	Many- see chapter....	[13, 14]
LGMD1C	Caveolin 3	Plasma membrane, caveolae	Dilated cardiomyopathy	[15, 16]

LGMD2A	Calpain 3	Cytoplasmic: proteolytic enzyme		[17, 18]
LGMD2B	Dysferlin	Predominantly plasma membrane: membrane repair	Miyoshi Myopathy, distal muscular dystrophy with anterior tibial involvement	[19, 20]
LGMD2C-F	Alpha, beta, gamma, delta sarcoglycan	Part of dystrophin glycoprotein complex in plasma membrane	Delta sarcoglycan: dilated cardiomyopathy	[21, 22]
LGMD2G	Telethonin	Sarcomeric localisation		[23]
LGMD2H	TRIM32	Ubiquitin ligase	Sarcotubular myopathy, Bardet Biedl Syndrome	[24, 25]
LGMD2I	FKRP	Probable glycosyl transferase: substrate alpha dystroglycan	Congenital muscular dystrophy MDC1C and intermediate phenotypes	[26, 27]
LGMD2J	Titin	Component of sarcomere	Heterozygotes have distal myopathy. Other mutations associated with cardiomyopathy	[28]
LGMD2K	POMT1	Glycosyl transferase	Walker Warburg syndrome and intermediate phenotypes	[2]

Table 2. Key clinical features and complications of the limb girdle muscular dystrophies

Type of LGMD	Age at onset	Key features from history	Key features from examination	Complications	Specific surveillance and treatment
LGMD1A	Usually adult-hood	May be dysarthria, tight TAs, swallowing difficulties	May be distal muscle involvement	Cardiomyopathy, arrhythmia, respiratory failure	Cardiac echo, ECG +/- Holter, FVC in sitting and lying. Treatment with pacing, respiratory support
LGMD1B	Any age	May be family history of sudden death	Joint contractures, rigid spine	Cardiac complications probably invariable: arrhythmia, subsequent cardiomyopathy, respiratory failure	Cardiac echo, ECG +/- Holter, FVC in sitting and lying. High risk of ventricular arrhythmia after pacing so implantable defibrillator indicated. Medical management of cardiomyopathy, respiratory support
LGMD1C	Any age	Myalgia, muscle rippling	PIRCs, rippling, muscle	Not reported with LGMD1C phenotype	

			hypertrophy		
LGMD2A	Typically 2-15: in some patients older	May present with toe walking	Scapular winging, some patients have contractures, often atrophic	Not frequent	
LGMD2B	Most present between 17-25 years	Inability to walk on tip-toe. Around 10% may present with calf pain and swelling	Usually calf wasting, biceps wasting. Shoulder girdle weakness usually later than proximal/ distal lower limb weakness	Not frequent	
LGMD2C-F	May present any age:	May present in Duchenne/ Becker like way	May be muscle hypertrophy, scapular winging	Cardiomyopathy and respiratory failure after confinement to	Cardiac echo and ECG on annual basis, FVC particularly after loss of ambulation, pulse oximetry. Medical management of cardio-myopathy, nocturnal respiratory

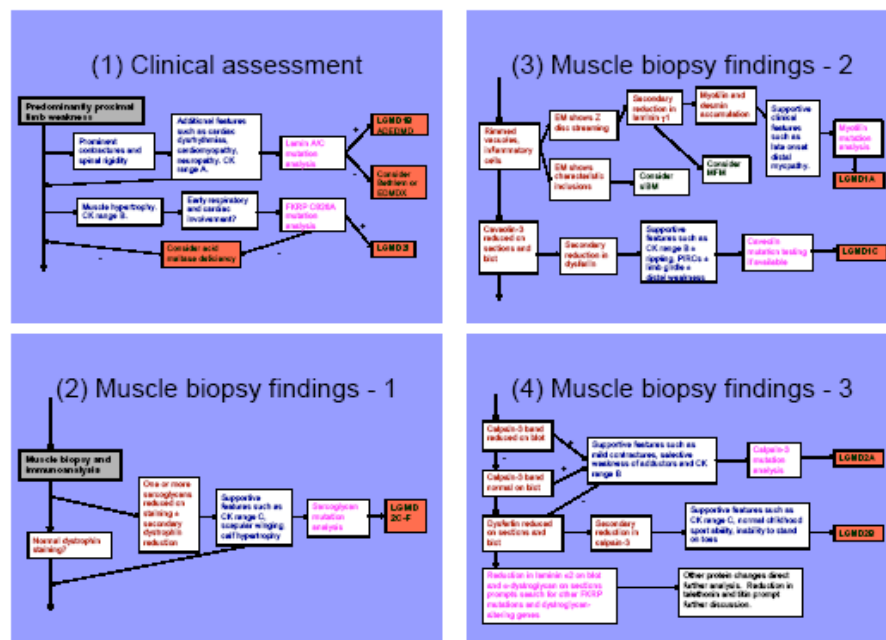
	most in child- hood			wheelchair	support
LGMD2G	2 nd decade		May be distal weakness	Not reported	
LGMD2H	2 nd decade			Not reported	
LGMD2I	Wide range of severity	Clinically may resemble Duchenne/ Becker MD	Muscle hypertrophy	Cardiomyopathy and respiratory failure (diaphragmatic) possible even while still ambulant	Cardiac echo and ECG on annual basis, FVC in sitting and lying at all ages, pulse oximetry. Medical management of cardio-myopathy, nocturnal respiratory support
LGMD2J	1 st decade	History of distal weakness in heterozygotes		Late respiratory complications	
LGMD2K	1 st decade	May present early with global delay	May be mental retardation, microcephaly.	Full spectrum of complications possibly not yet appreciated	

			Upper limb weakness may be worse than lower limb weakness		
--	--	--	--	--	--

Table 3. Diagnostic features: creatine kinase and muscle biopsy findings.

Disease	Creatine kinase levels	Histology	Primary abnormality on immunolabelling	Secondary abnormality on immunolabelling
LGMD1A	Usually normal or mild elevation	Dystrophic, may be desmin accumulation, rimmed vacuoles	myotilin N	↓ laminin γ 1
LGMD1B	Typically normal or mild elevation: severe cases may be higher	dystrophic	lamin A/C N	↓ laminin β 1
LGMD1C	From 3- 10x normal	myopathic, dystrophic	↓ caveolin-3	↓ dysferlin
LGMD2A	Often at least 10x normal	dystrophic	Variable loss on immunoblotting	
LGMD2B	May be up to 100x normal	Dystrophic, may be inflammatory features	↓ dysferlin	(may be ↓ calpain 3, and/or ↓ caveolin 3)
LGMD2C-F	Often at least 10x normal	dystrophic	↓ sarcoglycans	↓ other SGs, dystrophin
LGMD2I	Often at least 10x normal	dystrophic	FKRP antibody not in routine use	↓ laminin α 2, α DG
LGMD2J	Few cases: high CK	Myopathic, dystrophic, may be rimmed vacuoles	↓ titin	↓ calpain-3
LGMD2K	At least 10x normal	dystrophic	POMT1 antibody not in routine use	↓ laminin α 2, α DG

Figure



References:

- [1] A. Starling, F. Kok, M.R. Passos-Bueno, M. Vainzof and M. Zatz. A new form of autosomal dominant limb-girdle muscular dystrophy (LGMD1G) with progressive fingers and toes flexion limitation maps to chromosome 4p21. *Eur J Hum Genet* 12 (2004) 1033-40.
- [2] B. Balci, G. Uyanik, P. Dincer, C. Gross, T. Willer, B. Talim, G. Haliloglu, G. Kale, U. Hehr, J. Winkler and H. Topaloglu. An autosomal recessive limb-girdle muscular dystrophy (LGMD2) with mild mental retardation is allelic to Walker-Warburg syndrome (WWS) caused by a mutation in the POMT1 gene. *Neuromusc Disord* 15 (2005) 271-5.
- [3] V. Nigro. Molecular bases of autosomal recessive limb-girdle muscular dystrophies. *Acta Myol* 22 (2003) 35-42.
- [4] K. Nguyen, G. Bassez, R. Bernard, M. Krahn, V. Labelle, D. Figarella-Branger, J. Pouget, H. Hammouda el, C. Beroud, A. Urtizberea, B. Eymard, F. Leturcq and N. Levy. Dysferlin mutations in LGMD2B, Miyoshi myopathy, and atypical dysferlinopathies. *Hum Mutat* 26 (2005) 165.
- [5] M. Olive, L.G. Goldfarb, A. Shatunov, D. Fischer and I. Ferrer. Myotilinopathy: refining the clinical and myopathological phenotype. *Brain* 128 (2005) 2315-26.
- [6] V. Decostre, R. Ben Yaou and G. Bonne. Laminopathies affecting skeletal and cardiac muscles: clinical and pathophysiological aspects. *Acta Myol* 24 (2005) 104-9.
- [7] S.E. Woodman, F. Sotgia, F. Galbiati, C. Minetti and M.P. Lisanti. Caveolinopathies: mutations in caveolin-3 cause four distinct autosomal dominant muscle diseases. *Neurology* 62 (2004) 538-43.

- [8] K. Bushby, F. Muntoni and J.P. Bourke. 107th ENMC international workshop: the management of cardiac involvement in muscular dystrophy and myotonic dystrophy. 7th-9th June 2002, Naarden, The Netherlands. *Neuromuscul Disord* 13 (2003) 166-72.
- [9] C. Wallgren-Pettersson, K. Bushby, U. Mellies and A. Simonds. 117th ENMC workshop: ventilatory support in congenital neuromuscular disorders - congenital myopathies, congenital muscular dystrophies, congenital myotonic dystrophy and SMA (II) 4-6 April 2003, Naarden, The Netherlands. *Neuromuscul Disord* 14 (2004) 56-69.
- [10] M.L. Sveen, M. Schwartz and J. Vissing. High prevalence and phenotype-genotype correlations of limb girdle muscular dystrophy type 2I in Denmark. *Ann Neurol* 59 (2006) 808-15.
- [11] M.A. Hauser, S.K. Horrigan, P. Salmikangas, U.M. Torian, K.D. Viles, R. Dancel, R.W. Tim, A. Taivainen, L. Bartoloni, J.M. Gilchrist, J.M. Stajich, P.C. Gaskell, J.R. Gilbert, J.M. Vance, M.A. Pericak-Vance, O. Carpen, C.A. Westbrook and M.C. Speer. Myotilin is mutated in limb girdle muscular dystrophy 1A. *Hum Mol Genet* 9 (2000) 2141-7.
- [12] D. Selcen and A.G. Engel. Mutations in myotilin cause myofibrillar myopathy. *Neurology* 62 (2004) 1363-71.
- [13] A. Muchir, G. Bonne, A.J. van der Kooi, M. van Meegen, F. Baas, P.A. Bolhuis, M. de Visser and K. Schwartz. Identification of mutations in the gene encoding lamin A/C in autosomal dominant limb girdle muscular dystrophy with atrioventricular conduction disturbances (LGMD1B). *Hum Mol Genet* 9 (2000) 1453-1459.

- [14] S. Benedetti and L. Merlini. Laminopathies: from the heart of the cell to the clinics. *Curr Opin Neurol* 17 (2004) 553-60.
- [15] T. Hayashi, T. Arimura, K. Ueda, H. Shibata, S. Hohda, M. Takahashi, H. Hori, Y. Koga, N. Oka, T. Imaizumi, M. Yasunami and A. Kimura. Identification and functional analysis of a caveolin-3 mutation associated with familial hypertrophic cardiomyopathy. *Biochem Biophys Res Commun* 313 (2004) 178-84.
- [16] C. Minetti, F. Sotgia, C. Bruno, P. Scartezzini, P. Broda, M. Bado, E. Masetti, M. Mazzocco, A. Egeo, M.A. Donati, D. Volonte, F. Galbiati, G. Cordone, F.D. Bricarelli, M.P. Lisanti and F. Zara. Mutations in the caveolin-3 gene cause autosomal dominant limb-girdle muscular dystrophy. *Nat Genet* 18 (1998) 365-8.
- [17] I. Richard, O. Broux, V. Allamand, F. Fougereousse, N. Chiannikulchai, N. Bourg, L. Brenguier, C. Devaud, P. Pasturaud, C. Roudaut and et. al.. Mutations in the proteolytic enzyme calpain 3 cause limb-girdle muscular dystrophy type 2A. *Cell* 81 (1995) 27-40.
- [18] A. Saenz, F. Leturcq, A.M. Cobo, J.J. Poza, X. Ferrer, D. Otaegui, P. Camano, M. Urtasun, J. Vilchez, E. Gutierrez-Rivas, J. Emparanza, L. Merlini, C. Paisan, M. Goicoechea, L. Blazquez, B. Eymard, H. Lochmuller, M. Walter, C. Bonnemann, D. Figarella-Branger, J.C. Kaplan, J.A. Urtizberea, J.F. Marti-Masso and A. Lopez de Munain. LGMD2A: genotype-phenotype correlations based on a large mutational survey on the calpain 3 gene. *Brain* 128 (2005) 732-42.
- [19] R. Bashir, S. Britton, T. Strachan, S. Keers, E. Vafiadaki, M. Lako, I. Richard, S. Marchand, N. Bourg, Z. Argov, M. Sadeh, I. Mahjneh, G. Marconi, M.R.

- Passos-Bueno, S. Moreira Ede, M. Zatz, J.S. Beckmann and K. Bushby. A gene related to *Caenorhabditis elegans* spermatogenesis factor *fer-1* is mutated in limb-girdle muscular dystrophy type 2B. *Nat Genet* 20 (1998) 37-42.
- [20] J. Liu, M. Aoki, I. Illa, C. Wu, M. Fardeau, C. Angelini, C. Serrano, J.A. Urtizberea, F. Hentati, M.B. Hamida, S. Bohlega, E.J. Culper, A.A. Amato, K. Bossie, J. Oeltjen, K. Bejaoui, D. McKenna-Yasek, B.A. Hosler, E. Schurr, K. Arahata, P.J. de Jong and R.H. Brown, Jr. Dysferlin, a novel skeletal muscle gene, is mutated in Miyoshi myopathy and limb girdle muscular dystrophy. *Nat Genet* 20 (1998) 31-6.
- [21] L.E. Lim and K.P. Campbell. The sarcoglycan complex in limb-girdle muscular dystrophy. *Curr Opin Neurol* 11 (1998) 443-52.
- [22] S. Tsubata, K.R. Bowles, M. Vatta, C. Zintz, J. Titus, L. Muhonen, N.E. Bowles and J.A. Towbin. Mutations in the human delta-sarcoglycan gene in familial and sporadic dilated cardiomyopathy. *J Clin Invest* 106 (2000) 655-62.
- [23] E.S. Moreira, T.J. Wiltshire, G. Faulkner, A. Nilforoushan, M. Vainzof, O.T. Suzuki, G. Valle, R. Reeves, M. Zatz, M.R. Passos-Bueno and D.E. Jenne. Limb-girdle muscular dystrophy type 2G is caused by mutations in the gene encoding the sarcomeric protein telethonin. *Nat Genet* 24 (2000) 163-6.
- [24] B.G. Schoser, P. Frosk, A.G. Engel, U. Klutzny, H. Lochmuller and K. Wrogemann. Commonality of TRIM32 mutation in causing sarcotubular myopathy and LGMD2H. *Ann Neurol* 57 (2005) 591-5.
- [25] P. Frosk, T. Weiler, E. Nylen, T. Sudha, C.R. Greenberg, K. Morgan, T.M. Fujiwara and K. Wrogemann. Limb-girdle muscular dystrophy type 2H

- associated with mutation in TRIM32, a putative E3-ubiquitin-ligase gene. *Am J Hum Genet* 70 (2002) 663-72.
- [26] M. Brockington, D.J. Blake, P. Prandini, S.C. Brown, S. Torelli, M.A. Benson, C.P. Ponting, B. Estournet, N.B. Romero, E. Mercuri, T. Voit, C.A. Sewry, P. Guicheney and F. Muntoni. Mutations in the fukutin-related protein gene (FKRP) cause a form of congenital muscular dystrophy with secondary laminin alpha2 deficiency and abnormal glycosylation of alpha-dystroglycan. *Am J Hum Genet* 69 (2001) 1198-209.
- [27] M. Brockington, Y. Yuva, P. Prandini, S.C. Brown, S. Torelli, M.A. Benson, R. Herrmann, L.V. Anderson, R. Bashir, J.M. Burgunder, S. Fallet, N. Romero, M. Fardeau, V. Straub, G. Storey, C. Pollitt, I. Richard, C.A. Sewry, K. Bushby, T. Voit, D.J. Blake and F. Muntoni. Mutations in the fukutin-related protein gene (FKRP) identify limb girdle muscular dystrophy 2I as a milder allelic variant of congenital muscular dystrophy MDC1C. *Hum Mol Genet* 10 (2001) 2851-2859.
- [28] B. Udd, A. Vihola, J. Sarparanta, I. Richard and P. Hackman. Titinopathies and extension of the M-line mutation phenotype beyond distal myopathy and LGMD2J. *Neurology* 64 (2005) 636-42.