



HAL
open science

Tissue expression of Carbonic Anhydrase IX (CA IX) in different Gleason grades of prostate cancer

Lisa G Smyth, Gillian O'Hurley, Anthony Ogrady, John Fitzpatrick, Elaine Kay,
William Watson

► **To cite this version:**

Lisa G Smyth, Gillian O'Hurley, Anthony Ogrady, John Fitzpatrick, Elaine Kay, et al.. Tissue expression of Carbonic Anhydrase IX (CA IX) in different Gleason grades of prostate cancer. *Prostate Cancer and Prostatic Diseases*, 2009, n/a (n/a), pp.n/a-n/a. <10.1038/pcan.2009.58>. <hal-00495783>

HAL Id: hal-00495783

<https://hal.science/hal-00495783v1>

Submitted on 29 Jun 2010

HAL is a multi-disciplinary open access archive for the deposit and dissemination of scientific research documents, whether they are published or not. The documents may come from teaching and research institutions in France or abroad, or from public or private research centers.

L'archive ouverte pluridisciplinaire **HAL**, est destinée au dépôt et à la diffusion de documents scientifiques de niveau recherche, publiés ou non, émanant des établissements d'enseignement et de recherche français ou étrangers, des laboratoires publics ou privés.



HAL Authorization

Carbonic anhydrase IX expression in prostate cancer

Lisa G Smyth¹ (MB BCh BAO), Gillian O'Hurley² (MSc) , Anthony O'Grady² (PhD), John M Fitzpatrick² (MD), Elaine Kay² (MD), R William G Watson¹ (PhD), University College Dublin School of Medicine and Medical Science, Conway Institute of Biomolecular & Biomedical Research, University College Dublin, Dublin 4¹ and the Pathology department, Beaumont Hospital, P.O. Box 1297, Beaumont Road, Dublin 9, Ireland²

Correspondence: Lisa G Smyth: lisa.smyth@ucd.ie, Conway Institute of Biomolecular & Biomedical Research, University College Dublin, Belfield, Dublin 4, Ireland, Ph; +353 86 865 1892, Fax: +353 1 716 6701.

Abstract

Introduction: Tumour hypoxia is associated with over 70% of solid tumours including prostate and colorectal cancer. Hypoxia promotes tumour progression and resistance to treatment. Carbonic anhydrase IX (CA IX) is an endogenous marker of hypoxia. It is expressed in lung and renal cell carcinomas and is associated with a poor prognosis. CA IX plays an important role in maintaining pH levels in the highly metabolically active cancer cell. The expression of CA IX in prostate cancer has not previously been investigated.

Materials & Methods: Immunohistochemistry was used to examine CA IX expression in 59 patients, using tissue microarrays (TMAs) and full sections of benign prostatic hyperplasia, surrounding stroma and prostate adenocarcinoma. Cores reviewed included 189 benign prostatic hyperplasia, 130 Gleason grade 3, 93 Gleason grade 4, 40 Gleason grade 5. CA IX expression in colorectal cancer and HIF 1 α in prostate cancer acted as positive controls.

Results: There was only occasional cell staining for CA IX expression.

Discussion: Although prostate cancer is a hypoxic tumour it does not express CA IX. This implies it relies on alternative pathways for maintaining pH balance in cancer. These studies would indicate that CA IX is not a suitable marker of hypoxia in prostate cancer.

Key words: hypoxia, prostate cancer, carbonic anhydrase IX

Introduction

Prostate cancer is the most common solid tumour affecting men. Tumour hypoxia is characteristic of a wide range of solid tumours such as prostate, breast and head and neck tumours [1, 2]. Hypoxia promotes tumour progression [3] and resistance to therapeutic treatment [4] through reduced apoptosis, increased proliferation and angiogenesis. Tumour hypoxia can be measured by immunohistochemical analysis of endogenous markers, exogenous drugs (2-nitroimidazoles), needle probe estimation and imaging techniques. Endogenous markers commonly used in prostate cancer are HIF 1 α and VEGF [5]. There are methodological difficulties as a result of extended fixation and surgical ischaemia on levels of HIF1 α in addition to the dilemma of measuring nuclear or cytoplasm levels. Carbonic anhydrase IX (CA IX) has been used as an endogenous marker of hypoxia in a range of solid tumours including bladder, renal cell, lung and tumours of the head and neck [6-9]. CA IX expression is associated with a more aggressive phenotype and resistance to treatment.

Hypoxia occurs in the prostate as a result of inflammation, cell remodelling, proliferating tumour cells and abnormal tumour vasculature. As a result of hypoxia cell metabolism switches to anaerobic glycolysis leading to the production of acidic metabolites. Adaptation of cells to hypoxia and acidosis is vital for cell survival and tumourigenesis. The pH of solid tumours is significantly more acidic than that of normal tissues and impairs the uptake of weakly basic chemotherapeutic drugs thus reducing their anti cancer effect on the tumours [10-12]. Carbonic anhydrases are a group of zinc containing

metalloenzymes that are involved in pH balance and the reversible conversion of carbon dioxide to bicarbonate and protons [13]. They facilitate diffusion and active transport with membrane associated ion transport systems such as sodium- hydrogen exchanger and chloride- bicarbonate anion exchanger. The CAs are located in the normal mucosa of the intestinal tract, gallbladder and seminal ducts. CA IX is found in high concentrations in the rapidly dividing Krypts of Luberkuhn [14]. CA IX is up regulated in hypoxia in response to HIF 1 alpha binding to the hypoxia responsive element of CA IX promoter [13, 15-17]. They have a pro-survival function maintaining intra-cellular pH (pHi) high preventing cell death and extracellular pH (pHe) low (6.9-7.0) [18] ensuring cell growth and invasion through activation of proteolytic and signal transduction pathways. Research in CA IX has led to the development of specific inhibitors [19]. The objective of this study was to investigate if CA IX is upregulated in prostate cancer.

Materials and Methods

Patients: This study included 59 patients with a wide range of Gleason scores (5-10) who underwent radical retropubic prostatectomy (RRP) in the Mater Misericordiae University Hospital and St James's Hospital between 2002-2008 for prostate adenocarcinoma. These samples were collected as part of the Prostate Cancer Research Consortium with ethical approval.

Pathological specimens: TMAs and full sections were examined for CA IX expression. TMAs were constructed from 59 RRP specimens using the Beecher Instruments Tissue-Arrayer™ (Beecher Instruments, Silver Spring, MD). Suitable formalin fixed paraffin

embedded blocks of each case representing as many Gleason grades as possible were selected. The corresponding Haematoxylin and Eosin (H&E) stained sections were reviewed by a Pathologist (EK). One to three cores from histologically benign glands and from each grade of prostate cancer were sampled from each case where available. A total of 189 areas of histologically benign glands, 130 areas of Gleason grade 3, 93 areas of Gleason grade 4 and 40 areas of Gleason grade 5 were present on the TMAs. Representative full sections from 5 cases used in the TMAs were also examined for CA IX. These full sections consisted of histologically benign glands and prostate adenocarcinoma.

Immunohistochemistry: Tissue microarray sections (4µm) and full sections underwent deparaffinization, antigen retrieval and immunohistochemistry on an automated immunohistochemistry (ICH) platform (Bond MaxTM-Leica Microsystems). 3'3 Daiminobenzidine (DAB) was used as a chromagen with a polymer detection system, resulting in a brown end colour. Table 1 shows the optimal antigen retrieval and optimal concentrations of primary antibodies determined for immunohistochemistry. Sections were counterstained with haematoxylin. The immunohistochemical reactivity of the proteins analysed were scored in a blinded fashion with regard to histological diagnosis by a single observer (GOH), and 10% were randomly spot checked by a pathologist (EK).

Results

Immunohistochemical analysis of CA IX expression on TMAs:

Overall histologically benign glands and all grades of prostate cancer had negative immunoexpression for CA IX. However, positivity was noted in the nuclei of two epithelial cells in a Gleason grade 3 tumour from one case (Fig. 1K, see arrows).

Immunohistochemical analysis of CA IX expression on full sections:

There was no CA IX expression in the prostate full sections analysed. The findings of the full sections reflected those of the TMAs

Discussion

CA IX usually stains heterogeneously with the highest intensity adjacent to areas of necrosis or on luminal surfaces or papillary structures [20]. Renal cell carcinoma (RCC) is an exception; it demonstrates a uniform staining pattern. This is thought to be as a result of constitutively up-regulated HIF 1 α pathway secondary to the inactivity of the von Hippel Lindau (VHL) gene [13]. CA IX is now the best and most powerful diagnostic and predictive marker of clear cell RCC [21]. RCC stain positively for CA IX in 94% of cases [22] and this is associated with poor prognosis [8].

In colon cancer CA IX tends to stain the epithelial cell membrane. One large study demonstrated that it tends to stain early Dukes' stage and lymph node negative rectal cancer[23]. In transitional cell carcinoma of the bladder CA IX expression is also

predominantly membranous and occurs in luminal, peri-necrotic areas or infrequently nuclear staining has been demonstrated [6].

Prostate cancer is associated with hypoxia as shown on needle electrode studies [24] and up regulation of endogenous markers of hypoxia, HIF 1 alpha and VEGF [25]. However we have shown only scattered cells staining for CA IX. To ensure that hypoxic areas were not missed on TMA we also stained full sections and the results reflected that of the TMAs.

Cells use different mechanisms for pH regulation in addition to the carbonic anhydrases there are the proton extruders; Na^+ / H^+ exchanger (NHE), HCO_3^- - based H^+ - transporting mechanisms, monocarboxylate transporters (MCT1 & MCT4) and Vacuolar-type H^+ ATPases (V-ATPases).

The V-ATPases are proton pumps composed of 14 subunits. They are organized into 2 domains (V_1 and V_0). The V_1 domains carries out hydrolysis of ATP while V_0 domain carries out proton transport. They are involved in pH regulation, renal tubule acidification, and bone resorption [26]. They are regulated by several mechanisms including glucose dependent V_1 and V_0 dissociation and by their cellular localization [27]. They have been demonstrated on the apical surface of human prostate epithelial cells [28]. They are up regulated in certain cancers and their metastases. Immunocytochemical and confocal microscopy studies have demonstrated the presence of the V-ATPases on the cell surface of breast cancer cells [12].

Monocarboxylate transporters (MCTs) are involved in the efflux of lactic acid, pyruvate, acetate and butyrate from the cell [29]. This is carried out through the co-transport of H⁺ with the above monocarboxylate anions [30]. There are four known members (MCT1-4). MCT 4 is the most common in cells with a high glycolytic rate such as tumor cells [31] and is shown to accumulate on the migrating surface of cells[29]. It is known to be inducible by hypoxia in bladder cancer cells [32]. They may have a role in the acidification of the pHe in prostate cancer. Although further studies are required to elucidate the exact pH regulation mechanism involved in prostate cancer we have given new insight into prostate cancer cell physiology and clearly demonstrated that CA IX is not expressed in cancer of the prostate.

Although prostate cancer is a hypoxic tumour it does not express CA IX and cannot be used as an endogenous marker of hypoxia. We hypothesise that the prostate depends on alternative mechanisms for pH regulation.

Acknowledgements

This study was supported by individual grants from the British Urological Foundation and the Joint RCSI/UCD Surgical Research Grant Incorporating the Gussie Mehigan Scholarship. We thank Professor Adrian Harris, Molecular Oncology laboratories, University of Oxford for the gift of the M75 antibody.

Conflict of interest statement

The authors declare no competing financial interests.

References

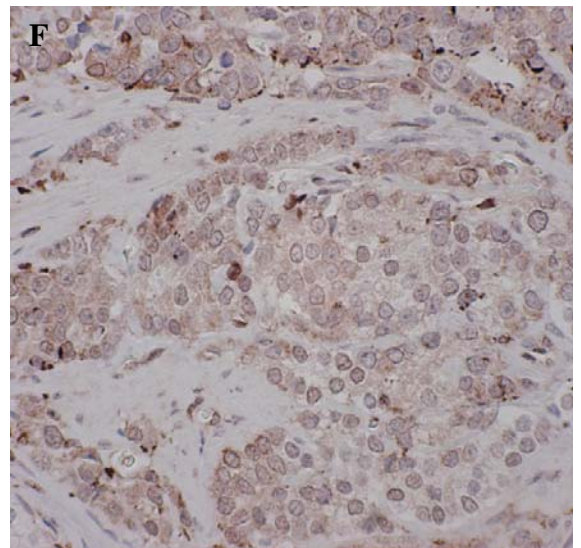
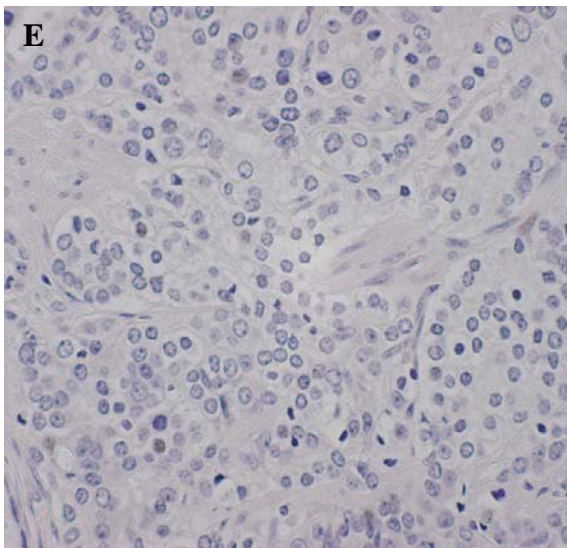
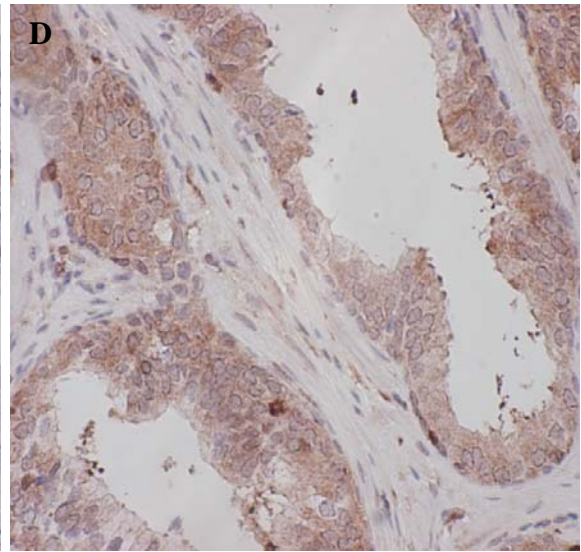
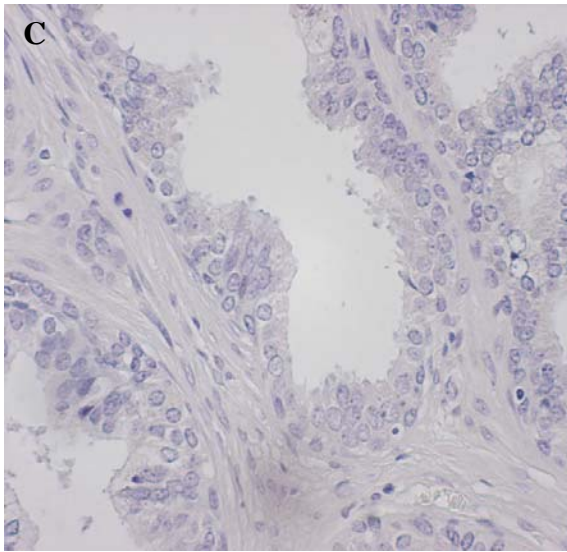
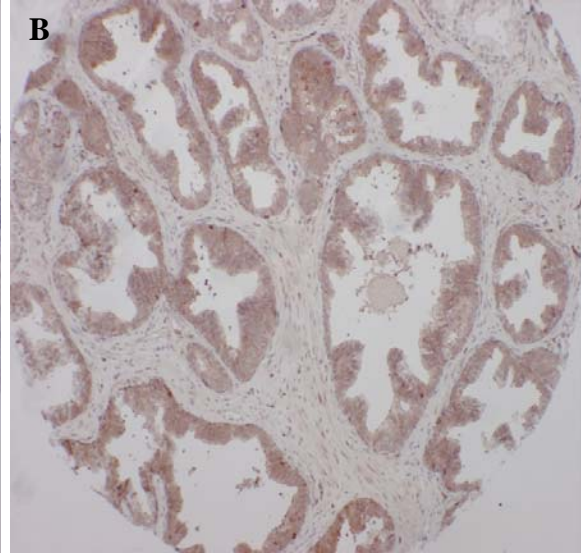
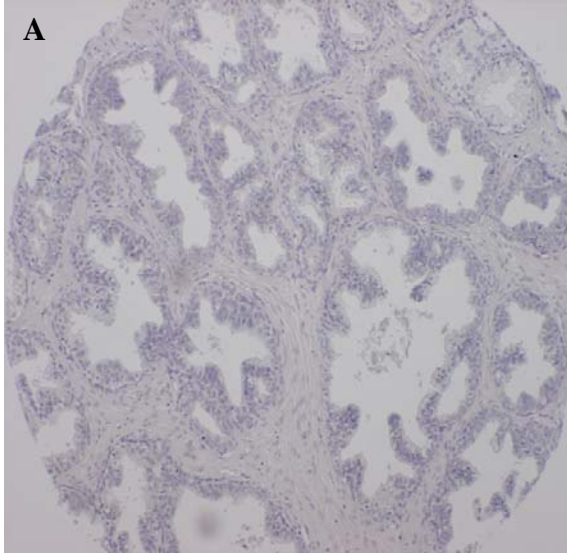
1. Vaupel, P., *Hypoxia in breast cancer: Pathogenesis, characterisation and biological/therapeutic implications*. Wiener Medizinische Wochenschrift, 2002. **152**: p. 334-342.
2. Marginol, L., Coffey, M., Lawlor, M., Hollywood D., *Hypoxia in prostate cancer: a powerful shield against tumour destruction?* Cancer Treat Rev, 2008. **34**(4): p. 313-27.
3. Hoekel, M., Vaupel, P., *Biological consequences of tumour hypoxia*. Semin Oncol, 2001. **28**: p. 26-41.
4. Harris, A., *Hypoxia a key regulatory factor in tumour growth*. Nat Rev Cancer, 2002. **2**: p. 38-47.
5. Vergis, R., Corbishley, CM., Norman, AR., Bartlett, J., Jhavar, S., Borre, M., et al., *Intrinsic markers of hypoxia and angiogenesis in localised prostate cancer and outcome of radical treatment: a retrospective analysis of two randomised radiotherapy trials and one surgical cohort study*. Lancet Oncol, 2008. **9**: p. 342-51.
6. Sherwood, B., Colquhoun, AJ., Richardson, D., Bowman, KJ., O'Byrne, KJ., et al., *Carbonic anhydrase IX expression and outcome after radiotherapy for muscle-invasive bladder cancer*. Clin Oncol (R Coll Radiol), 2007. **19**(10): p. 777-83.
7. Swinson, D., Jones, JL., Richardson, D., *Carbonic anhydrase IX expression, a novel surrogate marker of tumour hypoxia, is associated with a poor prognosis in non-small- cell lung cancer*. J Clin Oncol, 2003. **21**: p. 473-82.
8. Bui, M., Seligson, D., Han, KR., Pantuck, AJ., Dorey, FJ, Huang, Y, et al., *Carbonic anhydrase IX is an independent predictor of survival in advanced renal clear cell carcinoma: implications for prognosis and therapy*. Clinical Cancer Research, 2003(9): p. 802-811.
9. Schrijvers, M., van der Laan, BF., de Bock, GH., Pattje, WJ., Mastik, MF., Menkema, L., et al., *Overexpression of intrinsic hypoxic markers HIF1 alpha and CA IX predict for local recurrence in stage T1-T2 glottic laryngeal carcinoma treated with radiotherapy*. Int J Radiat Oncol Biol Phys., 2008. **72**(1): p. 161-9.
10. Sennoune, S., Luo, D., Martinez-Zaguilam, R., *Plasma-lemmal vacuolar-type H⁺-ATPase in cancer biology*. Cell Biochem Biophys, 2004(40): p. 185-206.
11. Nishi, T., Forgac, M., *The vacuolar (H⁺)-ATPases- nature's most versatile proton pumps*. Nature Rev Mol Cell Biol, 2002(3): p. 94-103.

12. Sennoune, S., Bakunts, K., Martinez, GM., *Vacuolar H⁺-ATPase in human breast cancer cells with distinct metastatic potential: distribution and functional activity.* Am J Physiol Cell, 2004. **286**: p. 1443-52.
13. Potter, C., Harris, AL., *Hypoxia inducible carbonic anhydrase IX, marker of tumour hypoxia, survival pathway and therapy target.* Cell Cycle, 2004(3): p. 164-167.
14. Saarnio, J., Parkkila, S., Parkkila, AK., *Immunohistochemistry of carbonic anhydrase isozyme in human gut reveals polarised expression in the epithelial cells with the highest proliferative capacity.* Cytochem, 1998. **46**: p. 497-504.
15. Zavada, J., Zadadova, Z., Pastorek, J., Biesova, Z., Jezek, J., Velek, J., *Human tumour-associated cell adhesion protein MN/CA IX: identification of M75 epitope and of the region mediating cell adhesion.* BrJ Cancer, 2000. **82**: p. 1808-1813.
16. Svastova, E., Zilka, N., Zat'ovicova, M., Gibadulinova, A., Ciampor, F., Pastorek, J., *Carbonic anhydrase IX reduces E-cadherin-mediated adhesion of MDCK cells via interaction with beta-catenin.* Exp Cell Res, 2003. **290**: p. 332-345.
17. Robertson, N., Potter, C., Harris, AL., *Role of carbonic anhydrase IX in human tumour cell growth, survival and invasion.* Cancer Research, 2004. **64**: p. 6160-6165.
18. Parkkila, S., *Significance of pH regulation and carbonic anhydrases in tumour progression and implications for diagnostic and therapeutic approaches.* BJU Int., 2008. **Supp 4**: p. 16-21.
19. Winum, J., Innocenti, A., Scozzafava, A., Montero, JL., Supuran, CT, *Carbonic anhydrase inhibitors. Inhibition of the human cytosolic isoforms I and II and transmembrane, tumor-associated isoforms IX and XII with boronic acids.* Bioorg Med Chem, 2009. **17**(10): p. 3649-52.
20. Klatter, T., Belldegrun, AS., Pantuck, AJ., *The role of carbonic anhydrase IX as a molecular marker for transitional cell carcinoma of the bladder.* BJU Int., 2008. **101**(Supp 4): p. 45-48.
21. Belldegrun, A., Bevan, P., *Carbonic anhydrase IX: role in the diagnosis and cancer therapy. Introduction.* BJU Int., 2008. **101**(Supp 4): p. 1.
22. Said, J., *Biomarker discovery in urogenital cancer.* Biomarkers, 2005. **10** p. 83-6.
23. Rasheed, S., Harris, AL., Tekkis, PP., Silver, A., McDonald, PJ., Talbot IC., et al., *Assessment of microvessel density and carbonic anhydrase-9 (CA-9) expression in rectal cancer.* Pathol Res Pract, 2009. **205**(1): p. 1-9.
24. Parker, C., Milosevic, M., Toi, A., Sweet, J., Panzarella, T., et al., *Polarographic electrode study of tumour oxygenation in clinically localised prostate cancer.* Int J Radiat Oncol Biol Phys., 2004. **58**(3): p. 750-7.
25. Lekas, A., Lazaris, AC., Deliveliotis, C., Chrisofos, M., Zoubouli, C., Lapas, D., Papatomas, T. et al, *The expression of hypoxia-inducible factor-1alpha and angiogenesis in hyperplastic and malignant prostate tissue.* Anticancer, 2006. **26**(4B): p. 2989-93.
26. Forgac, M., *Vacuolar ATPases: rotary proton pumps in physiology and pathophysiology.* Nature Rev/ Molecular Cell Biology, 2007. **8**: p. 917-929.
27. Jefferies, K., Cipriano, DJ., Forgac, M., *Function, structure and regulation of the vacuolar (H⁺)-ATPases.* Arch Biochem and Biophysics, 2008. **476**(1): p. 33-42.

28. Herak-Kramberger, C., Breton, S., Brown, D., Kraus, O., Sabolic, I., *Distribution of the vacuolar H⁺ ATPase along the rat and human male reproductive tract*. Biol Reprod, 2001. **64**(6): p. 1699-707.
29. Stock, C., Schwab, A., *Protons make tumour cells move like clockwork*. Pflugers Arch., 2009.
30. Halestrap, A., Meredith, D., *The SLC16 gene family-from monocarboxylate transporters (MCTs) to aromatic amino acid transporters and beyond*. Pflugers Arch., 2004. **447**(5): p. 619-28.
31. Halestrap, A., Price, NT., *The proton linked monocarboxylate transporter (MCT) family: structure, function and regulation*. Biochem J, 1999. **343**(2): p. 281-99.
32. Ord, J., Streeter, EH., Roberts, IS., Cranston, D., Harris, AL., *Comparison of hypoxia in vitro with in vivo gene expression in human bladder cancer*. Br J Cancer, 2005. **93**(3): p. 346-54.

<u>Protein</u>	<u>Antibody</u>	<u>Antibody Company</u>	<u>Optimal Dilution</u>	<u>Optimal Epitope Retrieval for Bond Max™ - Leica Microsystems</u>
CA IX	anti-CA IX monoclonal M75 antibody	(Research Gift)	1\100	No Epitope Retrieval
HIF-1 α	anti-HIF-1 α Polyclonal, mono-specific HPA001275	Atlas Antibodies	1\200	ER 2 for 20 mins

Table 1. Summary of antibodies used for immunohistochemistry staining



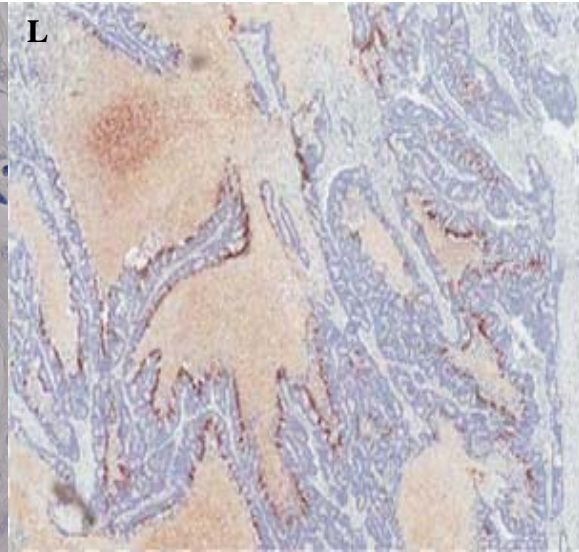
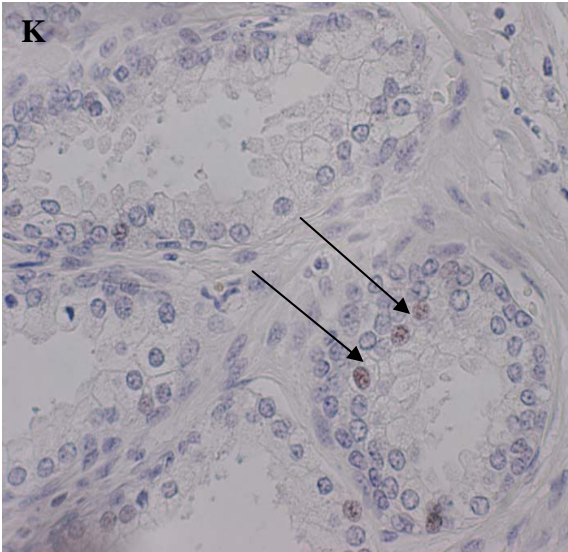
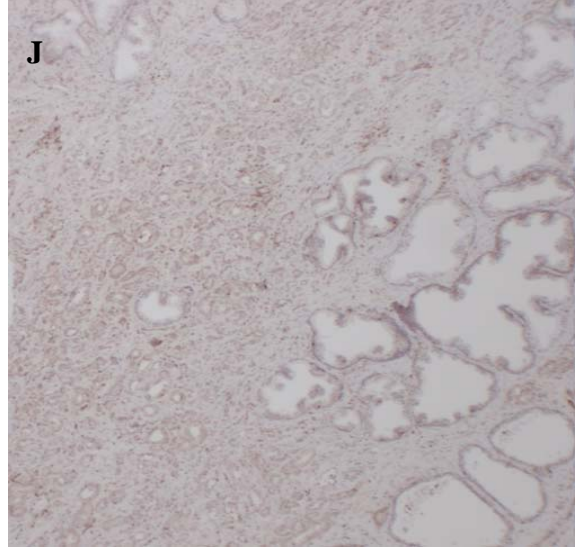
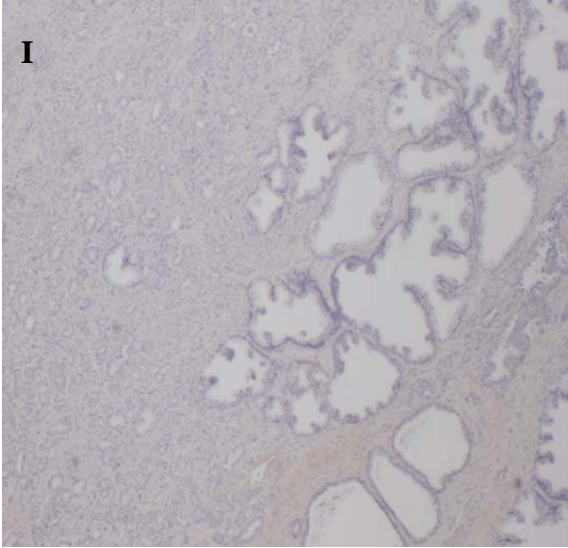
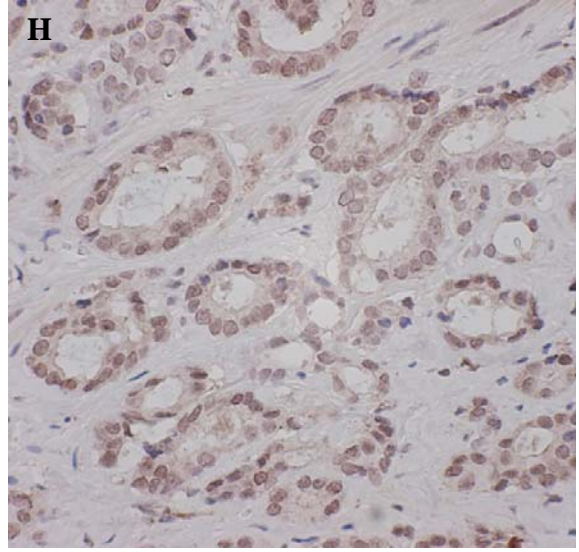
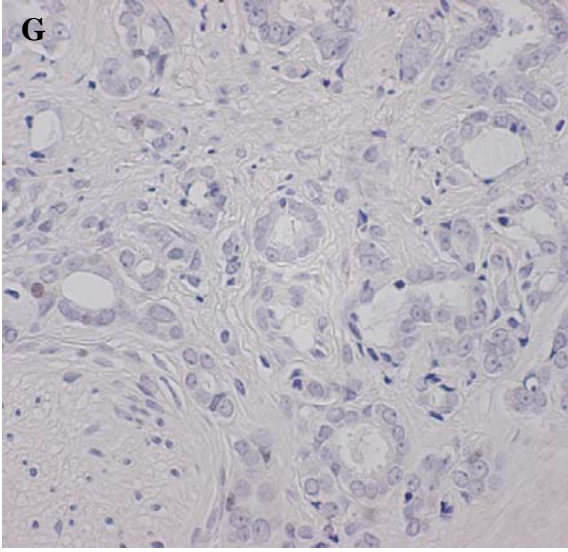


Fig.1. Immunohistochemistry results for CA IX and HIF 1 α in corresponding cores/sections of benign prostatic hyperplasia (BPH) and prostate adenocarcinoma. **(A):** Benign prostatic hyperplasia (BPH) TMA negative for CA IX. **(B):** BPH TMA staining positively for HIF 1 α . **(C):** High power BPH (TMA) negative epithelial/ stromal staining for CA IX. **(D):** High power BPH (TMA) positive epithelial staining for HIF 1 α . **(E):** High grade tumour (TMA) epithelial/ stroma negative for CA IX. **(F):** High grade tumour (TMA) strongly positive epithelial staining for HIF 1 α . **(G):** Low grade tumour (TMA) negative for CA IX. **(H):** Low grade tumour (TMA) positive for HIF 1 α . **(I):** Negative whole section of tumour for CA IX. **(J):** Positive whole section of tumour positive for HIF 1 α . **(K):** CA IX positive nuclei in a Gleason grade 3 tumour (see arrows) **(L):** CA IX positive control in colorectal cancer.