



HAL
open science

Functional and Structural Changes in the Memory Network Associated with Left Temporal Lobe Epilepsy

Natalie L Voets, Jane E Adcock, Richard Stacey, Yvonne Hart, Katherine Carpenter, Paul M Matthews, Christian F Beckmann

► **To cite this version:**

Natalie L Voets, Jane E Adcock, Richard Stacey, Yvonne Hart, Katherine Carpenter, et al.. Functional and Structural Changes in the Memory Network Associated with Left Temporal Lobe Epilepsy. *Human Brain Mapping*, 2009, 30 (12), pp.4070-n/a. 10.1002/hbm.20830 . hal-00490914

HAL Id: hal-00490914

<https://hal.science/hal-00490914>

Submitted on 10 Jun 2010

HAL is a multi-disciplinary open access archive for the deposit and dissemination of scientific research documents, whether they are published or not. The documents may come from teaching and research institutions in France or abroad, or from public or private research centers.

L'archive ouverte pluridisciplinaire **HAL**, est destinée au dépôt et à la diffusion de documents scientifiques de niveau recherche, publiés ou non, émanant des établissements d'enseignement et de recherche français ou étrangers, des laboratoires publics ou privés.



Functional and Structural Changes in the Memory Network Associated with Left Temporal Lobe Epilepsy

Journal:	<i>Human Brain Mapping</i>
Manuscript ID:	HBM-09-0036.R2
Wiley - Manuscript type:	Technical Report
Date Submitted by the Author:	21-Apr-2009
Complete List of Authors:	Voets, Natalie; University of Oxford, FMRIB Centre; GSK Clinical Imaging Centre, Imperial College London Adcock, Jane; John Radcliffe Hospital, Dept of Clinical Neurology Stacey, Richard; John Radcliffe Hospital, Dept of Neurosurgery Hart, Yvonne; John Radcliffe Hospital, Dept of Clinical Neurology Carpenter, Katherine; John Radcliffe Hospital, Russell Cairns Unit Matthews, Paul; GSK Clinical Imaging Centre, Imperial College London; Imperial College London, Dept Clinical Neurosciences Beckmann, Christian; Imperial College London, Dept Clinical Neurosciences; FMRIB Centre, Dept Clinical Neurology
Keywords:	Independent Component Analysis, Memory, fMRI, DTI, functional connectivity, Temporal Lobe Epilepsy



Voets, N.L., et al.

Functional and Structural Changes in the Memory Network associated with Left Temporal Lobe

Epilepsy

TECHNICAL REPORT

Voets N.L.^{1,2}, Adcock J.E.³, Stacey R.⁴, Hart Y.³, Carpenter K.⁵, Matthews P.M.^{2,6}, Beckmann C.F.^{1,6}

¹ FMRIB Centre, Department of Clinical Neurology, University of Oxford

² GlaxoSmithKline Clinical Imaging Centre, Clinical Pharmacology and Discovery Medicine, Hammersmith Hospital, London

³ Department of Clinical Neurology, John Radcliffe Hospital, Oxford

⁴ Department of Neurosurgery, John Radcliffe Hospital, Oxford

⁵ Russell Cairns Unit, John Radcliffe Hospital, Oxford

⁶ Department of Clinical Neurosciences, Imperial College, London

Corresponding author: Natalie L Voets

Corresponding address: FMRIB Centre, John Radcliffe Hospital, Headington, Oxford OX3 9DU

Tel: +44 (0) 20 8008 6051

Fax: +44 (0) 20 8008 6491

Email: natalie@fmrib.ox.ac.uk

Abstract: 245

Article Word Count: 4438

Figures: 5

Tables: 1

Short Title: **Imaging Functional Plasticity of Memory**

Keywords: Temporal Lobe Epilepsy, Memory, fMRI, DTI, functional connectivity, Independent

Component Analysis

Deleted: 1

Deleted: 27

Page 1 of 27

Voets, N.L., et al.

1
2
3
4 **ABSTRACT**

5 Understanding functional plasticity in memory networks associated with Temporal Lobe Epilepsy (TLE) is
6 central to predicting memory decline following surgery. However, the extent of functional reorganisation
7 within memory networks remains unclear. In this preliminary study, we used novel analysis methods
8 assessing network-level changes across the brain during memory task performance in patients with TLE to
9 test the hypothesis that hippocampal functions may not readily shift between hemispheres, but instead may
10 show altered intra-hemispheric organisation with unilateral damage. **In addition, we wished to relate**
11 **functional differences to structural changes along specific fibre pathways associated with memory function.**
12 9 pre-operative patients with intractable left TLE and 10 healthy controls underwent functional MRI during
13 complex scene encoding. Diffusion tensor imaging was additionally performed in the same patients. In our
14 study, we found no evidence of inter-hemispheric shifts in memory-related activity in TLE using standard
15 General Linear Model Analysis. However, Tensor Independent Component Analysis revealed significant
16 reductions in functional connectivity between bilateral MTL, occipital and left orbitofrontal regions **among**
17 **others** in left TLE. This altered **orbitofrontal** activity was directly related to measures of fornix tract
18 coherence in patients ($p < 0.05$). Our results suggest that specific fibre pathways, potentially affected by
19 MTL neurodegeneration, may play a central role in functional plasticity in TLE and highlight the
20 importance of network-based analysis approaches. Relative to standard model-based methods, novel
21 objective functional connectivity analyses may offer improved sensitivity to subtle changes in the
22 distribution of memory functions relevant for surgical planning in TLE.
23
24
25
26
27
28
29
30
31
32
33
34
35
36
37
38
39
40
41
42
43
44
45
46
47
48
49
50
51
52
53
54
55
56
57
58
59
60

Deleted: 1

Deleted: 27

Voets, N.L., et al.

INTRODUCTION

Surgical resection of epileptogenic medial temporal lobe tissue is a highly effective treatment for medically intractable unilateral temporal lobe epilepsy (TLE). However, mounting data suggest that metabolic and structural changes extend beyond the medial temporal lobe (MTL) even with localised seizures, including to temporal stem white matter (Joo et al., 2005) and ipsilateral frontal regions (Savic et al., 1997). These extra-temporal metabolic changes in TLE have been related to, among others, deafferentation (e.g. Cendes et al., 1994) and demyelination (Meiners et al., 2000). Consistent with this notion, changes in fractional anisotropy (FA) and diffusivity have been noted in TLE patients along direct hippocampal efferent pathways such as the fornix (Concha et al., 2005). However, the network-level impact of neuronal loss in the MTL on specific fibre pathways and associated functional systems remains unclear.

Preoperatively, patients with Left TLE typically demonstrate verbal memory deficits (e.g. Hermann et al., 1992). However, their relatively limited memory impairments in the presence of potentially extensive unilateral hippocampal pathology has suggested functionally compensatory mechanisms associated with chronic seizures. The localisation of memory functions therefore remains critical in the pre-surgical evaluation of individual unilateral TLE patients to minimize the risk of post-operative amnesic syndromes.

Non-invasive imaging studies suggest the potential for functional MRI (fMRI) to predict post-operative memory decline (Rabin et al., 2004; Powell et al., 2007a). Confident localisation of memory functions using fMRI, however, remains challenging due to hardware, physiological and statistical issues. The lack of validated, objective method for determining clinically meaningful hemispheric shifts in activation limits characterisation of functional plasticity in memory networks (e.g. Seghier et al., 2008; Chlebus et al., 2007; Jansen et al., 2006). For example, many studies (including ours) of language- and memory-related changes in TLE have assessed inter-hemispheric shifts using laterality indices based on a simple count of “significantly” activated voxels in a region of the left hemisphere compared with the right. Such calculations are inherently dependent on selection of arbitrary statistical thresholds at which to compare left and right hemisphere activations, a problem in itself as the ‘correct’ way to determine significance of fMRI results remains an area of ongoing research. Unsurprisingly, both evidence supporting (e.g. Deblaere et al.,

Deleted: 1

Deleted: 27

Voets, N.L., et al.

2005; Vannest et al., 2008) and contraindicating (e.g. Rabin et al., 2004; Cheung et al., 2006) absolute changes in the laterality of memory-related activation in TLE has been reported.

In addition to methodological limitations, pathophysiological mechanisms contributing to refractory seizures such as abnormal axonal and dendritic sprouting (e.g. Mathern et al., 1996, Rao et al., 2006, Siddiqui et al., 2005) could also contribute to negative findings of interhemispheric shifts in memory functions. We therefore hypothesized that unilateral epilepsy may affect the relative communication between distinct but related anatomical regions within a wider memory network rather than inducing reorganization of memory functions to the contra-lesional hippocampus. Independent Component Analysis methods measuring correlations in fMRI signals across all voxels of the brain during task performance (but independent of task models) have recently shown increased sensitivity, as compared with model-based approaches, to disease-related differences in functional processing (Rombouts et al., 2009). To test our hypothesis, we studied a small group of patients with unilateral left TLE to directly compare standard model-based methods with novel, objective functional connectivity analyses sensitive to network-level changes across the whole brain. To our knowledge, such a comparison has not previously been conducted to assess functional reorganization with disease. In addition, we wished to relate any resulting functional differences to structural changes along specific fibre pathways associated with memory function.

A variety of fMRI memory paradigms has been described in the literature, spanning encoding and retrieval/recognition for a range of stimuli from autobiographical (hometown) and spatial navigation (virtual town) to word, face, scene, and pattern items. We chose to examine complex scene encoding, as this has been shown to engage bilateral MTL regions (Stern et al, 1996, Rombouts et al., 2001) through use of both verbal and visuo-spatial encoding strategies (Detre et al., 1998), thus presenting an ideal task for both left and right TLE patients as part of a larger fMRI battery. As TLE is associated with hippocampal dysfunction, we set out to test whether memory-encoding functional connectivity differences between LTLE patients and controls relate to alterations in structural connectivity along the fornix, the primary hippocampal efferent pathway. However, as the contribution of specific fibre pathways to the encoding of stimuli that may be processed through both verbal and spatial routes is unknown, (see, for example, an elegant study by Gaffan

Deleted: 1

Deleted: 27

Voets, N.L., et al.

et al., (2001) demonstrating composite effects on visual 'scene' learning impairments of fornix transections added to temporal stem resections), we also investigated uncinate structural coherence.

Using fMRI and DTI in patients with left TLE and healthy volunteers, we tested whether (i) LTLE is associated with overt inter-hemispheric reorganisation of memory functions, (ii) LTLE is associated with altered functional connectivity (for example, intra-hemispherically) in the memory network, and (iii) changes in the relative distribution of memory activations relate to altered coherence of fibre pathways. Evidence for the latter could have potentially important implications for pre-surgical planning.

SUMMARY OF MATERIALS & METHODS USED

Subjects

Nine right-handed pre-operative patients with intractable LTLE (mean age 34 years, range 18-47) being evaluated by the Oxford Epilepsy Surgery Service were included (Table 1). Data for an additional LTLE patient was rejected due to a technical issue with the data. A dedicated epilepsy surgery team determined that each patient had intractable left TLE on the basis of ictal video EEG, MRI, neuropsychological assessment and, where available, amytal test results. Clinical Neuropsychological examination was performed for all but one of the patients and included the Weschler Adult Intelligence Scale (WAIS-III), verbal fluency measures and the Adult Memory and Information Processing (AMPIB) form. Ten neurologically normal healthy volunteers (mean age 29, range 24-38) also took part. All volunteers gave written informed consent to take part in the study. The research was conducted in accordance with the principles of the Declaration of Helsinki and the study was approved by the Berkshire Local Research Ethics Committee.

Imaging methods

Blood-Oxygen-Level-Dependent (BOLD) fMRI data were acquired on a 3T Siemens-Varian scanner while subjects performed a complex visual memory-encoding task similar to that described in (Rombouts et al., 2001). Prior to scanning, subjects were familiarized with a set of 10 colour photographs depicting landscapes, animals, unfamiliar people or buildings shown in random order a total of ten times. Each image

Deleted: 1

Deleted: 27

Voets, N.L., et al.

was presented for 4 seconds with a one second inter-stimulus interval. To ensure each image was seen and to facilitate encoding, subjects indicated whether a building was present in the image using a button box. During the fMRI scan, subjects viewed 50s alternating blocks of these (randomized) “familiar” images and sets of novel images. Subjects again indicated the presence of a building in each image. Single-shot echo-planar T2*-weighted images were acquired continuously using the following acquisition parameters: TR=3s, TE=30ms, voxel dimensions 3x4x5mm, 5mm slice thickness.

Whole-head diffusion data sets (60 slices, 2.5mm thickness) consisted of 3 non-diffusion-weighted and 60 diffusion-weighted images acquired with a b value of $1000 \text{ s}\cdot\text{mm}^{-2}$ (TE=106 ms, effective TR of 20 R-R intervals, half k-space acquisition, matrix=62x96, FOV=240x240 mm²). The images were interpolated to achieve a matrix size of 128×128 and a final resolution of $1.875 \times 1.875 \times 2.5 \text{ mm}^3$. The protocol used a doubly-refocused spin-echo sequence to minimise eddy currents (Reese et al., 2003) and cardiac gating to minimise pulsatile motion artefacts (Nunes et al., 2005).

fMRI Data Analysis: Model-based analyses

fMRI data acquired during task performance were analysed both using model-based and model-free methods. In the model-based approach, data were analysed using a whole-brain General Linear Model (GLM) (FEAT, part of FSL, www.fmrib.ox.ac.uk/fsl/) (Smith et al., 2004). Pre-processing steps included: motion correction (Jenkinson et al., 2002), spatial smoothing (Gaussian kernel, full-width half-maximum 5mm) and high-pass temporal filtering. Activation maps were generated using cluster statistics performed on all voxels above a threshold of $z=2.3$ with a corrected cluster extent threshold of $p<0.05$.

As whole-brain multiple comparison correction may be overly stringent when examining localised MTL activity, the GLM analysis was repeated using a voxel-wise approach confined to a region-of-interest (ROI) defined on the standard MNI152 brain template incorporating hippocampal and parahippocampal labels from the Harvard-Oxford standard brain atlas. This probabilistic atlas is based on manual segmentations of cortical and subcortical regions defined in 38 individual subject T1-weighted structural images, carried out at the Centre for Morphometric Analysis at Harvard University, Boston, MA, USA. Due to the proximity

Deleted: 1

Deleted: 27

Voets, N.L., et al.

1
2 of MTL regions to cerebrospinal fluid surrounding the brainstem, a threshold was applied to restrict the
3 probabilistic masks to cortex (75% for the parahippocampal gyri, 50% for hippocampi) and any gaps
4 resulting from thresholding manually filled. The resulting bilateral ROI was applied to each subject's fMRI
5 data and used as a mask before conducting voxel-wise statistics within this ROI.
6
7
8
9

10
11 *fMRI Data Analysis: Model-free analysis*

12 To probe group-level differences in functional connectivity during memory-task performance, we used
13 novel model-free Tensor Independent Component Analysis (TICA) (Beckmann et al., 2005). TICA
14 analyses the temporal correlation of BOLD signals across all voxels in the brain and all subjects to identify
15 "independent components", each consisting of a spatial map, a time course and a subject-mode vector
16 (encoding the relative contribution of each subject to the spatio-temporal effect). Spatial maps were
17 thresholded using a Gaussian/Gamma mixture model (Beckmann et al., 2005) fitted to the histogram of
18 intensity values and employing an alternative hypothesis testing approach at $p > 0.5$. Task-related
19 components were identified using post-hoc regression analysis of each component's time course against the
20 GLM design. Similarly, significant changes between groups were assessed by testing the subject-specific
21 effect sizes using a GLM.
22
23
24
25
26
27
28
29
30

31 *Medial temporal lobe Laterality Index (LI) and regional percent signal change calculation*

32 Voxel-based laterality indices (LIs) were calculated based on the ROI analysis. The MTL ROI, mapped
33 onto each subject's fMRI image, was divided into left and right hemisphere components. A LI was
34 obtained by calculating $(L-R)/(L+R)$, where L is the number of activated voxels at a given statistical
35 threshold in the left hemisphere mask, and R is the number of activated voxels at the same threshold in the
36 right hemisphere mask. Voxel-count based LIs are inherently limited by the arbitrary selection of statistical
37 thresholds at which to obtain voxel counts. Only 3 patients showed ROI activation above a z-statistical
38 threshold of 3.3, therefore LIs were calculated only at the z-statistical threshold of 2.3. Additionally we
39 quantified mean and maximum regional BOLD percent signal change within the same ROIs using
40 Featquery.
41
42
43
44
45
46
47
48
49
50
51

Deleted: 1

Deleted: 27

Voets, N.L., et al.

Diffusion Tensor Image Analysis

After pre-processing (motion and eddy current correction, averaging of same-direction diffusion acquisitions), principal eigenvector and fractional anisotropy (FA) maps were generated using FMRIB's Diffusion Tool (FDT). To track the fornix in individual patients, the single voxel with the highest FA value within the fornix was identified on individual data sets as previously described by Ringman et al., (2007). Pathways from this voxel were tracked in each patient using probabilistic tractography (ProbtrackX within FDT)(Behrens et al., 2007)(www.fmrib.ox.ac.uk/fsl/fdt/). The resulting pathways were thresholded at 90% to ensure tracts were confined to the fornix. Mean and maximum FA values were extracted from each patient's thresholded fornix tract applied to their FA map. To track the uncinate fasciculus, the location of this fibre bundle was visually identified in each patient on sagittal brain slices by overlaying the principal diffusion direction vector map onto each subject's FA map. The uncinate typically spanned 3-4 sagittal slices at the level of the temporal stem. On the central-most slice, a 3x3 voxel seed mask was drawn, spanning the posterior curve of the pathway in the left hemisphere. A target mask was placed in anterior prefrontal white matter on the standard MNI 152 template, and an exclusion mask placed directly behind this to prevent paths from continuing into grey matter (introducing high variability into FA samples). For uncinate analyses, tracts via fimbria-fornix routes, and false-positive tracts traversing the sylvian fissure were prevented using exclusion masks placed on one coronal slice of the standard MNI template brain at the posterior level of the anterior hippocampus (y=51, or -24mm), and along the sylvian fissure. Tracts were thresholded at a fifth of resulting paths before mean and maximum FA values were extracted from each individual's left uncinate tract applied to their FA map.

Statistical Analyses

Statistical analyses were conducted using SPSS (v13.0). One-tailed Pearson's correlations were used to test the relationship between signal change measures and FA within the patient group as these were predicted to decrease in parallel. Two-tailed Pearson's correlations were used to test relationships with neuropsychological scores.

RESULTS

Deleted: 1

Deleted: 27

Voets, N.L., et al.

Standard fMRI GLM analyses

Group FEAT analysis revealed bilateral MTL activation in both LTLE patients and healthy controls during complex scene encoding. No significant differences in activation (e.g. in the right hemisphere) were found in patients relative to controls using standard GLM analysis (Figure 1).

ROI analysis yielded significant voxel-wise activation in all controls and all but one of the patients. Voxel-count LIs did not reveal any significant difference between LTLE patients (mean: -0.1, +/-0.7) and healthy controls (mean: -0.1, +/- 0.4) ($p=0.862$), (Figure 3A). Additionally, neither mean, nor maximum percent signal change measures differed in either the left or the right MTL ROIs in patients compared with controls (Figure 3B).

TICA results

Tensor ICA analysis performed on the same fMRI memory-task data identified one (out of 54) component which showed (i) significant correlation with the task and (ii) significant difference in the relative activation strength between patients and controls. The subject-mode vector revealed a significant decrease in functional connectivity between the bilateral MTLs and a region encompassing the left gyrus rectus, medial and posterior orbital gyri in LTLE patients (Figure 2). This network was additionally associated with decreased functional connectivity to occipital regions encompassing bilateral lateral occipital cortex, the temporo-occipital part of inferior temporal gyrus, occipital pole and a small cluster in left lingual gyrus, as well as small regions in the paracingulate gyrus, precentral gyrus, superior parietal gyrus, and thalami.

Relation of structural and functional memory measures

The region showing reduced functional connectivity with the MTLs in TLE patients appeared to localize to an orbitofrontal region containing limbic afferents (Barbas & De Olmos 1990; Porrino et al., 1981; Ongur & Price 2000), via the fornix (Poletti & Creswell 1977; Votaw & Lauer 1963). Unthresholded tractography results in a single-subject are presented in Supplementary Figure 1 for illustrative purposes only. To test for a relationship between fornix white matter coherence and memory-related differences in functional connectivity, a mask was created based on activated voxels in the TICA-derived group difference map.

Deleted: 1

Deleted: 27

Voets, N.L., et al.

After applying temporal low-pass filtering to each subjects' data in order to remove high-frequency noise from the BOLD recordings, mean (average 0.1 +/-0.4) and maximum (0.2 +/-0.4) percent signal change were extracted from the orbitofrontal mask. Maximum FA along the fornix (average 0.72 +/- 0.17) correlated significantly with both mean percent signal change from the orbitofrontal mask ($r=0.593$, $p=0.046$) and maximum percent signal change in this region ($r=0.607$, $p=0.041$) in the LTLE patients. No relationship was found between uncinate mean (average 0.38+/- 0.06) or maximum (average 0.83+/-0.18) FA and BOLD signal change from the orbitofrontal mask.

Correlating our MRI measures with clinical neuropsychological measures, one patient emerged as a clear outlier (see boxplot Figure 5). Excluding this patient, both maximum and mean BOLD signal change correlated strongly with clinical neuropsychological measures of story immediate ($r=0.88$, $p<0.009$, $p=0.84$, $p<0.02$ for max and mean, respectively) and delayed ($r=0.91$, $p<0.004$ and $r=0.81$, $p<0.03$ for max and mean, respectively) recall (Figure 5). No significant correlations were found between our diffusion-based measures and neuropsychological scores with our sample size.

DISCUSSION

Using novel analysis methods, we aimed to clarify the extent of memory-related functional changes associated with left temporal lobe epilepsy at the systems-level, and compare these to standard measures of hemispheric reorganization, measures of fibre pathway coherence and behavioural measures of memory function. To our knowledge, our preliminary study offers the first direct comparison of analyses aimed at demonstrating functional reorganization in TLE. Our results suggest that (i) LTLE is associated with network-level changes, including connectivity with the unilesional frontal lobe and bilateral occipital regions, rather than inter-hemispheric re-distribution, during scene memory encoding and (ii) medial-frontal functional changes correlate with white matter coherence in the fornix.

Much interest has focused on understanding the relationship between hippocampal pathology and memory functions to help predict patients at risk of cognitive decline following surgery. It has been advanced that in the presence of chronic seizures affecting one of the MTLs, the contralateral MTL may adopt a

Deleted: 1

Deleted: 27

Voets, N.L., et al.

1
2 compensatory role. Several recent functional imaging studies employing laterality index analysis methods
3
4 have lent support to this notion. However, microscopic pathophysiological changes (Mathern et al., 1996)
5
6 altering local connectivity may limit the potential for complete inter-hemispheric reorganization. Several
7
8 studies using direct electrical stimulation of the hippocampus have demonstrated preserved material-
9
10 specific deficits in TLE patients as a group (Lee et al., 1990, Coleshill et al., 2004), contra-indicating
11
12 absolute hemispheric functional reorganization. Additionally, the extent of ipsilesional fMRI activation
13
14 during a variety of memory tasks has been convincingly shown to predict post-surgical memory decline
15
16 (Richardson et al., 2004, 2006; Powell et al., 2007, 2008; Rabin et al., 2004), casting doubt over the clinical
17
18 significance of compensatory activity.

19
20 Consistent with these observations we found no evidence for significantly altered MTL activation relative
21
22 to healthy volunteers during a complex scene encoding task either at the whole-brain level, or within a
23
24 restricted ROI. Only qualitative decreases were observed in the magnitude of activation in the LTLE
25
26 patient group as compared with healthy controls. While the biological significance of differences in BOLD
27
28 signal amplitude remains unknown, a recent study (Petrella et al., 2007) suggests intrinsic differences in
29
30 regional BOLD signal during task performance may be of prognostic value in disease populations. Testing
31
32 systems-level changes using novel model-free multivariate TICA, however, identified decreased functional
33
34 connectivity between the bilateral MTLs and a region in the left orbitofrontal gyrus (among others) in
35
36 LTLE patients. As ICA methods are more robust against disease-related changes in the haemodynamic
37
38 response function (which may result in decreased sensitivity when using GLM methods), we propose that
39
40 our finding supports subtle alterations in the contribution of distinct but inter-connected regions of the pre-
41
42 existing memory network rather than inter-hemispheric shifts in the distribution of memory functions
43
44 between the MTLs. Altered recruitment of extra-temporal regions, particularly within frontal lobes, has
45
46 been previously found using memory tasks employing verbal stimuli (Dupont et al., 2000, Macotta et al.
47
48 2007) and suggest dynamic changes in temporo-frontal interactions during memory performance in TLE.
49
50 Using an autobiographical retrieval task, these interactions were recently directly probed using effective
51
52 connectivity analysis within *a priori* selected hippocampal and medial prefrontal regions (among others)
53
54 (Addis et al., 2007). The authors confirmed a weakening in the strength of functional connections during
55
56
57
58
59
60

Deleted: 1

Deleted: 27

Voets, N.L., et al.

1
2 autobiographical retrieval in LTLE between these regions. Our results extend these findings to the
3
4 encoding network, and additionally provide a sensitive unbiased method to test for systems-level changes
5
6 in a wide range of tasks without the need to limit the search to functional-anatomical regions defined on
7
8 previous task-derived data.
9

10
11 Voxel-Based Morphometry (VBM) studies in unilateral TLE patients have identified grey matter volume
12
13 reductions in the thalamus and prefrontal cortex (Bonilha et al., 2004; Keller et al., 2002, Riederer et al.,
14
15 2008) and are supported by observations of ipsilesional frontal lobe metabolic abnormalities (Henry et al.,
16
17 1993; Savic et al., 1997). These changes have been attributed to consequences of deafferentation,
18
19 particularly axonal damage to temporal lobe white matter efferent tracts (Cendes et al., 1994) possibly
20
21 secondary to hippocampal cell loss (Joo et al., 2005). Consistent with this, white matter changes affecting
22
23 the uncinate (Rodrigo et al., 2007) and fornix (Baldwin et al., 1994) have been found. Such structural and
24
25 metabolic changes may directly explain variations in behavioural performance, for example through
26
27 Wallerian degeneration (e.g. Sawlani et al., 1997). Indeed, DTI FA measures in the left temporal lobe have
28
29 been related to fluency task laterality (Briellmann et al., 2003). These findings suggest changes in memory
30
31 performance and the distribution of associated neural correlates may be explained by injury more broadly
32
33 affecting the network underlying memory functions.

34
35 Our results demonstrate a direct relationship between orbitofrontal signal change during memory task
36
37 performance and coherence of one of the primary hippocampal efferent pathways, the fornix, in the same
38
39 population of LTLE patients. The predominance of temporo-frontal interactions are mediated by the
40
41 uncinate and fornix white matter fibre bundles. Experimental lesion data suggest the uncinate may subserve
42
43 particularly verbal memory functions such as word list learning (Niogi et al., 2008) rather than visual
44
45 associative learning or recognition memory (Gaffan & Eacott 1995, Eacott & Gaffan, 1992), which instead
46
47 may be supported by the fornix (e.g. Aggleton et al., 2000) through hippocampo-frontal interactions (Ridley
48
49 et al., 1996, Gaffan et al., 2002). Consistent with these models, we found a relationship between altered
50
51 functional connectivity and fornix, but not uncinate fibre coherence using a scene-encoding task. As the
52
53 stimuli in our task were selected so as not to preferentially engage verbal encoding processes, we interpret

Deleted: 1

Deleted: 27

Voets, N.L., et al.

1
2 the lack of significant association between uncinate coherence and our fMRI findings as support for the
3
4 notion that the uncinate may be more specifically engaged during semantic processing. Indeed, two recent
5
6 studies identified a significant correlation between diffusion parameters along the uncinate (Diehl et al.,
7
8 2008) or parahippocampal gyrus tract (Yogarajah et al., 2008, which extends into the inferior frontal lobe
9
10 via the uncinate (Powell et al., 2004)) and neuropsychological test performance in LTLE relative to controls.
11
12 These findings are not in conflict with our results, as in these studies, left uncinate diffusion measures
13
14 (reduced in LTLE relative to controls) related to auditory immediate and delayed verbal memory while FA
15
16 along the left parahippocampal gyrus (visually decreased in LTLE relative to the contralesional side) was
17
18 associated with verbal learning.

19
20 These results suggest that white matter changes, potentially secondary to neurodegeneration of MTL
21
22 structures, contribute significantly to functional pathology in TLE, and highlight a central role for the fornix
23
24 in memory functions. This is consistent with a recent study of memory deficits arising from colloidal cyst
25
26 resections emphasizing the crucial role of hippocampal projections via the fornix in sustaining long-term
27
28 memory functions, most notably for recall (Tsvivilis et al., 2008), a measure which correlated with
29
30 orbitofrontal signal change in our small population (Figure 5). Interestingly, a recent VBM observation of
31
32 reduced grey matter density in the left orbitofrontal gyrus of LTLE patients with hippocampal sclerosis
33
34 (Riederer et al 2008) appears to co-localise with our observed orbitofrontal functional connectivity
35
36 differences. These authors additionally noted grey matter changes in thalamus, superior temporal gyrus,
37
38 parahippocampal gyrus, right middle cingulum, and cerebellum, lending support to the notion that chronic
39
40 seizures affect widespread interconnected regions connected to the hippocampus. Better characterisation of
41
42 changes in functional and structural connectivity will improve our understanding of pre-operative memory
43
44 deficits in TLE, and factors impacting on cognitive surgical outcome. Further research will need to be
45
46 conducted to determine the relationship of these imaging markers to neuropsychological measures of
47
48 memory impairment in this patient population.

49
50 An interesting additional result to emerge from our study was a decrease in functional connectivity in LTLE
51
52 patients relative to controls between occipital regions and the MT-IFG network involved in novel scene

Deleted: 1

Deleted: 27

Voets, N.L., et al.

1
2 encoding. Visual processing has not been extensively studied in TLE with regard to neural correlates,
3
4 however both Focke et al., (2008) and Yogarajah et al., (2008) identified differences in diffusion-based
5
6 measures in occipital or occipito-temporal regions. Evidence for such structural changes may lend support
7
8 to the notion advanced by Vannucci et al., (2008) that despite normal visual performance, TLE patients may
9
10 sub-optimally encode visual aspects of novel stimuli. Our results are consistent with this proposal and
11
12 suggest decreased temporo-occipital interaction during processing of novel scenes may underlie this
13
14 encoding difference.

15
16 A few limitations warrant description. This is a preliminary study and the sample size is small. The linear
17
18 spread of signal change and FA values suggest our results were not driven by a subgroup of the patients
19
20 included in this trial, but will need replication in a larger group of participants. Additionally, our (absence
21
22 of) laterality results are consistent with a previous larger study in 35 TLE patients (Rabin et al., 2004).
23
24 Signal loss and distortion near sinus tissue-air boundaries affects sensitivity to BOLD activation in the
25
26 MTL. Our observations of robust activations localized to the MTLs in both populations suggest this was
27
28 not the primary cause for our lack of detection of hemispheric reorganization. Thirdly, we employed a
29
30 single task designed to recruit bilateral structures for enhanced sensitivity to functional shifts and suitable
31
32 for both LTLE and RTLE patients. For individual LTLE patients where verbal memory loss is of particular
33
34 concern, additional domain-specific tasks may be valuable. Lastly, one patient presented with cortical
35
36 dysplasia rather than hippocampal sclerosis, which could have presented a confound in our analysis. TICA,
37
38 however, intrinsically manages outlier confounds affecting a) spatial extent or b) signal amplitudes within a
39
40 given map. If this patient had a different functional connectivity pattern as compared with the rest of the
41
42 TLE group, TICA would have automatically extracted this into a separate component. If the patient had
43
44 been an outlier in terms of BOLD signal amplitude within a unified map, this would have been reflected in
45
46 the subject-mode boxplot (Figure 2). As all individual patient values fell within 2 standard deviations of
47
48 the rest of the patient group, our results appeared consistent across this pathophysiological difference. Our
49
50 sample size was too small to adequately investigate the potential contributions of age-at onset of seizures
51
52 and durations of epilepsy (years) to functional plasticity, and warrants further investigation.

Deleted: 1

Deleted: 27

Voets, N.L., et al.

In conclusion, our results demonstrate a loss of functional connectivity between distinct anatomical regions involved in memory processing in patients with left TLE. These changes were not observed using commonly employed General Linear Model analysis and emphasise the value of a network-based analysis to understanding memory (and possibly other) deficits in TLE. Signal change during task performance in the orbitofrontal region of LTLE patients was significantly related to coherence along the primary hippocampal efferent pathway, the fornix. These findings may have important implications for understanding disease-related adaptive functional plasticity in TLE and has potentially important implications for predicting cognitive outcome following pre-surgical planning in TLE patients.

For Peer Review

1
2
3
4
5
6
7
8
9
10
11
12
13
14
15
16
17
18
19
20
21
22
23
24
25
26
27
28
29
30
31
32
33
34
35
36
37
38
39
40
41
42
43
44
45
46
47
48
49
50
51
52
53
54
55
56
57
58
59
60

Deleted: 1
Deleted: 27

Voets, N.L., et al.

Acknowledgements

We acknowledge the Medical Research Council (MRC) and a private donation to the Cairns Fund for personal support to NLV and PMM. JEA received support from the Epilepsy Research Foundation (UK). Research conducted at FMRIB was supported by the MRC. We gratefully acknowledge Laura Stamper and colleagues at FMRIB, particularly Heidi Johansen-Berg, Tim Behrens and Steve Smith, the participants and Peter Hobden, the senior radiographer. PMM is a full-time employee of GlaxoSmithKline.

For Peer Review

1
2
3
4
5
6
7
8
9
10
11
12
13
14
15
16
17
18
19
20
21
22
23
24
25
26
27
28
29
30
31
32
33
34
35
36
37
38
39
40
41
42
43
44
45
46
47
48
49
50
51
52
53
54
55
56
57
58
59
60

Deleted: 1
Deleted: 27

Page 16 of 27

Voets, N.L., et al.

1
2
3
4
5
6
7
8
9
10
11
12
13
14
15
16
17
18
19
20
21
22
23
24
25
26
27
28
29
30
31
32
33
34
35
36
37
38
39
40
41
42
43
44
45
46
47
48
49
50
51
52
53
54
55
56
57
58
59
60

REFERENCES

Aggleton JP, McMackin D, Carpenter K, Hornak J, Kapur N, Halpin S, Wiles CM, Kamel H, Brennan P, Carton S, Gaffan D (2000). Differential cognitive effects of colloidal cysts in the third ventricle that spare or compromise the fornix. **Brain 234(Pt 4): 800-15**

Baldwin GN, Tsuruda JS, Maravilla KR, Hamill GS, Hayes CE (1994). The fornix in patients with seizures caused by unilateral hippocampal sclerosis: detection of unilateral volume loss on MR images. *Am J Roentgenol* 162(5):1185-1189.

Barbas H & De Olmos J (1990). Projections from the amygdala to basoventral and mediodorsal prefrontal regions in the rhesus monkey. *J Comp Neurol* 300: 549-571

Beckmann CF & Smith SM (2005). Tensorial extension of independent component analysis for multisubject fMRI analysis. *NeuroImage* 25(1): 294-311

Behrens TE, Johansen-Berg H, Jbabdi S, Rushworth MF, Woolrich MW (2007) Probabilistic diffusion tractography with multiple fibre orientations: What can we gain? *NeuroImage* 34(1) :144-55

Blümcke I, Thom M, Wiestler OD (2002). Ammon's horn sclerosis: a maldevelopmental disorder associated with temporal lobe epilepsy. *Brain Pathol* 12(2): 199-211

Bonilha L, Rorden C, Castellano G, Pereira F, Rio PA, Cendes F, Li LM (2004). Voxel-based morphometry reveals gray matter network atrophy in refractory medial temporal lobe epilepsy. *Arch Neurol* 61(9):1379-1384.

Briellmann RS, Mitchell LA, Waites AB, Abbott DF, Pell GS, Saling MM, Jackson GD (2003) Correlation between language organization and diffusion tensor abnormalities in refractory partial epilepsy. *Epilepsia* 44(12):1541-1545.

Deleted: 1

Deleted: 27

Voets, N.L., et al.

1
2
3
4 Cendes F, Andermann F, Preul MC, Arnold DL (1994) Lateralization of temporal lobe epilepsy based on
5 regional metabolic abnormalities in proton magnetic resonance spectroscopic images. *Ann neurol* 35(2):
6 211-6
7
8

9
10
11 Cheung MC, Chan AS, Chan YL, Lam JM, Lam W (2006). Effects of illness duration on memory
12 processing of patients with temporal lobe epilepsy. *Epilepsia* 47(8): 1320-8
13

14
15
16 Chlebus P, Mikl M, Brazdil M, Pazourkove M, Krupa P, Rektor I (2007). fMRI evaluation of hemispheric
17 language dominance using various methods of laterality index calculation. *Exp Brain res* 179(3): 365-74
18

19
20
21 Coleshill SG, Binnie CD, Morris RG, Alarcon G, van Emde Boas W, Velis DN, Simmons A, Polkey CE,
22 van Veelen CW, van Rijen PC (2004). Material-specific recognition memory deficits elicited by unilateral
23 hippocampal electrical stimulation. *J Neurosci* 24(7): 1612-6.
24

25
26
27 Concha L, Beaulieu C & Gross DW (2005). Bilateral limbic diffusion abnormalities in unilateral temporal
28 lobe epilepsy. *Ann Neurol* 57(2): 188-96
29

30
31
32 Deblaere K, Backes WH, Tieleman A, Vandemaele P, Defreyne L, Vonck K, Hofman P, Boon P,
33 Vermeulen J, Wilmink J, Aldenkamp A, Boon PA, Vingerhoets G, Achten E (2005). Lateralized anterior
34 mesiotemporal lobe activation: semirandom functional MR imaging encoding paradigm in patients with
35 temporal lobe epilepsy--initial experience. *Radiology* 236(3): 996-1003
36
37
38

39
40
41 Detre JA, Maccotta L, King D, Alsop DC, Glosser G, D'Esposito M, Zarahn E, Aguirre GK, French JA
42 (1998). Functional MRI lateralization of memory in temporal lobe epilepsy. *Neurology* 50: 926-932
43
44
45
46
47

48 Deleted: 1

49 Deleted: 27

Voets, N.L., et al.

1
2 Diehl B, Busch RM, Duncan JS, Piao Z, Tkach J, Luders HA (2008). Abnormalities in diffusion tensor
3
4 imaging of the uncinate fasciculus relate to reduced memory in temporal lobe epilepsy. *Epilepsia*
5
6 49(8):1409-1418
7

8
9 Dudek FE & Sutula TP (2007). Epileptogenesis in the dentate gyrus: a critical perspective. *Prog Brain Res*
10
11 163: 755-773.
12

13
14 Focke NK, Yogarajah M, Bonelli SB, Bartlett PA, Symms MR, Duncan JS (2008). Voxel-based diffusion
15
16 tensor imaging in patients with mesial temporal lobe epilepsy and hippocampal sclerosis. *NeuroImage*
17
18 40(2):728-37
19

20
21 Gaffan D, Parker A, Easton A (2001). Dense amnesia in the monkey after transection of fornix, amygdala
22
23 and anterior temporal stem. *Neuropsychologia* 39: 51-70
24

25
26 Golby AJ, Poldrack RA, Illes J, Chen D, Desmond JE, Gabrieli JDE (2002). Memory lateralization in
27
28 medial temporal lobe epilepsy assessed by functional MRI. *Epilepsia* 43(8): 855-863.
29

30
31 Hamberger MJ, Seidel WT, Goodman RR, Williams A, Perrine K, Devinsky O, McKhann GM (2007).
32
33 Evidence for cortical reorganization of language in patients with hippocampal sclerosis. *Brain* 130(11):
34
35 2942-2950
36

37
38 Henry TR, Engel J Jr, Mazziotta JC (1993) Clinical evaluation of interictal fluorine-18-fluorodeoxyglucose
39
40 PET in partial epilepsy. *J Nucl Med* 34(11): 1892-8
41

42
43 Hermann BP, Seidenberg M, Haltiner A, Wyler AR (1992). Adequacy of language function and verbal
44
45 memory performance in unilateral temporal lobe epilepsy. *Cortex* 28(3): 423-33
46

47
48 Deleted: 1

49 Deleted: 27

Voets, N.L., et al.

1
2 Jansen A, Menke R, Sommer J, Forster AF, Bruchmann S, Hempleman J, Weber B, Knecht S (2006). The
3 assessment of hemispheric lateralization in functional MRI-robustness and reproducibility. *Neuroimage*
4 33(1): 204-17.
5
6

7
8
9 Jenkinson M, Bannister P, Brady M, Smith S (2002). Improved optimization for the robust and accurate
10 linear registration and motion correction of brain images. *Neuroimage* 17(2): 825-41
11

12
13
14 Joo EY, Hong SB, Han HJ, Tae WS, Kim JH, Han SJ, Seo DW, Lee KH, Hong SC, Lee M, Kim S, Kim
15 BT (2005). Postoperative alteration of cerebral glucose metabolism in mesial temporal lobe epilepsy. *Brain*
16 128:1802-10.
17

18
19
20 Keller SS, Mackay CE, Barrick TR, Wieshmann EC, Howard MA, Roberts N (2002). Voxel-based
21 morphometric comparison of hippocampal and extrahippocampal abnormalities in patients with left and
22 right hippocampal atrophy. *Neuroimage* 16(1): 23-31
23

24
25
26 Lee GP, Loring DW, Smith JR, Flanigin HF (1990). Material specific learning during electrical stimulation
27 of the human hippocampus. *Cortex* 26(3): 433-42.
28

29
30
31 Mathern GW, Babb TL, Leite JP, Pretorius K, Yeoman KM, Kuhlman PA (1996). The pathogenic and
32 progressive features of chronic human hippocampal epilepsy. *Epilepsy Res* 26(1): 151-61.
33

34
35
36 Meiners LC, Witkamp TD, de Kort GA, van Huffelen AC, van der Graaf Y, Jansen GH, van der Grond J,
37 van Veelen CW (1999). Relevance of temporal lobe white matter changes in hippocampal sclerosis.
38
39 Magnetic resonance imaging and histology. *Invest Radio* 34(1): 38-45
40
41

42
43
44 Meiners LC, van der Grond J, van Rijen PC, Springorum R, de Kort GA, Jansen GH (2000). Proton
45 magnetic resonance spectroscopy of temporal lobe white matter in patients with histologically proven
46 hippocampal sclerosis. *J Magn Reson Imaging* 11(1):25-3
47
48

Deleted: 1

Deleted: 27

Voets, N.L., et al.

1
2
3
4 Niogi SN, Mukherjee P, Ghajar J, Johnson CE, Kolster R, Lee H, Suh M, Zimmerman RD, Manley GT,
5 McCandliss BD (2008). Structural dissociation of attentional control and memory in adults with and without
6 mild traumatic brain injury. *Brain* 131:3209-3221
7
8
9

10
11 Nunes RG, Jezzard P & Clare S (2005). Investigations on the efficiency of cardiac-gated methods for the
12 acquisition of diffusion-weighted images. *J Magn Reson* 177(1): 102-10
13
14

15
16 Ongur D & Price JL (2000). The Organization of Networks within the Orbital and Medial Prefrontal
17 Cortex of Rats, Monkeys and Humans. *Cereb Cortex* 10: 206-219.
18
19

20
21 Pierpaoli C, Barnett A, Pajevic S, Chen R, Penix LR, Virta A, Basser P (2001) Water diffusion changes in
22 Wallerian degeneration and their dependence on white matter architecture. *NeuroImage* 13: 1174-85
23
24

25
26 Petrella JR, Prince SE, Wang L, Hellegers C, Doraiswamy PM (2007). Prognostic value of posteromedial
27 cortex deactivation in mild cognitive impairment. *PLoS ONE* 2(10):e1104
28
29

30
31 Poletti CE, Creswell G (1977). Fornix system efferent projections in the squirrel monkey: an experimental
32 degeneration study. *J Comp Neurol* 175(1):101-28
33
34

35
36 Porrino LJ, Crane AM, Goldman-Rakic PS (1981). Direct and Indirect Pathways from the Amygdala to the
37 Frontal Lobe in Rhesus Monkeys. *J Comp Neurol* 198: 121-136.
38
39

40
41 Powell HWR, Guye M, Parker GJM, Symms MR, Boulby P, Koepp MJ, Barker GJ, Duncan JS (2004).
42 Noninvasive in vivo demonstration of the connections of the human parahippocampal gyrus. *NeuroImage*
43 22: 740-747
44
45
46
47

48 Deleted: 1

49 Deleted: 27

Voets, N.L., et al.

Powell HW, Richardson MP, Symms MR, Boulby PA, Thompson PJ, Duncan JS, Koepp MJ (2007a).
Preoperative fMRI predicts memory decline following anterior temporal lobe resection. *J Neurol Neurosurg Psychiatry* 79(6): 686-93.

Powell HWR, Richardson MP, Symms MR, Boulby PA, Thompson PJ, Duncan JS, Koepp MJ (2007b).
Reorganisation of verbal and nonverbal memory in temporal lobe epilepsy due to unilateral hippocampal sclerosis. *Epilepsia* 48(8): 1512-1525.

Rabin ML, Narayan VM, Kimberg DY, Glosser G, Tracy JI, French JA, Sperling MR, Detre JA (2004).
Functional MRI predicts post-surgical memory following temporal lobectomy. *Brain* 127:2286-98

Rao MS, Hattiangady B, Reddy DS, Shetty AK (2006). Hippocampal Neurodegeneration, Spontaneous Seizures, and Mossy Fiber Sprouting in the F344 Rat Model of Temporal Lobe Epilepsy. *J Neurosci Res* 83: 1088-1105.

Reese TG, Heid O, Weisskoff RM, Wedeen VJ (2003). Reduction of eddy-current-induced distortion in diffusion MRI using a twice-refocused spin echo. *Magn Reson Med* 49(1): 177-82.

Richardson MP (2003). Epilepsy and surgical mapping. *Br Med Bull* 65: 179-192.

Ridley RM, Baker HF, Harder JA, Pearson C (1996). Effects of lesions of different parts of the septo-hippocampal system in primates on learning and retention of information acquired before or after surgery. *Brain Res Bull* 40(1): 21-32

Ringman JM, O'Neill J, Geschwind D, Apostolova LG, Rodriguez Y, Schaffer B, Varpetian A, Tseng B, Ortiz F, Fitten J, Cummings JL, Bartzokis G (2007). Diffusion tensor imaging in preclinical and presymptomatic carriers of familial Alzheimer's disease mutations. *Brain* 130:1767-76

Deleted: 1

Deleted: 27

Voets, N.L., et al.

Rodrigo S, Oppenheim C, Chasoux F, Golestani N, Cointepas Y, Poupon C, Semah F, Mangin J-F, Le Bihan D, Meder J-F (2007). Uncinate fasciculus fibre tracking in mesial temporal lobe epilepsy. Initial findings. *Eur Radiol* 17: 1663-1668.

Rombouts SA, Barkhof F, Witter MP, Machielsen WC, Scheltens P (2001). Anterior medial temporal lobe activation during attempted retrieval of encoded visuospatial scenes: an event-related fMRI study. *Neuroimage* 14:67-76

Rombouts SA, Damoiseaux JS, Goekoop R, Barkhof F, Scheltens P, Smith SM, Beckmann CF (2009). *Hum Brain Map* 30(1): 256-66.

Saunders RC, Aggleton JP (2007). Origin and topography of fibres contributing to the fornix in macaque monkeys. *Hippocampus* 17:399-411

Savic I, Altshuler L, Baxter L, Engel J Jr (1997). Pattern of interictal hypometabolism in PET scans with fludeoxyglucose F 18 reflects prior seizure types in patients with mesial temporal lobe seizures. *Arch Neurol* 54(2): 129-36

Sawhani V, Gupta RK, Singh MK, Kohli A (1997) MRI demonstration of Wallerian degeneration in various intracranial lesions and its clinical implications. *J Neurol Sci* 146(2):103-108.

Seghier ML (2008). Laterality index in functional MRI: methodological issues. *Magn Reson Imaging* 26(5): 594-601.

Siddiqui AH & Joseph SA (2005). CA3 axonal sprouting in kainate-induced chronic epilepsy. *Brain Res* 1066(1-2):129-46

Deleted: 1

Deleted: 27

Voets, N.L., et al.

1
2 Smith SM, Jenkinson M, Woolrich MW, Beckmann CF, Behrens TEJ, Johansen-Berg H, Bannister PR,
3
4 De Luca M, Drobnjak I, Flitney DE, Niazy R, Saunders J, Vickers J, Zhang Y, De Stefano N, Brady JM,
5
6 and Matthews PM (2004). Advances in functional and structural MR image analysis and implementation
7
8 as FSL. *NeuroImage* 23(S1): 208-219.

9
10
11 Stern CE, Corkin S, Gonzalez RG, Guimaraes AR, Baker JR, Jennings PJ, Carr CA, Sujiura RM,
12
13 Vedantham V, Rosen BR (1996). The hippocampal formation participates in novel picture encoding:
14
15 evidence from functional magnetic resonance imaging. *Proc Natl Acad Sci USA* 93(16): 8660-5.

16
17
18 Vannuci M, Pezer N, Helmstaedter C, Schaller K, Viggiano MP, Elger CE, Grunwald T (2008).
19
20 Hippocampal response to visual objects is related to visual memory functioning. *Neuroreport* 19(9):965-
21
22 968

23
24
25 Vannest J, Szaflarski JP, Privitera MD, Schefft BK, Holland SK (2008). Medial temporal fMRI activation
26
27 reflects memory lateralization and memory performance in patients with epilepsy. *Epilepsy Behav* 12(3): 410-
28
29 8

30
31 Votaw CL & Lauer EW (1963). An afferent hippocampal fiber system in the fornix of the monkey. *J Comp*
32
33 *Neurol* 121:195-206

34
35
36 Yogarajah M, Powell HWR, Parker GJM, Alexander DC, Thompson PJ, Symms MR, Boulby P, Wheeler-
37
38 Kingshott CA, Barker GJ, Koepp MJ, Duncan JS (2008). Tractography of the parahippocampal gyrus and
39
40 material specific memory impairment in unilateral temporal lobe epilepsy. *NeuroImage* 40: 1755-1764
41
42
43
44
45
46
47
48
49
50
51

Deleted: 1

Deleted: 27

Voets, N.L., et al.

Table 1: LTLE patient Demographics.

Patient	Sex	Age	Age at onset (years)	Early complicated prolonged convulsion	Duration (years)	Clinical MRI diagnosis	Verbal/non-verbal IQ
1	M	35	2	Yes	33	HS	66/84
2	F	18	7	Unknown	11	HS	74/87
3	F	28	11	No	17	HS	95/101
4	F	47	43	Yes	4	HS	86/94
5	F	41	12	Yes	29	HS	84/104
6	M	32	4	No	28	HS	74/93
7	F	38	34	No	4	HS	n/a
8	F	33	28	No	5	Dysplasia	105/119
9	M	38	11	No	27	HS	107/99

Table 1. Abbreviations: HS=Hippocampal sclerosis, n/a=not available

Voets, N.L., et al.

Figure Legends

Figure 1: Whole-brain group memory task-related activations in healthy volunteers and LTLE patients.

Legend: Group average maps during memory encoding in healthy controls (left) and LTLE patients (right).

No statistically significant between-group differences were found in the lateralization or localization of memory-task related activation (contrast maps not shown, as these were empty).

Figure 2: Functional connectivity differences between LTLE patients and healthy volunteers identified from memory-task derived TICA.

Legend: TICA group difference map (left) demonstrating significantly reduced functional connectivity

between the bilateral medial temporal lobes, an ipsilesional orbitofrontal region (green arrow), **occipital**

regions, and small clusters in the paracingulate gyrus, precentral gyrus, superior parietal gyrus, and thalami

in LTLE patients relative to healthy volunteers. A boxplot illustrating the separate patient and control group effect sizes and 1 standard deviation range is presented to the (right). All individual patient signal amplitudes fell within a range of two standard deviations from the mean of the patient group.

Figure 3: Memory Laterality Index and MTL BOLD percent signal change in LTLE patients and healthy controls.

Legend: Voxel-count laterality indices (A) did not reveal inter-hemispheric shifts in memory task-related

activation between LTLE patients and healthy controls. Regional mean and maximum fMRI signal change

measures (B) similarly failed to identify significant group differences.

Figure 4: Correlation between fornix coherence measures and orbitofrontal fMRI signal change during memory task performance.

Legend: Measures of white matter coherence along the fornix in LTLE patients correlated significantly

($p < 0.05$) with task-related mean (A) and maximum (B) BOLD percent signal change in an orbitofrontal

region showing altered functional connectivity with the medial temporal lobes in LTLE patients. OFG=

orbitofrontal gyrus.

Deleted: 1

Deleted: 27

Voets, N.L., et al.

1
2
3
4 **Figure 5: Orbitofrontal fMRI signal correlation with story recall.**

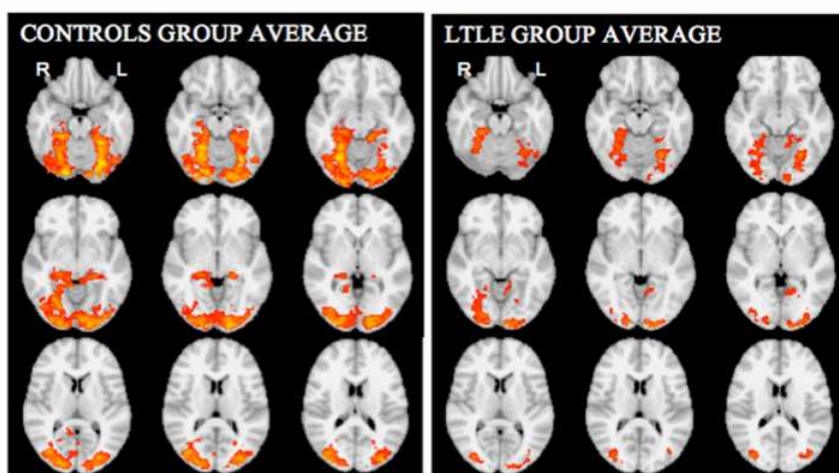
5 Legend: fMRI maximum signal change in the region of the orbitofrontal cortex showing altered functional
6 connectivity to the medial temporal lobes in LTLE patient during memory task performance correlated
7 significantly with clinical neuropsychological measures of story immediate (A) and delayed (B) recall
8 assessed using the Adult Memory and Information Processing Battery. Neuropsychological scores were
9 available for 8/9 patients reported.
10
11
12
13

14
15
16 **Supplementary Figure 1: Illustrative single-subject fornix and uncinate tractography results.**

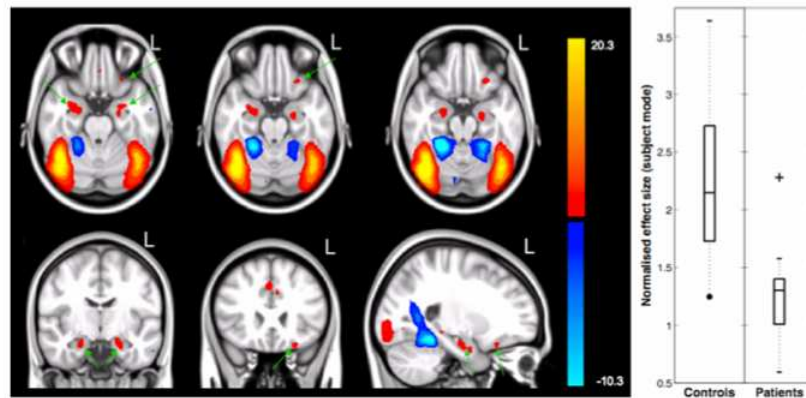
17 Legend: Single subject unthresholded fornix (light blue) and uncinate tracts (dark blue), rendered onto the
18 standard 1mm MNI template depicting the group memory-task TICA result (red-yellow). These single-
19 subject tracts are presented un-thresholded for illustrative purposes only. All manuscript results are derived
20 from thresholded pathways, which were restricted to white matter and thus did not extend into the cortical
21 regions as presented here.
22
23
24
25
26
27
28
29
30
31
32
33
34
35
36
37
38
39
40
41
42
43
44
45
46
47
48
49
50
51
52
53
54
55
56
57
58
59
60

Deleted: 1

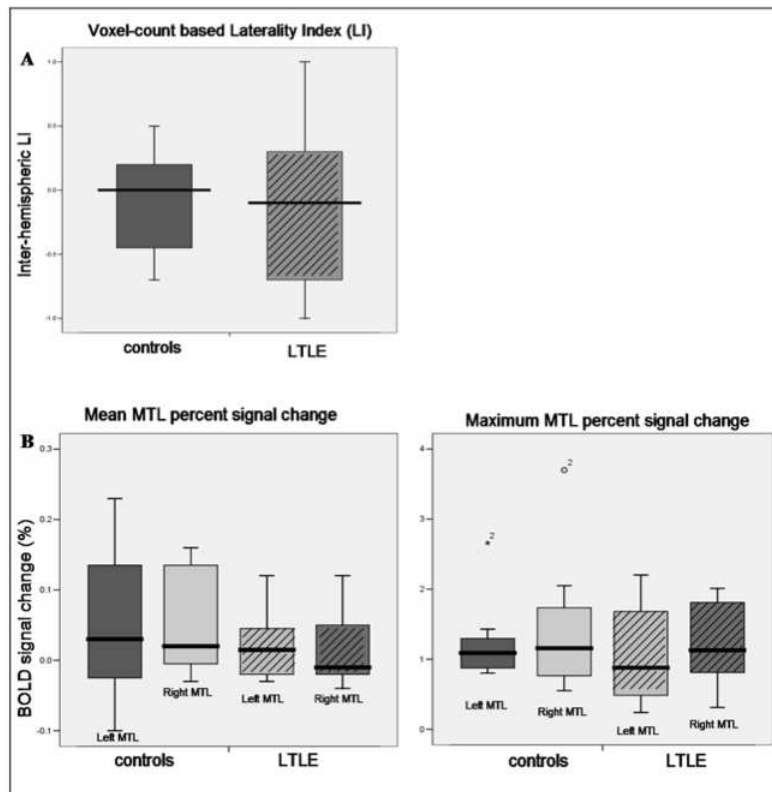
Deleted: 27



Group average maps during memory encoding in healthy controls (left) and LTLE patients (right). No statistically significant between-group differences were found in the lateralization or localization of memory-task related activation (contrast maps not shown, as these were empty).
264x352mm (72 x 72 DPI)



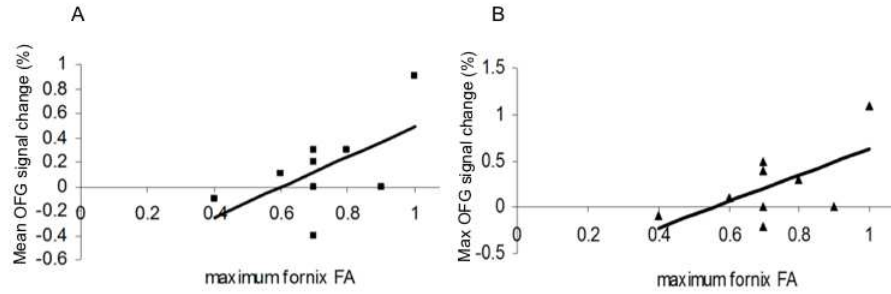
TICA group difference map (left) demonstrating significantly reduced functional connectivity between the bilateral medial temporal lobes and an ipsilesional orbitofrontal region (green arrow) in LTLE patients relative to healthy volunteers. A boxplot illustrating the separate patient and control group effect sizes and 1 standard deviation range is presented to the (right). All individual patient signal amplitudes fell within a range of two standard deviations from the mean of the patient group.
264x352mm (72 x 72 DPI)



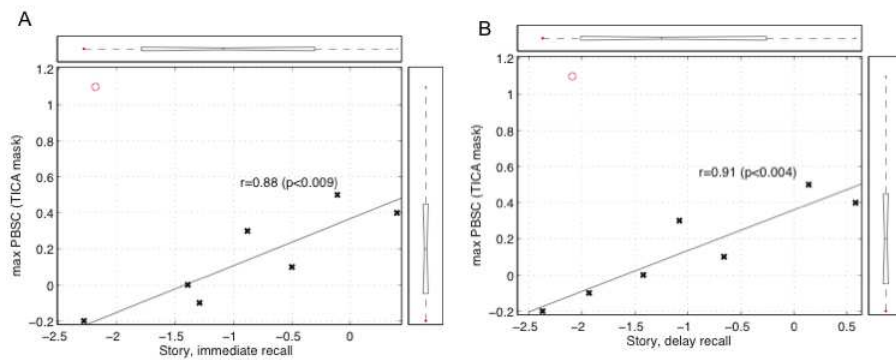
Voxel-count laterality indices (A) did not reveal inter-hemispheric shifts in memory task-related activation between LTLE patients and healthy controls. Regional mean and maximum fMRI signal change measures (B) similarly failed to identify significant group differences.

264x352mm (72 x 72 DPI)

1
2
3
4
5
6
7
8
9
10
11
12
13
14
15
16
17
18
19
20
21
22
23
24
25
26
27
28
29
30
31
32
33
34
35
36
37
38
39
40
41
42
43
44
45
46
47
48
49
50
51
52
53
54
55
56
57
58
59
60



Measures of white matter coherence along the fornix in LTLE patients correlated significantly ($p < 0.05$) with task-related mean (A) and maximum (B) BOLD percent signal change in an orbitofrontal region showing altered functional connectivity with the medial temporal lobes in LTLE patients. OFG= orbitofrontal gyrus.



fMRI maximum signal change in the region of the orbitofrontal cortex showing altered functional connectivity to the medial temporal lobes in LTLE patient during memory task performance correlated significantly with clinical neuropsychological measures of story immediate (A) and delayed (B) recall assessed using the Adult Memory and Information Processing Battery. Neuropsychological scores were available for 8/9 patients reported.