



HAL
open science

Adenovirus and mycoplasma infection in an ornate box turtle () in Hungary

Szilvia L. Farkas, János Gál

► **To cite this version:**

Szilvia L. Farkas, János Gál. Adenovirus and mycoplasma infection in an ornate box turtle () in Hungary. *Veterinary Microbiology*, 2009, 138 (1-2), pp.169. 10.1016/j.vetmic.2009.03.016 . hal-00490553

HAL Id: hal-00490553

<https://hal.science/hal-00490553v1>

Submitted on 9 Jun 2010

HAL is a multi-disciplinary open access archive for the deposit and dissemination of scientific research documents, whether they are published or not. The documents may come from teaching and research institutions in France or abroad, or from public or private research centers.

L'archive ouverte pluridisciplinaire **HAL**, est destinée au dépôt et à la diffusion de documents scientifiques de niveau recherche, publiés ou non, émanant des établissements d'enseignement et de recherche français ou étrangers, des laboratoires publics ou privés.

Accepted Manuscript

Title: Adenovirus and mycoplasma infection in an ornate box turtle (*Terrapene ornata ornata*) in Hungary

Authors: Szilvia L. Farkas, János Gál

PII: S0378-1135(09)00145-X
DOI: doi:10.1016/j.vetmic.2009.03.016
Reference: VETMIC 4386

To appear in: *VETMIC*

Received date: 6-10-2008
Revised date: 26-2-2009
Accepted date: 6-3-2009

Please cite this article as: Farkas, S.L., Gál, J., Adenovirus and mycoplasma infection in an ornate box turtle (*Terrapene ornata ornata*) in Hungary, *Veterinary Microbiology* (2008), doi:10.1016/j.vetmic.2009.03.016

This is a PDF file of an unedited manuscript that has been accepted for publication. As a service to our customers we are providing this early version of the manuscript. The manuscript will undergo copyediting, typesetting, and review of the resulting proof before it is published in its final form. Please note that during the production process errors may be discovered which could affect the content, and all legal disclaimers that apply to the journal pertain.



1 **Adenovirus and mycoplasma infection in an ornate box turtle (*Terrapene ornata ornata*)**
2 **in Hungary**

3

4 **Szilvia L. Farkas**^{1,*}, **János Gál**²

5

6 ¹ Veterinary Medical Research Institute, Hungarian Academy of Sciences, PO Box 18, 1581
7 Budapest, Hungary

8 ² Szent István University, Faculty of Veterinary Medicine, Department of Pathology and
9 Forensic Veterinary Medicine, PO Box 2, 1400 Budapest, Hungary

10

11 * Corresponding author. Tel.: +36 1 467 40 79; fax: +36 1 467 40 76. *E-mail address:*
12 *szilvia@vmri.hu*

13

14 **Abstract**

15 A female, adult ornate box turtle (*Terrapene ornata ornata*) with fatty liver was submitted for
16 virologic examination in Hungary. Signs of an adenovirus infection including degeneration of
17 the liver cells, enlarged nuclei and intranuclear inclusion bodies were detected by light
18 microscopic examination. The presence of an adenovirus was later confirmed by obtaining
19 partial sequence data from the adenoviral DNA-dependent DNA-polymerase. Phylogenetic
20 analyses revealed that this novel chelonian adenovirus was distinct from previously described
21 reptilian adenoviruses, not belonging to any of the recognized genera of the family
22 *Adenoviridae*. As a part of the routine diagnostic procedure for chelonians the detection of
23 herpes-, rana- and iridoviruses together with *Mycoplasma* spp. was attempted. Amplicons
24 were generated by a general mycoplasma polymerase chain reaction (PCR) targeting the
25 16S/23S ribosomal RNA (rRNA) intergenic spacer region, as well as, a specific *M. agassizii*

1 PCR targeting the 16S rRNA gene. Based on the analyses of partial sequences of the 16S
2 rRNA gene, the *Mycoplasma* sp. of the ornate box turtle seemed to be identical with the
3 recently described eastern box turtle (*Terrapene carolina carolina*) *Mycoplasma* sp. This is
4 the first report of a novel chelonian adenovirus and a mycoplasma infection in an ornate box
5 turtle (*Terrapene ornata ornata*) in Europe.

6
7 Keywords: Ornate box turtle; *Terrapene ornata ornata*; Adenovirus; *Mycoplasma*

8 9 **Introduction**

10 Adenoviruses (AdVs) are double stranded non-enveloped viruses with a diameter of 80-110
11 nm. They are present in a wide range of vertebrate species, including mammals, birds, reptiles,
12 amphibians and fish. They belong to the family *Adenoviridae* which presently contains four
13 accepted genera (*Mastadenovirus*, *Aviadenovirus*, *Atadenovirus*, *Siadenovirus*) and a fifth
14 proposed genus (*Ichtadenovirus*) containing the white sturgeon AdV 1, the only known fish
15 AdV so far (Benkő et al., 2005; Kovács et al., 2003).

16 Adenovirus-like viruses have already been detected in various reptilian hosts, including
17 snakes and lizards, as well as in Nile crocodiles (*Crocodilus niloticus*) (Fry et al., 1994;
18 Ramis et al., 2000; Kim et al., 2002; Wellehan and Johnson, 2005; Kübber-Heiss et al., 2006),
19 a leopard tortoise (*Geochelone pardalis*) (Wilkinson, 2004) and Sulawesi tortoise
20 (*Indotestudo forstenii*) (Rivera et al., 2008). Based on available sequence data, most of the
21 snake and lizard AdVs examined have been shown to belong to the genus *Atadenovirus*
22 (Wellehan et al., 2004, Farkas et al., 2008; Papp et al., 2009). From chelonians molecular data
23 is currently available only from the Sulawesi tortoise AdV (Rivera et al., 2008). Interestingly,
24 the recently detected Sulawesi tortoise AdV appears to be a member of the genus
25 *Siadenovirus* (Rivera et al., 2008).

1 Mycoplasmas can infect different reptile species, but they are most often detected from
2 chelonians. Some of them are members of the normal flora living in association with the host,
3 others may cause diseases leading even to the death of the animal (Brown et al., 2002). *M.*
4 *testudinis* is a non-pathogenic agent of the excretory tract in Greek tortoises (*Testudo graeca*),
5 *M. agassizii* (Brown et al., 1999) or *M. testudineum* (Brown et al., 2004) is causing the upper
6 respiratory tract disease in wild and captive tortoises in the USA and Europe. In the eastern
7 box turtles (*Terrapene carolina carolina*) the detected *Mycoplasma* sp. was associated with
8 clinical signs of upper respiratory tract disease-like syndrome (Feldman et al., 2006). Due to
9 its high incidence and clinical importance mycoplasma detection is a part of the routine
10 diagnostic procedures for chelonians in many laboratories.

11 This is the first description of a novel AdV and a box turtle *Mycoplasma* sp. infection in an
12 ornate box turtle (*Terrapene ornata ornata*) in Europe characterized by fatty liver
13 degeneration and inclusion body hepatitis.

14

15 **Material and methods**

16 Case history

17 On February 12, 2008 the carcass of a female ornate box turtle (*Terrapene ornata ornata*) was
18 delivered to Szent István University, Faculty of Veterinary Science, Department of Pathology
19 and Forensic Veterinary Medicine for postmortem evaluation. The turtle might have been
20 dead for several days before finding it. Prior to its death the turtle was hibernated at 6-12°C
21 beginning in November and monitored weekly. Before hibernation the turtle was fed daily
22 with insects (crickets: *Acheta domesticus*, *Gryllus bimaculatus*, *Gryllus assimilis*; *Zophobas*
23 *morio* larvae) purchased in a pet shop. Drinking water was constantly available in a shallow
24 dish.

25

1 Gross examination and microbiological investigations

2 A routine pathological dissection was carried out with macroscopic examination. Various
3 organs were examined and samples fixed in 4% buffered formalin for later histological
4 investigations. These tissues were then embedded in paraffin, cut in ultra-thin sections and
5 stained with hematoxylin-eosin. Bacterial culture was carried out from the liver of the turtle on
6 blood agar and Drigalski agar at 24°C for 48 hours. Samples of the liver, lung and intestines
7 were collected for virus isolation and polymerase chain reaction (PCR). Small pieces of the
8 organs were homogenized in Dulbecco's modified Eagle's medium (DMEM; Invitrogen,
9 Carlsbad, USA), diluted, passed through a 0.2 µm filter and used for inoculation of turtle
10 heart (ATCC CCL-50) cell monolayer supplemented with DMEM and 2% fetal bovine serum.
11 The cultures were incubated at 28°C in 5% v/v CO₂ and observed daily for cytopathic effects.

12

13 DNA extraction and PCR

14 Small tissue specimens of the liver, lung and intestine were used for DNA extraction using the
15 DNeasy Blood & Tissue Kit (Qiagen, Hilden, Germany) according to the manufacturer's
16 instructions. A nested PCR targeting a portion of the adenoviral DNA-dependent DNA-
17 polymerase gene (Wellehan et al., 2004) was carried out. The sample was also screened for
18 chelonian herpesviruses (VanDevanter et al., 1996), ranaviruses (Marschang et al., 1999) and
19 invertebrate iridoviruses (Jakob et al., 2002, Weinmann et al., 2007) by PCR according to the
20 protocols described by the authors. For detection of mycoplasma infection a general
21 mycoplasma PCR (Lauerma et al., 1995), amplifying a fragment from the end of the 16S
22 ribosomal RNA (rRNA) gene through the intergenic spacer region (ISR) to the beginning of
23 the 23S rRNA gene, was used. After obtaining and sequencing the amplicon of the general
24 PCR, a specific *M. agassizii* PCR (Brown et al., 1999) was carried out targeting the 16S
25 rRNA gene to gain more sequence data.

1

2 Sequencing and sequence analyses

3 PCR products were directly sequenced by using the Big Dye Terminator V3.1 Cycle
4 Sequencing Kit (Applied Biosystems, Foster City, USA) according to the manufacturer
5 instructions. The sequencing reaction was analyzed on an ABI PRISM® 3100 Genetic
6 Analyzer. New sequences were compared with sequences deposited into GenBank (National
7 Center for Biotechnology Information, Bethesda, USA) using BLASTX and BLASTN
8 (Atschul et al., 1997). Pairwise and multiple alignments of nucleotide and amino acid
9 sequences were made with the EMBOSS Pairwise Alignment Algorithms (Labarga et al.,
10 2007) and the Multalin computer program (Corpet, 1988)l, respectively. The aligned
11 sequences were edited with the GeneDoc program (Nicholas and Nicholas, 1997).

12 Phylogenetic analyses were carried out with several programs. Bayesian analysis was
13 performed using MrBayes 3.1 (Ronquist and Huelsenbeck, 2003) with gamma-distributed rate
14 variation, a proportion of invariant sites and Rtrv aminoacid substitution model. Maximum
15 likelihood analysis was carried out by using the PhyML online web server (Guindon et al.,
16 2005) with Rtrv aminoacid substitution model. Distance matrix analysis was performed with
17 programs included in the PHYLIP (Phylogeny Inference Package, version 3.68) program
18 package (Felsenstein, 1989). The trees were visualized using the TREEVIEW 1.6.6 program
19 (Page, 1996).

20

21 **Results and discussion**

22 Adenoviral infections are very common in different reptile species, but have only been
23 described in chelonians in two cases – in leopard tortoise (Wilkinson, 2004) and in Sulawesi
24 tortoises (Rivera et al., 2008) - so far. There is only limited information published about the
25 AdV of the leopard tortoise which was isolated together with a herpesvirus. The tortoise

1 exhibited biliverdinuria, wasting and episodes of hemorrhages were observed. The Sulawesi
2 tortoise AdV caused severe systemic disease with very high mortality rate, 92 of 105 animals
3 died due to the infection. Multifocal hepatic necrosis with amphophilic to basophilic
4 intranuclear inclusions and diffuse hepatic lipidosis were observed in the Sulawesi tortoises.
5 Other pathologic changes included myeloid necrosis in the bone marrow and severe
6 necrotizing enterocolitis.

7 Pathologic findings observed during macroscopic and microscopic examination of the box
8 turtle were typical of an adenovirus infection. Upon opening its body cavity the liver appeared
9 clay yellow in color. A small amount of transparent fluid was observed in the stomach, the
10 mucosa of which was intact and wrinkled. Transparent phlegm was seen in the intestines and
11 its mucosa had a slightly reddish color. The microscopic examination of the liver revealed
12 degeneration of liver cells, a pronounced vacuolization of the cytoplasm and pyknosis of
13 nuclei (Fig. 1). Large vacuoles were observed in the cytoplasm of some liver cells, in some
14 cases leading to marginization of the nuclei, whereas only small, fine vacuoles were present in
15 other cells. A light-bordered bright purplish blue, intensely staining inclusion body was also
16 seen in some nuclei. These nuclei were substantially enlarged, with chromatin
17 marginalization. Lymphoid cell infiltration was seen along the blood-vessels of the liver. The
18 submucosa of the small intestine also showed lymphoid cell infiltration.

19 Although attempts at virus isolation were unsuccessful, the sample was PCR positive for
20 adenoviruses supporting our observations described above. Chelonian herpesviruses, as well
21 as ranaviruses and invertebrate iridoviruses were not detected by PCR. Nucleotide sequencing
22 confirmed our PCR results. The sequence of the 275 bp long fragment of the partial DNA-
23 polymerase (Accession number: EU828750) gene indicated a novel AdV, with a balanced GC
24 content (49.45%). Comparison of the Box turtle AdV sequence with the corresponding region
25 of other AdVs showed that it was unique and distinct from previously known adenoviral

1 sequences. Amino acid sequence alignment of the DNA-polymerase gene showed that motifs
2 found in all known AdVs were less conserved in the Box turtle AdV (see Supplementary
3 material). Phylogenetic analyses also gave an interesting result (Fig. 2; see Supplementary
4 material). While the Sulawesi tortoise AdV seems to be related to siadenoviruses, the Box
5 turtle AdV did not cluster to any known genera. Although there were differences between the
6 branching topologies obtained by the different programs, all calculations confirmed the
7 distinctness of the Box turtle AdV. The analyses were based on a relatively short nested PCR
8 product (91 amino acid), therefore final conclusions cannot be drawn; further investigations
9 are needed to reveal its genome organization, further genes (hexon, protease) should be
10 included into phylogenetic calculations to establish the exact taxonomic position of this
11 exceptional virus. Characterization of other turtle and tortoise AdVs would also give more
12 information about the evolution and origin of chelonian AdVs.

13 Mass mortality in reptiles due to an adenoviral infection was demonstrated previously only in
14 a few cases (Kim et al., 2002; Rivera et al., 2008), usually single animals died, therefore the
15 pathogenicity of reptilian adenoviruses and their ability to cause primary disease remains
16 uncertain. Factors leading to immune suppression have been postulated to play a role in the
17 development of adenoviral disease, including stress (transportation, overcrowding),
18 inadequate housing, hibernation, co-infection with other pathogens (viruses, bacteria and/or
19 parasites), etc. In our instance the death of the turtle was also a single case. Additional
20 research is necessary to determine the prevalence of AdVs in chelonians and its clinical
21 importance.

22 Bacterial culture of the liver resulted in no growth; however, mycoplasma DNA was detected
23 by PCR. Sequences of the ISR (Accession number: FJ159565) and from the 16S rRNA
24 (Accession number: FJ159564) were obtained from the detected *Mycoplasma* sp. The analysis
25 of the amplified partial 16S rRNA sequence showed it to be identical with the formerly

1 identified *Mycoplasma* sp. of the eastern box turtle (Feldman et al., 2006). There was only 1
2 nucleotide difference between the overlapping sequences of the 16S rRNA gene. Pairwise
3 alignment of the amplified fragment containing the less conserved ISR sequence and the
4 corresponding region of the other two *Mycoplasma* spp. using testudinian hosts, *M. agassizii*
5 (AY780801) and *M. testudineum* (AY973570) demonstrated 87.9% (5.1% gaps) and 75.2%
6 (11.3% gaps) sequence identity, respectively. Unfortunately the homologous sequence of the
7 eastern box turtle *Mycoplasma* sp. was not available. Comparison of the chelonian
8 mycoplasma ISR sequences also confirmed that the box turtle *Mycoplasma* sp. is a distinct
9 species, since it differs from the previously characterized *Mycoplasma* spp. described in
10 chelonians.

11 Although we could detect the presence of the *Mycoplasma* sp. by PCR in our case, there were
12 no pathological lesions consistent with disease caused by mycoplasma. Successful isolation of
13 the detected infectious agents and experimental transmission studies should be carried out in
14 order to clarify the role the Box turtle AdV and the *Mycoplasma* sp. plays in the death of the
15 turtle.

16

17 **Acknowledgements**

18 We would like to thank to Rachel E. Marschang, Petra Stumpf and Tibor Papp at the Institut
19 für Umwelt- und Tierhygiene, Hohenheim University, Stuttgart, Germany for their help and
20 advices. This work was supported by the OTKA F67847 grant of the National Research Fund
21 of Hungary and the János Bolyai Research Scholarship of the Hungarian Academy of
22 Sciences.

23

24 **References**

- 1 Benkő, M., Harrach, B., Both, G.W., Russell, W.C., Adair, B.M., Adam, E., Dejong, J.C.,
2 Hess, M., Johnson, M., Kajon, A., Kidd, A.H., Lehmkuhl, H.D., Li, Q.G., Mautner, V., Pring-
3 Akerblom, P., and Wadell G., 2005. Family *Adenoviridae*. In: Fauquet, C.M., Mayo, M.A.,
4 Maniloff, J., Desselberger, U., Ball, L.A. (Eds.), *Virus Taxonomy*. Eighth Report of the
5 International Committee on Taxonomy of Viruses. Academic Press, San Diego, CA, pp. 213-
6 228.
- 7
- 8 Brown, D.R., 2002. Mycoplasmosis and immunity of fish and reptiles. *Front. Biosci.* 7, 1338-
9 46.
- 10
- 11 Brown, M.B., McLaughlin, G.S., Klein, P.A., Crenshaw, B.C., Schumacher, I.M., Brown,
12 D.R., Jacobson, E.R., 1999. Upper respiratory tract disease in the gopher tortoise is caused by
13 *Mycoplasma agassizii*. *J. Clin. Microbiol.* 37, 2262-2269.
- 14
- 15 Brown D.R., Merritt J.L., Jacobson E.R., Klein P.A., Tully J.G., Brown M. B., 2004.
16 *Mycoplasma testudineum* sp. nov., from a desert tortoise (*Gopherus agassizii*) with upper
17 respiratory tract disease. *Int. J. Syst. Evol. Microbiol.* 54, 1527-1529.
- 18
- 19 Corpet, F., 1988. Multiple sequence alignment with hierarchical clustering. *Nucleic Acids*
20 *Res.*, 16, 10881-10890.
- 21
- 22 Farkas, S.L., Harrach, B., Benko, M., 2008. Completion of the genome analysis of snake
23 adenovirus type 1, a representative of the reptilian lineage within the novel genus
24 *Atadenovirus*. *Virus Res.* 132, 132-139.
- 25

- 1 Feldman, S.H., Wimsatt, J., Marchang, R.E., Johnson, A.J., Brown, W., Mitchell, J.C.,
2 Sleeman, J.M., 2006. A novel mycoplasma detected in association with upper respiratory
3 disease syndrome in free-ranging eastern box turtles (*Terrapene carolina carolina*) in
4 Virginia. *J. Wildl. Dis.* 42, 279-289.
- 5
- 6 Felsenstein, J., 1989. PHYLIP - Phylogeny Inference Package (Version 3.2). *Cladistics* 5,
7 164-166.
- 8
- 9 Frye, F.L., Munn, R.J., Gardner, M., Barten, S.L., Hadfy, L.B., 1994. Adenovirus-like
10 hepatitis in a group of related rankins dragon lizards (*Pogona-henrylawsoni*). *J. Zoo Wildl.*
11 *Med.* 25, 167-171.
- 12
- 13 Guindon, S., Lethiec, F., Duroux, P., Gascuel, O., 2005. PHYML Online – a web server for
14 fast maximum likelihood-based phylogenetic inference. *Nucleic Acids Res.* 33 (Web Server
15 issue), W557-559.
- 16
- 17 Jakob, N.J., Kleespies, R.G., Tidona, C.A., Müller, K., Gelderblom, H.R., Darai, G. 2002.
18 Comparative analysis of the genome and host range characteristics of two insect iridoviruses:
19 Chilo iridescent virus and a cricket iridovirus isolate. *J. Gen. Virol.* 83, 463-470.
- 20
- 21 Kim, D.Y., Mitchell, M.A., Bauer, R.W., Poston, R., Cho, D.Y., 2002. An outbreak of
22 adenoviral infection in inland bearded dragons (*Pogona vitticeps*) coinfecting with
23 dependovirus and coccidial protozoa (*Isospora sp.*). *J. Vet. Diagn. Invest.* 14, 332-334.
- 24

- 1 Kovács, G.M., LaPatra, S.E., D'Halluin, J.C., Benkő, M., 2003. Phylogenetic analysis of the
2 hexon and protease genes of a fish adenovirus isolated from white sturgeon (*Acipenser*
3 *transmontanus*) supports the proposal for a new adenovirus genus. *Virus Res.* 98: 27-34.
4
- 5 Kübber-Heiss, A., Benetka, V., Filip, T., Benyr, G., Schilcher, F., Pallan, C., Möstl, K., 2006.
6 First detection of an adenovirus infection in a bearded dragon (*Pogona vitticeps*) in Austria
7 *Wiener Tierärztliche Monatsschrift* 93, 68-72.
8
- 9 Labarga, A., Valentin, F., Anderson, M., Lopez R., 2007. Web services at the European
10 bioinformatics institute. *Nucleic Acids Res.*, 35, W6-11.
11
- 12 Lauerman, L.H., Chilina, A.R., Closser, J.A., Johansen, D. 1995. Avian mycoplasma
13 identification using polymerase chain reaction amplicon and restriction fragment length
14 polymorphism analysis. *Avian Dis.* 39, 804-811.
15
- 16 Marschang, R.E., Becher, P., Posthaus, H., Wild, P., Thiel, H.J., Müller-Doblies, U., Kalet,
17 E.F., Bacciarini, L.N., 1999. Isolation and characterization of an iridovirus from Hermann's
18 tortoises (*Testudo hermanni*). *Arch. Virol.* 144, 1909-1922.
19
- 20 Nicholas, K.B., Nicholas, H.J.B., 1997. Genedoc: a tool for editing and annotating multiple
21 sequence alignments. Distributed by the author.
22
- 23 Page, R.D., 1996. TREEVIEW: An application to display phylogenetic trees on personal
24 computers. *Comput. Appl. Biosci.* 12, 357-358.
25

- 1 Papp, T., Fledelius, B., Schmidt, V., Kaján, G., Marschang, R.E., 2009. PCR-sequence
2 characterisation of new adenoviruses found in reptiles, and the first successful isolation of a
3 lizard adenovirus. *Vet. Microbiol.* 134, 233-240.
- 4
- 5 Ramis, A., Fernandez-Bellon, H., Majo, N., Martinez-Silvestre, A., Latimer, K., Campagnoli,
6 R., Harmon, B.G., Gregory, C.R., Steffens, W.L., Clubb, S., Crane, M., 2000. Adenovirus
7 hepatitis in a boa constrictor (*Boa constrictor*). *J. Vet. Diagn. Invest.* 12, 573-576.
- 8
- 9 Rivera, S., Wellehan, J.F.X., McManamon, R., Innis, C.J., Garner, M.M., Raphael, B.L.,
10 Gregory, C.R., Latimer, K.S., Rodriguez, C.E., Diaz-Figueroa, O., Marlar, A.B., Nyaoke, A.,
11 Gates, A.E., Gilbert, K., Childress, A.L., Risatti, G.R., Frasca S., 2008. Systemic adenovirus
12 infection in Sulawesi Tortoises (*Indotestudo fortseni*) caused by a novel siadenovirus.
13 (Submitted for publication)
- 14
- 15 Ronquist, F., Huelsenbeck, J.P., 2003. MrBayes 3: Bayesian phylogenetic inference under
16 mixed models. *Bioinformatics* 19, 1572-1574.
- 17
- 18 VanDevanter D.R., Warrenner, P., Bennett, L., Schultz, E.R., Coulter, S., Garber, R.L., Rose,
19 T.M. 1996. Detection and analysis of diverse herpesviral species by consensus primer PCR. *J.*
20 *Clin. Microbiol.* 34, 1666-1671.
- 21
- 22 Weinmann, N., Papp, T., Alves de Matos, A.P., Teifke, J.P., Marschang, R.E., 2007.
23 Experimental infection of crickets (*Gryllus bimaculatus*) with an invertebrate iridovirus
24 isolated from a high-casqued chameleon (*Chamaeleo hoehnelii*). *J. Vet. Diagn. Invest.* 19,
25 674-679.

1

2 Wellehan, J.F.X., Johnson, A.J., 2005. Reptile virology. *Vet. Clin. Exot. Anim.* 8, 27-52.

3

4 Wellehan, J.F.X., Johnson, A.J., Harrach, B., Benkő, M., Pessier, A.P. Johnson, C.M., Garner,
5 M.M., Childress, A., Jacobson, E.R., 2004. Detection and analysis of six lizard adenoviruses
6 by consensus primer PCR provides further evidence of a reptilian origin for the
7 atadenoviruses. *J. Virol.* 78, 13366-13369.

8

9 Wilkinson R., 2004. Clinical pathology. In: McArthur, S., Wilkinson, R., Meyer, J. (Eds.)
10 *Medicine and surgery of tortoises and turtles.* Blackwell Press, Oxford, UK, pp. 141-186.

11

12 **Figure captions:**

13

14 Fig. 1. Inclusion body hepatitis in an ornate box turtle. Histological section of the liver
15 (magnification: 300x, staining: hematoxylin-eosin); 1. inflammatory cell infiltration, 2. cross-
16 section of a blood-vessel, 3. physiological pigmentation, 4. intranuclear inclusion body in the
17 hepatocytes.

18

19 Fig. 2. Unrooted phylogenetic tree based on maximum likelihood analysis of partial
20 adenoviral DNA-dependent DNA-polymerase amino acid sequences showing the clustering
21 of adenoviruses. Bayesian posterior probability values for branchings are in bold. Bootstrap
22 values for the maximum likelihood tree are given for 100 data sets. Bayesian posterior
23 probability values and bootstrap values are shown only for the main branches. Abbreviations
24 of the adenovirus types: B, bovine; C, canine; D, duck; F, fowl; Fr, frog; M, murine; O, ovine;
25 P, porcine; S, simian; T, turkey; TS, tree shrew. GenBank accession numbers are as follows:

- 1 Agamid AY576678; B1 NC_006324; B4 AF036092; C1 U55001; Chameleonid AY576679;
- 2 D1 AC_000004; Eublepharid AY576677; F1 AC_000014; F9 AC_000013; Fr1 AF224336;
- 3 Gekkonid AY576681; H2 J01917; H4 AY487947; H40 L19443; Helodermatid AY576680;
- 4 M1 AC_000012; O7 U40839; P3 AB026117; P5 AF289262; Parakeet EU056825; Meyer
- 5 AY644731; S21 AC_000010; Scincid AY576682; Snake DQ106414; Sulawesi EU056826;
- 6 T3 AF074946; TS NC_004453.

Accepted Manuscript

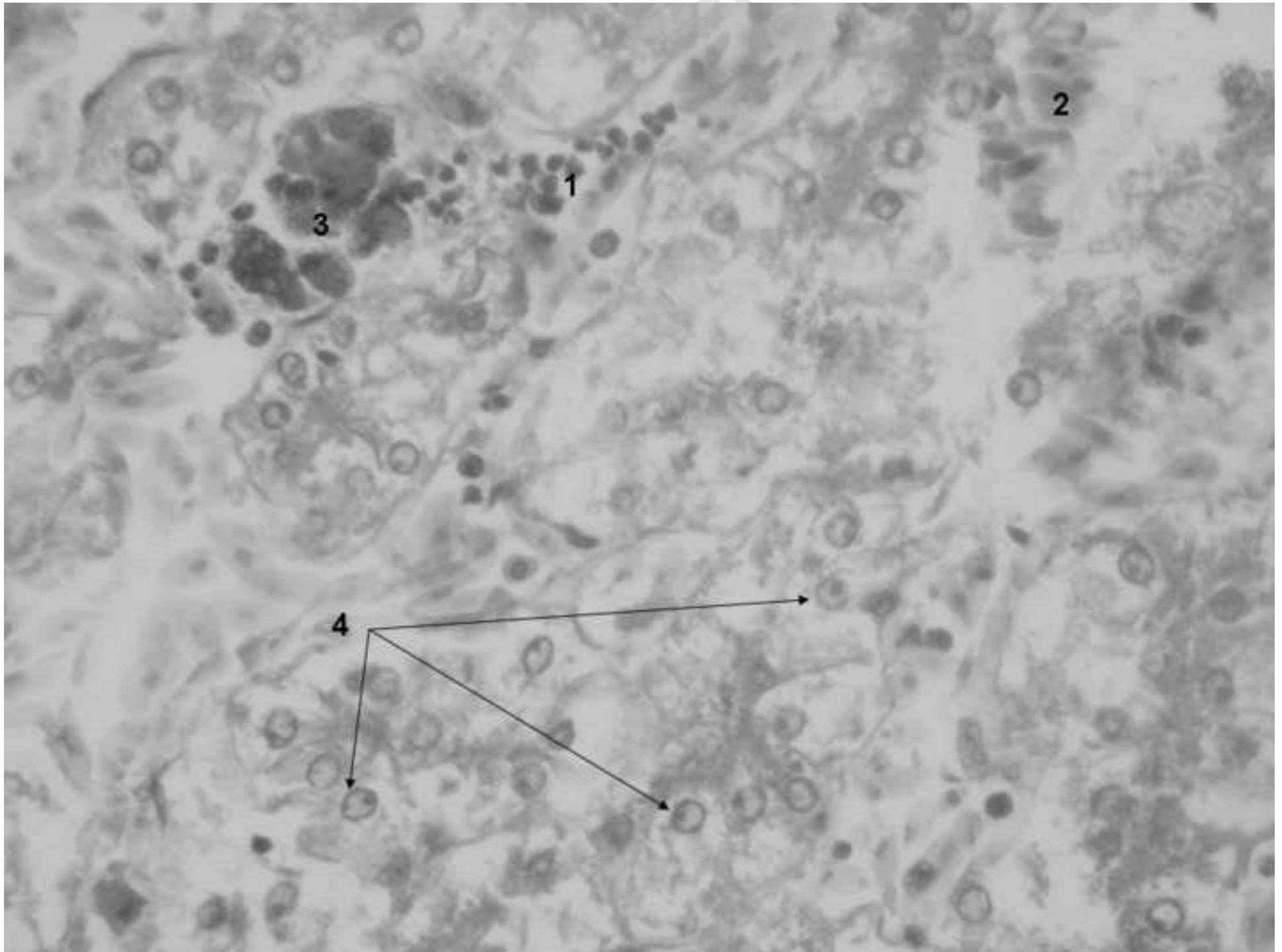
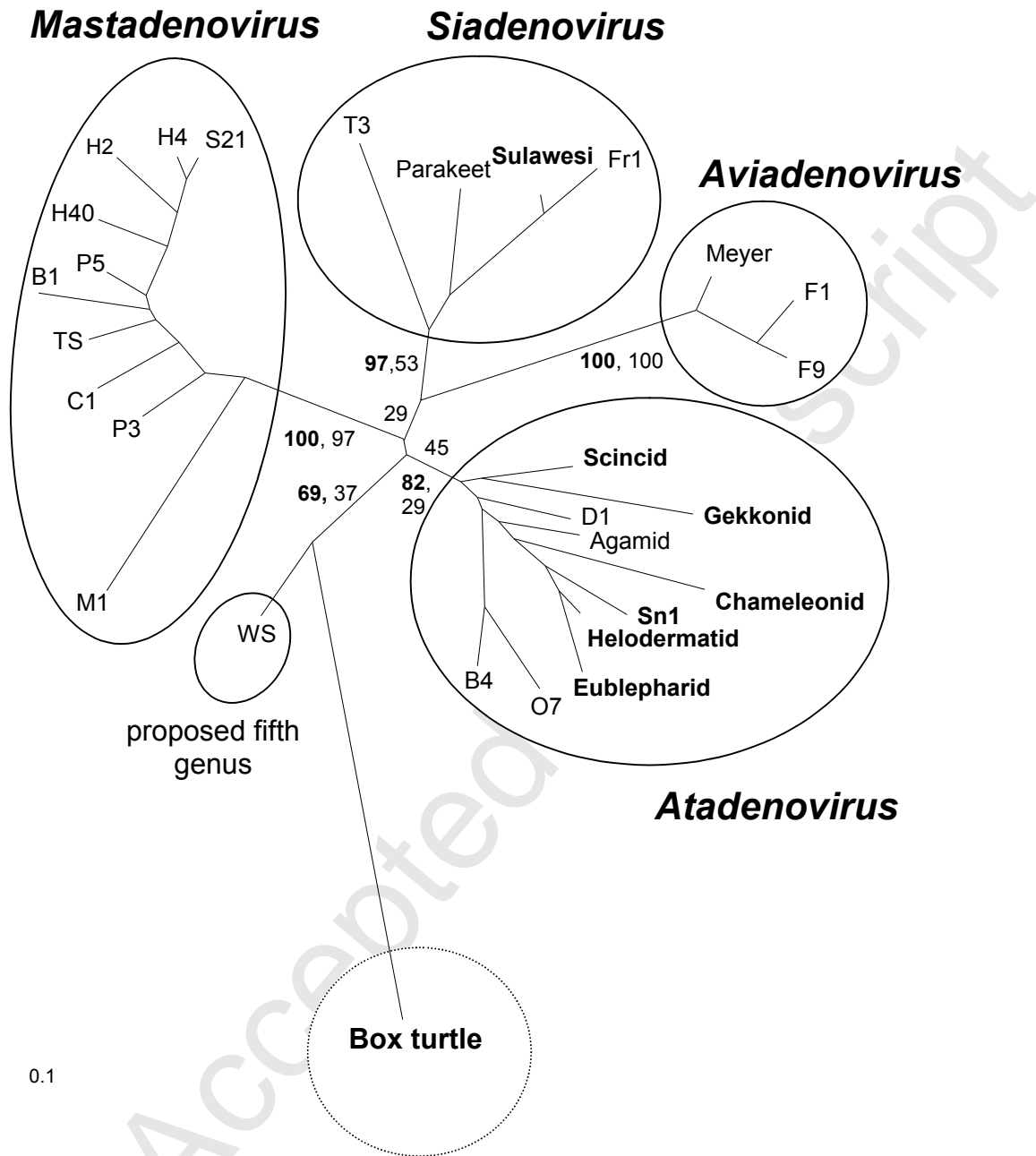
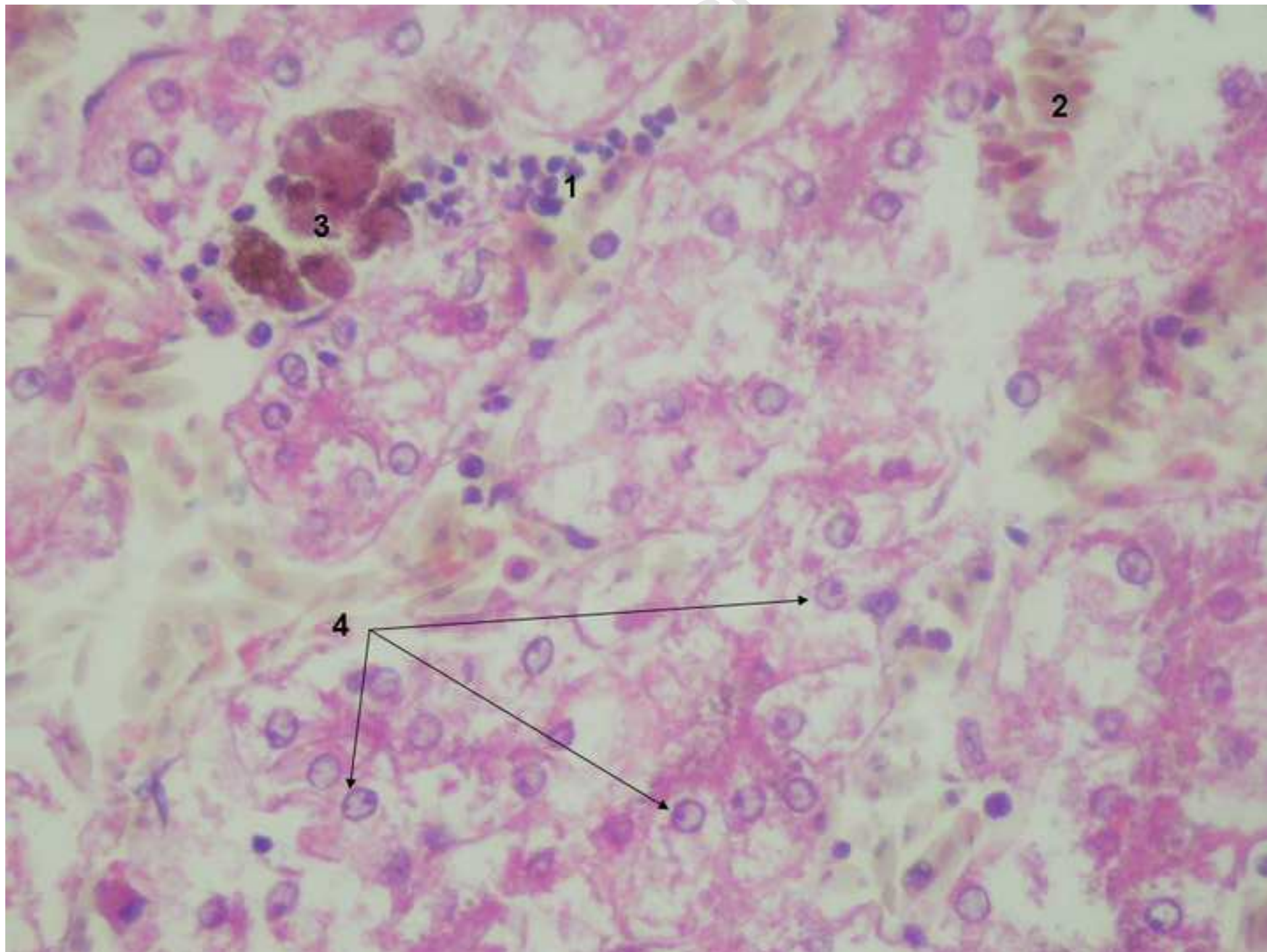


Figure 2.





Mouse AdV1 SALTHEMFSQWPLEPKARAEALADWTKHLSN-SAPISYFN-TCLLHGIVLIDADPPCETQLDVLPPFCSRKGGRLCWTNEPLRGEITTTIDV : 90
 Tupaia AdV1 SALTHEFFSQRPLNPFDRALAVKNWEMRLKN-SQTIIDYFT-PHLLPGIFTIDADPPSETYLDVLPFFCSRKGGRLCWTNEPLRGEVATSVDI : 90
 Canine AdV1 SALTHEFFSAGSPLNPFYERAVAIKAYEHKMQE-HKTIISYFD-EDLLPGIFTIDADPPAEFLDVLPPFCSRKGGRLCWTNEPLRGEVTTSIDV : 90
 Porcine AdV3 SALTHEFFSAGQPLNPFDRALAARRWQDRLDG-PEPLISYFD-PDLLPALFTIDADPPDEDQLDVLPPYCSRKGGRLCWTNEPLRGEVATSVDV : 90
 Porcine AdV5 SALTHEMFSQSPLNPFERALAVAVWEDQLKSVGQKMDYFD-EKLLPGIFTIDADPPDESFLDVLPPFCSRKGGRLCWTNEPLRGEVATSVDV : 91
 Bovine AdV1 SALTHEFFSAGQPLNPFERAVAASDWSRRLSAHGSRIDYFD-DTLLPGIFTVDADPPDELFDELPHFCSRKGGRLCWTNEPLRGEVATSVDM : 91
 Simian AdV21 SALTHEMFWGTPLNPFYERALAAREWQMALDD-PAHISYFD-KDLLPGIFTMDADPPDELMLDPLPHFCSRKGGRLCWTNEPLRGEVATSVDL : 90
 Human AdV2 SALTHEMFWGPPLNPFYERALAARAWQQAIDLQGCKIDYFD-ARLLPGVFTVDADPPDETQLDPLPHFCSRKGGRLCWTNERLRGEVATSVDL : 91
 Human AdV4 SALTHEMFWGTPLSPYERALAVREWQASIDDLGTCISYFD-PDLLPGIFTIDADPPDELMLDPLPHFCSRKGGRLCWTNEPLRGEVATSVDL : 91
 Human AdV40 SALTHEMFWGFPLNPFYERALAVRDWEHALLQVGTPIIDYFN-RTLLPGIFTIDADPPENLLDVLPPFCSRKGGRLCWTNEPLRGEVVTSDV : 91

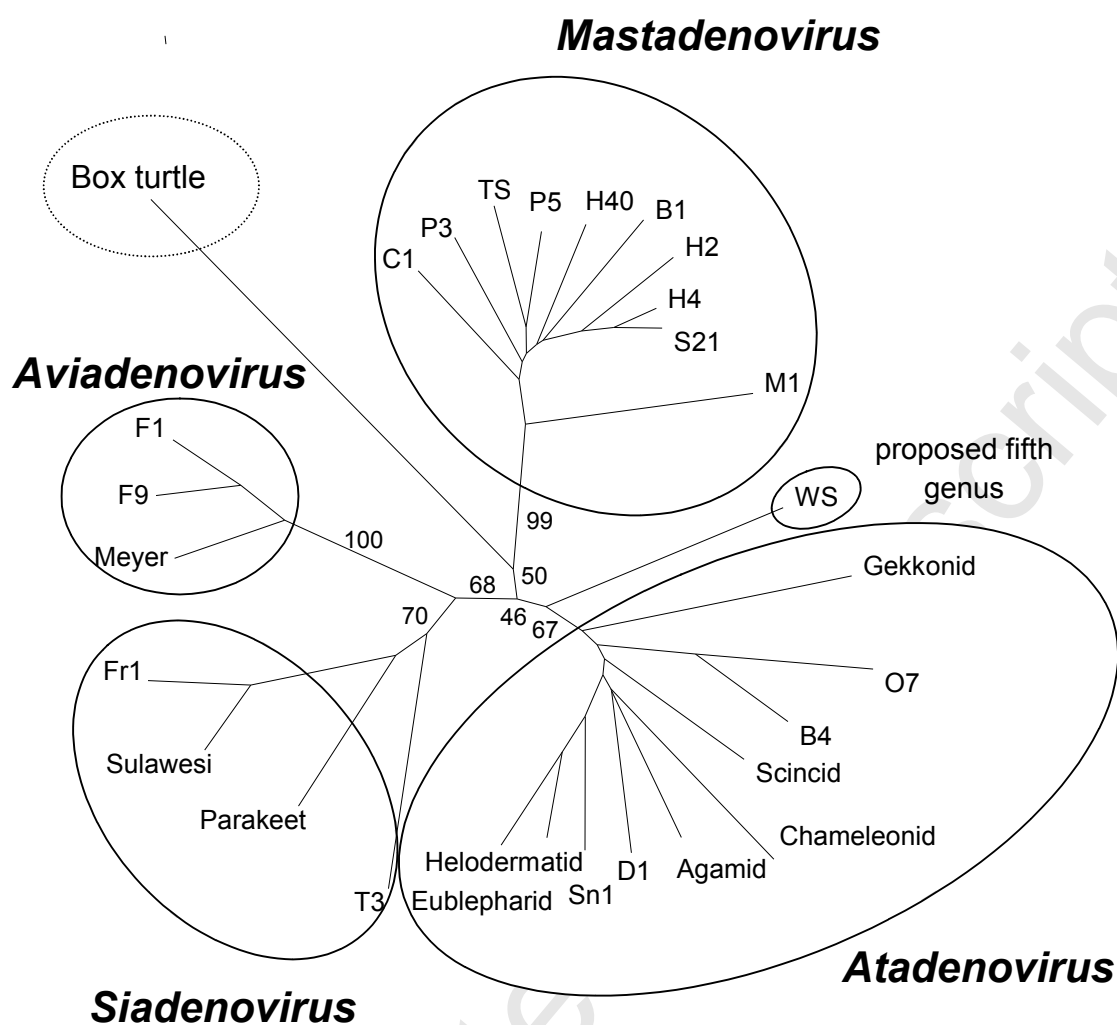
 Fowl AdV1 SALTHEMFBHGMPLDPKFTAQHVEELNRLLTN-ESHISYFD-ARIKPSILKIEAYPPPEMLDPLPHICSRKGGRLVWTNEALYDEVVTVIDI : 90
 Fowl AdV9 SALTHEMFBHGMPLDPKFTAKHVDELNELMSS-ERPLISYFD-HRIKPCILKVEAYPPAEHLDTLPHICSRKGGRLVWTNEALYDEVITVIDI : 90
 Meyer's parrot AdV1 SALTHEMFBHGIPLDPHHTVTHVNLNIIIASGERPLISYFD-PRIKPAILKTDAPPPPEMLDVLPHICSRKGGRLVWTNEPLHDEVITIIDV : 91

 Frog AdV1 SALTHEMFFCVPLSQEKNQEIHILQSKLQN-EKTIINLYFD-PEIKPMIISISAFPPVEYLTNIPPHICSRKSGRLCWTNEALYDEVVTVIDV : 90
 Turkey AdV3 SALTHEMFPYGFPIGEKERNNEITKLNEKIKKTKTKLSYFT--DIKPMVVMIDAIPPPEHLDPPLPFCSRQSGKLCWTNEILKNEIVTSIDI : 90
 Parakeet AdV1 SALTHELFFGIPVKGTEKEQEIEKFORLDDT-KEKISYFE--NIKPMIININAFPPPEKLDCLPPLCSRKSGKLCWTNEPLKDEVITSIDA : 89
 Sulawesi tortoise AdV1 SALTHEMFFGIPISKKEKEQAIELLQSKLEN-KKTIISYFD-HEIKPMIISISALPPVEFLTNIPPLCSRKSGRLCWTNEPLYDEVVTVIDV : 90

 Duck AdV1 SALTHEMFFGRTEDPLTASISIKTFQDKLDS-PAKISYFG-ESIKPMIVYADCYPPLEHVVDVLPPLCSRKSGRLCWTNEPLLGEVVTITIDL : 90
 Bovine AdV4 SALTHEMFPYGRITLNFEEANTSIDEMONMDS-SEVLISYFD-PRIKAMIVVADCEPPTLEYLDVLPPLCSKKS GKLCWTNEPLLINEVTTSIDL : 90
 Ovine AdV7 SALTHELFPYKTLNAFEANAQIDYFQELLQR-KEKIDYFD-NSIKPMIVVADCEPPLSLDYLDVLPPLCSKKS GKLCWSNETLINEVLTSIDL : 90
 Snake AdV1 SALSHMFPYGPPTLSPFDSAVAIAEFORKLDG-QSELISYFD-PDIFPMIVVADAFPPSLHCLDVLPPPLCSKRS GKLCWTNEPLLGEVLTITVDL : 90
 Gekkonid AdV1 SALTHEMFFGLPCEPFTANIHIRQFOYLLDEVGKPIISYFD-ERIKPMIVAADCFPPSIKELDVLPPMCTRKGKLCWTNEPLHMEILTSVDL : 91
 Agamid AdV1 SALSHMFPCCRTLPPLDASIEIRRFQDKLKD-CHKISYFD-PNLKPMIVAADCIPPLNELDVLPPPLCSKAS GKLCWTNEPLVGEVLTSIDL : 90
 Eublepharid AdV1 SALSHMFPYGTTLSPFDSSKAMASFOALLDG-KDCLISYFD-PRILPMIVKVDCEPPLYHLDLTPPLCSKKS GKLCWTNEPLLGEVITTTVDI : 90
 Helodermatid AdV1 SALSHMFPYGLTLPPLDASVAMAREFQDKLDS-TEKLSYFD-KNILPMIVKADCFPPPLYHLDVLPPLCSKKS GKLCWTNEPLLGEVLTITVDI : 90
 Scincid AdV1 SALTHEMFSGIPLDPFTSSIAIRKFKONKLE-PSTISYFD-PDIFPMIVVADCSPPLEQLDVLPPPLCSKKS GKLCWTNEPLEVEITLITIDL : 90
 Chameleonid AdV1 SALSHMFSGTTESPTDAALS IAYFQDLK-PDQISYFS--QVKPMIVLADCYPPALARLDVLPPLCSRSGKLCWTNEVLTAEALTTVDL : 89

 Sturgeon AdV1 SALTHEMFPYGYPLEPLEASTHIKLFQELLDLDR-PEDISYFN-DTVKPMILSIDAHPPNINYLDTLPPFCSRQSGRLCWTNEALISEIVTSLDC : 90
Box turtle AdV1 SALTYLEFYGMPLDPPAAEAAIIRFQHYITTT-EETISWLDLFEAYPPAFQADLHPDPLLTDTLPPFCSRDS GKLCWTNEFMSCGIIITSLDA : 91

Alignment of partial adenoviral DNA-dependent DNA-polymerase amino acid sequences generated by the Multalin computer program. Lines separate genera and the Box turtle adenovirus is in bold font.



Unrooted phylogenetic tree of partial adenoviral DNA-dependent DNA-polymerase amino acid sequences showing the clustering of adenoviruses. The tree was constructed with the programs included in the PHYLIP (Phylogeny Inference Package, version 3.572c) program package. For distance matrix analysis, the aligned sequences were processed first with PROTDIST (Jones-Taylor-Thornton substitution model) and then with the FITCH (Fitch-Margoliash; global rearrangements) program. For bootstrap analysis, the SEQBOOT program was run before PROTDIST and FITCH. The most probable tree was calculated with the

CONSENSE program. The length of the branches indicates the phylogenetic distance between the different viruses. Bootstrap values are given for 100 data sets and shown only for the main branches.

Accepted Manuscript