



**HAL**  
open science

## Life-threatening interstitial lung disease associated with trastuzumab: case report

M. J. Pepels, K. A. Boomars, R. Kimmenade, P. S. Hupperets

### ► To cite this version:

M. J. Pepels, K. A. Boomars, R. Kimmenade, P. S. Hupperets. Life-threatening interstitial lung disease associated with trastuzumab: case report. *Breast Cancer Research and Treatment*, 2008, 113 (3), pp.609-612. 10.1007/s10549-008-9966-8 . hal-00486607

**HAL Id: hal-00486607**

**<https://hal.science/hal-00486607>**

Submitted on 26 May 2010

**HAL** is a multi-disciplinary open access archive for the deposit and dissemination of scientific research documents, whether they are published or not. The documents may come from teaching and research institutions in France or abroad, or from public or private research centers.

L'archive ouverte pluridisciplinaire **HAL**, est destinée au dépôt et à la diffusion de documents scientifiques de niveau recherche, publiés ou non, émanant des établissements d'enseignement et de recherche français ou étrangers, des laboratoires publics ou privés.

## Life-threatening interstitial lung disease associated with trastuzumab: case report

M. J. Pepels · K. A. Boomars · R. van Kimmenade ·  
P. S. Hupperets

Received: 18 November 2007 / Accepted: 4 March 2008 / Published online: 16 March 2008  
© Springer Science+Business Media, LLC. 2008

**Abstract** A female patient with HER2 positive, metastatic breast cancer presented with pulmonary infiltrates, and a plural effusion dyspnoea after several months of trastuzumab treatment. She had been treated without complications with six courses of docetaxel and trastuzumab in combination with dexamethasone with partial remission of disease. Malignancy, infection and cardiomyopathy were excluded as causes of dyspnoea. Pleural and bronchoalveolar fluid analyses (BAL) showed eosinophils. A diagnosis of trastuzumab-induced pneumonitis was made. After treatment with steroids there was gradual clinical improvement and disappearance of infiltrates. Although a causative association between trastuzumab and this patient's pulmonary syndrome was not proven, the potential for this toxicity should be considered.

**Keywords** Breast cancer · Dyspnoea · Eosinophils · Infiltrates · Trastuzumab

### Introduction

The HER-2/neu proto-oncogene is a poor prognostic factor and is amplified in 20–30% of patients with primary breast cancer. Trastuzumab, a monoclonal antibody directed against HER2, improves response, time to progression, and overall survival in both the metastatic and adjuvant settings in patients with HER2 positive breast cancer [1–3]. Trastuzumab is introduced as standard adjuvant treatment to patients with HER-2 positive tumors [1]. Before, trastuzumab was already introduced as first-line treatment in combination with a taxane after prior use of anthracyclines, for metastasized disease. Patients who express high levels of HER-2/neu are most likely to respond to trastuzumab.

### Case description

A 56-year-old non-smoking female underwent neoadjuvant chemotherapy for cT3N1M0 ductal carcinoma of the left breast in December 2003. The chemotherapy consisted of six courses of 5-fluorouracil, doxorubicin, and cyclophosphamide (FAC) administered every 3 weeks. Chemotherapy resulted in a partial remission after which a radical mastectomy was performed in June 2004. Histopathological findings revealed an invasive ductal carcinoma of 2.2 cm, grade III with HER-2(3+) receptor overexpression. With 1 out of 10 axillary lymph nodes involved with metastatic cancer.

Immunohistochemical staining for oestrogen and progesterone receptors was negative. At subsequent follow-up visits no signs of recurrent disease were found.

In January 2006 she noticed thickening of the skin under her left mastectomy scar. Histopathologic examination showed an invasive ductal adenocarcinoma, with HER-2(3+)

---

M. J. Pepels (✉) · P. S. Hupperets  
Division of Medical Oncology, Department of Internal  
Medicine, University Hospital Maastricht, P.O. Box 5800,  
6202 AZ Maastricht, The Netherlands  
e-mail: mpepels@hotmail.com

K. A. Boomars  
Department of Respiratory Diseases, University Hospital  
Maastricht, P.O. Box 5800, 6202 AZ Maastricht,  
The Netherlands

R. van Kimmenade  
Department of Internal Medicine, University Hospital  
Maastricht, P.O. Box 5800, 6202 AZ Maastricht,  
The Netherlands

receptor overexpression. A computed tomography of the chest and the abdomen demonstrated local thickening of the skin and abdominal lymphadenopathy. No apparent metastases were present in the lungs, liver or other sites. Before starting treatment she did not suffer from any pulmonary symptoms. Her ECOG performance score was one. In January 2006 treatment was initiated with trastuzumab and docetaxel, every 3 weeks. A gradual decline of the skin thickening and the abdominal lymphadenopathy was demonstrated after six courses of docetaxel/trastuzumab. A chest X-ray taken in March 2006 did still not show any abnormalities. In May 2006 docetaxel was discontinued and trastuzumab was continued as monotherapy.

Eight days after the first administration of trastuzumab (30 days after her last docetaxel) the patient complained of dry cough and progressive dyspnoea. Apart from Oxycontin 20 mg twice daily she was not taking any other medication at that time. Physical examination revealed a temperature of 38°C, a pulse rate of 119/min, blood pressure 125/85 mmHg and an oxygen saturation of 86%. No supplemental oxygen was administered at that time. At the lung bases crackles were noticed. Laboratory tests showed a haemoglobin level 6.2 mmol/l (normal >7.3), leucocytes  $7.8 \times 10^9/l$ , neutrophils  $5.0 \times 10^9/l$ , eosinophils  $1,000 \times 10^6/l$  (normal 40–440), CRP 133 (normal <9 mg/l). Renal and liver biochemistry test results did not show any abnormalities. An NT-proBNP and IgE level were not elevated nor was the ANCA titer.

With 5 l of nasal oxygen, the arterial blood gas analysis showed a hypoxemia with a PO<sub>2</sub> of 6.5 kPa (normal >8.7) and an oxygen saturation of 90%.

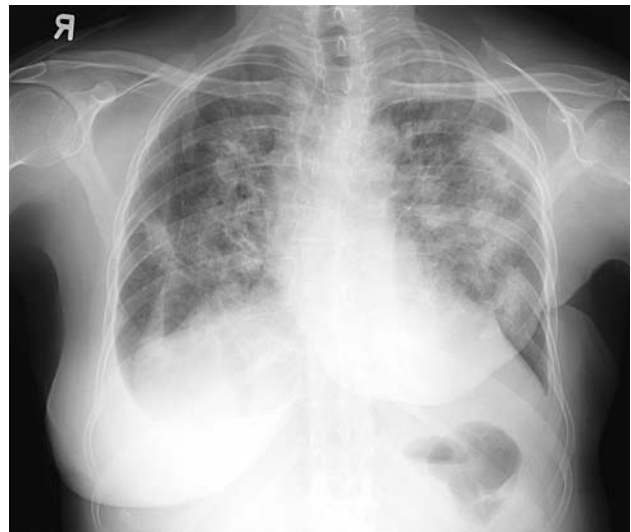
A chest X-ray showed bilateral patchy consolidations and pleural effusion without cardiomegaly or any other signs of heart failure (Fig. 1).

Blood cultures remained negative. A PCR for CMV was performed and was negative, as was a serological aspergillus antigen test (galactomanantest). A urine sample for Legionella did not show any antigen.

A spiral CT angio of the thorax showed no signs of pulmonary embolism. However, patchy consolidations were observed in both lungs as well as bilateral pleural effusions.

To exclude heart failure a transthoracic echocardiography was performed which showed a normal left ventricular ejection fraction (65%) without any signs of diastolic dysfunction or any other abnormalities.

A diagnostic thoracentesis was performed. Biochemical analysis of the serous fluid demonstrated an exudate. Microbiological examination revealed many leucocytes, but no bacteria were seen. Ziehl-Neelsen staining was negative. Cytological examination did not reveal any malignant cells. After cultures were taken treatment with amoxicillin with clavulanic acid and levofloxacin was initiated to cover typical and atypical respiratory infections. There was clinical



**Fig. 1** Chest ray at presentation

improvement of dyspnoea and oxygen supply was gradually diminished.

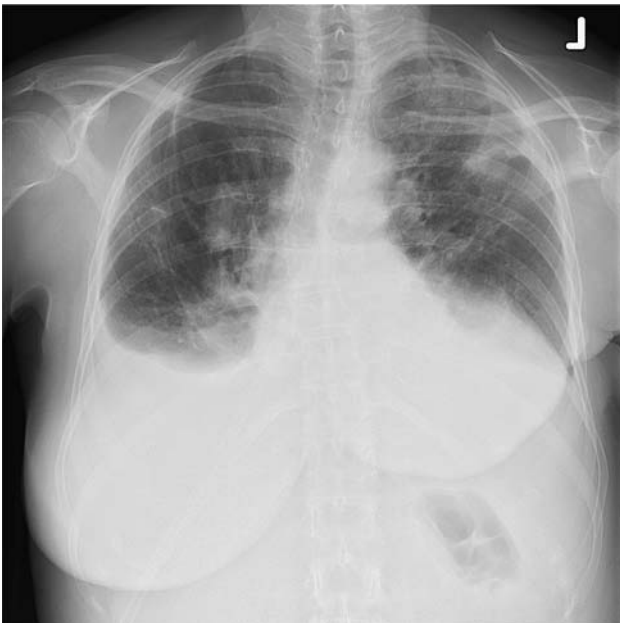
During hospitalization, trastuzumab was again administered, 3 weeks after the prior administration. After this dose the patient's temperature rose to 38.7°C. She also complained of progressive dyspnoea and wheezing. Thoracentesis was repeated, and 1,500 ml of pleural fluid was evacuated. Microbiological examination did not show any micro-organisms and cultures remained negative. Cytological examination again revealed no malignant cells; however many eosinophilic granulocytes were observed.

A bronchoalveolar lavage (BAL) was performed, with instillation of 4 × 50 ml NaCl 0.9% in the middle lobe. The cell count showed 257,000 cells/ml. Cell differentiation of 500 cells showed 38.8% alveolar macrophages, 25.2% lymphocytes, 17.8% polymorphonuclear neutrophils, and 18% eosinophils. No malignant cells and no intracellular bacteria were observed. Microbiological cultures of the BAL fluid for bacteria, viruses, fungi and tuberculosis remained negative. An immunofluorescence test for Legionella on BAL fluid was also negative.

An allergic reaction to trastuzumab was highly suspected, based on the presence of eosinophils in BAL and pleural fluid and in the absence of an infectious agent. A lung biopsy via VATS was considered but the risk of ventilatory complications was regarded too high. The patient was treated with prednisolone 40 mg once daily. She gradually recovered and became independent of oxygen. A chest X-ray showed diminishment of the consolidations (Fig. 2).

## Discussion

This female patient with HER2 positive breast cancer metastases to skin and abdominal lymph nodes was treated



**Fig. 2** Chest ray after some improvement

with docetaxel and trastuzumab. After six courses of combined therapy, docetaxel was stopped. Trastuzumab monotherapy was continued. After the first trastuzumab monotherapy infusion our patient was hospitalized because of dry cough and dyspnoea. With supportive therapy she gradually recovered but after a second treatment of trastuzumab there was again deterioration of her symptoms. Eventually, after exclusion of other causes, the pneumonitis appeared to be the consequence of trastuzumab. Analysis of BAL fluid demonstrated a pattern compatible with drug-induced pneumonitis. After treatment with corticosteroids dyspnoea and cough gradually disappeared and the consolidations on the chest X-ray diminished.

In several series, trastuzumab has been well-tolerated, and addition of trastuzumab to chemotherapy does not significantly increase the frequency of side effects [4]. Infusion-related events are common but rarely severe, and they are more common during the first administration [5]. In an analysis of the safety of the administration of trastuzumab to 25,000 patients, the only respiratory-associated serious adverse event was bronchospasm [6]. These reactions occurred usually within 2.5 h of administration. However, apart from described infusion-related bronchospasms, rare cases of interstitial pneumonitis have been reported. One patient with an organizing pneumonia and another with a pneumonitis were reported, probably due to trastuzumab administration [7, 8]. In trial B-31, four patients in the trastuzumab group had interstitial pneumonitis, one of whom died [1]. In the N9831 trial, five patients in the trastuzumab group had grade 3+ pneumonitis or pulmonary infiltrates, one of whom died [1].

Drug-induced infiltrative lung disease (DI-ILD) is the most common form of anti-neoplastic agent-induced respiratory disease. Patterns of DI-ILD are non-specific interstitial pneumonia, eosinophilic pneumonia, hypersensitivity pneumonitis, pulmonary fibrosis, or organizing pneumonia [9]. Early withdrawal of the causative drug will often lead to improvement or even cure of the ILD. Corticosteroids may suppress the inflammatory reaction [10, 11].

After trastuzumab monotherapy our patient developed symptoms and signs indicative of DI-ILD. Because of the time dependent relationship between the infusion of trastuzumab and the signs and symptoms a causal relationship is likely to exist although it is not proven.

Based on the history, physical examination and the HRCT and the BAL fluid analyses, our patient was diagnosed with drug-induced interstitial lung disease.

A peculiar feature of this case is why this patient did not develop symptoms of trastuzumab-induced pneumonitis earlier in her course? We speculate that before trastuzumab monotherapy was initiated, combination therapy with docetaxel was given with accompanying dexamethasone. Perhaps the concurrent dexamethasone prevented trastuzumab-related complications.

Taken together, the reports of apparent trastuzumab-related pulmonary interstitial disease in B-31, N9831, and by Vahid, et al., Radzikowska, et al., and ourselves are highly suggestive this syndrome is a rare, but real, complication of this therapy. Clinicians should be aware of it and prepared to respond appropriately, including discontinuation of further treatment or cautious co-administration with corticosteroids.

## References

1. Romond E, Perez A et al (2005) Trastuzumab plus adjuvant chemotherapy for operable HER2-positive breast cancer. *N Engl J Med* 353:1673–1684
2. Piccart M, Procter M et al (2005) Trastuzumab after adjuvant chemotherapy in HER2-positive breast cancer. *N Engl J Med* 353:1659–1672
3. Slamon D, Leyland B et al (2001) Use of chemotherapy plus a monoclonal antibody against HER2 for metastatic breast cancer that overexpresses HER2. *N Engl J Med* 344:783–792
4. Marty M, Cogenitti F et al (2005) Randomized phase II trial of the efficacy and safety of trastuzumab combined with docetaxel in patients with human epidermal growth factor receptor 2-positive metastatic breast cancer administered as first-line treatment: the M77001 study group. *J Clin Oncol* 23:4265–4274
5. Baselga J, Carbonell X et al (2005) Phase II study of efficacy, safety and pharmacokinetics of trastuzumab monotherapy administered on a 3-weekly schedule. *J Clin Oncol* 23:2162–2171
6. Cook-Burns N (2001) Retrospective analysis of the safety of Herceptin immunotherapy in metastatic breast cancer. *Oncology* 61(Suppl 2):58–66
7. Vahid B, Mehrotra A (2006) Trastuzumab (Herceptin)-associated lung injury. *Respirology* 11:655–658

8. Radzikowska E, Szczepulska E et al (2003) Organising pneumonia caused by trastuzumab (Herceptin) therapy for breast cancer. *Eur Respir J* 21:552–555
9. Dimopoulou I, Bamias A et al (2006) Pulmonary toxicity from novel antineoplastic agents. *Ann Oncol* 17:372–379
10. Camus P, Fanton A et al (2004) Interstitial lung disease induced by drugs and radiation. *Respiration* 71:301–326
11. Camus PH, Foucher P et al (2001) Drug-induced infiltrative lung disease. *Eur Respir J* 18(Suppl 32):93s–100s