



HAL
open science

18F-FDG PET/CT in primary non-Hodgkin's lymphoma of the sinonasal tract

Adrian Tempescul, Solene Querellou, Jean-Christophe Ianotto, Sylvie Boisramé, Gerald Valette, Christian C. Berthou

► **To cite this version:**

Adrian Tempescul, Solene Querellou, Jean-Christophe Ianotto, Sylvie Boisramé, Gerald Valette, et al.. 18F-FDG PET/CT in primary non-Hodgkin's lymphoma of the sinonasal tract. *Annals of Hematology*, 2009, 89 (6), pp.635-637. 10.1007/s00277-009-0842-3 . hal-00486565

HAL Id: hal-00486565

<https://hal.science/hal-00486565>

Submitted on 26 May 2010

HAL is a multi-disciplinary open access archive for the deposit and dissemination of scientific research documents, whether they are published or not. The documents may come from teaching and research institutions in France or abroad, or from public or private research centers.

L'archive ouverte pluridisciplinaire **HAL**, est destinée au dépôt et à la diffusion de documents scientifiques de niveau recherche, publiés ou non, émanant des établissements d'enseignement et de recherche français ou étrangers, des laboratoires publics ou privés.

Editorial Manager(tm) for Annals of Hematology
Manuscript Draft

Manuscript Number: AOHE-D-09-00225R1

Title: 18 FDG-PET in primary non-Hodgkin's lymphoma of the sinonasal tract

Article Type: Letter to the Editor

Keywords: lymphoma
sinonasal tract
18 FDG PET

Corresponding Author: Mr Adrian Tempescul, MD

Corresponding Author's Institution: Institute de Cancerologie et d'Hematologie

First Author: Adrian Tempescul, MD

Order of Authors: Adrian Tempescul, MD; Solene Querellou; Jean-Christophe Ianotto; Sylvie Boiramé; Gerald Valette; Christian Berthou

Abstract: Standard procedures for primary lymphoma of the sinonasal tract, before treatment and for therapeutic response evaluation include clinical examination, computed tomography and/or MRI. Many studies have demonstrated the utility of 18 FDG-PET for staging and for response assessment of lymphoma.

We present here the cases of two patients, with primary lymphoma of the sinonasal tract, in which the 18 FDG PET evaluations showed positive images, suspecting the presence of residual lymphoma tissue. This hypothesis was refuted by a biopsy of the residual lesions.

Response to Reviewers: Dear Editor, Dear Reviewer,

As requested, we tried to respond to all questions:

Question 1 and Question 2

We used for evaluation SUV max.

For the patient number one

Initial SUV max: 5.9

Residual SUV max: 3.9

Uptake reduction: 32%

For the patient number two

Initial SUV max: 4.19

Residual SUV max: 3.3

Uptake reduction: 21%

Question 3

It was proved that it is necessary an interval of 14 days between chemotherapy and PET scan to minimize the risks of false positive results due to the inflammation and increased macrophage activity (2)

The intermediate evaluation was made after two courses of chemotherapy, six days after the end of G-CSF, at day 18.

Question 4

G-CSF (Filgrastim 5µg/kg) was used starting day 8 to day 12

Question 5

We believe that is important to have a figure showing the extent of inflammation as recommended by the reviewer. Unfortunately, as requested into the "Type of papers" we can use only one figure.

We completed the References as recommended

1. Cheson BD, Pfistner B, Juweid ME, Gascoyne RD, Specht L, Horning SJ, Coiffier B, Fisher RI, Hagenbeek A, Zucca E, Rosen ST, Stroobants S, Lister TA, Hoppe RT, Dreyling M, Tobinai K, Vose JM, Connors JM, Federico M, Diehl V; International Harmonization Project on Lymphoma. - Revised response criteria for malignant lymphoma. *J Clin Oncol.* 2007 Feb 10;25(5):579-86. Epub 2007 Jan 22.)
2. Juweid ME, Stroobants S, Hoekstra OS, Mottaghy FM, Dietlein M, Guermazi A, Wiseman GA, Kostakoglu L, Scheidhauer K, Buck A, Naumann R, Spaepen K, Hicks RJ, Weber WA, Reske SN, Schwaiger M, Schwartz LH, Zijlstra JM, Siegel BA, Cheson BD; Imaging Subcommittee of International Harmonization Project in Lymphoma. - Use of positron emission tomography for response assessment of lymphoma: consensus of the Imaging Subcommittee of International Harmonization Project in Lymphoma. *J Clin Oncol.* 2007 Feb 10;25(5):571-8. Epub 2007 Jan 22.

10. Lin C, Itti E, Haioun C, Petegnief Y, Luciani A, Dupuis J, Paone G, Talbot JN, Rahmouni A, Meignan M - Early 18F-FDG PET for prediction of prognosis in patients with diffuse large B-cell lymphoma: SUV-based assessment versus visual analysis. *J Nucl Med.* 2007 Oct;48(10):1626-32. Epub 2007 Sep 14.

18F-FDG PET/CT in primary non-Hodgkin's lymphoma of the sinonasal tract

Tempescul Adrian (1), Querellou Solene (2), Ianotto Jean-Christophe (1), Boisramé Sylvie (3), Valette Gerald (4), Berthou Christian (1)

1. Department of Clinical Hematology, Institute of Cancerology and Hematology, CHU Brest, Avenue Foch, 29609 Brest, France
2. Department of Nuclear Medicine, CHU Brest, avenue Foch, 29609 Brest, France
3. Department of Odontology, CHU Brest, avenue Foch, 29609 Brest, France
4. Department of ORL, CHU Brest, avenue Foch, 29609 Brest, France

Running Title: lymphoma, sinus, PET scan

Corresponding author: Dr. Tempescul Adrian
Department of Clinical Haematology
Institute of Cancerology and Hematology
University Hospital Brest
2 avenue Foch
29609 Brest cedex,
France

Phone: + 33 (0)298 22 35 04
Fax: + 33 (0)298 22 38 35
Mail: tempescul@hotmail.com

Scientific category: Clinical Observations

Word count: 978

Dear Editor, Dear Reviewer,

As requested, we tried to respond to all questions:

Question 1 and Question 2

We used for evaluation SUV max.

For the patient number one

Initial SUV max: 5.9

Residual SUV max: 3.9

Uptake reduction: 32%

For the patient number two

Initial SUV max: 4.19

Residual SUV max: 3.3

Uptake reduction: 21%

Question 3

It was proved that it is necessary an interval of 14 days between chemotherapy and PET scan to minimize the risks of false positive results due to the inflammation and increased macrophage activity (2)

The intermediate evaluation was made after two courses of chemotherapy, six days after the end of G-CSF, at day 18.

Question 4

G-CSF (Filgrastim 5µg/kg) was used starting day 8 to day 12

Question 5

We believe that is important to have a figure showing the extent of inflammation as recommended by the reviewer. Unfortunately, as requested into the “Type of papers” we can use only one figure.

We completed the References as recommended

1. Cheson BD, Pfistner B, Juweid ME, Gascoyne RD, Specht L, Horning SJ, Coiffier B, Fisher RI, Hagenbeek A, Zucca E, Rosen ST, Stroobants S, Lister TA, Hoppe RT, Dreyling M, Tobinai K, Vose JM, Connors JM, Federico M, Diehl V; International Harmonization Project on Lymphoma. - Revised response criteria for malignant lymphoma. J Clin Oncol. 2007 Feb 10;25(5):579-86. Epub 2007 Jan 22.)

2. Juweid ME, Stroobants S, Hoekstra OS, Mottaghy FM, Dietlein M, Guermazi A, Wiseman GA, Kostakoglu L, Scheidhauer K, Buck A, Naumann R, Spaepen K, Hicks RJ, Weber WA, Reske SN, Schwaiger M, Schwartz LH, Zijlstra JM, Siegel BA, Cheson BD; Imaging Subcommittee of International Harmonization Project in Lymphoma. - Use of positron emission tomography for response assessment of lymphoma: consensus of the Imaging Subcommittee of International Harmonization Project in Lymphoma. J Clin Oncol. 2007 Feb 10;25(5):571-8. Epub 2007 Jan 22.

10. Lin C, Itti E, Haioun C, Petegnief Y, Luciani A, Dupuis J, Paone G, Talbot JN, Rahmouni A, Meignan M - Early 18F-FDG PET for prediction of prognosis in patients with diffuse large

Dear Editor,

Lymphoma represents 5% of all malignant neoplasm of the head and neck. This region is the second most frequent anatomical site in which can appear the extranodal localizations of lymphoma including the upper respiratory tract, especially the sino-nasal tract. The nasal cavity and the paranasal sinuses are affected by a lymphoma on approximately 0.2 to 2% of all types of lymphoma. Into the western population the lymphoma of the sino-nasal tract has B-phenotype and DLBCL (diffuse large B cell lymphoma) histology in 95% of cases.

Standard procedures for lymphoma, before treatment and for therapeutic response evaluation include clinical examination, computed tomography and/or MRI. Many studies have demonstrated the utility of 18F-FDG PET/CT for staging and for response assessment of lymphoma. (1)

We present here the cases of two patients, with primary lymphoma of the sinonasal tract, in which the 18F-FDG PET/CT scans highlighted pathological uptake, suspecting the presence of residual lymphoma tissue. This hypothesis was refuted by a biopsy of the residual lesions.

During a period of 2 years, we identified two patients with primary lymphoma of the sino-nasal tract.

The characteristic of the patients are presented in table one.

Patient	Age	Type of lymphoma	Line of TT	Type of TT	Intermediate TEP	TEP result	Biopsy Result	Consolidation	DFS
1	69	DLBCL	1	R-VACP	after 2 cycles	POZ	NEG	CT+RxT	12 months
2	59	DLBCL	2	R-DHAOX	after 2 cycles	POZ	NEG	CT+ABSCT+RxT	24 monts

VACP- Vincristin, Doxorubicin, Cyclophosphamide, Prednisone
DHAOX – Dexamethasone, Cytarabin, Oxaliplatin

Table 1 – Characteristics of the patients treated for primary DLBCL of the sinonasal tract

The diagnosis of DLBCL lymphoma was confirmed by histopathological analysis. An initial evaluation included: clinical examination, computed tomography and 18F-FDG PET/CT scanning. One patient was in first line of treatment and one was in relapsed disease. The patients were treated using standard anthracyclin based chemotherapy associated to monoclonal antibody – Rituximab in one patient and cytarabine-platine salvage chemotherapy associated to Rituximab in one. G-CSF (Filgrastim 5µg/kg) was used starting day 8 to day 12. It was proved that it is necessary an interval of 14 days between chemotherapy and PET scan to minimize the risks of false positive results due to the inflammation and increased macrophage activity (2). An intermediate evaluation was made after two courses of chemotherapy, six days after the end of G-CSF, at day 18. The evaluation includes computed tomography and 18F-FDG PET/CT scans. We compared the results obtained by CT and 18F-FDG PET/CT. For the two patients, CT highlighted residual tissue with focal uptake of FDG on PET/CT. For the first patient the SUV max decreased from 5.9 to 3.9 (32% response) and for the second patient SUV max decreased from 4.19 to 3.3 (21% response). These results suspected residual lymphoma disease.

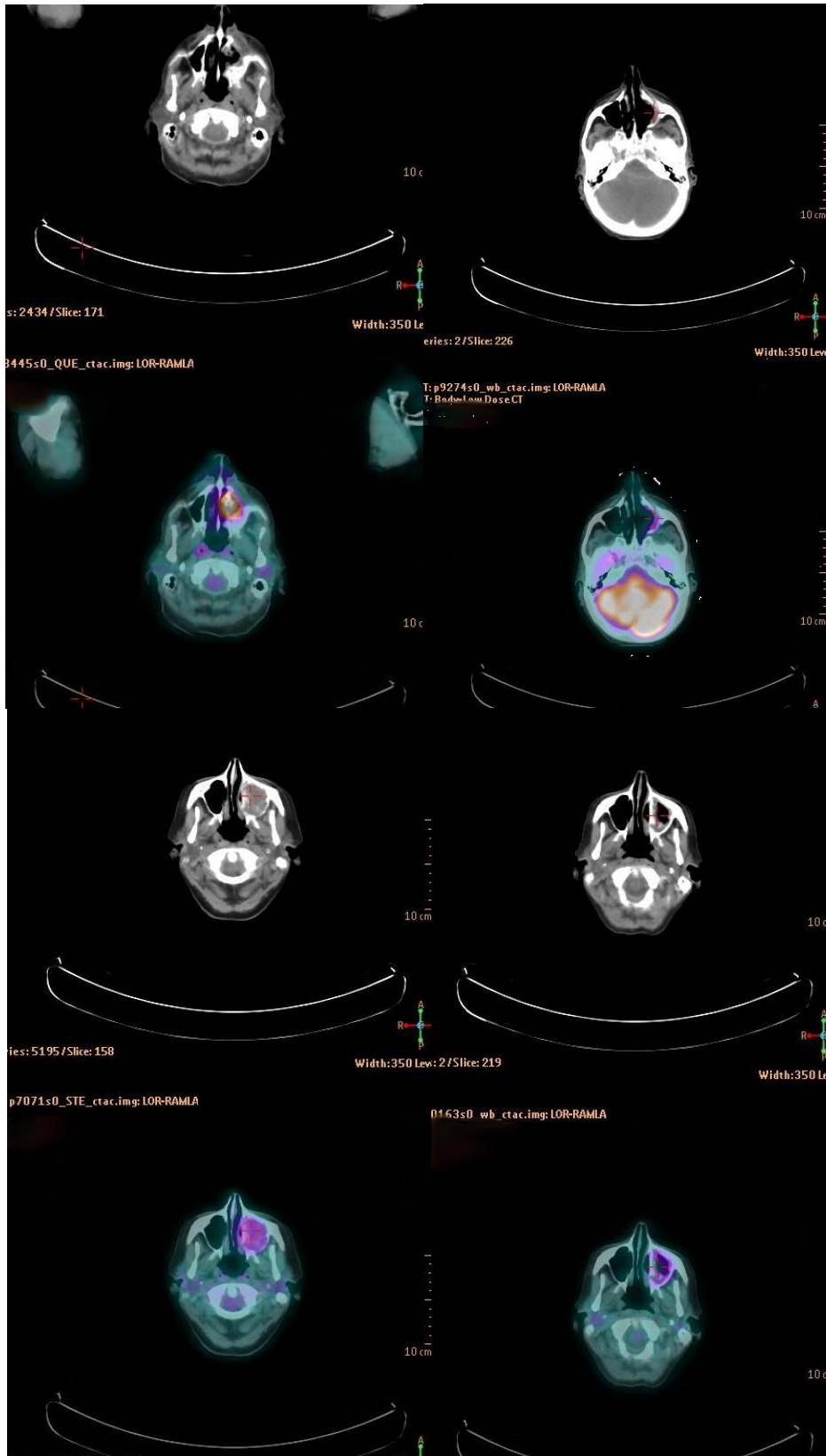


Photo 1 - ¹⁸F-FDG PET/CT of patients treated for lymphoma of the sinonasal tract (**up:** patient one – left: before treatment, right: after treatment; **down:** patient two – left: before treatment, right: after treatment)

1 We decided to confirm these results by a new biopsy. The histopathological analysis of the
2 biopsy piece was negative without any residual tumor, ensuring the complete remission. The
3 patients underwent their therapeutically program with consolidation chemotherapy
4 associated to radiotherapy.

5 The sino-nasal tract is rarely affected by primary non-Hodgkin's lymphoma (3). The
6 commonest histology is DLBCL with natural history similar to primary nodal NHL (4). The
7 standard treatment for DLBCL includes anthracyclin based chemotherapy associated to
8 monoclonal antibody – Rituximab (5). It has been proved that in case of primary lymphoma
9 of the sino-nasal tract, the combined modality treatment improves the outcome (4, 6). It has
10 also been proved that in case of incomplete remission, this type of lymphoma has an elevated
11 risk of relapse, especially on distant sites (7). It is very important to have a good evaluation
12 tool. 18F-FDG PET/CT has a growing interest for staging (8) and to evaluate the therapeutic
13 response in lymphomas (9; 10).

14 In our patients the initial evaluation by 18F-FDG PET/CT allows to establish the primary
15 sinuses localisation of the lymphoma. The intermediate PET/CT was positive suspecting a
16 residual tissue. The biopsy of the sinuses and a histopathological analysis were in favour of
17 complete remission showing only an important inflammatory reaction. The presence of this
18 inflammatory tissue gave a false positive image on PET/CT.

19 The patients are alive, in complete remission at distance from the end of treatment (12 and 24
20 months.

21 For the patients with non-Hodgkin's lymphoma affecting the sino-nasal tract, treated by
22 chemotherapy, is usual to find an important inflammatory tissue at the clinical and
23 histological examination. We believe that in case of residual lesions on 18F-FDG PET/CT or
24 on computed tomography, these examinations must be completed by a biopsy of the lesions to
25 confirm or refute the complete remission.
26
27
28
29
30
31
32
33
34
35
36
37
38
39
40
41
42
43
44
45
46
47
48
49
50
51
52
53
54
55
56
57
58
59
60
61
62
63
64
65

References

1. Cheson BD, Pfistner B, Juweid ME, Gascoyne RD, Specht L, Horning SJ, Coiffier B, Fisher RI, Hagenbeek A, Zucca E, Rosen ST, Stroobants S, Lister TA, Hoppe RT, Dreyling M, Tobinai K, Vose JM, Connors JM, Federico M, Diehl V; International Harmonization Project on Lymphoma. - Revised response criteria for malignant lymphoma. *J Clin Oncol*. 2007 Feb 10;25(5):579-86. Epub 2007 Jan 22.)
2. Juweid ME, Stroobants S, Hoekstra OS, Mottaghy FM, Dietlein M, Guermazi A, Wiseman GA, Kostakoglu L, Scheidhauer K, Buck A, Naumann R, Spaepen K, Hicks RJ, Weber WA, Reske SN, Schwaiger M, Schwartz LH, Zijlstra JM, Siegel BA, Cheson BD; Imaging Subcommittee of International Harmonization Project in Lymphoma. - Use of positron emission tomography for response assessment of lymphoma: consensus of the Imaging Subcommittee of International Harmonization Project in Lymphoma. *J Clin Oncol*. 2007 Feb 10;25(5):571-8. Epub 2007 Jan 22.
3. Cleary KR, Batsakis JG - Sinonasal lymphomas. - *Ann Otol Rhinol Laryngol*. 1994 Nov;103(11):911-4. Review
4. Laskar S, Mohindra P, Gupta S, Shet T, Muckaden MA - Non-Hodgkin lymphoma of the Waldeyer's ring: clinicopathologic and therapeutic issues. *Leuk Lymphoma*. 2008 Dec;49(12):2263-71. Review
5. Feugier P, Van Hoof A, Sebban C, Solal-Celigny P, Bouabdallah R, Fermé C, Christian B, Lepage E, Tilly H, Morschhauser F, Gaulard P, Salles G, Bosly A, Gisselbrecht C, Reyes F, Coiffier B. - Long-term results of the R-CHOP study in the treatment of elderly patients with diffuse large B-cell lymphoma: a study by the Groupe d'Etude des Lymphomes de l'Adulte. *J Clin Oncol*. 2005 Jun 20;23(18):4117-26.
6. Ezzat AA, Ibrahim EM, El Weshi AN, Khafaga YM, AlJurf M, Martin JM, Ajarim DS, Bazarbashi SN, Stuart RK, Zucca E. - Localized non-Hodgkin's lymphoma of Waldeyer's ring: clinical features, management, and prognosis of 130 adult patients. *Head Neck*. 2001 Jul;23(7):547-58
7. Frata P, Buglione M, Grisanti S, Bonetti B, Vitali E, De Stefani A, Magri E, Peveri A, Marini G, Rossi G, Magrini SM. - Localized extranodal lymphoma of the head and neck: retrospective analysis of a series of 107 patients from a single institution. *Tumori*. 2005 Nov-Dec;91(6):456-62.
8. Moog F, Bangerter M, Diederichs CG, Guhlmann A, Kotzerke J, Merkle E, Kolokythas O, Herrmann F, Reske SN. - Lymphoma: role of whole-body 2-deoxy-2-[F-18]fluoro-D-glucose (FDG) PET in nodal staging. *Radiology*. 1997 Jun;203(3):795-800
9. Mikhaeel NG, Hutchings M, Fields PA, O'Doherty MJ, Timothy AR. - FDG-PET after two to three cycles of chemotherapy predicts progression-free and overall survival in high-grade non-Hodgkin lymphoma. *Ann Oncol*. 2005 Sep;16(9):1514-23.

10. Lin C, Itti E, Haioun C, Petegnief Y, Luciani A, Dupuis J, Paone G, Talbot JN, Rahmouni A, Meignan M - Early 18F-FDG PET for prediction of prognosis in patients with diffuse large B-cell lymphoma: SUV-based assessment versus visual analysis. J Nucl Med. 2007 Oct;48(10):1626-32. Epub 2007 Sep 14.

1
2
3
4
5
6
7
8
9
10
11
12
13
14
15
16
17
18
19
20
21
22
23
24
25
26
27
28
29
30
31
32
33
34
35
36
37
38
39
40
41
42
43
44
45
46
47
48
49
50
51
52
53
54
55
56
57
58
59
60
61
62
63
64
65