



HAL
open science

Disseminated mucormycosis of an immunocompromised multiple myeloma patient: impact of biopsy of extramedullary tumours in refractory multiple myeloma

S. Gattenlöhner, C. Unzicker, S. Wörner, G. Stuhler, H. Einsele, H. K. Müller-Hermelink

► To cite this version:

S. Gattenlöhner, C. Unzicker, S. Wörner, G. Stuhler, H. Einsele, et al.. Disseminated mucormycosis of an immunocompromised multiple myeloma patient: impact of biopsy of extramedullary tumours in refractory multiple myeloma. *Annals of Hematology*, 2008, 88 (4), pp.385-387. 10.1007/s00277-008-0594-5 . hal-00486529

HAL Id: hal-00486529

<https://hal.science/hal-00486529>

Submitted on 26 May 2010

HAL is a multi-disciplinary open access archive for the deposit and dissemination of scientific research documents, whether they are published or not. The documents may come from teaching and research institutions in France or abroad, or from public or private research centers.

L'archive ouverte pluridisciplinaire **HAL**, est destinée au dépôt et à la diffusion de documents scientifiques de niveau recherche, publiés ou non, émanant des établissements d'enseignement et de recherche français ou étrangers, des laboratoires publics ou privés.

Disseminated mucormycosis of an immunocompromised multiple myeloma patient: impact of biopsy of extramedullary tumours in refractory multiple myeloma

S. Gattenlöhner · C. Unzicker · S. Wörner · G. Stuhler · H. Einsele · H. K. Müller-Hermelink

Received: 2 August 2008 / Accepted: 8 August 2008 / Published online: 29 August 2008
© The Author(s) 2008. This article is published with open access at Springerlink.com

Dear Editor,

We present the case of a 43-year-old female patient with an anaplastic IgG kappa multiple myeloma (MM) confirmed by morphological and molecular genetic analyses showing a tumorous bone marrow infiltration by highly atypical plasma cells (Fig. 1a) with strong expression of the plasma cell marker CD138 (Fig. 1b) and the kappa light chain (Fig. 1c, d reveals negative staining for lambda light chain) as well as a monoclonal rearrangement of the immunoglobulin heavy chain (IgH; Fig. 1e). In her 4-year treatment history, she underwent conventional chemotherapies as well as two autologous and one allogeneic peripheral blood stem cell transplantation from a matched related donor. Ten months after the latter, she presented with tumorous lesions in the left acetabulum, soft tissue, liver and dura mater coincidental with serum IgG kappa increase (IgG 2,400 mg/dL, free kappa light chains 1,550 mg/L), suggesting extramedullary manifestations of MM. After a third, salvage high-dose chemotherapy with autologous stem cell support, the patient received haplo-identical blood stem cell transplantation [1] in partial remission. However, due to an enlargement of the extramedullary infiltrates with increasing IgG values and an antibiotic/antimycotic therapy comprising fluconazole 400 mg/day, posaconazole 400 mg/day, voriconazole

400 mg/day, anidulafungin 100 mg/day and caspofungin 50 mg/day without substantial serological/microbiological hints at an infectious etiology, a renewed progression of MM was suspected. In a dramatically worsened terminal course with multiorgan failure and progressive cerebral clouding, the patient died under the suspicion of a progressive extramedullary relapsed anaplastic MM.

In autopsy, we found multiple nodular infiltrates in the liver (Fig. 2a, arrows) with parenchymatous scars and subacute infarctions (Fig. 2b) as well as a subtotal infarction of the right kidney and acute haemorrhagic infarctions of the lung and the cerebellum (Fig. 2d, arrow) showing fresh haemorrhages and necrosis in the cerebellar cortex (Fig. 2e). However, no residuals of the MM were detectable in the organ infiltrates neither by immunohistochemistry nor by molecular genetic analyses (Figs. 2c and f, showing polyclonal amplificates for the IgH rearrangement). By contrast, we could demonstrate an extensive vascular permeation with apparent occlusion of small to medium arteries by hyphae (Fig. 3) in all organs involved with subsequent haemorrhagic infarctions and the morphological diagnosis of mucormycosis (Fig. 3, inset) was confirmed by specific polymerase chain reaction amplification detecting *Rhizopus* species.

Extramedullary manifestations of MM occur in approximately 20% of patients and diffuse hepatic infiltration was even described in up to 50% of advanced cases [3]. However, since the differential diagnosis of extramedullary tumours in the refractory phase of MM includes other malignancies (e.g. transition to lymphoproliferative disorders [2]) as well as infectious diseases, a proper diagnostic clarification of any recurrent extramedullary tumour in MM by histological/molecular genetic analyses should be performed to improve the management and prognosis of such lesions.

S. Gattenlöhner (✉) · S. Wörner · H. K. Müller-Hermelink
Institute of Pathology, University of Würzburg,
Josef-Schneiderstr.2,
97080 Würzburg, Germany
e-mail: stefan.gattenloehner@mail.uni-wuerzburg.de

C. Unzicker · G. Stuhler · H. Einsele
Department of Internal Medicine, University of Würzburg,
Würzburg, Germany

Fig. 1 Tumourous bone marrow infiltration by highly atypical plasma cells (a) with strong expression of the plasma cell marker CD138 (b) and the kappa light chain (c) as well as negative staining for lambda light chain (d) and a monoclonal rearrangement of the immunoglobulin heavy chain (e)

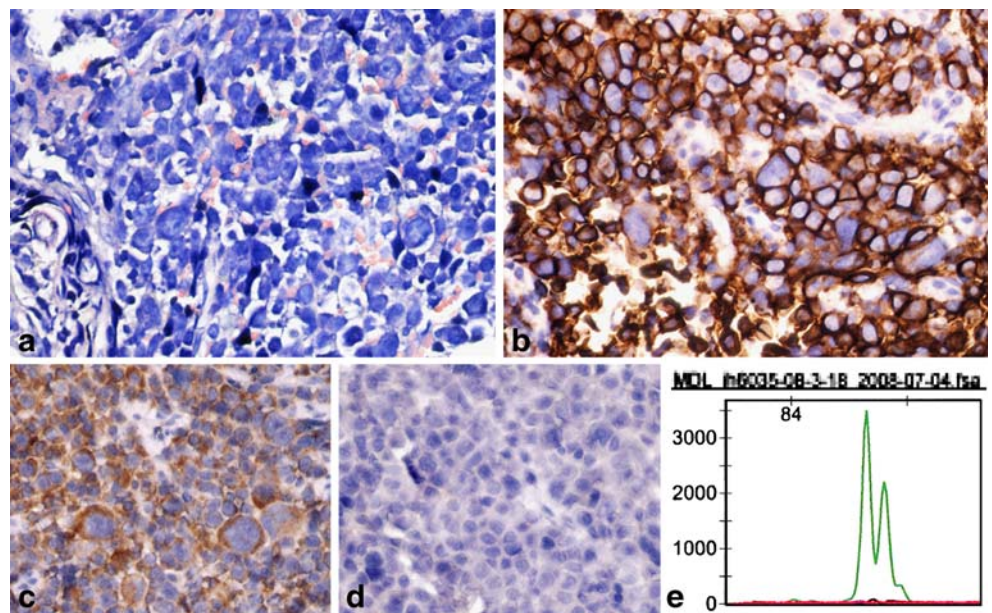
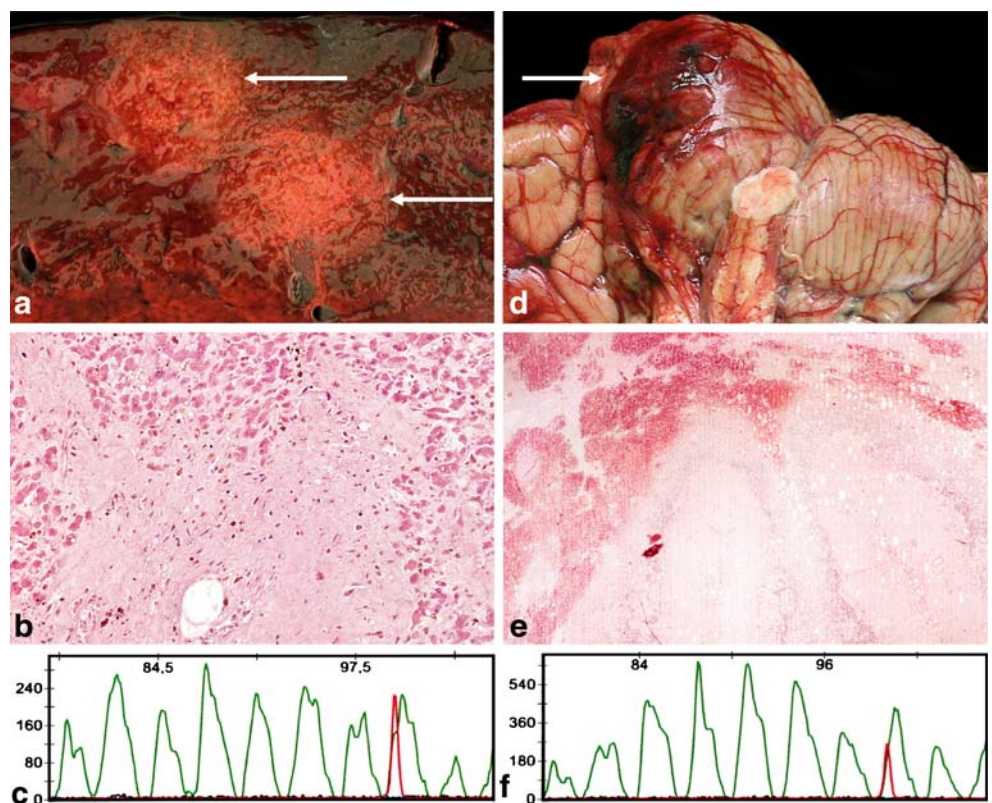


Fig. 2 Multiple nodular infiltrates in the liver (a, arrows) with parenchymatous scars and subacute infarctions (b) as well as a subtotal infarction of the right kidney and acute haemorrhagic infarctions of the lung and the cerebellum (d, arrow) showing fresh haemorrhages and necrosis in the cerebellar cortex (e). c and f Polyclonal amplificates for the IgH rearrangement



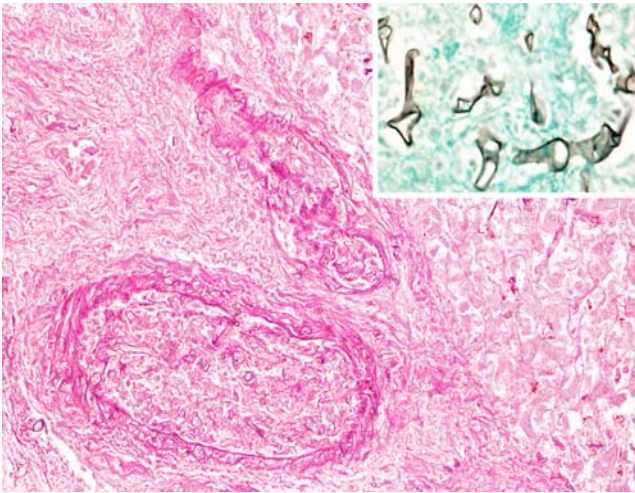


Fig. 3 Extensive vascular permeation with apparent occlusion of small to medium arteries by hyphae in all organs involved with subsequent haemorrhagic infarctions and the morphological diagnosis of mucormycosis (*inset*)

Open Access This article is distributed under the terms of the Creative Commons Attribution Noncommercial License which permits any noncommercial use, distribution, and reproduction in any medium, provided the original author(s) and source are credited.

References

1. Bethge WA, Faul C, Bornhauser M, Stuhler G, Beelen DW, Lang P et al (2008) Haploidentical allogeneic hematopoietic cell transplantation in adults using CD3/CD19 depletion and reduced intensity conditioning: an update. *Blood Cells Mol Diseases* 40:13–19 doi:10.1016/j.bcmd.2007.07.001
2. Miwa A (2007) How to diagnose a patient precisely as a myeloma patient?—Lots of problems during diagnostic process. *Nippon Rinsho* 65:2268–2279
3. Perez Gil MA, Ruiz Recuento J, Relanzon Molinero S, Martinez Yunta JA (2006) Focal liver lesions in multiple myeloma: echography, computed tomography, and magnetic resonance findings. *Radiologia* 48:251–254