



HAL
open science

Tri-lineage disease involving sideroblastic anaemia, multiple myeloma and B-cell non-Hodgkin's lymphoma in the same patient

Jean-Christophe Ianotto, Adrian Tempescul, Jean-Richard Eveillard,
Véronique Marion, Isabelle Quintin-Roué, Christian C. Berthou

► **To cite this version:**

Jean-Christophe Ianotto, Adrian Tempescul, Jean-Richard Eveillard, Véronique Marion, Isabelle Quintin-Roué, et al.. Tri-lineage disease involving sideroblastic anaemia, multiple myeloma and B-cell non-Hodgkin's lymphoma in the same patient. *Annals of Hematology*, 2008, 88 (3), pp.273-274. 10.1007/s00277-008-0586-5 . hal-00486527

HAL Id: hal-00486527

<https://hal.science/hal-00486527>

Submitted on 26 May 2010

HAL is a multi-disciplinary open access archive for the deposit and dissemination of scientific research documents, whether they are published or not. The documents may come from teaching and research institutions in France or abroad, or from public or private research centers.

L'archive ouverte pluridisciplinaire **HAL**, est destinée au dépôt et à la diffusion de documents scientifiques de niveau recherche, publiés ou non, émanant des établissements d'enseignement et de recherche français ou étrangers, des laboratoires publics ou privés.

Tri-lineage disease involving sideroblastic anaemia, multiple myeloma and B-cell non-Hodgkin's lymphoma in the same patient

Jean-Christophe Ianotto · Adrian Tempescul ·
Jean-Richard Eveillard · Véronique Marion ·
Isabelle Quintin-Roué · Christian Berthou

Received: 30 May 2008 / Accepted: 29 July 2008 / Published online: 22 August 2008
© Springer-Verlag 2008

Dear Editor,

We reported an exceptional case of a tri-lineage disease arising in a 67-year-old man. The patient was followed for IgG lambda monoclonal gammopathy of undetermined signification (MGUS) for 10 years. He developed painful symptomatic multiple myeloma (14% marrow mature plasmocytes IgG lambda of 28 g/l, osteolytic lesions of humerus, skull and femur) and his ISS score was 2 (β 2-microglobuline at 4.5 mg/l and albumin at 40 g/l). Conventional karyotype showed loss of chromosome Y, and *in-situ* fluorescence hybridisation revealed del(13q). Interestingly, the same marrow aspirate revealed 5% blasts and 31% erythroblasts despite the haemoglobin level being 9.5 g/dl. Refractory anaemia with ringed sideroblasts was identified by Perls' staining, which showed 53% ringed sideroblasts (Fig. 1).

J.-C. Ianotto (✉) · A. Tempescul · J.-R. Eveillard · C. Berthou
Institut de cancéro-hématologie, Département d'Hématologie,
Hôpital Morvan,
CHU Brest, France
e-mail: jcianotto@hotmail.com

V. Marion
Laboratoire d'hématologie, Hôpital Morvan,
CHU Brest, France

I. Quintin-Roué
Laboratoire d'anatomopathologie, Hôpital Morvan,
CHU Brest, France

The patient was treated using the VAD (Vincristin, adriamycin and dexamethasone) standard protocol and EPO. After three courses of chemotherapy, the response was evaluated to be at 20% only on the heavy chain compound in the plasma. Before the fourth course of treatment, he developed a dyspnoea. Pulmonary computed tomography showed four tumours ranging in size from 2 to 7 cm. A transparietal biopsy was performed, and immunohistochemistry revealed the presence of CD5-/CD10-/CD20+ diffuse large B-cell non-Hodgkin's lymphoma (All B-cells appeared positive for lambda light chain (Fig. 2). Unfortunately, the patient died 5 days after the biopsy.

This is the first case reporting the concomitant appearance of refractory anaemia with ringed sideroblasts, multiple myeloma and B-cell non-Hodgkin's lymphoma in the same patient. Furthermore, the lambda light chain was identified in the plasmocytic and lymphoid tissues. Association of the first two diseases has been published before [1–4]. However, only four concomitant cases with a predominant IgA isotype have been reported. Secondary cases of ringed sideroblasts following treatment of myeloma, with odd-ratio of 100, have been described as well [5]. The association between a non-Hodgkin's lymphoma (T type) and multiple myeloma has been reported only in one case [6].

Our brief report confirmed that a tri-lineage haematological disease may appear in the same patient. We suggest that the multiple myeloma and DLCLB may originate from the same clone because both presented the same light chain.

Fig. 1 Cytological aspect of bone marrow aspirates with mature plasmacytes and erythroblasts. Perls coloration confirmed the presence of ringed sideroblasts

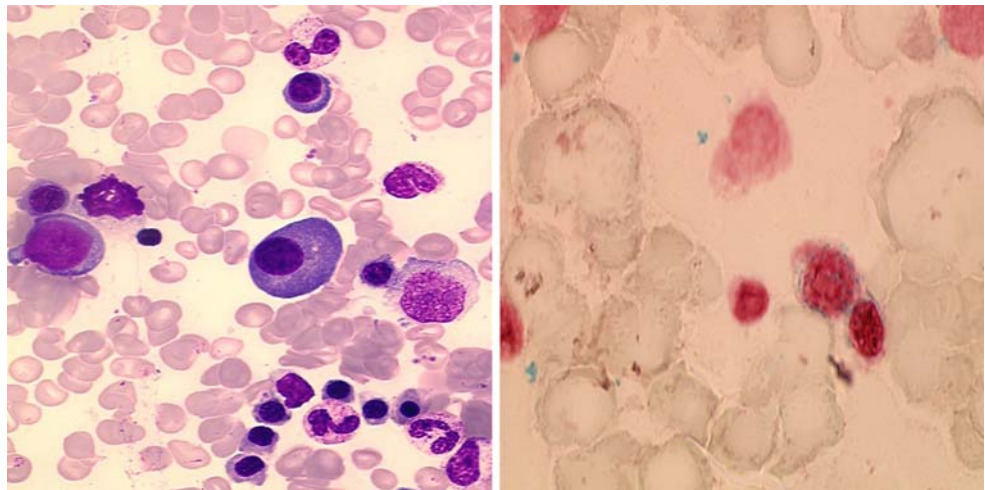
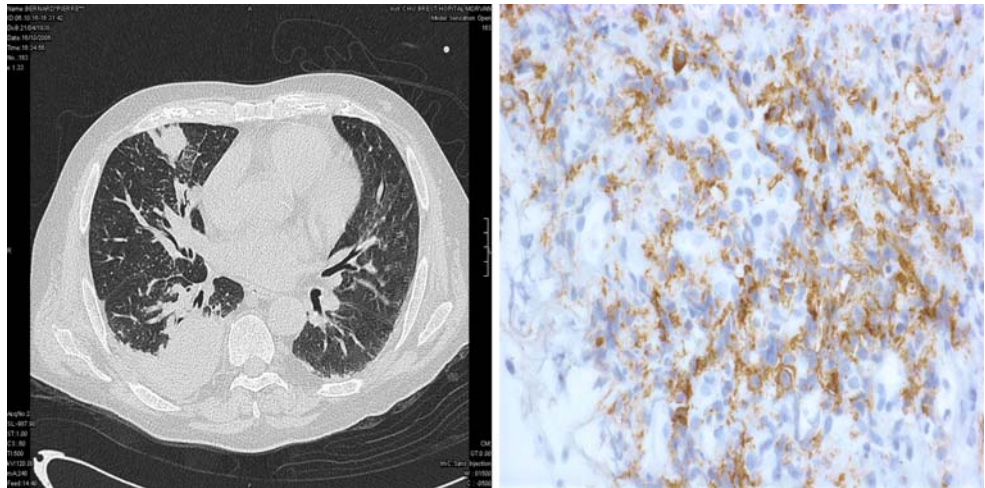


Fig. 2 A computed tomography scan showed two pulmonary tumours. Anti-CD20 staining on transparietal biopsy tissue confirmed the B-cell lineage with identification of diffuse large B-cell lymphoma



The cumulative haematological diseases were fatal to the patient.

References

1. Economopoulos T, Pappa V, Panani A et al (1991) Myelopathies during the course of multiple myeloma. *Haematologica* 76:289–292
2. Itoh K, Igarashi T, Wakita H et al (1992) Sideroblastic anemia associated with multiple myeloma in Turner's syndrome. *Int Med* 31:483–485
3. Sato S, Nagai T, Nishikiori Y et al (1992) Coexistence of myeloma and primary myelodysplastic syndrome (MDS). *Rinsho Ketsueki* 33:58–62
4. Shibata K, Shimamoto Y, Nakazato S et al (1997) Refractory anaemia with ringed sideroblasts concurrent with multiple myeloma—a brief review of the recent literature. *Haematologia (Budap)* 28:199–205
5. Gonzalez F, Trujillo JM, Alexanian R (1977) Acute leukaemia in multiple myeloma. *Ann Intern Med* 86:440–443
6. Takami A, Mizunoya S (2000) Orbital T-cell lymphoma in a multiple myeloma patient. *Am J Ophthalmol* 130:372–373