



**HAL**  
open science

## Fatal chylous ascites, pericarditis and extensive venous thrombosis, due to an aggressive T cell non-Hodgkin lymphoma

Elizabeth Ioannidou-Papagiannaki, Michael D. Diamantidis, Ioannis Livanis, Philippos Klonizakis, Styliani Haralambidou-Vranitsa, Efthymia Vlachaki, Ioannis Venizelos, Ioannis Klonizakis

### ► To cite this version:

Elizabeth Ioannidou-Papagiannaki, Michael D. Diamantidis, Ioannis Livanis, Philippos Klonizakis, Styliani Haralambidou-Vranitsa, et al.. Fatal chylous ascites, pericarditis and extensive venous thrombosis, due to an aggressive T cell non-Hodgkin lymphoma. *Annals of Hematology*, 2008, 88 (4), pp.371-373. 10.1007/s00277-008-0570-0 . hal-00486523

**HAL Id: hal-00486523**

**<https://hal.science/hal-00486523>**

Submitted on 26 May 2010

**HAL** is a multi-disciplinary open access archive for the deposit and dissemination of scientific research documents, whether they are published or not. The documents may come from teaching and research institutions in France or abroad, or from public or private research centers.

L'archive ouverte pluridisciplinaire **HAL**, est destinée au dépôt et à la diffusion de documents scientifiques de niveau recherche, publiés ou non, émanant des établissements d'enseignement et de recherche français ou étrangers, des laboratoires publics ou privés.

## Fatal chylous ascites, pericarditis and extensive venous thrombosis, due to an aggressive T cell non-Hodgkin lymphoma

Elizabeth Ioannidou-Papagiannaki ·  
Michael D. Diamantidis · Ioannis Livanis ·  
Philippos Klonizakis ·  
Styliani Haralambidou-Vranitsa · Eftymia Vlachaki ·  
Ioannis Venizelos · Ioannis Klonizakis

Received: 9 July 2008 / Accepted: 18 July 2008 / Published online: 5 August 2008  
© Springer-Verlag 2008

Dear Editor,

Chylous ascites or chyloperitoneum is the extravasation of milky peritoneal fluid rich in triglycerides in the abdominal cavity, because of lymphatic obstruction or trauma. Cirrhosis, malignancies and infectious agents are frequent etiologies, whereas congenital, inflammatory, post-operative and traumatic causes have been described [1]. The incidence of chylous ascites is between 1 in 50,000 and 1 in 187,000 hospital admissions. Neoplasms are mainly responsible for chyloperitoneum, with lymphomas predominating among malignant causes in young patients [2]. We report a case of a young patient presenting with chylous ascites, chylothorax, pericarditis and venous thrombosis in several anatomic regions, due to an aggressive T cell non-Hodgkin lymphoma (T-NHL). To the best of our knowledge, this is the first case of such co-existing pathologic features, revealing a T-NHL.

The need for effective treatment is essential in such medical incidents, especially when young patients suffer from aggressive neoplasms. However, rarity of such cases and lack of guidelines concerning therapeutic options

impede the task of haematologists. Therefore, reporting lymphomas combined with chyloperitoneum facilitates the choice of appropriate treatment and the outcome comparison between similar incidents.

A 38-year-old man with 3-month recurrent effusive right pleuritis, after being initially treated for presumed tuberculosis, was referred to our centre. The patient had increasing abdominal distention and shortness of breath. Physical examination revealed ascites, left axillary lymphadenopathy and upper limb oedema. Lymph node biopsy was diagnostic of peripheral T-NHL, unspecified. There was complete effacement of the nodal architecture, along with infiltration by neoplastic, lymphoid cells with abundant mitotic figures. They were medium-sized or enlarged with slightly eosinophilic cytoplasm and irregular-shaped nuclei. Immunohistochemically, tumour cells were strongly positive for CD5, mildly positive for CD3 and negative for CD20, CD79a, CD30, CD56, CD23 and cyclin D1 (Fig. 1). Peripheral, unspecified T-NHLs derive from post-thymic T cells at various differentiative stages. Computed tomography (CT) scan revealed ascites, ambilateral pleuritic fluid causing mediastinal compression, pericarditis and excessive left axillary, mediastinal, mesenteric and retroperitoneal lymphadenopathy (Fig. 2). Enlarged lymph nodes surrounding the thymus were traced. The presence of pericardial fluid was confirmed by an echocardiogram. Paracentesis elicited chylous-effusive pleuritic fluid and creamy white ascetic fluid with elevated triglycerides (1,212 mg/dl), low protein (2.6 g/dl) and cell count (550 cells per decilitre) with lymphocytic predominance.

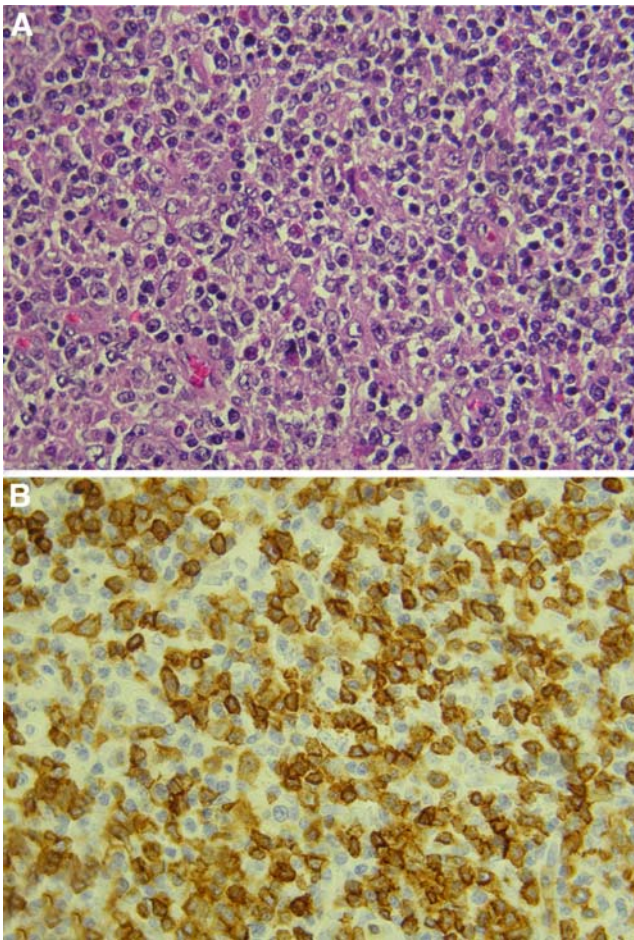
Moreover, thrombosis was detected in the left brachiocephalic, subclavian and internal jugular veins, as a result

---

E. Ioannidou-Papagiannaki · M. D. Diamantidis (✉) · I. Livanis ·  
P. Klonizakis · S. Haralambidou-Vranitsa · E. Vlachaki ·  
I. Klonizakis

Department of Hematology, Second Department of Internal  
Medicine, Aristotle University of Thessaloniki,  
Hippokraton General Hospital,  
Konstantinoupoleos St 49,  
546 42 Thessaloniki, Greece  
e-mail: diamantidis79@yahoo.gr

I. Venizelos  
Department of Pathology, Hippokraton General Hospital,  
Thessaloniki, Greece

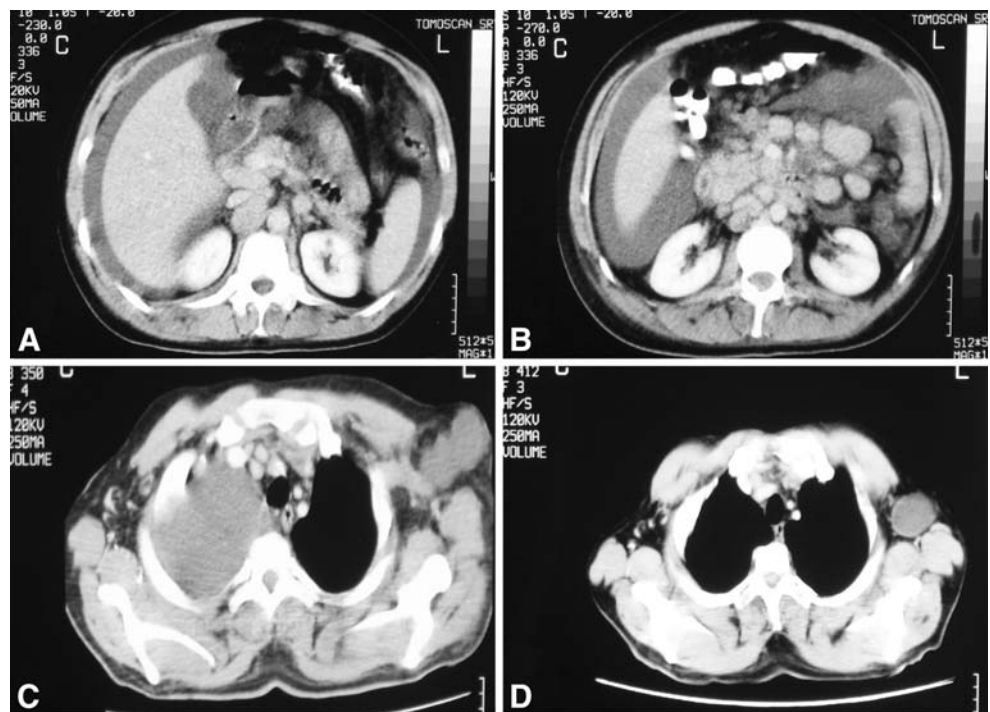


**Fig. 1** **a** Large and medium-sized lymphoma cells (haematoxylin and eosin stain,  $\times 400$ ). **b** Positive immunohistochemical stain for CD3

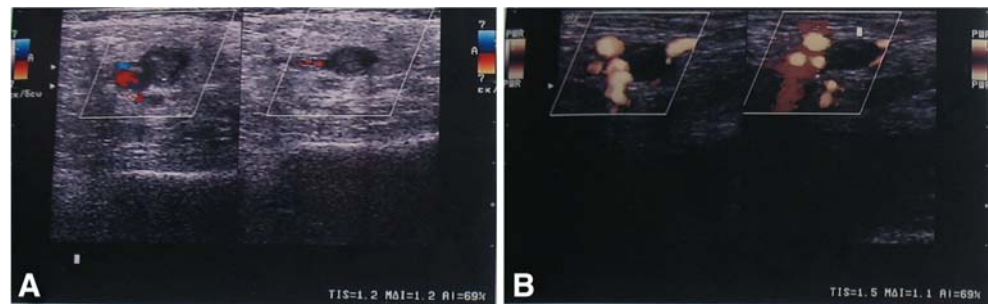
of the CT scan. Simultaneously, after inflammation of the right thigh skin was traced, color-flow Doppler ultrasonography revealed extensive thrombosis of the right femoral and popliteal veins (Fig. 3). D-dimers (382.6 ng/ml) and fibrinogen levels (791.6 mg/dl) were elevated. Protein S, protein C, antithrombin III and homocysteine levels were within normal range. No anti-phospholipoid antibodies or factor V Leiden mutation was present. Therefore, severe thrombosis was attributed to aggressive T-NHL.

The patient underwent six cycles of bi-weekly combination chemotherapy with cyclophosphamide ( $1,200 \text{ mg/m}^2$ ), doxorubicin ( $60 \text{ mg/m}^2$ ), vincristine (2 mg) and prednisone (500 mg) plus etoposide ( $600 \text{ mg/m}^2$ ; CHOEP) regimen. Treatment duration was 80 days. Granulocyte colony-stimulating factor ( $300 \mu\text{g}$  subcutaneously [s.c.]/week) and pegfilgrastim were also applied. Extensive thrombosis was successfully treated by fondaparinux sodium ( $7.5 \text{ mg s.c./day}$ ). Ascites receded for 5 months, before a new relapse. Albumin and diuretics were unsuccessfully used to treat recurrent chyloperitoneum. After another CHOEP cycle, therapeutic paracentesis was still necessary to overcome ascetic symptoms. Two cycles of dexamethasone ( $40 \text{ mg/m}^2$ ), mesna ( $400 \text{ mg/m}^2$ ), ifosfamide ( $1,500 \text{ mg/m}^2$ ), cisplatin ( $40 \text{ mg/m}^2$ ) and etoposide ( $180 \text{ mg/m}^2$ ) regimen at highest dosage were then applied, without success. Alemtuzumab (Campath<sup>®</sup>; 30 mg, three times weekly, for 6 weeks) was the final therapeutic approach [3]. Eighteen months after diagnosis, the patient died, due to thrombopenia, resulting in fatal gastrorrhagia.

**Fig. 2** CT scan: **a, b** excessive ascites combined with mesenteric and retroperitoneal lymphadenopathy. **c** Right effusive pleuritis along with left axillary lymphadenopathy before treatment. **d** Reduction to amount of pleuritic fluid and to size of left axillary lymph nodes after chemotherapy



**Fig. 3** Color-flow Doppler ultrasonography revealing extensive thrombosis of right popliteal (a) and femoral (b) veins



Despite rarity of lymphoma-caused chyloperitoneum, some cases have been reported. A case of Hodgkin's disease presenting with chylous ascites and cavernous transformation of the portal vein has been described [4]. Moreover, symptomatic enterocele as an unusual presentation of chylous ascites and follicular lymphoma has been reported recently [5]. There is a lack of data regarding appropriate treatment of T-NHLs, which develop the complication of chylous ascites. The prognosis is dismal. The majority of patients die within a few months, regardless of chemotherapy [1].

Despite fatal outcome, our patient survived 18 months, which is much longer than the expected 3 to 6 months, and became free of ascites for 5 months. This rare case shows the efficacy of CHOEP regimen, even in aggressive NHLs of young patients, which present with systemic complications and are characterized by bad prognosis. Furthermore, our patient received full average relative chemotherapy dose intensity (ARDI), as the administered dosage of all regimens was exactly equivalent to the dosage planned by our initial protocol. Thus, ARDI in our patient was 100%, which was an important goal achieved, regardless of the patient's death. When ARDI is less than 90%, NHL patients are at risk of reduced survival [6]. In conclusion, more clinical trials testing new chemotherapy combinations and

novel drugs are needed for increasing treatment options in aggressive T-NHLs of young patients. The latter will lead to better dosing schemes and therapeutic results.

## References

1. Almakdisi T, Massoud S, Makdisi G (2005) Lymphomas and chylous ascites: review of the literature. *Oncologist* 10:632–635
2. Bachmeyer C, Henni MA, Blanc AS, Langman B, Kazerouni F, Cadranet JF (2004) Chylous ascites revealing a non-Hodgkin lymphoma. *Presse Med* 33:167–169
3. Gallamini A, Zaja F, Patti C, Billio A, Specchia MR, Tucci A, Levis A, Manna A, Secondo V, Rigacci L, Pinto A, Iannitto E, Zoli V, Torchio P, Pileri S, Tarella C (2007) Alemtuzumab (Campath-1H) and CHOP chemotherapy as first-line treatment of peripheral T-cell lymphoma: results of a GITIL (Gruppo Italiano Terapie Innovative nei Linfomi) prospective multicenter trial. *Blood* 110:2316–2323
4. Gonen C, Akarsu M, Solmaz D, Yilmaz T, Secil M, Obuz F, Kargi A (2007) Hodgkin's disease presenting with chylous ascites and cavernous transformation of the portal vein. *Dig Dis Sci* 52:3511–3514
5. Ward RM, Rardin CR (2008) Symptomatic enterocele. An unusual presentation of chylous ascites and lymphoma. *Obstet Gynecol* 111:553–555
6. Pettengell R, Schwenkglens M, Bosly A (2008) Association of reduced relative dose intensity and survival in lymphoma patients receiving CHOP-21 chemotherapy. *Ann Hematol* 87:429–430