



HAL
open science

Successful treatment of spp. encephalitis occurring under Caspofungin treatment after allogeneic stem cell transplantation

G. Behre, M. Christopeit, T. Weber

► **To cite this version:**

G. Behre, M. Christopeit, T. Weber. Successful treatment of spp. encephalitis occurring under Caspofungin treatment after allogeneic stem cell transplantation. *Annals of Hematology*, 2008, 88 (1), pp.93-94. 10.1007/s00277-008-0551-3 . hal-00486518

HAL Id: hal-00486518

<https://hal.science/hal-00486518>

Submitted on 26 May 2010

HAL is a multi-disciplinary open access archive for the deposit and dissemination of scientific research documents, whether they are published or not. The documents may come from teaching and research institutions in France or abroad, or from public or private research centers.

L'archive ouverte pluridisciplinaire **HAL**, est destinée au dépôt et à la diffusion de documents scientifiques de niveau recherche, publiés ou non, émanant des établissements d'enseignement et de recherche français ou étrangers, des laboratoires publics ou privés.

Successful treatment of *Candida* spp. encephalitis occurring under Caspofungin treatment after allogeneic stem cell transplantation

G. Behre · M. Christopeit · T. Weber

Received: 6 May 2008 / Accepted: 24 June 2008 / Published online: 31 July 2008
© Springer-Verlag 2008

Dear Editor,

Caspofungin belongs to standard drugs for empirical antifungal therapy (A1 recommendation) [1]. Breakthrough fungal infections are rare complications under treatment of neutropenic fever with Caspofungin [2]. However, emergence of candidiasis under treatment with Caspofungin was reported in poorly penetrated organs [3]. Drug concentrations of Caspofungin are sub-optimal in brain tissue [4]. Cerebral fungal infections are rare but life-threatening complications after allogeneic stem cell transplantation. Early diagnosis and critical monitoring of response to the chosen antifungal agents is critical for successful treatment. We report about the diagnosis and treatment of a 69-year-old female patient who underwent allogeneic peripheral blood stem cell transplant from a related donor against AML M2 developed out of MDS. Conditioning comprised of TBI 2Gy, Fludarabin 120 mg/m², ATG 40 mg/kg, Cyclophosphamid 120 mg/kg. Immunosuppression was accomplished by Ciclosporin A and Mycophenolat Mofetil. The patient did not completely engraft. Six months after transplantation, the patient developed pneumonia. As she did not improve under treatment with piperacillin or com-bactam and teicoplanin, we added caspofungin after 72 h. Hereunder, she improved tremendously. After 4 weeks, she developed ataxia and dysarthria. The cranial magnetic resonance imaging (MRI) showed two lesions most likely to be of infectious origin in the left parietal lobe and in the cerebellum (Fig. 1). *Candida* polymerase chain reaction of the liquor was

positive. A second liquor puncture confirmed this result. Treatment was initiated with liposomal Amphotericin B 3 mg/d/kg intravenous and Voriconazol 200 mg twice a day per os. Within 2 weeks, all clinical symptoms resolved and within 4 weeks, the control MRI showed remission. Treatment with Voriconazol was continued for 6 weeks.

In part, *Candida* breakthrough infections may be due to the changing scope of strains [5]. However, to our knowledge, only a few cases of *Candida* breakthrough infections under Caspofungin are reported [3–9]. Krogh-Madson et al. isolated Caspofungin resistant *C. glabrata* from a critically ill liver transplant patient [6]. In another case *C. parapsilosis* infection emerged under co-administration of phenytoin maybe leading to decreased Caspofungin concentrations [6]. Mougald et al. showed by molecular-genetic studies that one initial susceptible *Candida glabrata* strain acquired resistance to Caspofungin under therapy [9]. As penetration of caspofungin in

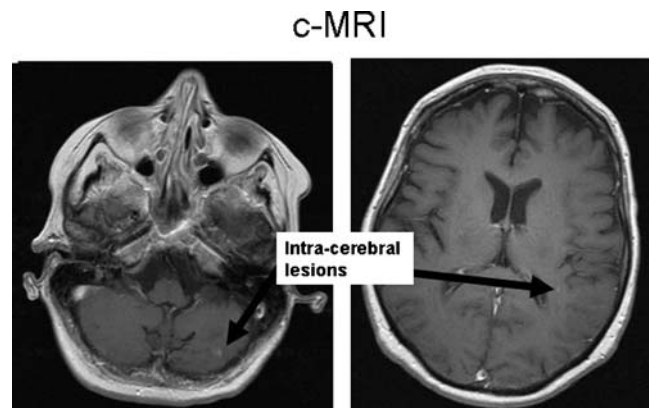


Fig. 1 The cranial magnetic resonance imaging (MRI) showed two lesions most likely to be of infectious origin in the left parietal lobe and in the cerebellum

G. Behre and T. Weber contributed equally.

G. Behre (✉) · M. Christopeit · T. Weber
Department of Oncology and Hematology,
University Hospital Halle,
Halle, Germany
e-mail: GerdBehre@aol.com

brain tissue is low, we think *Candida* could resist treatment in this tissue in our case. This report indicates that cerebral fungal infections can occur during Caspofungin therapy and should be considered as differential diagnosis.

References

1. Sobel JD, Revankar SG (2007) *N Engl J Med* 356:2525–2526 doi:[10.1056/NEJMe078078](https://doi.org/10.1056/NEJMe078078)
2. Walsh TJ, Tepller H, Donowitz GR et al (2004) *N Engl J Med* 351:1391–1402 doi:[10.1056/NEJMoa040446](https://doi.org/10.1056/NEJMoa040446)
3. Pelletier R, Alarie I, Lagacé R, Walsh TJ et al (2005) *Med Mycol* 43:559–564 doi:[10.1080/13693780500220415](https://doi.org/10.1080/13693780500220415)
4. Stone JA, Xu X, Winchell GA et al (2004) *Antimicrob Agents Chemother* 48:815–823 doi:[10.1128/AAC.48.3.815-823.2004](https://doi.org/10.1128/AAC.48.3.815-823.2004)
5. Nguyen MH, Peacock JE Jr, Morris AJ et al (1996) *Am J Med* 100:617–623 doi:[10.1016/S0002-9343\(95\)00010-0](https://doi.org/10.1016/S0002-9343(95)00010-0)
6. Cheung C, Guo Y, Gialanella P et al (2006) *Infection* 34:345–348 doi:[10.1007/s15010-006-5613-7](https://doi.org/10.1007/s15010-006-5613-7)
7. Krogh-Madsen M, Arendrup MC, Heslet L et al (2006) *Clin Infect Dis* 42:938–944 doi:[10.1086/500939](https://doi.org/10.1086/500939)
8. Wagner D, Sander A, Bertz H et al (2005) *Infection* 33:397–400 doi:[10.1007/s15010-005-5082-4](https://doi.org/10.1007/s15010-005-5082-4)
9. Moudgal V, Little T, Boikov D et al (2005) *Antimicrob Agents Chemother* 49:767–769 doi:[10.1128/AAC.49.2.767-769.2005](https://doi.org/10.1128/AAC.49.2.767-769.2005)