



HAL
open science

Comparison of extracellular matrix in skin and saphenous veins of from patients with varicose veins: does the skin reflect venous matrix changes?

Patricia Sansilvestri-Morel, Florence Fioretti, Alain Rupin, Karim Senni, Jean-Noel Fabiani, Gaston Godeau, Tony J. Verbeuren

► To cite this version:

Patricia Sansilvestri-Morel, Florence Fioretti, Alain Rupin, Karim Senni, Jean-Noel Fabiani, et al.. Comparison of extracellular matrix in skin and saphenous veins of from patients with varicose veins: does the skin reflect venous matrix changes?. *Clinical Science*, 2006, 112 (4), pp.229-239. 10.1042/CS20060170 . hal-00479332

HAL Id: hal-00479332

<https://hal.science/hal-00479332>

Submitted on 30 Apr 2010

HAL is a multi-disciplinary open access archive for the deposit and dissemination of scientific research documents, whether they are published or not. The documents may come from teaching and research institutions in France or abroad, or from public or private research centers.

L'archive ouverte pluridisciplinaire **HAL**, est destinée au dépôt et à la diffusion de documents scientifiques de niveau recherche, publiés ou non, émanant des établissements d'enseignement et de recherche français ou étrangers, des laboratoires publics ou privés.

**COMPARISON OF EXTRACELLULAR MATRIX IN SKIN AND
SAPHENOUS VEINS OF VARICOSE VEIN PATIENTS:
DOES THE SKIN REFLECT VENOUS MATRIX CHANGES ?**

Patricia SANSILVESTRI-MOREL, Florence FIORETTI*, Alain RUPIN, Karim SENNI*, Jean Noël FABIANI[§], Gaston GODEAU*[#] and Tony J. VERBEUREN[#].

Division of Angiology, SERVIER Research Institute, SURESNES, FRANCE.

***Laboratory of Physiopathology of non mineralised tissues, Faculte de Chirurgie Dentaire, Université Paris Descartes, MONTROUGE, FRANCE.**

[§] Department of Cardio Vascular Surgery, European Hospital Georges Pompidou, 20 rue Leblanc, PARIS 75015, FRANCE.

Authors for correspondance :

- Dr. Tony J. VERBEUREN:

Division of Angiology, SERVIER Research Institute

11, rue des Moulineaux, SURESNES 92150, FRANCE.

Tel: 33 1 55 72 25 18 Fax: 33 1 55 72 24 30

E-mail: tony.verbeuren@fr.netgrs.com

- Prof. Gaston GODEAU

Laboratory of physiopathology of non mineralised tissues, Faculte de Chirurgie Dentaire , Université Paris Descartes

1, rue Maurice Arnoux, MONTROUGE 92160, FRANCE.

Tel : 33 1 58 07 67 89 Fax : 33 1 58 07 67 87

E-mail : godeau_g@yahoo.fr

Word count: 5646

ABSTRACT

Varicose vein disease is a frequently occurring pathology with multifactorial causes and with a genetic component. An intense remodelling of the varicose vein wall has been described and could be at the origin of its weakness and altered elasticity. We previously described a dysregulation of collagen synthesis in cultured smooth muscle cells from the saphenous veins and in dermal fibroblasts from the skin of patients with varicose veins suggesting a systemic defect in their connective tissue. The present work describes comparative morphological and immunohistochemical data of both the skin and the saphenous veins of 8 control (undergoing coronary bypass surgery) and 8 varicose vein patients.

Histological staining of glycoproteins, the elastic fiber network and of collagen bundles shows that the remodelling and the fragmentation of elastic fibers observed in varicose veins are also present in the skin of the patients. As compared to control subjects, we noted in both the veins and the skin of varicose vein patients (1) an increase in the elastic network, as quantified by image analysis ; (2) an accumulation of collagen type I, fibrillin-1 and laminin and (3) an overproduction of the matrix metalloproteinase (MMP) -1,-2 and -3, analysed by immunohistochemistry, but normal levels of other MMPs (MMP-7 and -9) and their inhibitors (TIMP-1, -2, -3).

An imbalance of the extracellular matrix production/degradation was thus observed in veins as well as in the skin of the varicose vein patients and taken together, these findings show that a remodelling is present in different organs, confirming systemic alterations of connective tissues.

INTRODUCTION

Among the various connective tissues, the skin has been considered as a "window" for the evaluation of abnormalities that occur in acquired or inherited disease states [1]. Several authors have shown that in hereditary pathologies such as pseudoxanthoma elasticum, Ehlers-Danlos syndrome, Williams-Beuren syndrome, Marfan syndrome, as well as in acquired diseases such as anetoderma, the extracellular matrix alterations which affect the skin are also present in large blood vessels such as the aorta [2-5]. Furthermore, a correlation between the amount of elastic fibers from the skin and the temporal artery was detected during aging in man. Thus, analysis of skin biopsies may represent a valuable tool for predicting abnormalities of extracellular matrix proteins in the arterial wall [2,6].

In arterial diseases such as atherosclerosis, stenosis, aneurysms or hypertension, extracellular matrix remodelling of the vascular wall is observed. An accumulation of proteoglycans or collagens is demonstrated in early intimal thickenings that characterize developing atherosclerotic lesions [7]. The degradation of extracellular matrix by matrix metalloproteinases (MMPs) is involved in plaque instability; and in coronary arteries, the embolus can lead to myocardial infarction [8]. Saphenous vein (SV) bypass grafting is an important treatment for coronary artery disease. In comparison to arterial grafts, venous grafts are more prone to failure caused by accelerated remodelling leading to atherosclerosis and occlusion [9].

A typical disease of the human saphenous veins is "varicose vein disease". Varicose veins are a common pathology affecting 30-40% of adults in the European population [10].

Epidemiological studies point toward an involvement of hereditary factors for the transmission of this pathology with a high risk of developing varicose veins in children of patients affected by venous insufficiency [10-12]. Histological studies of varicose veins demonstrate the disorganization of the venous wall including varying degrees of intimal thickening, infiltration of fibrous tissue in the muscular layers, accumulation of collagen and fragmentation of elastic fibers [13,14]. In patients with varicose veins, skin abnormalities have been detected such as abnormal skin collagen or dermal tissue thinner than that of healthy subjects of the same range of age [15]. We previously showed that the synthesis of collagen type I and III is dysregulated in dermal fibroblasts derived from patients with varicose veins, and this dysregulation is comparable to that observed in smooth muscle cells derived from varicose veins [16]. Taken together, these findings suggest that a systemic biochemical defect of the extracellular matrix, affecting the entire body structure and not only

the veins, is present early in the patients and they suggest that venous disease is the expression of a systemic pathology of the connective tissue with a genetic cause. The undetected presence of venous disease could also have consequences for patients undergoing coronary bypass surgery for which the saphenous vein is still frequently used as a graft organ. To study the possible correlation between skin and saphenous vein matrix alterations in varicose vein patients, we have investigated qualitative and quantitative modifications of extracellular matrix components such as collagens, elastic fibers, glycoproteins and proteoglycans in skin and veins of these patients. Using indirect immunodetection, we have also determined the presence and localisation of collagen type I, fibrillin-1 and laminin in veins and skin as well as MMPs involved in tissue remodelling (MMP-1, MMP-2, MMP-3, MMP-7, MMP-9 and their specific inhibitors TIMP-1, TIMP-2 and TIMP-3).

MATERIALS AND METHODS

Specimen collection. Two groups of internal saphenous veins were used. Eight control veins were obtained from patients (5 men and 3 women mean age 63.8 years range 50-82) undergoing coronary bypass surgery. Preoperative evaluation of the absence of varicose abnormalities or retrograde flow was obtained by echo-Doppler studies; these veins are referred to as “control” veins in comparison with varicose. Skin biopsies were recovered from these patients during the surgery at the thorax to exclude solar elastosis.

Eight varicose veins (greater saphenous veins) were obtained from primary varicose vein patients (2 men and 6 women; mean age 58.3 years range 36-79) during saphenectomy by stripping. All patients were CEAP class 2 and 3 with saphenous vein reflux and varicosities all along the venous axis and did not present venous ulcers. Skin biopsies were retrieved from the groin (in non solar exposed zones) during the surgery.

The study was in accordance with the principles outlined in the Declaration of Helsinki and was approved by the local ethical committee. All patients gave their informed consent.

Histological studies. All specimens were fixed in Bouin’s solution for 48 hours and then embedded in paraffin. Serial tissue sections, 5µm thick, prepared with a manual microtome were routinely stained with haematoxylin and eosin to assess the tissue quality.

For staining the collagen bundles, Sirius red was used according to Junqueira’s technique [17]. To analyse elastic fibers, the (+)catechin method was used as an appropriate histological technique for the quantitative analysis of these fibers [18].

For staining proteoglycans, Alcian Blue was used according to Scott’s technique [19], and Schiff reagent was used for glycoprotein detection.

Image analysis. After staining with (+)catechin method, the microscopic slides were observed under a Zeiss microscope equipped with a CF 126 PHR video camera. Tissues were observed and processed for image analysis by two pathologists with no knowledge of the patients. Ten fields per skin or vein section, three sections per assay, thus a total of 30 microscopic fields, were analysed in each case, then summed and dealt statistically.

The black and white images generated by the video camera were converted into 256 different grey levels using a SOPHRETEC MVM 600 image memory transferred to a BFM 186

microcomputer, and analysed using a software for mathematical morphology [18,20]. The image generated in this way was composed of 256 x 256 picture elements (pixels). The elastic fibers were counted electronically and labelled in different colours to ease their identification. Then the program calculates the area fraction occupied by the elastic fibers (AA%), i.e., pixels of elastin/65536 pixels. This AA% represents the surface of elastic fibers, AA% as a function of the tissue area analysed. The evaluation of the diameters of the elastic fibers was performed semi automatically on a BIOCOM station (BIOCOM, France) using the Imagenia 3000 program.

Immunodetection of collagen I, laminin and fibrillin-1. Paraffin-embedded sections were deparaffinised and hydrated through xylene and graded alcohol series. Sections were rinsed for 5 minutes in distilled water. Endogenous peroxydase activity was blocked by incubation in 3% hydrogen peroxide for 5 minutes. Tissue sections were washed in Phosphate buffered saline (PBS) for 5 minutes, then incubated during 10 minutes with non fat dried milk, then washed twice 5 minutes in PBS. Tissue sections were incubated during 1 hour with primary monoclonal antibody in PBS and then washed three times for 10 minutes in PBS. Monoclonal antibodies were purchased from Chemicon for fibrillin-1 (dilution 1/50), Dako (Carpinteria, CA) for laminin (1/25), Biodesign (Saco, MN) for collagen type I (1/30). Absence of primary antibody was used as a blank and controls were performed using non immune mouse serum. Tissue sections were then incubated with anti- mouse peroxydase-conjugated antibody (Amersham, Buckinghamshire, England) during 30 minutes and washed several times 5 minutes in PBS. The sections were then incubated in peroxydase substrate solution (Di Amino Benzamidine) in a dark chamber for 20 minutes, then rinsed in distilled water (twice, 5 minutes), and counterstained with haematoxylin for collagen type I and fibrillin-1 or (+)catechin-fuchsin for laminin, cleared and mounted for observation under light microscope.

Preparation of frozen tissue sections. Vein and skin biopsies were washed in saline physiological solution, embedded in OCT compound (tissue-Tek) and then snap-frozen in liquid nitrogen and stored at -80°C until use. Frozen tissue sections, 7µm thick, were used at -20°C with a manual cryomicrotome on slides, air dried for 30 minutes, fixed in acetone at room temperature and stored at -80°C.

Immunodetection of MMPs and TIMPs. Frozen sections were air dried and then washed in PBS. Endogenous peroxydases were blocked as described previously. Immunolabelling of MMP-1, MMP-2, MMP-3, MMP-7, MMP-9, TIMP-1, TIMP-2 and TIMP-3 was performed as mentioned above. Monoclonal antibodies were purchased from France Biochem (Meudon, France). The staining was developed for a same period of time for each antibody in control and pathological specimen. Each antibody was tested at least on 8 patients, and the staining was blindly scored by three different people. The final results take into account the relative difference between control and varicose specimen as well as the intensity of the labelling in each sample. The intensity of staining scoring was appreciated as follows: - discrete, + small, ++ slight and +++ large.

Statistical analysis. All statistical analysis were performed by unpaired Student's *t*-test. P values < .05 were interpreted as statistically significant.

RESULTS

Histological studies

Veins: In control veins, the blood vessel wall is well-organized in three layers (Fig 1A): a continuous endothelial cell monolayer (intima), a thin continuous internal elastic lamella that separates the intima from the media and is composed of smooth muscle cells and regularly organized collagen bundles and finally, fibroblasts in the adventitia with elastic fibers close to each other. Elastic fibers are well organized from the intima to the adventitia (Fig 1B) and the collagen bundles are uniformly distributed in the vessel wall (Fig 1C).

In varicose veins, the venous wall is thickened with a poorly structured connective tissue (Fig. 1D). There is neither a clear limit between the intima and the media nor between the media and the adventitia. The smooth muscle cells have lost their original orientation, appear packed in the intima-media and surrounded by unstructured material. Staining for elastic fibers shows that the venous elastic network is highly disorganized (Fig 1E). Numerous elastic fibers appear thickened and fragmented from the intima to the adventitia. Collagen bundles are completely disorganized throughout the venous wall, especially in the inner part of the blood vessel without differentiation of the media and the adventitia (Fig 1F).

Skin: In control skin, two parts are distinguished: the epidermis, lying on thin, continuous and undulated basement membrane (Fig 2A) and the dermis with collagen bundles which appear thin and regularly ordered with distinct interspaces at the lower part (Fig 2C). Typical elastic fibers can be observed among the bundles of collagen (Fig 2B). The network of elastic fibers is composed of well-individualised oxytalan fibers oriented perpendicularly to the dermo-epidermal basement membrane. The oxytalan fibers are connected with elaunin fibers running parallel to the epidermis (Fig 2B). In the deep part and the mid-dermis the elastic fibers appear long and regularly positioned.

In skin from varicose vein patients, the epidermis lies on a continuous but thick and flat basement membrane (Fig 2D). From the upper to the deeper part of the dermis, the collagen bundles appear thick (Fig 2F). The oxytalan fibers of the elastic network become irregular, short, thickened while the elaunin fibers appear fragmented and thick (Fig 2E). The elastic fibers of the dermis are dispersed, fragmented and thickened (Fig 2E).

Quantitative analysis of diameter and fraction area of elastic fibers

Veins: The mean diameter of elastic fibers was calculated in the three layers of the venous wall (intima, media and adventitia). Figure 3A shows that this diameter is significantly increased in the intima, the media and the adventitia of varicose veins as compared to control veins.

The area fraction occupied by these lamellae was calculated and was also significantly augmented in the three layers of the varicose vein wall (Fig. 3B).

Skin: The diameter of oxytalan fibers in the skin of control patients and patients with varicose veins was measured. The diameter of these pre-elastic fibers was significantly increased in skin of patients with varicose veins ($.65 \pm .12\mu\text{m}$ and $1.05 \pm .13\mu\text{m}$ for control and varicose vein patients respectively, $n=6$, $P<.001$, unpaired t test).

The area fraction occupied by the oxytalan fibers in the skin of control patients was $3.95\% \pm .5\%$ and was similar to that noted in skin of varicose vein patients ($3.90\% \pm .50\%$, $n=6$, NS, unpaired t test).

Figure 3A shows that the diameter of the dermal elastic fibers was significantly augmented in skin of patients with varicose veins. The area fraction occupied by the dermal elastic fibers was also significantly increased in varicose vein patients (Fig.3B).

Immunodetection of collagen type I, fibrillin-1 and laminin

Veins: In control veins, the extracellular matrix contains predominantly collagen type I regularly distributed from the media to the adventitia throughout the vessel wall (Fig 4A). The fibrillin-1 underlines the elastic lamellae of the vein wall (Fig 4B) and the laminin is particularly observable associated to the endothelial and smooth muscle cells (Fig 4C).

In varicose veins, the accumulation of the extracellular matrix is demonstrated with large quantities of collagen type I but there is not apparent difference in its distribution (Fig 4D). Prominent labelling is observed in the media for fibrillin-1 (Fig 4E) and laminin (Fig 4F). The absence of labelling of laminin in the intima of varicose veins is probably due to the absence of endothelium in the specimen after stripping (Fig 4F).

Skin: In control skin, the extracellular matrix contains large quantities of collagen type I predominant throughout the dermis (Fig 5A).

Fibrillin-1 is recovered associated to pre-elastic fibers in the upper part of the dermis and to elastic fibers in the deep and mid-dermis (Fig 5B). The laminin underlines the dermo-epidermal basement membrane and also the outer part of vessels (Fig 5C).

In skin from varicose vein patients, no difference is observed in the distribution of collagen type I but the staining is more intense when compared with control (Fig 5D). Fibrillin-1 underlines the elastic network from the papillary to the deep dermis with a very intense labelling (Fig 5E) and the laminin is also positive for the basement membrane of the vessels and strongly positive for the dermo-epidermal basement membrane of the skin (Fig 5F).

Immunodetection of MMPs and TIMPs

Veins: Table 1 shows that MMP-1, 2, 3 and 7 are produced both by the endothelium and smooth muscle cells, MMP-9 is poorly detected in tissues (data not shown). The labelling of MMP-1, 2, 3 and 7 is increased in the intima and media of varicose veins (Table 1 and Figure 6). The staining of MMP-2 appears to be weak in the intima and media of control veins and positive in the adventitia whereas it strongly increases in all the compartments of the vessel wall of varicose veins (Fig 6A and C). The 3 inhibitors TIMP-1, 2 and 3 are also detected in the two parts of veins except in media of control veins for TIMP-3 and in intima of varicose veins for TIMP-2 (Table 1). TIMP-1 and 3 labellings are slightly increased in varicose vein media compared to control veins whereas TIMP-2 seems to be decreased in varicose veins (Table 1).

Skin: The 3 proteases MMP-1, 2 and 3 are present in epidermis and dermis and are increased in skin of patients with varicose veins (Table 1 and Fig. 7). MMP-7 labelling is similar in skin of patients with varicose veins and in control skin. The 3 inhibitors TIMP-1, 2 and 3 are present to a similar extend in skin of control and varicose vein patients (Table 1).

DISCUSSION

The major finding of the present study is the demonstration of similar tissue structure abnormalities in saphenous veins and skin of patients with varicose veins: (1) elastic fibers are thickened and fragmented, associated with increased levels of fibrillin-1, (2) collagen bundles are increased and have lost their original orientation, (3) the diameter and fraction area of elastic fibers are increased and (4), MMP-1, -2 and -3 labelling is increased.

Several studies have described a remodelling in varicose veins leading to a decreased elasticity and an increased distensibility of the venous wall [13,21]. All limb veins from patients with varicosities are more distensible than normal, suggesting a genetic basis for the abnormality [22]. This hypothesis was sustained by a similar dysregulation of collagen type I and III production in cultured venous smooth muscle cells and dermal fibroblasts obtained from varicose vein patients [16]. Thus, a genetic defect in the regulation of the composition of the extracellular matrix might participate to the pathogenesis of varicose veins. Such a genetic defect should affect different connective tissues, because the smooth muscle cells of blood vessels and fibroblasts of the dermis both derive from embryonic mesenchyme.

An altered elastic network with fragmented elastic fibers has been described in varicose veins [21,23-26]. In the present study, we have observed fragmentation, scattering and an abnormal distribution of elastic fibers in varicose veins and these alterations may help to explain the functional findings of their reduced strength and elasticity. The elastic network was quantified by the measurement of the diameter of the fibers and the area occupied by them. The method used has several advantages over previously published procedures: (1) the stain reproducibly distinguishes the elastic fibers from other macromolecular components and yields a colourless background which is a prerequisite for image analysis [27]; (2) two different staining methods were compared in a previous study to determine whether the dermal elastic fibers could be accurately measured by computerized image analysis; comparisons were made after indirect immunostaining using human monoclonal antibody to elastin and by the (+) catechin-fuchsin method [27]. The two stainings were superimposable and after image analysis the difference between the two methods corresponds to 5-6% [4,28]. In the present study, we demonstrated that the diameter and fraction occupied by elastic fibers in the skin of patients suffering from varicose veins correlates with those found in their veins. The diameter and the area fraction of these elastic fibers were significantly increased in the 3 layers of the varicose veins. It is possible that an extended disorganization of the extracellular matrix leads to a disassembly of elastic fibers. The demonstration in this study and others [25,29] of qualitative and

quantitative changes in elastic fibers may explain the weakness of the varicose vein wall and its subsequent dilatation.

In the skin of control patients, the network of elastic fibers presents a typical organization in agreement with previous studies on human skin elastic fibers [29]. In the skin of patients suffering from varicose vein disease, the elastic network becomes irregular with thickened and fragmented elastic and pre-elastic fibers. The amount of elastic fibers detected in skin of varicose vein patients when compared with control skin of individuals with similar age range is increased. Previous studies have demonstrated an augmentation of the content of elastic fibers with ageing of the skin [30] but the values obtained in varicose vein patients exceed greatly those reported with healthy patients with similar age range. Moreover, it has been described that these qualitative as well as the quantitative modifications of the skin elastic fibers with age involve a continuous decrease in the skin elasticity [31]. These observations suggest that the elastic properties of the skin of patients with varicose veins are profoundly altered. By immunodetection of fibrillin-1, we demonstrate a more intense labelling of the skin and also of venous elastic fibers in tissues of varicose vein patients. This is consistent with the structure of elastic fibers which are composed of an amorphous elastin core associated with microfibrils, the microfibrillar proteins including among others, fibrillins and microfibrillar-associated glycoproteins-1 and 2, MAGP1 and 2 [32]. This augmentation of fibrillin-1 in skin and veins of patients with varicose veins is well correlated with the increased amount of elastic fibers. Moreover, a visual disorganization of the elastic network in skin and veins of varicose vein patients is evidenced by the immunolabelling of fibrillin-1. Several studies have indicated that in certain acquired or hereditary conditions such as: atherosclerosis [2], Marfan syndrome [33], Williams Beuren syndrome [4] the amount of elastin in the skin and the loss of integrity of elastic fibers reflect similar changes in several vessels such as the aorta.

Collagen bundles in varicose veins appear thick and disorganized in the media; this is also observed in the skin of the patients, from the upper to the deeper part of the dermis. The thickening of collagen bundles may be due to an enhanced synthesis and deposition of collagen, mainly collagen type I as we demonstrated by immunolabelling, and also to a decrease in its susceptibility to catabolic enzymes due to the classic finding of Verzar [34] concerning crosslinking of collagen with age. The accumulation of collagen type I in varicose veins agrees with the findings of previous studies, which showed that varicosis is related to increased production of collagenous tissue involving fibrosis [35], and was also demonstrated in cultured venous smooth muscle cells and dermal fibroblasts of patients with varicose veins

[13,16]. This accumulation may be involved in the decreased elasticity and increased rigidity observed in varicose veins and probably also in skin of the patients.

An increase of laminin labelling was observed in the media of varicose veins and agrees with previous studies [23]. Laminin is responsible for the modulation of cellular functions and the organization of the extracellular matrix. Therefore, enhanced production of laminin can result in increased remodelling and disorganization of matrix vessel wall. The augmentation of laminin was also found in the skin of patients with varicose vein disease; intense labelling of laminin was indeed observed at the level of the dermo epidermal junction but also at the level of the vascular basement membrane by comparison with healthy patients. Some years ago, Olsen and Uitto [36] reported a differential regulation of the expression of different basement membrane macromolecules, namely collagen type IV and laminin during chronological aging of cultured skin fibroblasts. The expression of $\alpha 1$ and 2 collagen type IV genes was reduced in old individuals, but in contrast laminin B1 and B2 chains mRNA levels showed little age-associated variation. In our study, high levels of laminin appear in the dermo epidermal junction and it could be of interest to investigate whether this accumulation is due to enhanced expression or to an increased resistance to enzymatic hydrolysis or both.

In all pathologies involving matrix remodelling, an imbalance between the production of extracellular matrix proteins, MMPs and TIMPs is observed. The production of several MMPs and of the three inhibitors TIMPs was evaluated by immunohistochemistry. In varicose veins, the production of MMP-1,-2,-3 and -7 was augmented in the intima and the media. This increase in MMP expression reflects changes in the regulation of connective tissue. However, the level of TIMP labelling also appears to be increased in varicose veins, except for TIMP-2, the preferential inhibitor of MMP-2, indicating a possible over activity of MMP-2. The augmentation of MMP-1, -2 and TIMP-1 in varicose veins has already been described [37-39], whereas others describe a decrease of MMP-2 [40]. The findings appear to be contradictory but one has to take into account the lack of standardization of the specimen used in the different studies with respect to vein source, localization and subject age. In our present study, we compared the labelling in the varicose veins with that in the skin of the patients. The levels of MMP-1,-7 and the inhibitors TIMP-1,-2 and -3 were slightly modified, but the staining of MMP-2 and -3 was highly augmented in skin of varicose vein patients compared to control skin. The increase of MMP-2 production was also described previously for cultured dermal fibroblasts derived from skin of varicose vein patients [16]. Elastin and collagen type III, conferring elasticity, are substrates for MMP-2 and MMP-3 [41-43] and thus, the higher MMP-2 and MMP-3 production may be implicated in the degradation of

collagen type III and fragmentation of elastin in skin and saphenous veins of varicose vein patients. Moreover, MMP-3 was recently shown to be upregulated in cultured smooth muscle cells from varicose veins [44] and in tissues [45] and was described as a potential therapeutic target for the treatment of chronic venous ulcers [46].

Changes in extracellular matrix proteins are also abundant in atherosclerosis, a disease of the arteries. Saphenous veins, used for coronary artery bypass surgery are known to be susceptible to accelerated atherosclerosis leading to graft failure [47,48]. The use of veins, in coronary patients susceptible to venous disease, could present an increased risk for such graft failure.

All these findings show that the alterations of extracellular matrix in varicose veins are also present in the skin of these patients and may suggest that varicose veins are the expression of a systemic pathology of the connective tissue. It can thus be concluded that patients with varicose veins suffer from a systemic disease where cells deriving from embryonic mesenchyme synthesize and degrade matrix abnormally. Further studies are now necessary to search genes implicated in these matrix metabolism abnormalities.

ACKNOWLEDGEMENT

The authors would like to thank the excellent technical assistance of Sabah GHOMRASSENI.

Reference List

1. Holbrook,K.A. and Byers,P.H. (1982) Structural abnormalities in the dermal collagen and elastic matrix from the skin of patients with inherited connective tissue disorders. *J Invest.Dermatol.* 79 suppl 1, 7s-16s.
2. Bouissou,H., Pierragi,T., Jullian,M. and Douste Blazy,L. (1976) Simultaneous degradation of elastin in dermis and aorta. *Front Matrix Biol.* 3, 242-255.
3. Berteretche,M.V., Hornebeck,W., Pellat,B., Bardon,C.B. and Godeau,G. (1995) Histomorphometric parameters and susceptibility to neutrophil elastase degradation of skin elastic fibres from healthy individuals and patients with Marfan syndrome, Ehlers-Danlos type IV, and pseudoxanthoma elasticum. *Br.J.Dermatol.* 133, 836-841.
4. Dridi,S.M., Ghomrasseni,S., Bonnet,D. et al. (1999) Skin elastic fibers in Williams syndrome. *Am.J.Med.Genet.* 87, 134-138.
5. Ghomrasseni,S., Dridi,S.M., Bonnefoix,M. et al. (2001) Morphometric analysis of elastic skin fibres from patients with: cutis laxa, anetoderma, pseudoxanthoma elasticum, Buschke-Ollendorff and Williams-Beuren syndromes. *J.Eur.Acad.Dermatol.Venereol.* 15, 305-311.
6. Gogly,B., Godeau,G., Septier,D., Hornebeck,W., Pellat,B. and Jeandel,C. (1998) Measurement of the amount of elastic fibers in the skin and temporal arteries of healthy aged individuals by automated image analysis. *Gerontology* 44, 318-323.
7. Rekhter,M.D. (1999) Collagen synthesis in atherosclerosis: too much and not enough. *Cardiovasc.Res.* 41, 376-384.
8. Schoenhagen,P., Vince,D.G., Ziada,K.M. et al. (2002) Relation of matrix-metalloproteinase 3 found in coronary lesion samples retrieved by directional coronary atherectomy to intravascular ultrasound observations on coronary remodeling. *Am.J.Cardiol.* 89, 1354-1359.
9. Davies,M.G. and Hagen,P.O. (1995) Pathophysiology of vein graft failure: a review. *Eur.J.Vasc.Endovasc.Surg.* 9, 7-18.
10. Cornu-Thenard,A., Boivin,P., Baud,J.M., De Vincenzi,I. and Carpentier,P.H. (1994) Importance of the familial factor in varicose disease. Clinical study of 134 families. *J.Dermatol.Surg.Oncol.* 20, 318-326.
11. Reagan,B. and Folse,R. (1971) Lower limb venous dynamics in normal persons and children of patients with varicose veins. *Surg.Gynecol.Obstet.* 132, 15-18.
12. Fowke,S.F.G.R. (1996) Epidemiology of chronic venous insufficiency. *Phlebology* 11, 2-5.
13. Sansilvestri-Morel,P., Rupin,A., Badier-Commander,C. et al. (2001) Imbalance in the synthesis of collagen type I and collagen type III in smooth muscle cells derived from human varicose veins. *J.Vasc.Res.* 38, 560-568.

14. Charles,A.K. and Gresham,G.A. (1993) Histopathological changes in venous grafts and in varicose and non-varicose veins. *J.Clin.Pathol.* 46, 603-606.
15. Andreotti,L., Cammelli,D., Sampognaro,S. et al. (1985) Biochemical analysis of dermal connective tissue in subjects affected by primary uncomplicated varicose veins. *Angiology* 36, 265-270.
16. Sansilvestri-Morel,P., Rupin,A., Jaisson,S., Fabiani,J.N., Verbeuren,T.J. and Vanhoutte,P.M. (2002) Synthesis of collagen is dysregulated in cultured fibroblasts derived from skin of subjects with varicose veins as it is in venous smooth muscle cells. *Circulation* 106, 479-483.
17. Junquiera,L.C. and Brentani,R.R. (1979) A simple and sensitive method for the quantitative estimation of collagen. *Anal.Biochem.* 94, 96-99.
18. Godeau,G., Gonnord,G., Jolivet,O. et al. (1986) A selective histochemical method for the quantitative estimation of elastic fibers by computerized morphometric analysis. Effect of colchicin treatment. *Anal.Quant.Cytol.Histol.* 8, 321-325.
19. Scott,J.E. and Dorling,J. (1965) Differential staining of acid glycosaminoglycans (mucopolysaccharides) by alcian blue in salt solutions. *Histochemie* 5, 221-233.
20. Serra,J. (1982) Image analysis and mathematical morphology, Academic Press., London
21. Badier-Commander,C., Couvelard,A., Henin,D., Verbeuren,T., Michel,J.B. and Jacob,M.P. (2001) Smooth muscle cell modulation and cytokine overproduction in varicose veins. An in situ study. *J.Pathol.* 193, 398-407.
22. Zsoter,T. and Cronin,R.F. (1966) Venous distensibility in patients with varicose veins. *Can.Med.Assoc.J.* 94, 1293-1297.
23. Kirsch,D., Schreiber,J., Dienes,H.P., Bottger,T. and Junginger,T. (1999) Alterations of the extracellular matrix of venous walls in varicose veins. *Vasa* 28, 95-99.
24. Khan,A.A., Eid,R.A. and Hamdi,A. (2000) Structural changes in the tunica intima of varicose veins: a histopathological and ultrastructural study. *Pathology* 32, 253-257.
25. Wali,M.A. and Eid,R.A. (2002) Changes of elastic and collagen fibers in varicose veins. *Int.Angiol.* 21, 337-343.
26. Porto,L.C., Azizi,M.A., Pelajo-Machado,M., Matos,d.S. and Lenzi,H.L. (2002) Elastic fibers in saphenous varicose veins. *Angiology* 53, 131-140.
27. Godeau,G. (1984) Selective staining technique for the identification of human skin elastic fibers. *Pathol Biol* 32, 215-216.
28. Uitto,J., Lauzence,J., Brockley,K., Pearce,R.M. and Clarck,J.G. (1983) Elastic fibers in human skin: quantification of elastic fibers by computerized digital analysis

- and determination of elastin by radioimmunoassay of desmosin. *Lab Invest* 49, 499-508.
29. Cotta-Pereira,G., Guerra-Rodrigo,F. and Bittencourt-Sampaio,S. (1976) Oxytalan, elaunin and elastic fibers in human skin. *J.Invest.Dermatol.* 66, 143-148.
 30. Gogly,B., Godeau,G., Gilbert,S. et al. (1997) Morphologic analysis of collagen and elastic fibers in normal skin and gingiva in relation to age. *Clin Oral Invest* 1, 147-152.
 31. Robert,C., Dickstein,S. and Robert,L. (1988) Study of skin aging as a function of social and professional conditions: modifications of the rheological parameters measured with non invasive method. *Gerontology* 34, 284-290.
 32. Penner,A.S., Rock,M.J., Kielty,C.M. and Shipley,J.M. (2002) Microfibril-associated glycoprotein 2 interacts with fibrillin1 and fibrillin 2 suggesting a role for MAGP2 in elastic fiber assembly. *J Biol Chem* 38, 35044-35049.
 33. Bonneau,D., Huret,J.L. and Godeau,G. (1991) Recurrent ctb(7)(q31.3) and possible laminin involment in neonatal cutis laxa with a Marfan phenotype. *Hum Genet* 87, 317-319.
 34. Verzar,F. (1964) Aging of the collagen fiber. *Int.Rev.Connect.Tissue Res.* 2, 243-300.
 35. Rose,S.S. and Ahmed,A.A. (1986) Some thoughts on the aetiology of varicose veins. *J.Cardiovasc.Surg.* 27, 534-543.
 36. Olsen,D.R. and Uitto,J. (1989) Differential expression of type IV pro collagen and laminin genes by fetal vs. adult skin fibroblasts in culture: determination of subunit mRNA steady state level. *J Invest Dermatol* 93, 127-131.
 37. Gillespie,D.L., Patel,A., Fileta,B. et al. (2002) Varicose veins possess greater quantities of MMP-1 than normal veins and demonstrate regional variation in MMP-1 and MMP-13. *J.Surg.Res.* 106, 233-238.
 38. Parra,J.R., Cambria,R.A., Hower,C.D. et al. (1998) Tissue inhibitor of metalloproteinase-1 is increased in the saphenofemoral junction of patients with varices in the leg. *J.Vasc.Surg.* 28, 669-675.
 39. Bujan,J., Jurado,F., Gimeno,M.J. et al. (2000) Changes in metalloproteinases (MMP-1, MMP-2) expression in the proximal region of the varicose saphenous vein wall in young subjects. *Phlebology* 15, 64-70.
 40. Badier-Commander,C., Verbeuren,T.J., Lebard,C., Michel,J.B. and Jacob,M.P. (2000) Increased TIMP/MMP ratio in varicose veins: a possible explanation for extracellular matrix accumulation. *J.Pathol.* 192, 105-112.
 41. Aimes,R.T. and Quigley,J.P. (1995) Matrix metalloproteinase-2 is an interstitial collagenase. Inhibitor-free enzyme catalyzes the cleavage of collagen fibrils and soluble native type I collagen generating the specific 3/4- and 1/4-length fragments. *J.Biol.Chem.* 270, 5872-5876.

42. Berton,A., Rigot,V., Huet,E. et al. (2001) Involvement of fibronectin type II repeats in the efficient inhibition of gelatinases A and B by long-chain unsaturated fatty acids. *J.Biol.Chem.* 276, 20458-20465.
43. Lijnen,H.R. (2001) Plasmin and matrix metalloproteinases in vascular remodeling. *Thromb.Haemost.* 86, 324-333.
44. Sansilvestri-Morel,P., Rupin,A., Jullien,N.A. et al. (2005) The decreased production of collagen type III in cultured smooth muscle cells from varicose vein patients is due to a degradation by MMPs: possible implication of MMP-3. *J.Vasc.Res.* 42, 388-398.
45. Kowalewski,R., Sobolewski,K., Wolanska,W. and Gacko,M. (2004) Matrix metalloproteinases in the vein wall. *Int.Angiol.* 23, 164-169.
46. Saarialho-Kere,U.K. (1998) Patterns of matrix metalloproteinase and TIMP expression in chronic ulcers. *Arch.Dermatol.Res.* 290 Suppl, S47-S54.
47. Shi,Y., O'Brien,J.E., Jr., Mannion,J.D. et al. (1997) Remodeling of autologous saphenous vein grafts. The role of perivascular myofibroblasts. *Circulation* 95, 2684-2693.
48. Campbell,P.A., McGeachie,J.K. and Prendergast,F.J. (1981) Vein grafts for arterial repair: their success and reasons for failure. *Ann.R.Coll.Surg.Engl.* 63, 257-260.

LEGENDS OF FIGURES

Figure 1: Histological structure of the venous wall of control (A, B, C) and varicose (D, E, F) saphenous veins. Veins were stained with Hemalun and Schiff reagent (A, D) for the detection of glycoproteins and cell nuclei; (+) catechin (B, E) for the detection of elastic fibers; and Sirius red and visualised in polarized light (C, F) for the detection of collagen bundles. Smooth muscle cells of media appear unstructured in varicose veins (C), associated with fragmentation of elastic fibers (D) and disorganization of collagen bundles (E). l: lumen; m: media. Bar represents 100 μ m.

Figure 2: Histological structure of the skin of control patients (A, B, C) and varicose vein patients (D, E, F). Skins were stained with Hemalun and Schiff reagent (A, D) for the detection of glycoproteins and cell nuclei; (+) catechin (B, E) for the detection of elastic fibers, and Sirius red visualised in polarized light (C, F) for the detection of collagen bundles. Elastic fibers become irregular in patients with varicose veins (E, red arrows) and collagen bundles are thickened (F, white arrows). Ep: epidermis; d: dermis; Ox: oxytalan fibers; E: Elaunin fibers. Bar represents 100 μ m and 50 μ m for the upper part of B and E.

Figure 3: The diameter (A) and the fraction area (B) of elastic fibers are increased in skins and veins of varicose vein patients. Vein (intima, media and adventitia (ADV.)) and skin specimen from control (white) and varicose vein patients (black) were fixed, embedded in paraffin, cut with a microtome and stained by the (+) catechin method. Elastic fibers were quantified after acquisition with a video camera and analysed with an image analysis software. Results are reported as the mean \pm SEM.

*, **, ***: values significantly different from control value ($P < .05$; .01; .001 respectively; Student's *t*-test for unpaired observations, $n=8$).

Figure 4: Immunodetection of collagen type I (A,D); fibrillin-1 (B, E) and laminin (C, F) in control (A, B, C) and varicose veins (D, E, F). Immunohistochemistry was performed and revealed by a substrate of peroxydase. An increased labelling of collagen type I (D), fibrillin-1 (E) and laminin (F) was observed in the media of varicose veins. l: lumen; m: media. Bar represents 100 μ m for A, D, E and 50 μ M for B, C and F.

Figure 5: Immunodetection of collagen type I (A,D); fibrillin-1 (B, E) and laminin (C, F) in skin of control subjects (A, B, C) and varicose vein patients (D, E, F). Immunohistochemistry was performed and revealed by a substrate of peroxydase. The labelling for collagen I (D) and fibrillin-1 (E) was strongly increased in the dermis of varicose vein patients; laminin labelling was increased in the dermo-epidermal basement membrane (F, red arrows). Ep: epidermis; d: dermis. Bar represents 100µm.

Figure 6: Immunodetection of MMP-2 (A,C) and MMP-3 (B, D) in control (A, B) and varicose veins (C, D). The MMP-2 and MMP-3 labelling was increased in the media of varicose veins (C and D respectively). l: lumen; m: media. Bar represents 100µm.

Figure 7: Immunodetection of MMP-2 (A,C) and MMP-3 (B, D) in skin of control subjects (A, B) and varicose vein patients (C, D).). The MMP-2 and MMP-3 labelling was strongly increased in the dermis and epidermis of patients with varicose veins (C and D respectively). Ep: epidermis; d: dermis. Bar represents 100µm.

Table 1: Immunodetection of MMP-1,2,3 and 7, TIMP-1, 2 and 3 in tissue sections of veins and skins of control and varicose vein patients.

			MMP-1	MMP-2	MMP-3	MMP-7	TIMP-1	TIMP-2	TIMP-3
VEIN	INTIMA	CONTROL	+	+/-	+	+	+	+++	+
		VARICOSE	++	++	+++	+++	+	-	++
	MEDIA	CONTROL	+	+/-	+	+	+	+++	-
		VARICOSE	++	++	+++	+++	++	++	++
SKIN	EPIDERMIS	CONTROL	++	+	+	++	++	++	+
		VARICOSE	+++	++	++	+	++	++	+
	DERMIS	CONTROL	++	+	+	+	+	+++	+ / ++
		VARICOSE	+++	+ / +++	+++	+	+ / +++	+++	+++

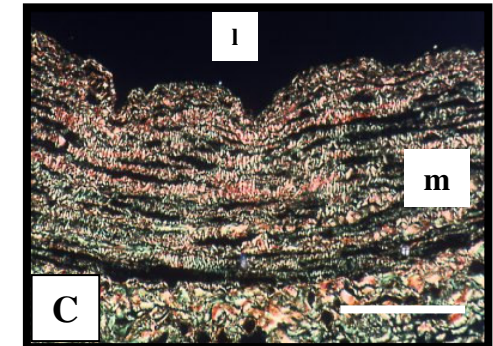
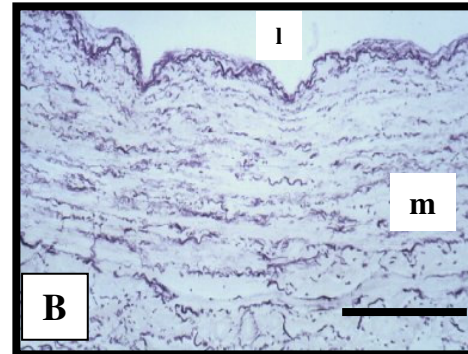
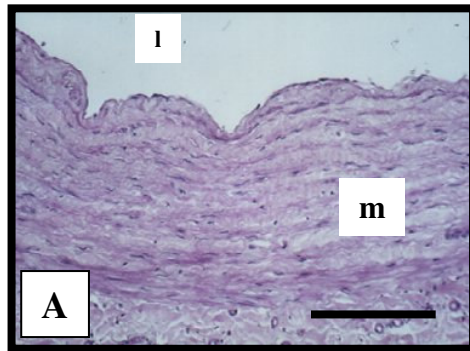
Frozen sections of control veins and varicose veins and skin from control and varicose vein patients were cut with a cryomicrotome and immunohistochemistry was performed.

The scores were blindly established by three independent observers according to the labelling observed with a microscope and abbreviated as follows:

-: discrete ; + : small ; ++ : slight ; +++ : large.

Figure 1

CONTROL



VARICOSE


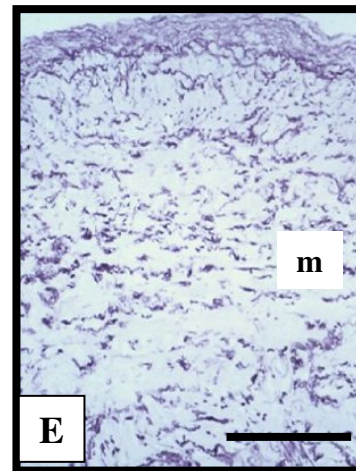
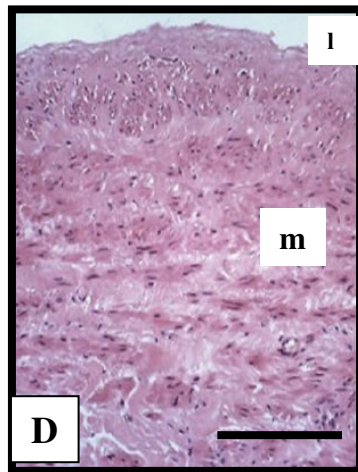


Figure 2

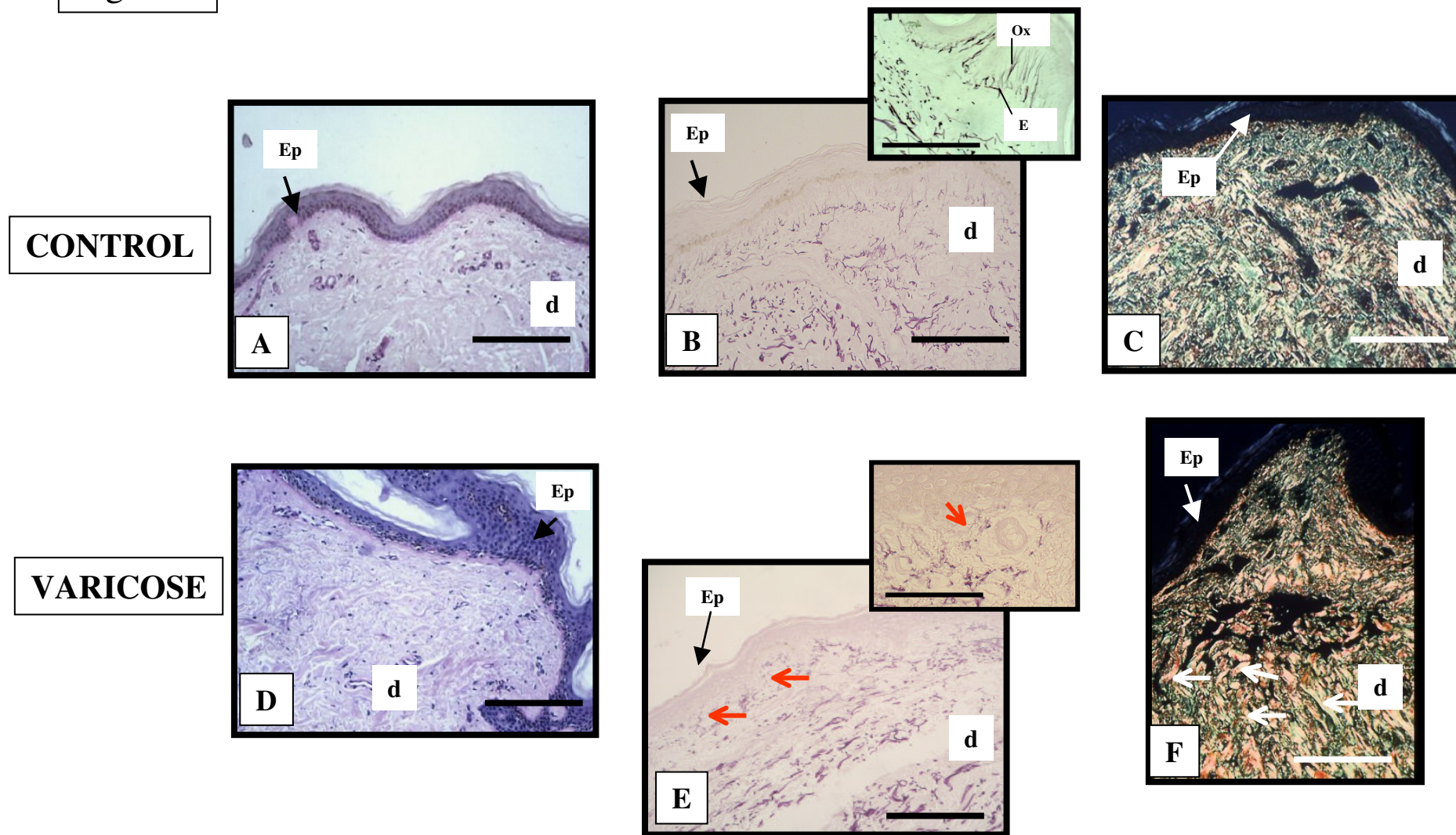
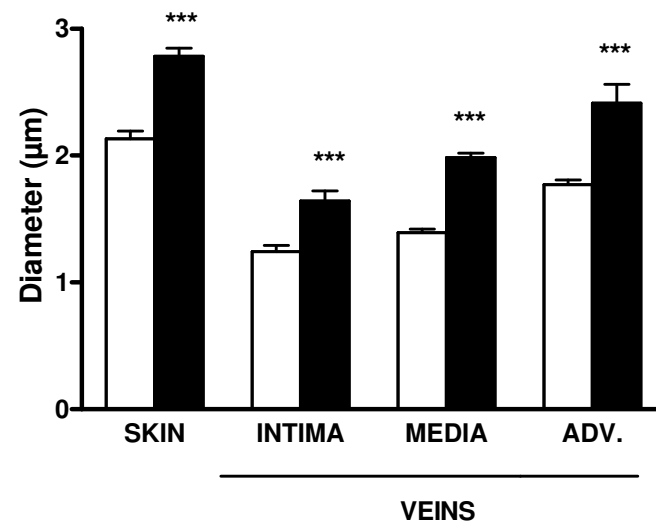


Figure 3

A



B

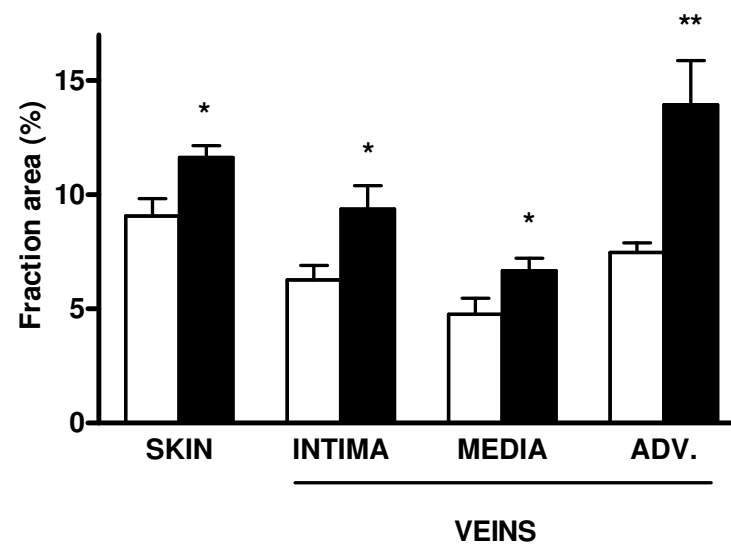


Figure 4


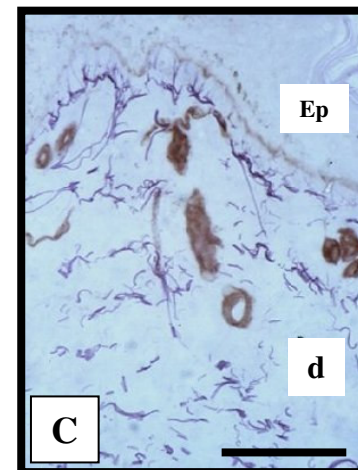
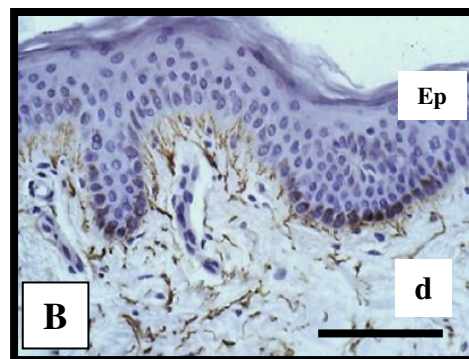
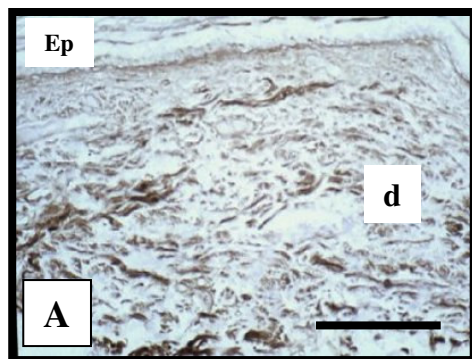


Figure 5

CONTROL



VARICOSE

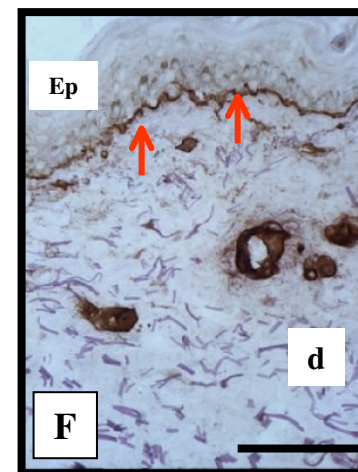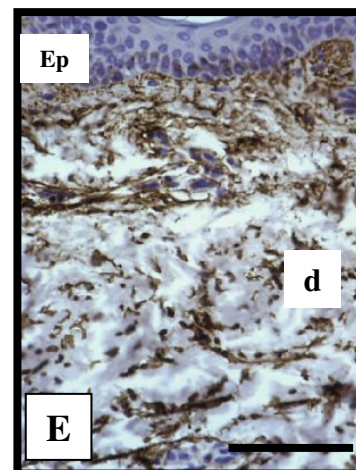
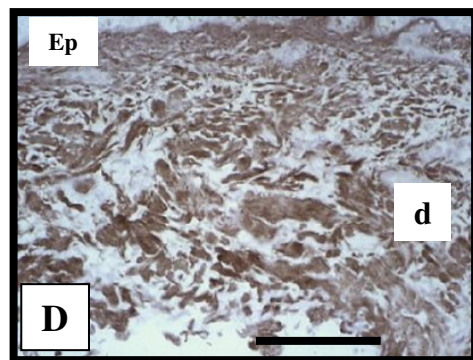
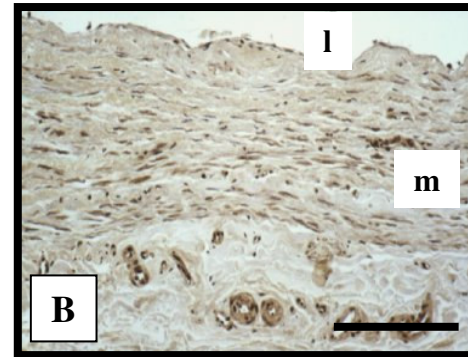
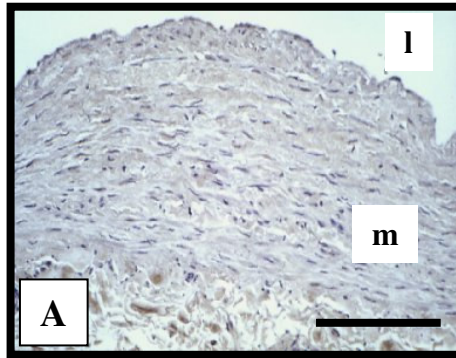


Figure 6

CONTROL



VARICOSE

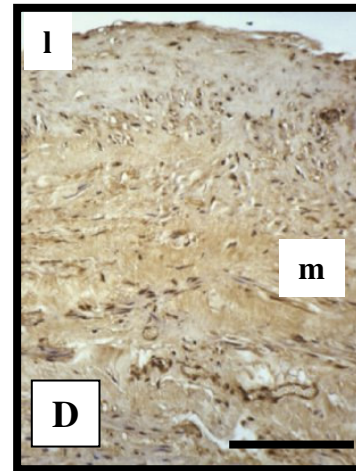
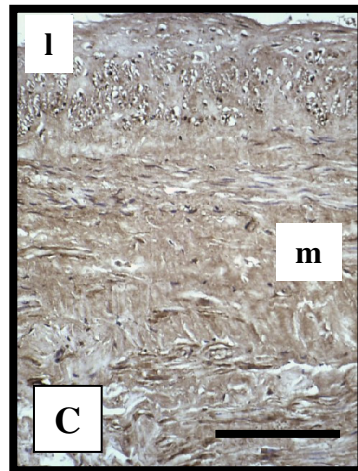
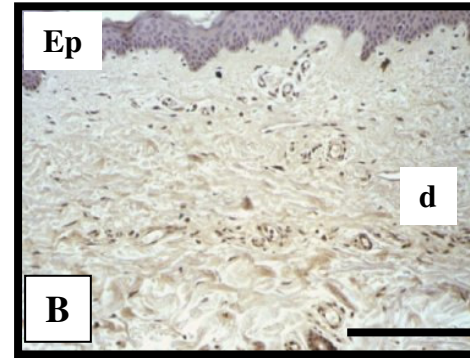
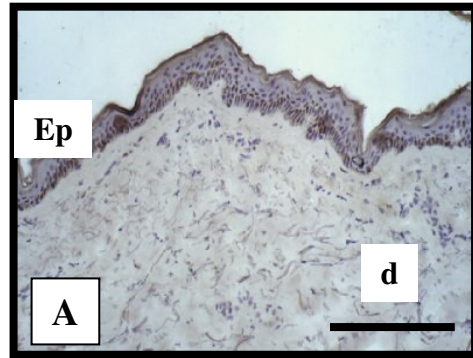


Figure 7

CONTROL



VARICOSE

