



## Tissue expression and plasma levels of adrenomedullin in renal cancer patients

Jens Michelsen, Helle C Thiesson, Steen Walter, Peter D Ottosen, Ole Skøtt,  
Boye L Jensen

### ► To cite this version:

Jens Michelsen, Helle C Thiesson, Steen Walter, Peter D Ottosen, Ole Skøtt, et al.. Tissue expression and plasma levels of adrenomedullin in renal cancer patients. *Clinical Science*, 2006, 111 (1), pp.61-70. 10.1042/CS20060030 . hal-00479320

**HAL Id: hal-00479320**

**<https://hal.science/hal-00479320>**

Submitted on 30 Apr 2010

**HAL** is a multi-disciplinary open access archive for the deposit and dissemination of scientific research documents, whether they are published or not. The documents may come from teaching and research institutions in France or abroad, or from public or private research centers.

L'archive ouverte pluridisciplinaire **HAL**, est destinée au dépôt et à la diffusion de documents scientifiques de niveau recherche, publiés ou non, émanant des établissements d'enseignement et de recherche français ou étrangers, des laboratoires publics ou privés.

## **Tissue expression and plasma levels of adrenomedullin in renal cancer patients**

Jens Michelsen<sup>1</sup>, Helle Thieson<sup>1</sup>, Steen Walter<sup>2</sup>, Peter D. Ottosen<sup>3</sup>, Ole Skøtt<sup>1</sup>, Boye L. Jensen<sup>1</sup>

<sup>1</sup>*Department of Physiology and Pharmacology, University of Southern Denmark, DK-5000 Odense, Denmark*

<sup>2</sup>*Department of Urology, Odense University Hospital, DK-5000 Odense, Denmark*

<sup>3</sup>*Department of Pathology, Odense University Hospital, DK-5000 Odense, Denmark*

### Running title

*Adrenomedullin in renal cancer*

### Key words

Kidney, carcinoma, tumour marker, hypoxia, plasma

### Correspondence

Boye L. Jensen, MD, PhD.

Dept. of Physiology and Pharmacology

University of Southern Denmark

Winsløwparken 21, 3.

DK-5000, Odense C

D E N M A R K

Telephone +45 65 50 37 96

FAX +45 66 13 34 79

**ABSTRACT**

The peptide adrenomedullin (AM) is stimulated by hypoxia through Hypoxia Inducible Factor 1 (HIF-1). The majority of human clear cell renal cell cancers (CC-RCC) display mutations in the tumour suppressor protein von Hippel-Lindau, which leads to constitutively elevated HIF-1. We hypothesized that AM is increased in CC-RCC tumours and that AM is a plasma biomarker for CC-RCC. Tumours and non-malignant kidney tissue were obtained from patients that underwent unilateral nephrectomy. Blood samples were drawn at the day of surgery, 3-6 days after and 4-5 weeks after surgery. We determined AM mRNA and peptide expression in tissue and AM plasma concentration. HIF-1 $\alpha$  was localized in tissue by immunohistochemistry. AM mRNA was elevated in CC-RCC compared to adjacent renal cortex (6-fold, n=18, P<0.02). There was no difference in AM mRNA between cortex and non-CC-RCC tissue (n=7). AM peptide concentration was elevated in CC-RCC tissue compared to adjacent cortex (4-fold, n=6, P<0.02), while there was no difference between cortex and non-CC-RCC tissue (n=5). HIF-1 $\alpha$  immunoreactivity was detected in the majority of cell nuclei in 76% of CC-RCC compatible with constitutive stabilization. In non-CC-RCC, HIF-1 $\alpha$  staining was focal. Before surgery there was no difference in plasma AM concentration between tumour types. Nephrectomy increased plasma AM significantly after 3-6 days and similar presurgery level was observed after 4-5 weeks in both groups of tumor patients. We conclude that elevated tissue AM is a distinguishing feature of CC-RCC compared to other kidney tumours. Plasma AM is not suited as a tumour marker for this disease.

## INTRODUCTION

The vasodilator peptide adrenomedullin (AM) was discovered in pheochromocytoma cell extracts by its ability to initiate cAMP production in target cells [1]. AM is now considered as a paracrine factor associated with states of cellular growth and is expressed in various human malignancies [2]. AM is stimulated by hypoxia [3] under control of the basic-helix-loop-helix transcription factor, Hypoxia Inducible Factor-1 (HIF-1) [4]. HIF-1 is found in several types of common human cancers in a pattern compatible with reactive hypoxic induction e.g. at the margins of necrotic areas in solid tumours or at the invading margins. However, in certain tumours, primary genetic alterations may be involved in the activation of HIF and its target genes rather than microenvironmental stimuli. Thus, 50-75 % of sporadic clear cell renal cell carcinomas (CC-RCC), the most common RCC type, displays biallelic loss-of-function mutations in the tumour-suppressor gene von-Hippel-Lindau (*VHL*) [5]. In the presence of oxygen, VHL is crucial for ubiquitin-mediated targeting of constitutively transcribed HIF-1 $\alpha$  to proteasomal degradation [6]. Indeed, in the vast majority of CC-RCC tumours with *VHL* mutations, HIF-1 $\alpha$  mRNA level is not changed while HIF-1 $\alpha$  protein is elevated significantly [7]. In these tumors, there is a close correlation between level of HIF-1 $\alpha$  protein and HIF-target gene products, e.g. vascular endothelial growth factor (VEGF) [7]. Based on these findings we hypothesized that AM would be constitutively up-regulated in solid kidney tumours of clear cell type. The proposal was tested in human tumour tissue from nephrectomy samples. CC-RCC is an obvious target for better approaches to early detection of disease. AM is not stored in cells but constitutively released at a rate that reflects transcription and translation. Since AM is expected to be elevated constitutively in all tumor cells in CC-RCC, we speculated that AM could be a potential serum marker for CC-RCC disease compared to other histological types of human renal and non-renal cancer. In the present study, we validated commercial immunoassays for the detection of AM in plasma and applied them to samples of patient plasma. Measurements were done in consecutive pre- and postsurgery samples of blood plasma from patients with CC-RCC and other renal neoplastic and non-neoplastic diseases.

## **Materials and Methods**

### **Subjects and design of study**

The study was approved by the Institutional Review Board-Ethical Committee (Approval No 20010035). All patients gave informed written consent to the use of tissue from the extirpated kidney and collection of blood samples. All samples in this study were obtained from randomly selected patients who underwent unilateral total nephrectomy for renal cancer at the Department of Urology, Odense University Hospital. Blood samples were obtained also in 6 patients who underwent nephrectomy for reasons other than malignant disease. The pathological profiles of the patients who participated with consecutive blood samples are presented in table 1. Before the blood sampling protocol began, several other patients had donated nephrectomy specimens.

### **Collection of human blood and renal tissue samples**

Antecubital venous blood was collected into cooled vacuum tubes containing ethylenediaminetetraacetic acid (EDTA) and transferred to tubes with aprotinin. The samples were then centrifuged at 1500g for 15 minutes at 4°C and separated plasma was stored at -80°C until assay. The first blood sample was obtained on the morning of surgery. The second was taken 3-6 days after surgery and the third was collected 4-5 weeks after surgery. Immediately after removal, the kidney was transported to the Department of Pathology. A nephro-pathologist excised a portion of the tumour and normal tissue from the same kidney. Normal tissue was only collected from specimens where a segment of normal tissue, including both cortex and an intact papilla, was present. The normal tissue was dissected into cortex and medulla. All tissue samples were frozen in liquid nitrogen and stored at -80°C. For histological analysis, a tissue block of the border zone between tumour and non-malignant kidney was fixed in 4% formaldehyde for 24 h and then embedded in paraffin. Tumours were diagnosed and classified according to the WHO classification [8].

### **Extraction of RNA and protein from kidney tumour and normal tissue**

Total RNA was extracted from tumours and adjacent non-malignant renal cortex by using the RNeasy Midi Kit (Qiagen). Protein was isolated by homogenisation of 200-

250 mg tissue in lysis buffer (1 mM Tris-NaOH, 10 mM EDTA, 1 mM DTT with a protease inhibitor mix “complete” (Roche Diagnostics GmbH) at pH 7.2. Then 10 µl Triton X-100 (10%) was added followed by centrifugation at 13000 rpm. The supernatant was removed and centrifuged again at 13000 rpm. Protein concentration was measured using a Biorad protein assay. Duplicate samples were diluted and compared to a BSA standard curve using spectrophotometry (Cary 50 Scan, Merck). Aliquots were stored at -80°C.

### **RT-PCR and cloning of PCR products**

Human kidney RNA and clear cell tumour RNA (1 µg) was reverse transcribed and 50 ng cDNA was used as template for amplification by PCR as described [9]. The following DNA oligonucleotides were used for amplification (Invitrogen): VEGF sense 5'-TCC GAA ACC ATG AAC TTT-3', antisense 5'-TCC ACC AGG GTC TCG ATT-3', covering bases 693-880, 188bp, genebank acc no nm003376; HIF1- $\alpha$  sense 5'-ACC GAT TCA CCA TGG AGG-3', antisense 5'-TCC AAA TCA CCA GCA TCC-3' covering bases 254-500, 257 bp, genebank acc no. nm001530. Primers were synthesized with restriction sites in the 5' direction for BamHI (sense) and EcoRI (antisense). PCR products were subcloned in plasmid pSP73 (Promega) and sequenced as previously described [9]. A fragment of human AM cDNA (310 bp) has previously been cloned and sequenced [10].

### **Ribonuclease Protection Assay (RPA) for AM, VEGF and HIF-1 $\alpha$ mRNAs**

Ribonuclease protection was performed as described [9]. In addition to AM, VEGF mRNA was determined as a positive control for CC-RCC [7]. HIF-1 $\alpha$  is stable at the mRNA level in malignant tissue and normal kidney cortex and it was used as a control of RNA quality and loading [7]. First, experiments were done to assure surplus of probes and to elucidate the linear range of assays and feasibility of detecting all three mRNAs in one sample. 28 patient RNA samples could be analysed simultaneously on one gel. RNA from matched samples of tumour and non-malignant renal cortex from one patient was always analysed on the same gel, each in duplicate. Thus, 4 wells were occupied by RNA from one patient and 7 different patients were analysed in each assay. The duplicates consisted of 10 and 20 µg or, when possible, 20 and 40 µg of total RNA.

By using this design it was possible to calculate the fold change of the relevant mRNA in the tumour compared to the adjacent cortex for each patient and thereby compare different assays. Protected probes were separated by urea-PAGE for 2 h and quantitated as described [9].

### **Extraction of plasma**

Because of reported inaccuracy and poor validity in commercial assays for AM [11,12], we validated two commercial assays for detection of human AM in plasma: 1) a radioimmunoassay (RIA) from DRG Diagnostics (Marburg, Germany) involving a plasma extraction procedure and 2) an immunoradiometric assay (IRMA) (Shionogi & Co, Japan) with no plasma extraction [13]. Plasma was extracted using Sep-Pak C18 cartridges (Waters) and various protocols were tested: manufacturers, (extraction 2); extraction 1, which is regularly used in our laboratory, and extractions 3a and b used to detect AM previously by others [11]. Samples were acidified or, alternatively, a buffer was added and they were applied to the conditioned Sep-Pak cartridges. After washing the cartridges, the samples were eluted using a strong solvent. The samples were collected in tubes containing Triton X-100 and evaporated to dryness under a stream of air in a 25°C water bath overnight.

### **Immunoassays for AM**

The radioimmunoassay (DRG Diagnostics, Germany) had a reported detection range of 1-128 pg/tube ( $\approx 0.17$ -21 fmol/tube;  $M_w$  AM 6029 g/mol) and used a polyclonal antibody which does not discriminate between active, mature AM, mAM, and the intermediate inactive form of glycine extended AM, AM-Gly [13]. The immunoradiometric assay (Shionogi & CO., Ltd, Japan) measured total AM (mAM+AM-Gly) and use two monoclonal antibodies against different regions of human AM. The assay had a detection range of 2-500 fmol/ml and did not require extraction of plasma. All procedures were conducted according to manufacturer's instructions. Final samples in both kits were counted in a gamma counter (Cobra TM, Auto Gamma, Packard).

### **Assay characteristics**

Plasma extraction protocols were evaluated by measuring recovery and precision by within-assay and between assays coefficients of variation. Accuracy was determined by measuring linearity of serially diluted plasma samples. Recovery was determined by adding 45.5 fmol/ml (Shionogi) or 49.8 fmol/ml (Phoenix Pharmaceuticals) exogenous AM to a plasma sample from a healthy human volunteer. Hot recovery was measured by applying an amount of  $^{125}\text{I}$ -labelled AM corresponding to 10200 counts per minute (cpm) to the Sep-Pak C18 cartridges.

### **Immunohistochemistry**

Tumour tissue was fixed in 4% formaldehyde at 4°C for at least 24 hours, dehydrated and embedded in paraffin by standard procedures. 4 µm sections were mounted on glass slides. All sections were stained under the same conditions with a specific anti-AM antibody (Phoenix Pharmaceuticals, H-010-01, Lot R-125-3) as described [10]. Staining for HIF-1 $\alpha$  was done basically as described [7] using anti-human HIF-1 $\alpha$  antibody (clon 67, NB 100-123, Novus Biologicals) at a dilution of 1:1000. Antigen retrieval was done by pressure cooking for 10 min with DAKO target retrieval solution (S1599) and the Catalyzed Signal Amplification (CSA) System was used (DAKO). Light counterstain with hematoxylin was used. Negative controls were performed using 5% dry milk and non-immune mouse IgG for amplification. Two investigators independently evaluated the labeled sections in a blinded fashion. We adopted the method of Zhong et al. [14] to score the tumor sections as follows: -, no staining, + nuclear staining in less than 1% of cells, ++, nuclear staining in 1-10 % of cells, +++ nuclear staining in 10-50% of cells and ++++, nuclear staining in more than 50 % of cells. When scoring of a sample differed the section was re-evaluated by both reviewers simultaneously. Sections were inspected in a BX51 Olympus microscope.

### **Statistics and Data Presentation**

Data obtained on mRNA expression and peptide concentration in paired samples of tumour and normal cortex were evaluated using the one-sample t-test on average tumour/cortex ratio. The null hypothesis was that there was no difference between cortex and tumour in which case the hypothetical ratio would be 1. Data obtained by consecutive plasma sampling in the same patient were evaluated by t-test for paired

observations. When two independent groups were compared (e.g. healthy controls and patients with malignant kidney disease) Student's t-test was used to evaluate the level of statistical significance.  $P < 0.05$  was considered significant. Values are expressed as mean  $\pm$  SEM.

## RESULTS

### Patient characteristics

A total of 25 patients were examined by 3 consecutive blood samples before and after nephrectomy, 19 with malignant kidney disease, (Table 1). Plasma creatinine was within the normal range before surgery ( $98.5 \pm 3.5$   $\mu\text{mol/L}$  mean  $\pm$  SE) and increased significantly 2-3 days after nephrectomy when data from all patients were pooled ( $114.5 \pm 4.8$   $\mu\text{mol/L}$ ,  $n=20$  paired observations,  $P<0.02$  paired t-test). Renography was done in all patients before surgery and showed that in patients with malignant renal disease, the kidneys did not display similar function (table 1,  $P<0.01$ ,  $n=18$ , paired t-test). The affected kidney had the lowest performance. In 6 patients who underwent nephrectomy for non-malignant indications, this difference was more pronounced (table 1,  $P<0.001$ ,  $n=6$ , paired t-test). There was no significant difference in blood pressure between patients with CC-RCC and non-CC-RCC (mean systolic in mmHg:  $153 \pm 7$  vs.  $152 \pm 8$ , diastolic:  $90 \pm 8$  vs  $85 \pm 4$ ) but patients with neoplastic disease exhibited systolic hypertension compared to the patients without neoplastic renal disease (mean systolic:  $152 \pm 5$  mmHg vs.  $128 \pm 8$  mmHg,  $p<0.02$ , diastolic:  $87 \pm 3$  mmHg vs  $80 \pm 6$  mmHg).

### AM, HIF-1 $\alpha$ and VEGF mRNA expression in homogenates of human renal tumours and adjacent cortex tissue

Cloned cDNAs matched the published sequences between 96-100%. There was a linear relationship between the assayed quantity of total RNA (5-40  $\mu\text{g}$ ) and protected radioactivity in all three hybridisation products, both when one probe was applied in one RNA sample and when all three probes were added simultaneously in one sample (Figure 1). This indicates that the probe was present in surplus. Hybridisation products displayed the expected molecular size and in the absence of template RNA, probes were completely digested whereas in the absence of RNase, probes remained intact (Figure 1). In CC-RCC patients, average AM mRNA ratio between tumor and adjacent non-malignant renal cortex was significantly higher than 1 ( $P<0.02$ , paired t-test) (Figure 2). Of note, in 4 of the 18 CC-RCC tumors analyzed the AM ratio was at or below 1.5 indicating no significant difference. In non-CC-RCC, there was no difference in AM mRNA level when the tumor tissue was compared to adjacent renal cortex (Figure 2).

VEGF mRNA level was also significantly increased in CC-RCC compared to adjacent non-malignant renal cortex ( $P < 0.001$ , paired t-test), but was not significantly different in non-CC-RCC tissue compared to adjacent renal cortex (Figure 2). As previously shown [7], HIF-1 $\alpha$  mRNA level was similar in all samples investigated, malignant and adjacent cortex tissues, which documented similar quality and loading of RNA.

### **Validation of AM peptide assays**

A radioimmunoassay kit from DRG Diagnostics was applied first and different extraction procedures were tested in an attempt to optimise the results (table 2). Extraction procedure 2 gave no meaningful results (not shown) and extraction procedures 1 and 3 exhibited low recoveries of added AM, displayed high between assay and intraassay variation and non-linear dilution curves with low accuracy (table 2). Thus, despite continuous dilution, AM was detected at similar concentrations. Hot recovery was comparably better, which indicated that the extraction procedure was effective but that downstream assay detection was not quantitative. The assay was therefore discarded. The IRMA kit did not require extraction and exhibited far better performance (table 2). Assay accuracy was demonstrated by the linearity of AM concentrations measured in serially diluted plasma samples (table 2). The assay exhibited low within-assay and between-assay coefficients of variation, that corresponded to values given by the manufacturer, both with control plasma ( $n=5$  within assay and  $n=8$  between assays) and with plasma spiked with 45.5 fmol/ml of exogenous AM ( $n=5$  within,  $n=9$  between assays) (table 2). Recovery was excellent with AM peptide from Shionogi, but not from a different manufacturer (table 2).

Assay validity for tissue homogenates was tested. Post-homogenisation recovery was between 33.7% and 46.7% but pre-homogenisation recovery was only found to be between 5.7% and 7.9%. Between and within CV was not measured for the tissue homogenates because of limited tissue availability.

### **AM peptide content in homogenates of renal tumour tissue and adjacent renal cortex**

AM peptide concentration was determined by IRMA in tissue homogenates and normalized for protein concentration. Figure 3A shows the absolute values from all

tissue samples analysed. There was no difference in AM content between normal adjacent cortices from kidneys with CC-RCC and non-CC-RCC and values were therefore pooled. There was a significantly higher AM concentration in homogenates from CC-RCC compared to non-malignant renal cortex (Figure. 3A,  $P < 0.02$ , unpaired t-test).. There was no significant difference in AM concentration between cortex and non-CC-RCC homogenates (Figure 3A). In a number of cortex samples the AM concentration was below the detection limit of the assay while AM in tumor was detectable. In those paired tissue homogenates where AM could be detected both in cortex and tumour the tumour/cortex AM concentration ratio was calculated. The AM ratio was significantly higher than 1 in CC-RCC but not in non-CC-RCC ( $P < 0.006$ , paired t-test, Figure 3B).

#### **Pre- and post-nephrectomy plasma concentration of AM in patients with renal tumours.**

Average plasma concentration of total AM (AM-Gly+mAM) in 8 healthy human control persons was  $8.14 \pm 0.72$  fmol/ml (range 5.37 to 11.20 fmol/ml; 4 male, 4 female, median age 37). Before nephrectomy, there was no difference between total AM plasma concentration in patients with CC-RCC (median age: 69,  $n=9$ ) compared to patients with a renal tumour of a different histological classification (median age: 65,  $n=10$ ) (Figure 4). Pre-surgery plasma AM concentration in all patients with malignant renal tumours was  $12.8 \pm 0.9$  ( $n=20$ ), which was significantly higher than in healthy control persons ( $P \leq 0.004$ , unpaired t-test). 3-6 days after surgery there was a significant increase in plasma AM level in both groups of tumour patients (CC-RCC:  $P < 0.05$ , non-CC-RCC:  $P < 0.005$ , paired t-tests). After 4-5 weeks, plasma AM concentration was not statistically different from presurgery level in the nephrectomized patients (Figure 4).

We measured plasma AM in 6 patients who underwent unilateral nephrectomy for indications other than malignant kidney disease (median age 48 years, Table 1). Pre-surgery AM concentration was  $15.6 \pm 3.1$  which was significantly higher than in healthy controls ( $P \leq 0.02$ , unpaired t-test). Plasma AM 3-6 days after surgery was  $24.1 \pm 3.9$  and  $15.9 \pm 1.9$  after 4-5 weeks. These values of plasma AM were not significantly different from presurgery levels (paired t-test).

**Immunohistochemical labelling of renal tumour tissue for AM and HIF-1 $\alpha$** 

A series of renal tumour samples were labelled for AM by immunohistochemistry (total n=33; CC-RCC n=25, papillary RCC n=1; urothelial carcinoma n=3; angiomyolipomas n=2; oncocytoma n=2, Figure 5). No obvious differences in staining intensity were found between the different tumour types. Thus, AM was detected in the cytoplasm of tumour cells in the vast majority of CC-RCC samples while little if any staining was associated with the stroma (Figure 5A) but most non-clear cell tumors also displayed a variable degree of AM-positive tumour cells. Of note, AM-labelled tumour cells were homogenously distributed in CC-RCC tissue (Figure 5A, B). In the adjacent non-malignant renal tissue, AM was associated with distal tubules (Figure 5D) and collecting ducts regardless of the type of malignancy. In the absence of primary AM antibody, no labelling was detected (Figure 5C).

Randomly selected CC-RCC tumors (n=17) and non-CC-RCC tumors (n=12) were stained for HIF-1 $\alpha$  in order to ascertain correct diagnosis of CC-RCC tumors and to compare the pattern of distribution with non-CC-RCC. Normal kidney tissue displayed very little staining for HIF-1 $\alpha$  and in several samples, no signals were detectable (Figure 6D). In some cases HIF-1 $\alpha$  immunoreactive protein was observed in normal tissue adjacent to the invading tumor (Figure 6H). In sharp contrast to normal kidney tissue, 13 of 17 (76%) of clear cell tumors exhibited homogenous strong labeling (+++ and +++) that was associated with tumor cell nuclei (Figure 6A, B). In CC-RCC, localization of HIF-1 $\alpha$  positive cells did not depend on position within the tumor e.g. at margins, in cysts or close to vessels (Figure 6A, B). Incubation with unspecific mouse IgG or omission of primary HIF-antibody did not result in labeling of CC-RCC despite the regular use of signal amplification (Figure 6C). Immunostaining for HIF-1 $\alpha$  in tumors diagnosed as non-CC-RCC was heterogenous and sparse (Figure 6E-G). HIF-1 $\alpha$  labeling was associated with cell nuclei that typically accumulated at sites associated with necrosis or inflammatory cell infiltrates (Figure 6E) or at the invading margin (Figure 6F, transitional RCC). In renal papillary tumors, HIF labeling was typically associated with single cells in the wall of intratumoral cysts whereas the bulk of tumor cells was negative (Figure 6G). Non-CC-RCC received low scores (all were + and ++) indicating that the estimated number of HIF-positive nuclei was below 10 % in all 12 investigated samples.

## Discussion

In the current study we tested the hypotheses that the vasodilator peptide adrenomedullin (AM) is constitutively elevated in clear cell-renal cell cancer (CC-RCC) tissue and that AM is a plasma marker for CC-RCC disease. The data showed that AM mRNA and protein was significantly and selectively elevated in CC-RCC tumours compared to adjacent renal cortical tissue. 76 % of CC-RCC displayed strong homogenous nuclear labeling for HIF-1 $\alpha$  while none of the examined non-CC-RCC showed this pattern of HIF-distribution. Plasma AM concentration was significantly increased in patients with renal malignant disease compared to a group of healthy controls. Plasma AM in patients with CC-RCC was not different from that in patients with other renal malignant tumours. Rather than the decrease in plasma AM predicted by the hypothesis, we observed that nephrectomy led to a significant increase in plasma AM concentration in all patient groups 3-6 days after surgery. Plasma AM subsequently stabilized at presurgery levels 4-5 weeks after nephrectomy.

The present and previously published [11,12] findings of unreliable detection of AM in plasma by immunoassays indicate that commercial assays should be subjected to rigorous validation before general use in clinical settings. Assay accuracy is vital because AM is known as a “sticky” peptide and most reported changes in plasma AM are of small magnitude. We found that the IRMA kit for total AM performed far better than the RIA and was valid and reproducible on all tested criteria. We are not aware of previous studies on plasma AM concentration in renal cancer patients. Plasma AM is elevated in patients with lung cancer and gastrointestinal cancers [15], while it is not different from control in patients with breast cancer [16]. Because localized hypoxia is an inherent property of most solid tumours, it is not surprising that plasma AM is elevated in many common cancer types. We observed that plasma AM was also elevated in 6 patients admitted for nephrectomy but without malignant disease. A common denominator for the patients that underwent nephrectomy was impaired function of the affected kidney as indicated by renography. Renal impairment is associated with increased plasma AM concentration [17] but judged from plasma creatinine concentration overall renal function was not affected differently in the patients. 4-5 weeks after nephrectomy, plasma AM was still significantly higher than in healthy controls. This indicates that the elevated AM level is not related to the diseased

kidney. Systolic blood pressure was significantly higher in patients with renal cancer compared to patients admitted for nephrectomy without neoplastic disease but AM was elevated equally in both groups. It is not clear which mechanism that underlies the elevated plasma AM in the group of nephrectomized patients.

Most sporadic CC-RCCs (50-70%) exhibit mutations in the von Hippel-Lindau tumour suppressor gene [5, 7]. We did not perform mutational analysis for VHL in the present study but relied on classical pathological criteria. The tissue and plasma measurements of AM showed very little variation. Thus, it is unlikely that a subgroup of patients diagnosed as “clear cell”, but without VHL mutations, display markedly different AM concentrations in plasma. In support of correct pathological diagnosis, the majority of clear cell tumors in the present study displayed uniform nuclear labeling for HIF-1 $\alpha$  throughout the tumor and VEGF mRNA was selectively elevated in these tumors. Both features are consistent findings in CC-RCC tumors with *VHL* mutations [7,18]. Only clear cell carcinomas exhibited elevated AM mRNA and peptide levels compared to normal kidney cortex. In a previous study, Fujita *et al.* [18] found very similar changes in AM and VEGF mRNAs in CC-RCC tumours by PCR analysis. Together, the findings support the concept that constitutively elevated HIF is crucial for increased expression of an array of hypoxia-controlled gene products, including AM, in CC-RCC with *VHL* mutations [7]. There are several ways that AM overexpression could affect growth of CC-RCC. AM is a direct growth factor for certain tumor cells [19], it inhibits apoptosis [20] and promotes angiogenesis [21]. In CC-RCC, AM correlates with vascular density and could be important for tumor angiogenesis in this highly vascularized tumor type [18]. AM is significantly expressed in normal kidney and is associated with distinct nephron segments and the collecting duct system and urothelium lining the urinary tract [10]. This indicates that renal AM expression is not controlled by hypoxia and/or HIF only and could be one reason that non-CC-RCC also display immunohistochemical staining for AM. AM therefore appears less suited to discriminate in an “all or none fashion” between non-CC-RCC and CC-RCC at the level of immunohistochemistry. Only quantitative measurements of AM in tumor tissue extracts document a significant difference between CC-RCC and non-CC-RCC. The significant higher level of AM mRNA and peptide in CC-RCC prompted us to test its use as a serum marker. Plasma AM increased acutely after excision of kidney and

tumour. There is no clearly defined organ source of AM in plasma under normal conditions [22]. The rise in plasma AM could be related to surgical manipulation of AM-rich tumours, or the adrenal, or to general surgical stress. Major surgical stress has been shown to elevate plasma AM concentration strongly during the operation and in the first days after surgery [23]. For this reason we included the second measurement of AM 4-5 weeks after surgery. After major surgery, AM stabilizes after 1 week [23]. However, the finding that AM had not decreased significantly below pre-surgery levels after 4 weeks precludes its use as a specific marker for CC-RCC disease. The only condition where consecutive determinations of plasma AM has been reported to reflect the presence of a tumour is pheochromocytoma. One study reported a dramatic decrease in plasma AM after adrenalectomy [24] whereas no difference in plasma AM was recorded in a second study of similar patients [25]. Thus, there are no well established conditions where AM could be used as a serum marker for the presence of tumour tissue at present. In summary, our findings show that HIF-1 $\alpha$  and the HIF-target gene products AM and VEGF are elevated in clear cell renal cancer tissue compared to other renal tumour types. Plasma AM is not a specific marker for clear cell renal cell carcinoma.

## **ACKNOWLEDGEMENTS**

The study was supported by The Danish Health Science Research Council, The Danish Cancer Foundation, A.J. Andersen og Hustrus Foundation, Else Poulsen's Foundation, Jens C. Christoffersen's Foundation, and Johannes Fogh's Foundation. We acknowledge excellent technical assistance from Lis Teusch and Bodil Kristensen. Peter Bie is thanked for valuable advice regarding assay validation and Anthony Carter for linguistic advice.

**Table 1.** Characteristics of the patient cohort that was examined with consecutive collection of blood plasma before surgery, 3-6 days after surgery and 4-5 weeks after surgery. BP: Systolic/diastolic blood pressure before surgery. RCC: renal cell carcinoma. C: carcinoma. The ratios shown under “renography” denote the estimated contribution of right/left kidney to overall renal function in percent. \*: affected kidney that was excised. N.a.: not available.

Pt. No.	Gender	Age years	BP mmHg	Pathological diagnosis- WHO criteria	Renography %
1	M	69	140/90	Clear cell-RCC	57/43*
2	F	79	125/80	Clear cell-RCC	58/42*
3	F	63	125/70	Clear cell-RCC	48/52*
4	M	60	144/75	Clear cell-RCC	*0/100
5	F	69	169/91	Clear cell-RCC	*34/66
6	M	63	175/95	Clear cell-RCC	n.a
7	M	70	169/109	Clear cell-RCC	48/52*
8	M	71	130/60	Clear cell-RCC	71/29*
9	M	44	150/85	Clear cell-RCC	n.a
10	F	49	120/80	Angiomyolipoma	*39/61
11	M	74	140/87	Angiomyolipoma	*47/53
12	M	37	135/75	Papillary-RCC	*49/51
13	M	62	134/90	Papillary-RCC	*28/72
14	M	73	167/103	Infiltrating urothelial C	*30/70
15	M	41	130/85	Infiltrating urothelial C	50/50*
16	M	68	147/80	Infiltrating urothelial C	*30/70
17	F	77	195/100	Infiltrating urothelial C	87/13*
18	M	81	180/70	Infiltrating urothelial C	*47/53
19	F	56	170/90	Cystic Nephroma	*36/54
20	F	50	159/99	Nephroureterolithiasis	*6/94
21	F	54	140/80	Nephrolithiasis, coral stone	88/12*
22	F	46	114/75	Nephrolithiasis, cyst	*43/57
23	M	35	125/95	Nephrolithiasis, coral stone	*6/94

24	M	52	110/60	Chronic inflammation	*10/90
25	F	35	120/70	Kidney cyst	*2/98

**Table 2.** Comparison of commercial immunoassays for AM with and without extraction procedures. N.d: not determined. Numbers of repeated measurements are indicated in the text. CV: Coefficient of variation. Recovery was determined with exogenous AM peptide from various suppliers as indicated.

	<b>Shionogi kit</b>	<b>DRG kit extraction 1</b>	<b>DRG kit extraction3a</b>	<b>DRG kit extraction3b</b>
Recovery % (Phoenix AM)	35.1	6.4	32	31.7
Recovery % (Shionogi AM)	100.7	n.d.	n.d.	n.d.
Curve fit (r-value)	1	0.89	0.93	0.92
Within assay CV % (pool sample)	4.3	25	16.7	21.7
Within assay CV % (pool spiked with AM)	3.2	18.2	6.8	11
Between assay CV % (pool sample)	8.3	35.9	n.d	n.d
Between assay CV % (pool spiked with AM)	9.8	n.d	n.d	n.d
Hot recovery	n.d	84.1	83.5	79.1

## References

1. Kitamura, K., Kangawa, K., Kawamoto, M. et al. (1993) Adrenomedullin: A Novel Hypotensive Peptide Isolated From Human Pheochromocytoma. *Biochem. Biophys. Res. Commun.* 192, 553-560
2. Martinez, A., Miller, M.J., Unsworth, E.J., Siegfried, J.M., Cuttita, F. (1995) Expression of Adrenomedullin in normal human lung and in pulmonary tumors. *Endocrinology*. 136, 4099-5105
3. Nguyen, S.V., Claycomb, W.C. (1999) Hypoxia regulates the expression of the adrenomedullin and HIF-1 genes in cultured HL-1 cardiomyocytes. *Biochem. Biophys. Res. Commun.* 265, 382-386
4. Garayoa, M., Martinez, A., Lee, S. et al. (2000) Hypoxia-Inducible Factor 1 (HIF-1) Up-Regulates Adrenomedullin Expression in Human Tumor Cell Lines during Oxygen Deprivation: A Possible Promotion Mechanism of Carcinogenesis. *Mol. Endocrinol.* 14, 848-862
5. Sufan, R.I., Jewett, M.A., Ohh, M. The role of von Hippel-Lindau tumor suppressor protein and hypoxia in renal clear cell carcinoma. (2004) *Am. J. Physiol. Renal. Physiol.* 287, F1-F6
6. Jaakkola, P., Mole, D.R., Tian, Y.M., et al. (2001) Targeting of HIF- $\alpha$  to the von Hippel-Lindau ubiquitylation complex by O<sub>2</sub>-regulated prolyl hydroxylation. *Science* 292, 468-472
7. Wiesener, M.S., Munchenhagen, P.M., Berger, I., et al. (2001) Constitutive activation of hypoxia-inducible genes related to overexpression of hypoxia-inducible factor1 $\alpha$  in clear cell renal carcinomas. *Cancer Res.* 61, 5215-5222
8. Eble, J.N., Sauter, G., Epstein, J.I., Sesterhenn, I.A., Eds. (2004) World Health Organization Classification of Tumors. Pathology and Genetics of Tumours of the Urinary System and Male Genital Organs, *IARC Press*, Lyon.
9. Andreasen, D., Jensen, B.L., Hansen, P.B., Kwon, T.H., Nielsen, S., Skott, O. (2000) The  $\alpha$  (1G)-subunit of a voltage-dependent Ca(2+) channel is localized in rat distal nephron and collecting duct. *Am. J. Physiol. Renal Physiol.* 279, F997-F2005

10. Sandner, P., Hofbauer, K., Tinell, H., et al.(2004) Expression of Adrenomedullin in Hypoxic and Ischemic Rat and Human Kidneys with arterial stenosis. *Am. J. Physiol. Regul. Integr. Comp. Physiol.* 286, R942-951
11. Lewis, L.K., Smith, M.W., Yandle, T.G., Richards, A.M., Nicholls, G. (1998) Adrenomedullin (1-52) measured in human plasma by radioimmunoassay: plasma concentration, adsorption, and storage. *Clin. Chem.* 44, 571-577
12. Gülberg, V., Liss, I., Gerbes, A.L. (2000) Determination of Plasma Adrenomedullin Concentrations With Commercial Radioimmunoassay Kits: A Note of Caution. *Liver Transplantation.* 3, 384-385
13. Ohta, H., Tsuji, T., Asai, S., et al. (1999) One-Step Direct Assay for Mature-type Adrenomedullin with Monoclonal Antibodies. *Clin. Chem.* 45, 244-251
14. Zhong, H., De Marzo, A.M., Laughner, E. et al. (1999) Overexpression of hypoxia-inducible factor 1alpha in common human cancers and their metastases. *Cancer Res.* 59: 5830-5835
15. Ehlenz, K., Koch, B., Preuss, P., Simon, B., Koop, I., Lang, R.E. (1997) High levels of circulating adrenomedullin in severe illness: correlation with C-reactive protein and evidence against the adrenal medulla as site of origin. *Exp. Clin. Endocrinol. Diabetes.* 105, 156-162
16. Oehler, M.K., Fischer, D.C., Orlowska-Volk, M. et al. (2003) Tissue and plasma expression of the angiogenic peptide adrenomedullin in breast cancer. *Br. J. Cancer.* 89, 1927-1933
17. Ishimitsu, T., Nishikimi, T., Saito, Y. et al. (1994) Plasma levels of adrenomedullin, a newly identified hypotensive peptide, in patients with hypertension and renal failure. *J. Clin. Invest.* 94, 2158-2161
18. Fujita, Y., Mimata, H., Nasu, N., Nomura, T., Nomura, Y., Nakagawa, M. (2002) Involvement of adrenomedullin in human renal cell carcinoma. *Int. J. Urol.* 9: 285-295
19. Miller, M.J., Martínez, A., Unsworth, E.J. et al. (1996). Adrenomedullin Expression in Human Tumor Cell Lines. *J. Biol. Chem.* 271: 23345-23351
20. Kato, H., Shichiri, M., Marumo, F., Hirata, Y. (1997) Adrenomedullin as an autocrine/paracrine apoptosis survival factor for rat endothelial cells. *Endocrinology* 138: 2615-2620

21. Zhao, Y., Hague, S., Manek, S., Zhang, L., Bicknell, R., Rees, M.C. (1998) PCR display identifies tamoxifen induction of the novel angiogenic factor adrenomedullin by a non estrogenic mechanism in the human endometrium. *Oncogene* 22: 409-415.
22. Nishikimi T, Kitamura K, Saito Y. et al. (1994) Clinical studies on the sites of production and clearance of circulating adrenomedullin in human subjects. *Hypertension*. 24: 600-604
23. Nishikimi, T., Hayashi, Y., Iribu, G. et al. (1998) Increased plasma adrenomedullin concentrations during cardiac surgery. *Clin Sci (Lond)*. 94:585-590
24. Letizia, C., Toma, G.D., Caliumi, C. et al. ( 2001) Plasma Adrenomedullin concentrations in patients with adrenal pheochromocytoma. *Horm. Metab. Res.* 33, 290-294
25. Minami, J., Nishikimi, T., Todoroki, M., et al. (2002) Source of plasma adrenomedullin in patients with pheochromocytoma. *Am. J. Hypertens.* 15, 994-997

## Figure Legends

### Figure 1.

Validation of ribonuclease protection assays for AM, VEGF and HIF-1 $\alpha$  mRNAs. Left panels display the result of 3 separate ribonuclease protection assays (RPA) in which increasing amounts of total RNA were hybridized with AM, VEGF and HIF-specific antisense RNA probes. Right panel shows the result of a similar ribonuclease protection assay where all three specific probes hybridized simultaneously in each RNA sample. The penultimate lane shows hybridization with 40  $\mu$ g yeast tRNA (negative control). The last lane shows cRNA probes. The graph displays the quantitative evaluation of the gels.

### Figure 2

Expression of AM, VEGF and HIF-1 $\alpha$  mRNAs in clear cell and non-clear cell renal tumours and adjacent nonmalignant cortex tissue.

Upper panels display the results of two separate ribonuclease protection assays where malignant tissue and nonmalignant cortex from individual patients were analyzed in duplicate (10 and 20  $\mu$ g or 20 and 40  $\mu$ g total RNA samples). CC-RCC: Clear cell renal cell cancer; T-RCC: Transitional cell cancer; P-RCC Papillary renal cell cancer; N: nonmalignant cortex, T: Tumour. Histogram shows ratios between AM, VEGF, and HIF-1 mRNA in tumours and in adjacent non-malignant renal cortex measured by ribonuclease protection assay. There was a significantly higher level of AM (\*:  $P < 0.02$ ) and VEGF (\*:  $P < 0.001$ ) mRNAs in CC-RCC compared to cortex, but not in non-CC-RCC. Values are means of individual patient ratios between tumour and nonmalignant tissue  $\pm$ SE.

### Figure 3

AM peptide concentration in clear cell and non-clear cell renal tumour tissue and adjacent kidney cortex tissue.

A. AM was determined by immunoradiometric assay (IRMA) in tissue homogenates.

AM level is shown as fmol/mg total protein in homogenates of nonmalignant cortex and

renal tumours. There was a significantly higher level of AM peptide in CC-RCC compared to adjacent non-malignant cortex and non-CC-RCC tumours. Values are means  $\pm$ SEM. \*:  $P < 0.02$

B. Ratio between AM peptide concentration in paired samples of tumours and adjacent non-malignant renal cortex measured by IRMA. There was a significantly higher level of AM in CC-RCC compared to cortex (\*:  $P < 0.02$ ). Values are means  $\pm$ SE.

#### Figure 4

Total AM (AM-Gly+mAM) concentration in plasma from patients with malignant disease of the kidney before and after nephrectomy.

There was no significant difference between plasma AM levels in patients with CC-RCC compared to patients with non-CC-RCC. Plasma AM increased significantly in both groups of patients 3-5 days after surgery (CC-RCC \*:  $P < 0.05$ , non –CC-RCC \*:  $P < 0.005$ ). 4-5 weeks after nephrectomy, plasma AM had returned to presurgery levels. Values are means  $\pm$ SE.

#### Figure 5

A-B. Immunohistochemical labeling of renal clear cell tumours for AM. The invading margin is seen. AM labeling is homogeneously associated with tumour cells. Inset in A shows larger magnification of typical tumour stroma, which is negative for AM, and AM-positive clear cells within the tumour.

C. In nonmalignant adjacent kidney cortex, AM labeling was associated with distinct tubules. Inset shows labeling of tubules close to glomeruli, most likely distal convoluted tubules.

D. Negative control, where primary antibody was omitted.

Bars represent 200  $\mu$ m.

#### Figure 6

Immunohistochemical analysis of HIF-1 $\alpha$  expression in kidney tumors.

Analysis of sections from: A-B, typical clear cell tumors (CC-RCC); C, CC-RCC negative control reacted with non-immune mouse IgG ; D, normal kidney cortex; E-F

transitional cell tumors, F shows the invading margin (upper left) and a HIF-1 $\alpha$ -positive collecting duct in adjacent renal medulla; G, Papillary renal cell cancer with few HIF-1 $\alpha$ -positive cells in the wall of a cystic structure; H, normal kidney medulla showing two collecting ducts and the papillary surface epithelium (lower left corner). Bars represent 50  $\mu$ m in all micrographs.

The diagram displays the result of a comparison of HIF-1 $\alpha$  immunohistochemical labeling distribution in non-CC-RCC tumors with CC-RCC. Tumors were scored in a blinded fashion by two independent observers as follows: -, no staining, + nuclear staining in less than 1% of cells, ++, nuclear staining in 1-10 % of cells, +++ nuclear staining in 10-50% of cells and ++++, nuclear staining in more than 50 % of cells. Columns represent the distribution of scores in percent of total number of tumors analyzed.

Figure 1

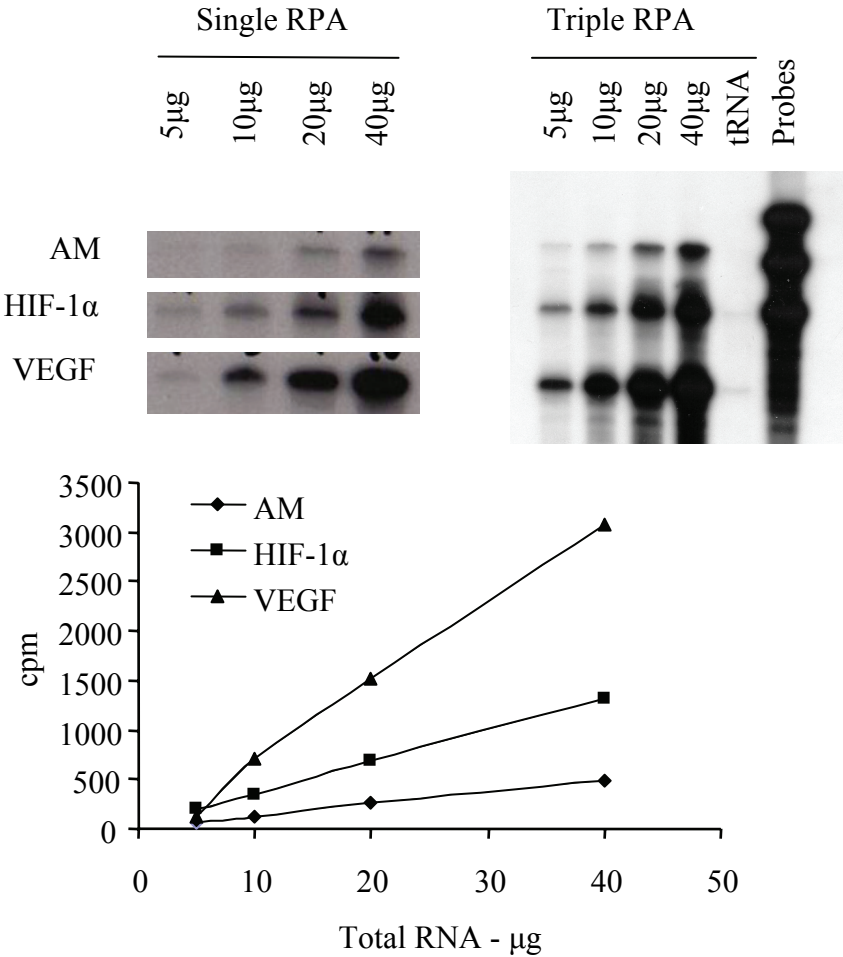


Figure 2

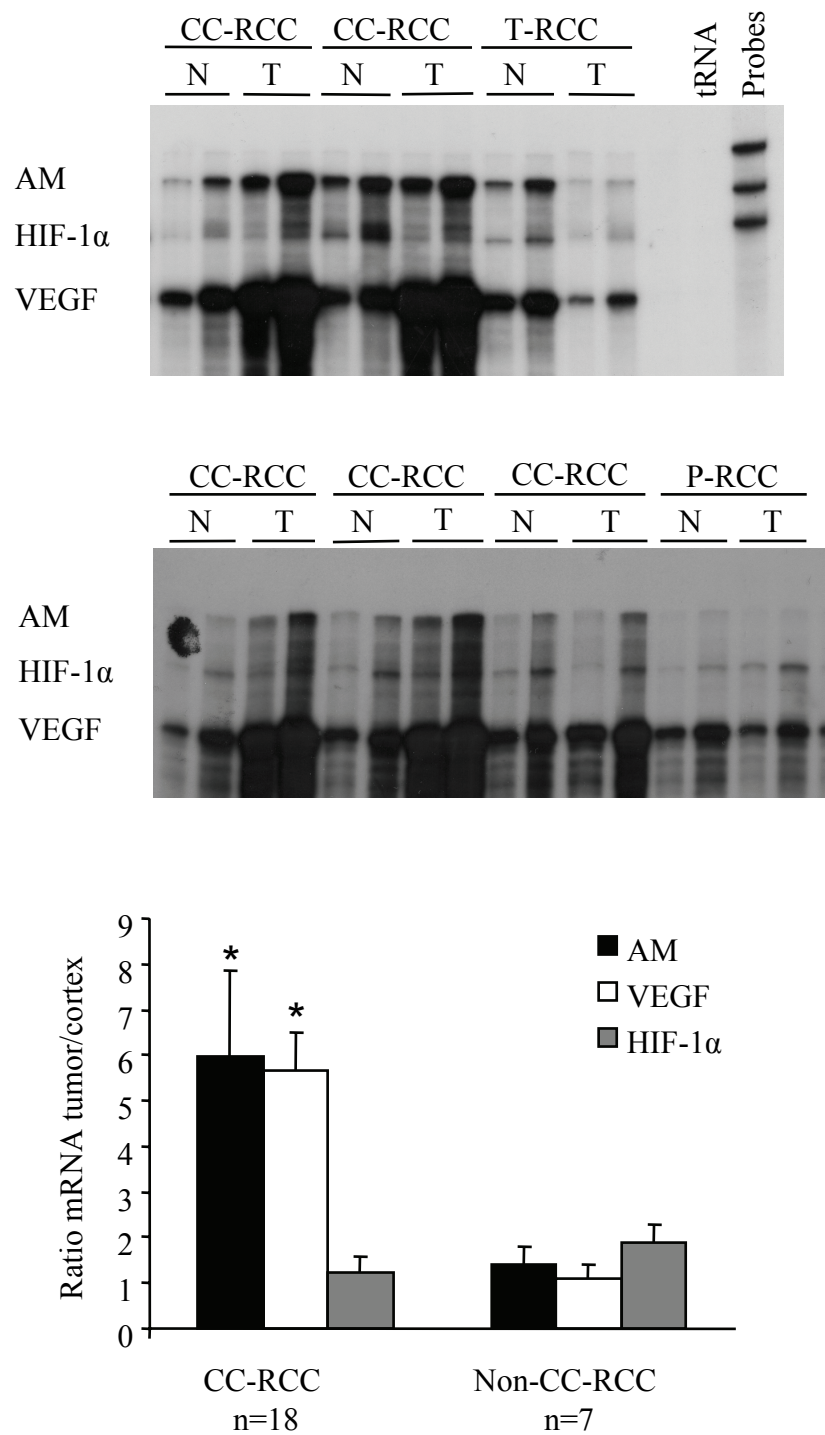


Figure 3

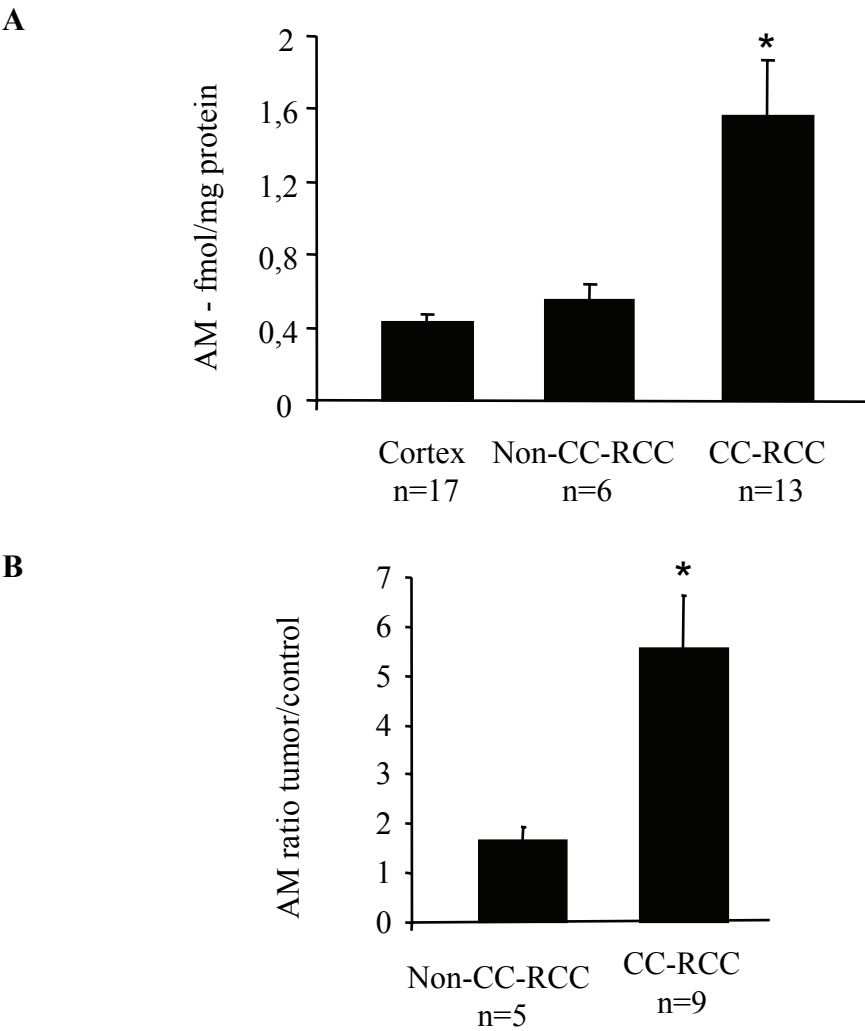


Figure 4

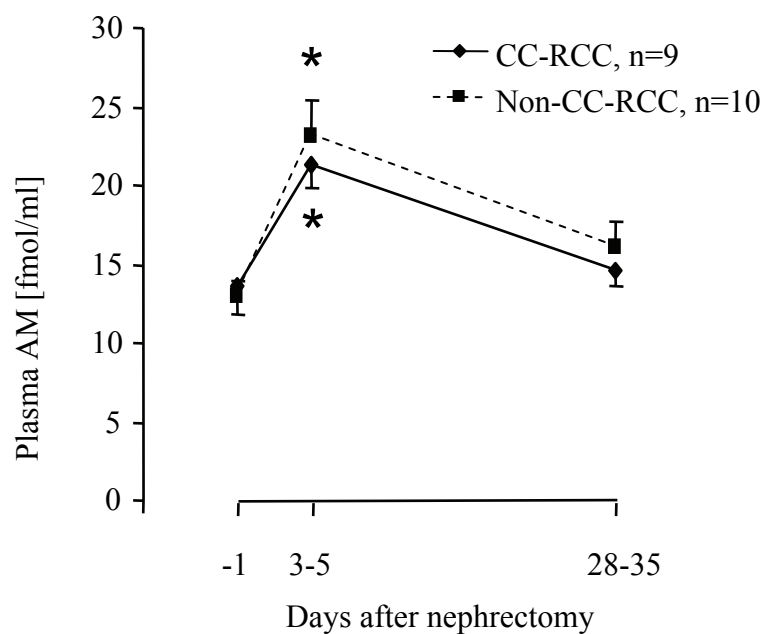


Figure 5

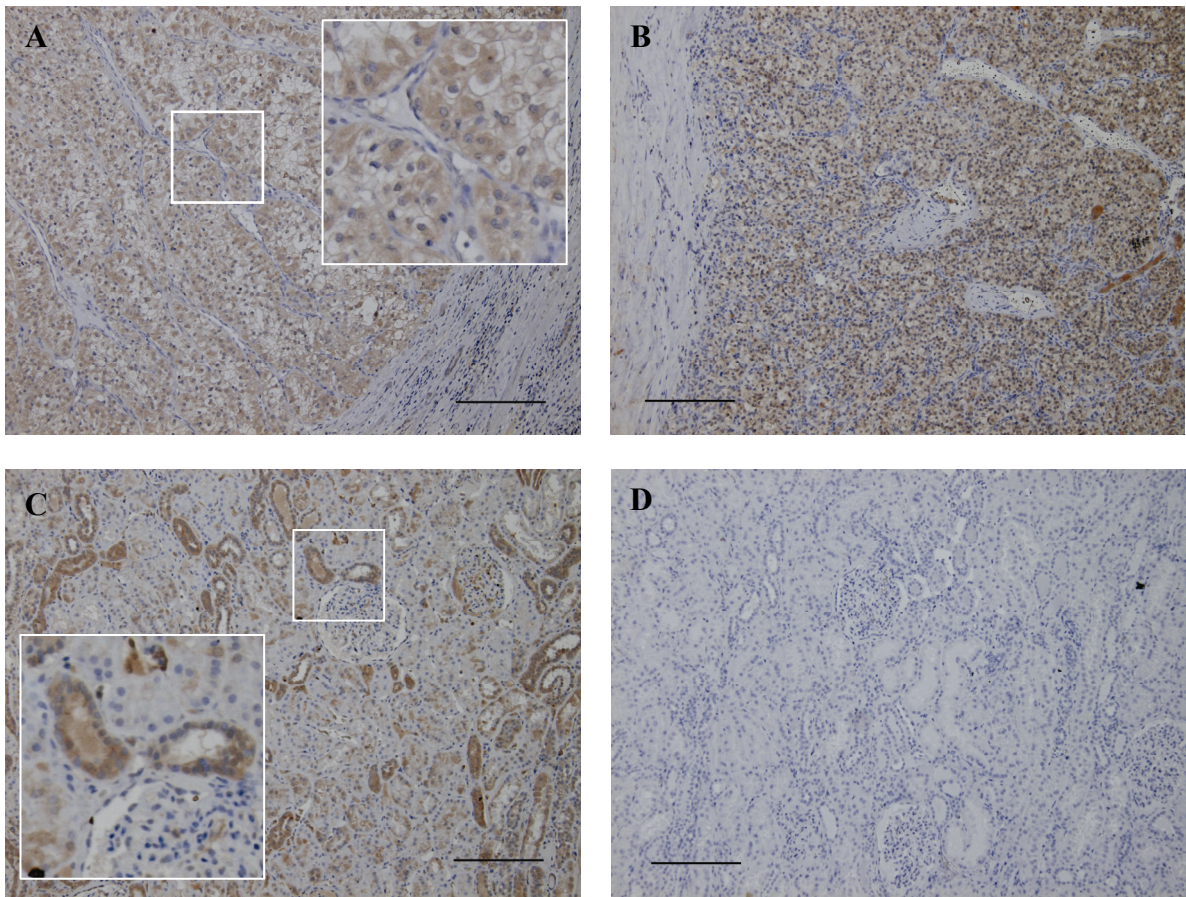


Figure 6

