



HAL
open science

Loss of expression of chromosome 16q genes DPEP1 and CTCF in lobular carcinoma in situ of the breast

Andrew R. Green, Sophie Krivinskas, Peter J.W. Young, Emad A. Rakha, E. Claire Paish, Desmond G. Powe, Ian O. Ellis

► To cite this version:

Andrew R. Green, Sophie Krivinskas, Peter J.W. Young, Emad A. Rakha, E. Claire Paish, et al.. Loss of expression of chromosome 16q genes DPEP1 and CTCF in lobular carcinoma in situ of the breast. *Breast Cancer Research and Treatment*, 2008, 113 (1), pp.59-66. 10.1007/s10549-008-9905-8 . hal-00478302

HAL Id: hal-00478302

<https://hal.science/hal-00478302>

Submitted on 30 Apr 2010

HAL is a multi-disciplinary open access archive for the deposit and dissemination of scientific research documents, whether they are published or not. The documents may come from teaching and research institutions in France or abroad, or from public or private research centers.

L'archive ouverte pluridisciplinaire **HAL**, est destinée au dépôt et à la diffusion de documents scientifiques de niveau recherche, publiés ou non, émanant des établissements d'enseignement et de recherche français ou étrangers, des laboratoires publics ou privés.

Loss of expression of chromosome 16q genes DPEP1 and CTCF in lobular carcinoma in situ of the breast

Andrew R. Green · Sophie Krivinskas · Peter Young ·
Emad A. Rakha · E. Claire Paish · Desmond G. Powe ·
Ian O. Ellis

Received: 24 November 2007 / Accepted: 9 January 2008 / Published online: 23 January 2008
© Springer Science+Business Media, LLC. 2008

Abstract *Background* Loss of the chromosomal material at 16q is the most frequent genetic event in invasive and in situ (LCIS) lobular carcinoma of the breast. However, the smallest region of overlap at 16q is not restricted to just the CDH1 locus harbouring E-cadherin, suggesting that neighbouring genes might be involved in the development and progression of these tumours. Potential novel tumour suppressor genes (TSG) at 16q include CCCTC-binding factor (CTCF), Decreased Expression in Renal and Prostate Cancer (DERPC) and Dipeptidase 1 (DPEP1). The aim of this study is to assess the expression of these genes in LCIS and compare them with normal breast, using CDH1 as a control, in order to evaluate their role as TSGs. *Methods* Cells from LCIS cases and normal breast lobules were microdissected and expression of target genes were quantified using real-time PCR. In addition, immunohistochemistry (IHC) for E-cadherin and CTCF was performed on paraffin processed LCIS (n = 49) and normal breast cases. *Results* All LCIS showed negative expression of E-cadherin. Similar to CDH1, CTCF and DPEP1 gene expression was significantly lower in LCIS cases compared with normal cases ($P < 0.05$). CTCF IHC expression showed significant reduction in LCIS compared to normal parenchymal cells. However, there was no difference in expression of DERPC between LCIS and normal breast tissue. *Conclusions* In addition to CDH1, loss of CTCF and

DPEP1 gene expression suggest they are possible TSG in breast cancer and may, similar to CDH1, be potentially utilised as markers of predisposition of women diagnosed with LCIS.

Keywords Lobular carcinoma in situ · E-cadherin · CCCTC-binding factor · Dipeptidase 1 · Laser microdissection

Introduction

Breast cancer can be divided into different histological types, the most common type being invasive ductal carcinoma (41–75%), followed by invasive lobular (ILC) carcinoma (2–16%). ILC has characteristic cytomorphic features that help to differentiate it from ductal carcinomas. When the cells with the morphology of ILC still contained within a basement membrane in the terminal duct-lobular unit, with or without pagetoid involvement of terminal ducts, the lesion is called lobular carcinoma in situ (LCIS). In this respect, there are parallels with ductal carcinoma in situ (DCIS) however, LCIS is characteristically both multifocal and bilateral in a large percentage of cases. The majority of LCIS cases are discovered through mammographic screening, accounting for 0.5–3.8% in otherwise benign breast biopsies and approximately 1.3% of all breast malignancies [1, 2]. In a recent study, we have proposed the existence of a family of low grade breast carcinoma, suggesting a developmental pathway from normal to precursor to breast carcinoma [3]. We and others [4–7] have confirmed a high association between LCIS and the development of ILC. Therefore, its detection and treatment substantially improves survival [1]. However, the

A. R. Green (✉) · S. Krivinskas · P. Young ·
E. A. Rakha · E. C. Paish · D. G. Powe · I. O. Ellis
Division of Pathology, School of Molecular Medical Sciences,
University of Nottingham and Nottingham University Hospitals
NHS Trust, Queen's Medical Centre, Nottingham,
UK NG7 2UH
e-mail: andrew.green@nottingham.ac.uk

exact mechanisms of progression of LCIS from a non-invasive neoplastic proliferation to an invasive cancer and which women with LCIS are predisposed to develop invasive cancer currently remain unknown.

Loss of chromosomal material at 16q, as detected by loss of heterozygosity (LOH) and comparative genomic hybridization (CGH) studies, is one of the most frequent somatic genetic events in breast cancer [8]. 16q loss is seen with a similar high frequency in LCIS, ILC, tubular cancer, and in low and intermediate DCIS, whereas high grade invasive or in situ ductal carcinomas shows 16q loss much less frequently [4, 5, 9]. The loss of 16q regions is believed to be an early genetic event in the development of invasive breast cancer from in situ lesions [6]. A common region of deletion in breast cancer is found at the centromeric part of 16q22.1 which includes genes encoding E-cadherin (CDH1), CCCTC-binding factor (CTCF) [10], and Decreased Expression in Renal and Prostate Cancer (DERPC). Dipeptidase 1 (DPEP1) has been localised to 16q24.3, another common region of deletion [11].

E-cadherin is a calcium dependent cell adhesion protein that mediates cell-to-cell interactions. It is involved in cell development, migration and morphology and therefore may have a critical role in tumour development, invasion and progression. In some breast carcinomas, particularly those with lobular morphology, plasma membrane associated E-cadherin expression is decreased or absent [9]. Loss of expression of E-cadherin occurs in lobular carcinomas mainly due to mutation of one allele with loss of the other wild type allele (loss of heterozygosity; LOH), resulting in loss of defective E-cadherin expression [9]. LOH at 16q is an example of Knudson's two-hit hypothesis, presenting on the inactivation of tumour suppressor genes (TSGs). Mutational inactivation of the CDH1 has been demonstrated in lobular breast cancer [12] which shows a characteristic diffuse growth pattern with characteristic cellular dissociation consistent with loss of the adhesion function of the absent protein. However, the smallest region of overlap (SRO) at 16q is not restricted to CDH1 locus harbouring E-cadherin gene indicating that other genes may be involved in the development of these tumour types. In addition, 15–20% of ILC show positive expression of E-cadherin protein despite retaining the characteristic cytomorphological features of lobular carcinoma. Moreover, although low grade ductal carcinomas show LOH at chromosome 16q, neither CDH1 mutation nor loss of expression has been reported [9]. It is therefore suggested that in addition to CDH1, which acts as a TSG in LCIS and may play a role in subsequent invasive properties [13], other genes may be involved in these processes.

The CTCF gene has been mapped to chromosome 16q22.1 approximately 1.2 Mbp from the CDH1 gene but within one of the smallest regions of overlapping deletions

in breast cancer. CTCF is a transcriptional regulator of several genes including IGF2 and the oncogene C-MYC both of which are linked with tumorigenesis. The loss of CTCF protein expression has been detected in invasive ductal carcinoma [10], but expression levels in LCIS and infiltrating lobular carcinomas remain unknown. CTCF is a widely expressed transcription factor that is involved in different aspects of gene regulation including promoter activation [14] and repression [15], hormone-responsive gene silencing [16], methylation-dependent chromatin insulation and genomic imprinting [17, 18]. It has also been shown that CTCF can inhibit cell growth and induce cell cycle arrest at multiple stages [19].

DPEP1 hydrolyses a wide range of dipeptides implicated in the renal metabolism of glutathione and its conjugates [20]. It may also play an important role in the regulation of leukotriene activity. It is highly expressed in colon tumours and may act as a marker for disseminated colon tumours [11]. Its role in breast cancer, particularly LCIS, however is unknown.

Decreased Expression in Renal and Prostate Cancer (DERPC), is located on 16q22.1, 260 kbp apart from the CDH1 locus. It is ubiquitously expressed with abundant expression in kidney, skeletal muscle, testis, liver, ovary and heart, with moderate expression in prostate [21]. Expression of DERPC has inhibitory potential on prostate cancer cell growth. It has been found to be significantly decreased in renal tumours and prostate tumours [21]. Its role in breast cancer is unknown.

Due to their location in the SROs at 16q, we therefore investigated the gene expression of CTCF, DPEP1 and DERPC in addition to CDH1 on microdissected LCIS and compared them with normal breast tissue to determine their candidacy as TSG. In addition, the expression of E-cadherin and CTCF protein were studied in the same tissue types.

Material and methods

Collection of patient samples

Cases of formalin-fixed and paraffin embedded surgically-resected breast tissue were collected retrospectively from the Nottingham Breast Tumour Bank comprising 49 LCIS and 6 normal lobular samples, devoid of hyperplasia. All LCIS cases were subsequently reviewed by a pathologist (EAR) to ensure histological diagnosis. The average age of LCIS patients was 56 years (age range 39–74).

Tissue microarrays and immunohistochemistry

Whole breast tumour sections were immunohistochemically stained employing the standard streptavidin-biotin

complex method as previously described [22]. Primary antibodies used were: E-cadherin (Mouse Anti-Human E-cadherin; Dakocytomation, Glostrup, Denmark; 1:100) and CTCF (Goat polyclonal IgG Santa Cruz Biotechnology; 1: 100). 3-3' Diaminobenzidine tetrahydrochloride (Dako liquid DAB plus, K3468, Denmark) was used as a chromagen. The sections were counterstained with Mayer's haematoxylin.

Assessment of E-cadherin membranous immunoreactivity in LCIS and normal lobular cells was assessed as positive, weak or negative. CTCF nuclear immunoreactivity in LCIS and normal lobular cells was assessed using a modified histochemical score (H-score) [23]. This comprises a determination of both intensity of staining and percentage of stained cells. For intensity, a score index of 0, 1, 2 and 3 corresponding to absent, weak, moderate or strong staining intensity was used and the percentage of positive cells at each intensity was estimated. A final score of 0–300 was the product of both intensity and percentage. Intensity of CTCF cytoplasmic immunoreactivity was assessed as positive, weak or negative. All cases were scored in a blind manner on two separate occasions and any differences in scoring were agreed upon on re-evaluation.

RNA extraction from patient tissue samples

Laser microdissection

Breast tissue sections (4 μm) mounted on precleaned glass slides (Snowcoat X-tra; Surgipath, Richmond, IL, USA) were deparaffinised with xylene and alcohol, then rehydrated in RNase-free 75% ethanol, rinsed in RNase-free water for 1 min each and stained with 0.1% Toluidine blue (RNase-free). Sections were dehydrated with alcohol and xylene. A PALM Microbeam (Zeiss, PALM Microlaser Technologies, Bernried, Germany) was used to isolate LCIS cells from tissue sections using the Laser Pressure Catapulting (LPC) microdissection method. On average approximately 340,000 μm^2 of pure LCIS cells from each patient sample ($n = 11$) and 230,000 μm^2 from each normal sample ($n = 6$) were isolated and collected in sterile PALM Opaque Adhesive Caps (PALM Microlaser Technologies, Fig. 1). For each patient, triplicate samples were taken. Each LCIS structure was marked using the software at $\times 40$ magnification.

RNA extraction

Total RNA was extracted from whole tissue sections or microdissected cells using the Optimum FFPE RNA Isolation Kit (Ambion Europe Ltd, Huntingdon, UK) following

manufacturer's instructions with several minor modifications: (a) Proteinase K digestion using 4.5 mg/ml proteinase K for 16 h at 55°C [24], (b) the RNA was eluted in a total of 13.5 μl which was passed through the column twice and c) residual genomic DNA was degraded using 1 μl TURBO DNase (2 U/ μl ; Ambion) following manufacturer's instructions. RNA quantity and quality was assessed using an RNA 6000 Pico LabChip with an Agilent 2100 bioanalyser (Agilent Technologies UK Ltd, West Lothian, UK) and a NanoDrop ND-1000 UV-Vis Spectrophotometer (Nanodrop Technologies) according to manufacturer's instructions.

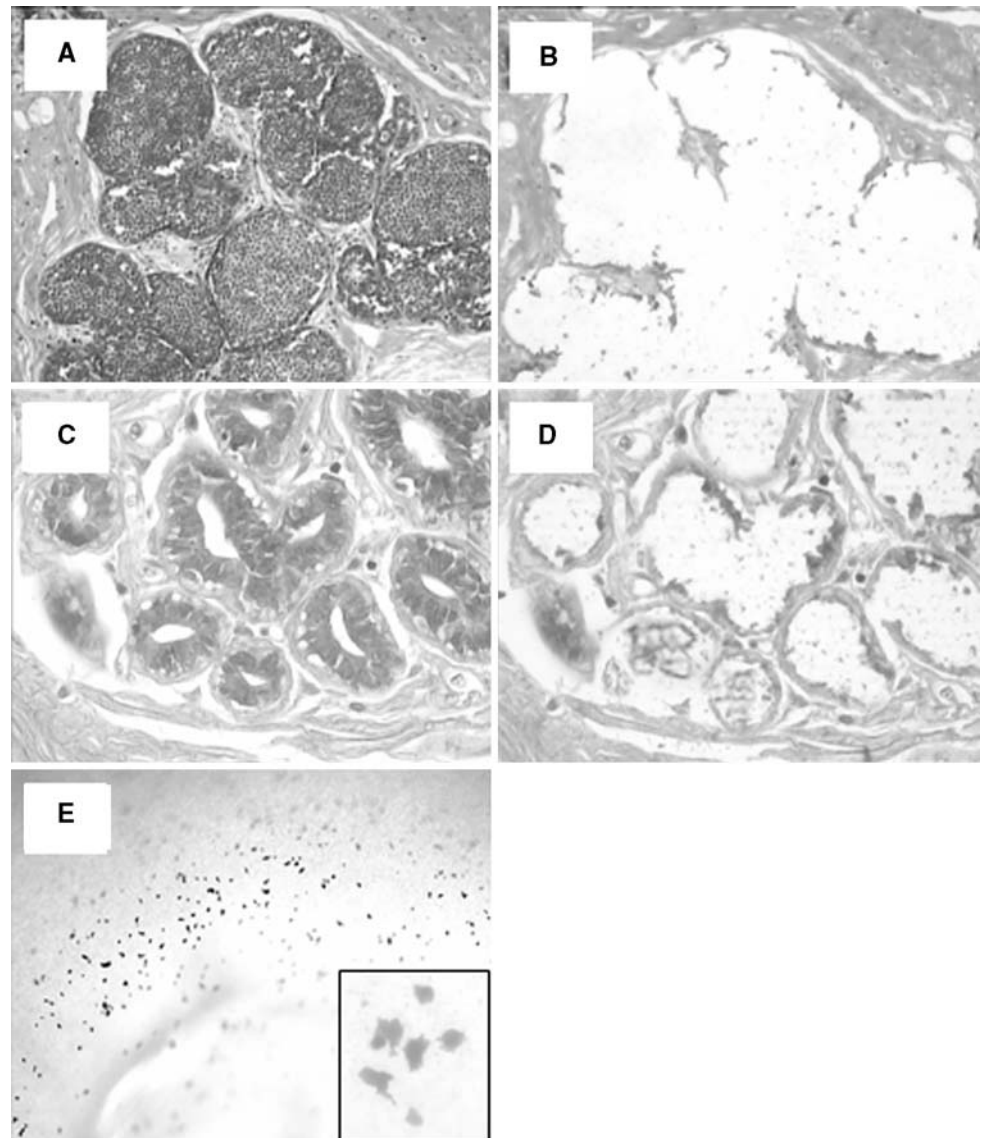
Reverse transcription

First strand cDNA synthesis was performed with 11.5 μl of total RNA and Superscript III RNase H reverse transcriptase (Invitrogen, Glasgow, Strathclyde, UK), according to the manufacturer's instructions using random hexamers (Promega, Southampton, Hants, UK) and SUPERase-In (Ambion).

Real time-PCR

Expression for the housekeeping gene 18S rRNA and target genes CDH1, CTCF, DPEP1 and DERPC were quantified in each sample using optimised real-time PCR with SYBR Green fluorescent signal and specific oligonucleotide primers (MWG Biotech; Table 1). Amplification of each target gene was performed in duplicate using a 1 μl aliquot of each first strand cDNA reaction in a 20 μl total reaction volume of Quantitect SYBR Green Mastermix (Qiagen, Crawley, UK) with optimised MgCl_2 and primer concentrations (Table 1). Gene amplification was performed using a MX4000 (Stratagene, Amsterdam, The Netherlands) following manufacturer's instructions with the following incubation times: 95°C for 15 min followed by 50 cycles of 95°C for 30 s, 61°C for 30 s and 72°C for 30 s. Fluorescence signals were obtained once in each cycle by sequential fluorescence monitoring of each sample tube at the end of extension. A dissociation curve of the PCR amplicons was also conducted to ensure specificity. Standard curves were prepared for each gene target using a 10-fold serial dilution between 1×10^6 and 1×10^1 gene copies of the specific purified PCR amplicons. The appropriate standard curve was included with each experimental run. Two negative controls were run in duplicate for each gene in which deionised water was substituted for cDNA which showed no amplification. The crossing threshold (CT) of each target was determined from the exponential phase of the fluorescence amplification profiles. Average CT values were

Fig. 1 Laser microdissection of normal breast lobules and LCIS. (a) LCIS pre-microdissection $\times 40$ magnification, (b) LCIS post-microdissection $\times 40$ magnification, (c) normal lobules pre- microdissection $\times 20$ magnification, (d) normal lobules post-microdissection $\times 20$ magnification, (e) Cap of laser microdissector after UV light has catapulted pieces of LCIS from slide on stage $\times 10$ magnification, inset: $\times 40$ magnification



calculated for each gene and the 18S rRNA gene was used to normalise all other genes tested in the same cDNA sample. In each case, target gene expression was normalised against 18s rRNA expression and stated as target gene copies/ 10^3 copies of 18s rRNA.

Statistical analysis

A t-test was carried out on the immunohistochemistry results and a Mann–Whitney test was performed on the real-time PCR results. Both tests compared differences between normal control and LCIS samples. A difference of $P < 0.05$ was considered significant.

This research was approved by Nottingham Research Ethics Committee 2 under the title of “Development of a molecular genetic classification of breast cancer”.

Results

Immunohistochemistry

E-cadherin

The luminal epithelium of normal breast parenchyma exhibited uniformly strong membranous immunoreactivity for E-cadherin (Fig. 2a). As expected, all LCIS cases either demonstrated negative or weakly positive E-cadherin immunoreactivity (Fig. 2b).

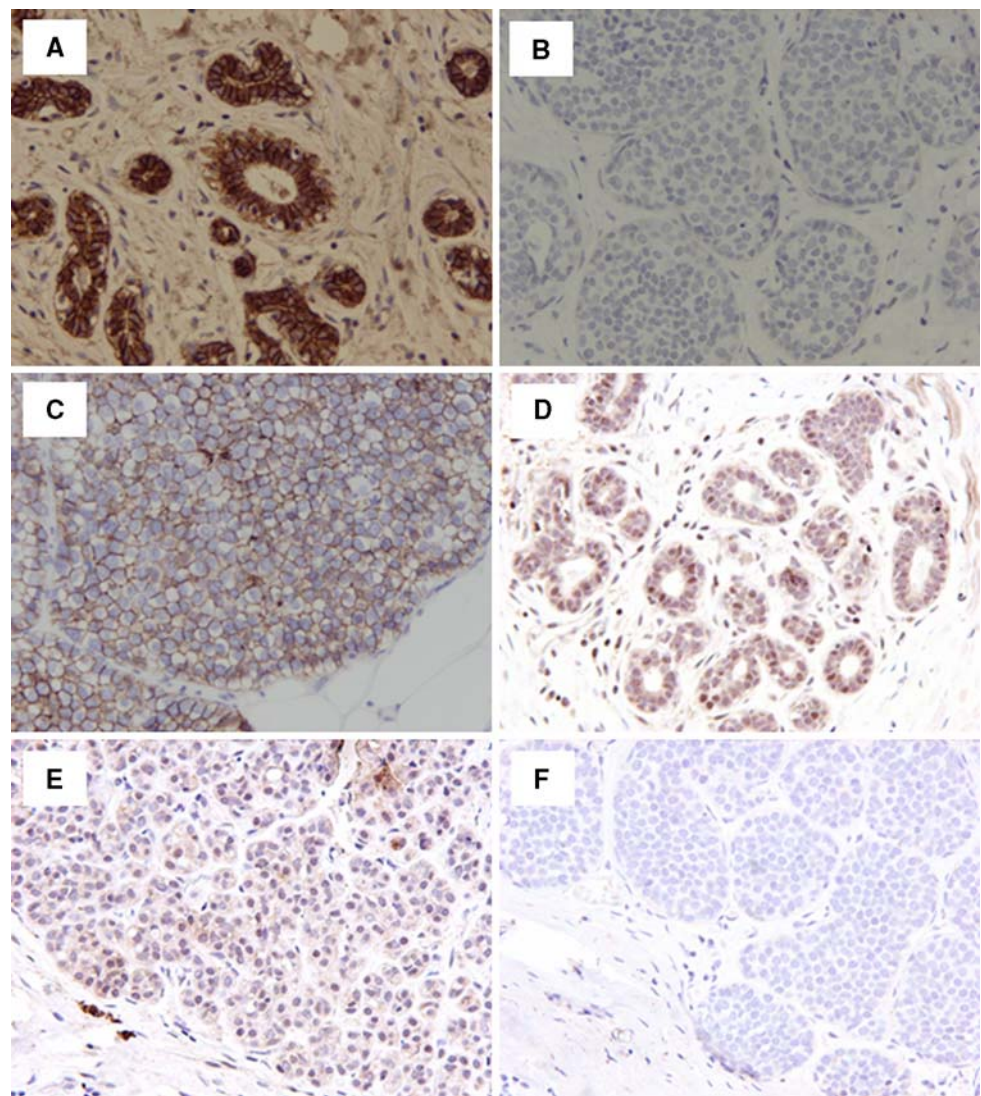
CTCF

CTCF immunoreactivity was observed in the parenchymal cells of normal breast lobules which showed strong nuclear

Table 1 Primer sequences for real-time PCR

Gene target	Oligonucleotide primers (5'–3')	Sequence position	Sequence accession	Annealing temp (°C)	MgCl ₂ (mM)	Primer conc (μM)	Product size (bp)	T _m (°C)
18S rRNA	CAACTTTCGATGGTAGTCG CCTTCCTGGATGTGGTA	502–522 594–611	K03432	61	3.0	0.5	110	83.5
CDH1	CCAGGAACCTCTGTGATGGA TTTTGT CAGGGAGCTCAGGA	953–973 1047–1067	NM_004360	61	5.0	0.5	115	81.5
CTCF	TTGTGCAGTTATGCCAGCAG CACTTTGGGTA AACCGAGCA	1138–1158 1129–1249	NM_006565	61	5.0	0.5	112	77.5
DPEP1	CAAGGACCAGCATCTCCTGA TTTATTGCGGGCCTACTGTG	1629–1649 105–1725	NM_004413	61	4.0	0.5	97	82.5
DERPC	GGCCCTCTACTCATCCAAC TTCCAATATCCCATCCACA	2680–2700 2753–2773	AF525164	61	5.0	0.5	93	75.5

Fig. 2 E-cadherin and CTCF immunohistochemical staining in normal breast and LCIS (a) Positive staining for E-cadherin in normal breast lobules, (b) negative E-cadherin staining in LCIS, (c) LCIS with reduced immunoreactivity for E-cadherin. (d) Positive cytoplasmic and positive nuclear CTCF staining in normal lobules, (e) weak cytoplasmic CTCF staining and reduced nuclear CTCF staining in LCIS, (f) negative cytoplasmic CTCF staining in LCIS. All ×20 magnification



staining in all cases (Fig. 2d). Lymphocytes and endothelial cells also showed a positive staining pattern. All normal cases also showed positive cytoplasmic staining. LCIS cells

showed a heterogeneous nuclear and/or cytoplasmic granular staining pattern. Cases were stratified according to nuclear staining into two groups; reduced (H-score < 50;

Table 2 CTCF immunohistochemical staining in lobular carcinoma in situ (LCIS) and normal breast lobules

	Nuclear			Cytoplasmic			
	Positive	Reduced	<i>P</i> -value	Positive	Weak	Negative	<i>P</i> -value
LCIS	0/49 (0%)	49/49 (100%)	0.0001	0/49 (0%)	39/49 (79.6%)	10/49 (20.4%)	0.0001
Normal lobules	6/6 (100%)	0/6 (0%)	0.041	6/6 (100%)	0/6 (0%)	0/6 (0%)	0.0025
<i>P</i> -value	<0.0001			<0.0001			

Fig. 2e), and positive (≥ 50) where all 49/49 (100%) LCIS cases showed a significant reduction in CTCF staining. A total of 39/49 (79.6%) cases showed weak CTCF cytoplasmic immunoreactivity (Fig. 1e), whilst the remaining 10 cases (20.4%) were negative (Fig. 1f; Table 2) compared with normal lobules ($P < 0.05$).

Gene expression

Amplification of all four gene targets, CDH1, DPEP1, DERP1 and CTCF was successful in normal and LCIS samples. The average number of copies of each transcript was compared between tumours and normal lobules (Fig. 3). The difference between copies of CDH1 in normal lobules and LCIS was significant ($P = 0.001$, Fig. 3). CTCF expression was significantly reduced in LCIS compared with normal breast tissue ($P = 0.045$, Fig. 3) where all LCIS cases had lower CTCF levels than the normal lobules. There was a strong correlation between CTCF gene and protein expression ($P = 0.0005$). Furthermore, DPEP1 gene expression was increased in normal lobules compared with LCIS ($P = 0.023$, Fig. 3). All LCIS cases had a lower DPEP1 gene expression than the normal lobules. There was no significant difference in expression of DERP1 between LCIS and normal lobules (Fig. 3).

Discussion

Research evaluating various candidate TSGs on 16q has shown that loss of expression of specific genes is associated with various carcinomas. Loss of genetic material at the long arm of chromosome 16 is one of the most frequent somatic genetic events in breast cancer, occurring in about half of all ductal carcinomas and slightly more frequently in lobular carcinomas [5]. In our study, the genes investigated were located on the most frequent smallest regions of deletion (SROs) at 16q (16q22.1 and 16q24.3) and are therefore considered potential target TSGs [8]. We used CDH1 as a positive control as it has previously been recognised as a TSG in lobular carcinomas [5, 9, 13, 25]. The results presented here further support previous studies [9, 26–28] in suggesting that CDH1 is a TSG in LCIS, as

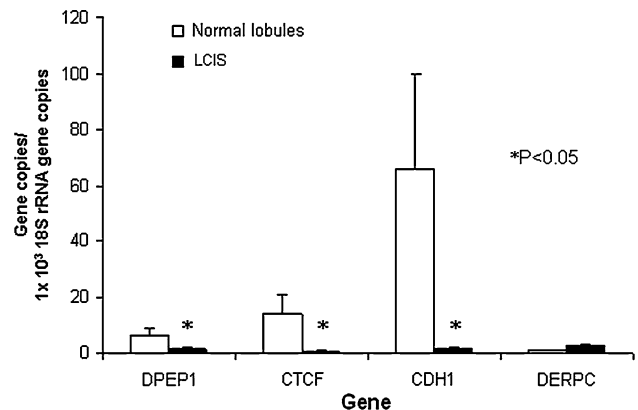


Fig. 3 Comparison of gene expression of dipeptidase 1 (DPEP1), CCCTC-binding factor (CTCF), E-cadherin (CDH1) and Decreased Expression in Renal and Prostate Cancer (DERP1) in normal breast lobules ($n = 6$) and lobular carcinoma in situ ($n = 11$). Values are means \pm S.E.M. * $P < 0.05$

immunohistochemistry and RT-PCR showed almost complete absence of expression compared with normal breast lobules. However, in vitro evidence suggests that the loss of E-cadherin alone is not responsible for tumorigenesis and that it has been proposed that additional TSG at 16q are required to complete the multistep process. For this reason, we hypothesised that neighbouring genes might synergistically contribute to oncogenesis, or their loss might represent coincidental events.

Loss of CTCF expression is involved in tumour initiation or proliferation of invasive ductal breast carcinoma [29]. However it has been suggested that CTCF is unlikely to be the TSG targeted by the 16q22.1 loss in invasive breast cancer as no association was found between CTCF expression in invasive ductal carcinoma and tumour type, lymph node stage, oestrogen receptor expression or patient outcome [10]. Ours is the first study to investigate the association between CTCF and LCIS using both RT-PCR and immunohistochemical techniques. We found significant loss of protein expression in the nuclei and cytoplasm of LCIS cells (by IHC) and CTCF gene expression (by RT-PCR) in LCIS compared with normal lobules, suggesting that CTCF may act as a TSG in LCIS.

Loss of expression of DPEP1 is associated with colorectal cancer [11] and Wilms' tumour [30]. Although no link has previously been found between DPEP1 and breast

cancer, our study showed that LCIS is associated with loss of DPEP1 expression. RT-PCR results show a marked reduction in expression in LCIS compared with normal lobules, suggesting that DPEP1 may act as a TSG. DPEP1 is a membrane bound dipeptidase and may be involved in the degradation of surrounding extracellular matrix components [11], a mechanism that would aid the invasion processes of tumours. Its reduction in LCIS may explain why LCIS may persist in an insitu lesion but further experiments determining DPEP1 in invasive carcinomas using laser microdissection and RT-PCR need to be conducted. DPEP1 is also implicated in the metabolism of glutathione [30], an important antioxidant. If DPEP1 expression is reduced less glutathione is produced, increasing oxidative stress, which may increase carcinogenesis [31].

Although loss of expression of the novel gene DERPC has been found in renal and prostate tumours [21], no link has been found with breast cancer. The results using RT-PCR show no association between DERPC and LCIS. Protein expression of DPEP1 or DERPC could not be investigated as part of this study as no commercial antibodies for these genes were available.

Genetic loss of 16q, including 16q22 and 16q24, provides a mechanism for loss of the target gene. Additional mechanisms, such as promoter methylation or gene mutation [32], might also be responsible for gene inactivation. It is important to realise that although gene expression of CDH1, CTCF and DPEP1 is reduced, complete loss of gene expression may not occur. If protein expression was particularly reduced for a gene that was highly expressed, other processes might be involved, such as defective translational processes, or the life-span of the protein may be shorter than usual which would also lead to decreased protein expression despite high gene expression. This could provide an explanation for presence of weak rather than absent cytoplasmic staining with CTCF in LCIS.

The chromosome regions 16q22.1 and 16q24.3 on which CDH1, CTCF, DERPC and DPEP1 are present, are SROs and these regions are less stable and therefore more likely to harbour one or more TSGs. CDH1 is situated on chromosome 16 between CTCF and DERPC. As there is a loss of CTCF expressed in LCIS but not DERPC, in comparison to normal lobules, it is possible to hypothesise that genes between CDH1 and CTCF are more likely to be lost in LCIS and to act as TSG compared with genes situated between CDH1 and DERPC and beyond towards the telomere. Without loss of DERPC compared with the other genes investigated suggests that in LCIS a SRO boundary of 16q22.1 possibly occurs between CDH1 and DERPC. To determine this hypothesis, it would be necessary to investigate further gene and protein expression of the genes between CDH1 and CTCF and between CDH1 and

DERPC. It would also be useful to synthesise antibodies for DERPC and DPEP1 to compare gene and protein expression in these samples.

In conclusion, CTCF immunohistochemistry showed reduced protein expression in LCIS compared with normal breast lobules. A reduction of gene expression in LCIS was also seen with CTCF and DPEP1 using RT-PCR. These chromosome 16 genes are all potential TSG in breast cancer, particularly LCIS. Further investigation into these genes may therefore be warranted.

References

- Frykberg ER (1999) Lobular carcinoma in situ of the breast. *Breast J* 5:296–303
- Bland KI, Menck HR, Scott-Conner CE, Morrow M, Winchester DJ, Winchester DP (1998) The National Cancer Data Base 10-year survey of breast carcinoma treatment at hospitals in the United States. *Cancer* 83:1262–1273
- Abdel-Fatah TM, Powe DG, Hodi Z, Lee AH, Reis-Filho JS, Ellis IO (2007) High frequency of coexistence of columnar cell lesions, lobular neoplasia, and low grade ductal carcinoma in situ with invasive tubular carcinoma and invasive lobular carcinoma. *Am J Surg Pathol* 31:417–426
- Gunther K, Merkelbach-Bruse S, Amo-Takyi BK, Handt S, Schroder W, Tietze L (2001) Differences in genetic alterations between primary lobular and ductal breast cancers detected by comparative genomic hybridization. *J Pathol* 193:40–47
- Cleton-Jansen AM (2002) E-cadherin and loss of heterozygosity at chromosome 16 in breast carcinogenesis: different genetic pathways in ductal and lobular breast cancer? *Breast Cancer Res* 4:5–8
- Amari M, Suzuki A, Moriya T, Yoshinaga K, Amano G, Sasano H, Ohuchi N, Satomi S, Horii A (1999) LOH analyses of premalignant and malignant lesions of human breast: frequent LOH in 8p, 16q, and 17q in atypical ductal hyperplasia. *Oncol Rep* 6:1277–1280
- Baum M (1995) *Breast cancer: a guide for every women*. Oxford University Press
- Rakha EA, Green AR, Powe DG, Roylance R, Ellis IO (2006) Chromosome 16 tumor-suppressor genes in breast cancer. *Genes Chromosomes Cancer* 45:527–535
- Etzell JE, Devries S, Chew K, Florendo C, Molinaro A, Ljung BM, Waldman FM (2001) Loss of chromosome 16q in lobular carcinoma in situ. *Hum Pathol* 32:292–296
- Rakha EA, Pinder SE, Paish CE, Ellis IO (2004) Expression of the transcription factor CTCF in invasive breast cancer: a candidate gene located at 16q22.1. *Br J Cancer* 91:1591–1596
- McIver CM, Lloyd JM, Hewett PJ, Hardingham JE (2004) Dipeptidase 1: a candidate tumor-specific molecular marker in colorectal carcinoma. *Cancer Lett* 209:67–74
- Berx G, Becker KF, Hofler H, van Roy F (1998) Mutations of the human E-cadherin (CDH1) gene. *Hum Mutat* 12:226–237
- Berx G, Cleton-Jansen AM, Strumane K, de Leeuw WJ, Nollet F, van Roy F, Cornelisse C (1996) E-cadherin is inactivated in a majority of invasive human lobular breast cancers by truncation mutations throughout its extracellular domain. *Oncogene* 13:1919–1925
- Vostrov AA, Quitschke WW (1997) The zinc finger protein CTCF binds to the APBbeta domain of the amyloid beta-protein precursor promoter. Evidence for a role in transcriptional activation. *J Biol Chem* 272:33353–33359
- Filippova GN, Fagerlie S, Klenova EM, Myers C, Dehner Y, Goodwin G, Neiman PE, Collins SJ, Lobanenkov VV (1996) An

- exceptionally conserved transcriptional repressor, CTCF, employs different combinations of zinc fingers to bind diverged promoter sequences of avian and mammalian c-myc oncogenes. *Mol Cell Biol* 16:2802–2813
16. Burcin M, Arnold R, Lutz M, Kaiser B, Runge D, Lottspeich F, Filippova GN, Lobanekov VV, Renkawitz R (1997) Negative protein 1, which is required for function of the chicken lysozyme gene silencer in conjunction with hormone receptors, is identical to the multivalent zinc finger repressor CTCF. *Mol Cell Biol* 17:1281–1288
 17. Kanduri C, Pant V, Loukinov D, Pugacheva E, Qi CF, Wolffe A, Ohlsson R, Lobanekov VV (2000) Functional association of CTCF with the insulator upstream of the H19 gene is parent of origin-specific and methylation-sensitive. *Curr Biol* 10:853–856
 18. Filippova GN, Qi CF, Ulmer JE, Moore JM, Ward MD, Hu YJ, Loukinov DI, Pugacheva EM, Klenova EM, Grundy PE, Feinberg AP, Cleton-Jansen AM, Moerland EW, Cornelisse CJ, Suzuki H, Komiya A, Lindblom A, Dorion-Bonnet F, Neiman PE, Morse HC 3rd, Collins SJ, Lobanekov VV (2002) Tumor-associated zinc finger mutations in the CTCF transcription factor selectively alter its DNA-binding specificity. *Cancer Res* 62:48–52
 19. Rasko JE, Klenova EM, Leon J, Filippova GN, Loukinov DI, Vatolin S, Robinson AF, Hu YJ, Ulmer J, Ward MD, Pugacheva EM, Neiman PE, Morse HC 3rd, Collins SJ, Lobanekov VV (2001) Cell growth inhibition by the multifunctional multivalent zinc-finger factor CTCF. *Cancer Res* 61:6002–6007
 20. Kozak EM, Tate SS (1982) Glutathione-degrading enzymes of microvillus membranes. *J Biol Chem* 257:6322–6327
 21. Sun M, Ma L, Xu L, Li J, Zhang W, Petrovics G, Makarem M, Sesterhenn I, Zhang M, Blanchette-Mackie EJ, Moul J, Srivastava S, Zou Z (2002) A human novel gene DERPC on 16q22.1 inhibits prostate tumor cell growth and its expression is decreased in prostate and renal tumors. *Mol Med* 8:655–663
 22. Madjd Z, Pinder SE, Paish C, Ellis IO, Carmichael J, Durrant LG (2003) Loss of CD59 expression in breast tumours correlates with poor survival. *J Pathol* 200:633–639
 23. McCarty KS Jr, Miller LS, Cox EB, Konrath J, McCarty KS Sr (1985) Estrogen receptor analyses. Correlation of biochemical and immunohistochemical methods using monoclonal antireceptor antibodies. *Arch Pathol Lab Med* 109:716–721
 24. Lehmann U, Kreipe H (2001) Real-time PCR analysis of DNA and RNA extracted from formalin-fixed and paraffin-embedded biopsies. *Methods* 25:409–418
 25. Fernandez-Gonzalez R, Jones A, Garcia-Rodriguez E, Chen PY, Idica A, Lockett SJ, Barcellos-Hoff MH, Ortiz-De-Solorzano C (2002) System for combined three-dimensional morphological and molecular analysis of thick tissue specimens. *Microsc Res Tech* 59:522–530
 26. Vos CB, Cleton-Jansen AM, Berx G, de Leeuw WJ, ter Haar NT, van Roy F, Cornelisse CJ, Peterse JL, van de Vijver MJ (1997) E-cadherin inactivation in lobular carcinoma in situ of the breast: an early event in tumorigenesis. *Br J Cancer* 76:1131–1133
 27. Emmert-Buck MR, Bonner RF, Smith PD, Chuaqui RF, Zhuang Z, Goldstein SR, Weiss RA, Liotta LA (1996) Laser capture microdissection. *Science* 274:998–1001
 28. Mastracci TL, Tjan S, Bane AL, O'Malley FP, Andrulis IL (2005) E-cadherin alterations in atypical lobular hyperplasia and lobular carcinoma in situ of the breast. *Mod Pathol* 18:741–751
 29. Aulmann S, Blaker H, Penzel R, Rieker RJ, Otto HF, Sinn HP (2003) CTCF gene mutations in invasive ductal breast cancer. *Breast Cancer Res Treat* 80:347–352
 30. Austruy E, Cohen-Salmon M, Antignac C, Beroud C, Henry I, Nguyen VC, Brugieres L, Junien C, Jeanpierre C (1993) Isolation of kidney complementary DNAs down-expressed in Wilms' tumor by a subtractive hybridization approach. *Cancer Res* 53:2888–2894
 31. Klaunig JE, Xu Y, Isenberg JS, Bachowski S, Kolaja KL, Jiang J, Stevenson DE, Walborg EF Jr (1998) The role of oxidative stress in chemical carcinogenesis. *Environ Health Perspect* 106 1(Suppl):289–295
 32. Hiraguri S, Godfrey T, Nakamura H, Graff J, Collins C, Shayesteh L, Doggett N, Johnson K, Wheelock M, Herman J, Baylin S, Pinkel D, Gray J (1998) Mechanisms of inactivation of E-cadherin in breast cancer cell lines. *Cancer Res* 58:1972–1977