



HAL
open science

The impact of preoperative MRI on breast-conserving surgery of invasive cancer: a comparative cohort study

K. E. Pengel, C. E. Loo, H. J. Teertstra, S. H. Muller, J. Wesseling, J. L. Peterse, H. Bartelink, E. J. Rutgers, K. G. A. Gilhuijs

► To cite this version:

K. E. Pengel, C. E. Loo, H. J. Teertstra, S. H. Muller, J. Wesseling, et al.. The impact of preoperative MRI on breast-conserving surgery of invasive cancer: a comparative cohort study. *Breast Cancer Research and Treatment*, 2008, 116 (1), pp.161-169. 10.1007/s10549-008-0182-3 . hal-00478264

HAL Id: hal-00478264

<https://hal.science/hal-00478264>

Submitted on 30 Apr 2010

HAL is a multi-disciplinary open access archive for the deposit and dissemination of scientific research documents, whether they are published or not. The documents may come from teaching and research institutions in France or abroad, or from public or private research centers.

L'archive ouverte pluridisciplinaire **HAL**, est destinée au dépôt et à la diffusion de documents scientifiques de niveau recherche, publiés ou non, émanant des établissements d'enseignement et de recherche français ou étrangers, des laboratoires publics ou privés.

The impact of preoperative MRI on breast-conserving surgery of invasive cancer: a comparative cohort study

K. E. Pengel · C. E. Loo · H. J. Teertstra ·
S. H. Muller · J. Wesseling · J. L. Peterse ·
H. Bartelink · E. J. Rutgers · K. G. A. Gilhuijs

Received: 22 July 2008 / Accepted: 2 September 2008 / Published online: 21 September 2008
© Springer Science+Business Media, LLC. 2008

Abstract *Aim* To assess whether preoperative contrast-enhanced magnetic resonance imaging (MRI) of the breast influences the rate of incomplete tumor excision. *Methods* In a cohort of 349 women with invasive breast cancer, patients eligible for breast-conserving therapy (BCT) on the basis of conventional imaging and palpation only ($N = 176$) were compared to those who had an additional preoperative MRI ($N = 173$). Multivariate analysis was applied to explore associations with incomplete tumor excision. *Results* MRI detected larger extent of breast cancer in 19 women (11.0%), leading to treatment change: mastectomy (8.7%) or wider excision (2.3%). Tumor excision was incomplete in 22/159 (13.8%) wide local excisions in the MRI group and in 35/180 (19.4%) in the non-MRI group ($P = 0.17$). Stratified to tumor type, incompletely excised infiltrating

ductal carcinoma (IDC) was significantly associated with absence of MRI: 11/136 (8.1%) versus 2/126 (1.6%) (MRI present) ($P = 0.02$). No significant factors explained incomplete excision of other tumor types. *Conclusion* Preoperative MRI did not significantly affect the overall rate of incomplete tumor excision, but it yielded significantly lower rate of incompletely excised IDC. The reduction of incomplete excisions after MRI was smaller than the rate of a prior treatment change incurred by MRI.

Keywords MRI · Breast cancer · Breast-conserving therapy · Incomplete excision

Introduction

Breast-conserving therapy (BCT), consisting of wide local excision (WLE) of the tumor combined with postoperative radiotherapy, is the standard of care in loco-regional treatment of early (<3 cm) breast cancer. Large prospective randomized trials have demonstrated that the survival rates after BCT are equivalent to those obtained after radical mastectomy [1–3]. The 5-year local-recurrence rate after BCT is about 5% with survival rates of approximately 92% [2–5]. The local-recurrence rate is, however, approximately twice as large in patients with incompletely excised tumors and in patients 40 years of age or younger [2–5]. Results from major trials with long-term follow-up demonstrated that improvement of local control results in better survival, and complete gross excision of the primary tumor has been shown to maximize local control [2–6].

To select the optimal therapeutic strategy, the size, growth pattern and location of the lesion must be accurately visualized. Conventional imaging by mammography and ultrasonography fails to accurately assess tumor extent

J. L. Peterse was deceased.

K. E. Pengel · C. E. Loo · H. J. Teertstra ·
S. H. Muller · K. G. A. Gilhuijs (✉)
Department of Radiology, The Netherlands Cancer Institute,
Antoni van Leeuwenhoek Hospital (NKI-AVL),
Plesmanlaan 121, 1066 CX Amsterdam, The Netherlands
e-mail: k.gilhuijs@nki.nl

J. Wesseling · J. L. Peterse
Department of Pathology, The Netherlands Cancer Institute,
Antoni van Leeuwenhoek Hospital (NKI-AVL),
Plesmanlaan 121, 1066 CX Amsterdam, The Netherlands

E. J. Rutgers
Department of Surgery, The Netherlands Cancer Institute,
Antoni van Leeuwenhoek Hospital (NKI-AVL),
Plesmanlaan 121, 1066 CX Amsterdam, The Netherlands

H. Bartelink
Department of Radiotherapy, The Netherlands Cancer Institute,
Antoni van Leeuwenhoek Hospital (NKI-AVL),
Plesmanlaan 121, 1066 CX Amsterdam, The Netherlands

in approximately one-third of patients eligible for BCT [7]. Several studies reported a higher sensitivity of contrast-enhanced magnetic resonance imaging (CE MRI) to detect invasive breast cancer and to visualize disease extent compared to the standard workup using conventional imaging [8–11]. These observations have led to changes in the surgical management of patients [12–17]. Preoperative breast MRI for women with known breast cancer is, however, controversial due to the increase in cost, mastectomy rate and larger excisions, without knowing the benefit in local control [18–23]. The therapy of most patients is not converted after preoperative MRI, but little is known whether the high sensitivity of CE MRI improves the precision of BCT in this group of patients.

The aim of this study was to assess whether preoperative MRI reduces the risk of an incomplete tumor excision, and to assess consequences in patient management.

Materials and methods

Patient cohort

All women with invasive breast cancer and eligible for BCT on the basis of conventional imaging and palpation presenting at our hospital between March 2002 and July 2004 were consecutively included. Women who underwent chemo- or hormone-therapy prior to surgery and women with only primary ductal carcinoma in situ (DCIS) were not included. Detection and staging of breast cancer was performed by mammography, ultrasonography, and physical examination. Ultrasonography was also used to detect pathological loco-regional lymph nodes [24]. Proof of breast cancer was obtained using fine-needle aspiration (FNA) or core biopsy. Treatment plans were established in consensus by a multi-disciplinary team of breast cancer specialists (radiologists, surgeons, medical oncologists, radiation oncologists, pathologists, and nurse practitioners).

In 2000, the MARGINS (*Multi-modality Analysis and Radiological Guidance IN breast conServing therapy*) study started at our hospital. The aim of this single-institutional study was to investigate the use of conventional imaging in combination with MRI to improve the definition of the extent and localization of the tumor. In the MARGINS study, women with pathology-proven breast cancer and eligible for BCT were recruited for an additional preoperative breast MRI (the MRI group). The MRI results were discussed in a subsequent multi-disciplinary meeting at which time the initial treatment plan was confirmed or adjusted. In the current study, patients not recruited (the non-MRI group), either refused to participate, could not be imaged by MRI prior to the scheduled surgery date, or had contraindications for MRI, such as claustrophobia.

All data were obtained after written informed patient consent and approval of the institutional review board (the MRI group) or from established clinical guidelines and waiver of consent (the non-MRI group).

Prospective guidelines for management of additional findings at MRI

Guidelines were established to handle additional findings detected at CE MRI, aiming to minimize treatment changes on benign findings [12]. In short, if additional findings were sufficiently close to the index lesion, BCT was pursued with larger wide-local excision margins to include the additional findings. Depending on the size of the breast, the total diameter of disease in patients eligible for BCT typically does not exceed 3 cm. If additional MRI findings were further away from the index lesion, attempts were made to obtain proof of malignancy by second-look targeted ultrasonography and FNA or biopsy. If pathology confirmed malignant disease over a region too large to allow cosmetically acceptable BCT, a conversion to mastectomy was advised. If pathology proof could not be obtained, BCT was advised and follow-up by MRI. The final treatment plan was implemented after consultation with the patient.

Magnetic resonance imaging

Magnetic resonance imaging was performed with a 1.5-tesla scanner (Magnetom, Siemens Medical Systems, Erlangen, Germany) using a coronal FLASH-3D technique. Both breasts were imaged in prone orientation, using a dedicated double-breast array coil. One series was acquired before the injection of contrast agent, and four series were acquired after intravenous injection of contrast agent (Prohance, Bracco-Byk Gulden, Konstanz, Germany); 0.1 mmol/kg body weight, at a rate of 2–4 ml/s. The series were acquired at intervals of approximately 120 s. The following MRI parameters were used: 3D coronal T1-weighted sequence, repetition time 8.1 ms, echo time 4.0 ms, isotropic voxels of $1.35 \times 1.35 \times 1.35 \text{ mm}^3$ and no fat suppression. Subtraction images were available to examine initial and late enhancement. Radiologists with experience in breast MRI read the examinations. If multiple lesions were visible, the total area including normal breast tissue between lesions, was indicated as the total disease extent.

Surgery

The surgical procedures were performed according to accepted surgical standards, with the aim to achieve tumor-free margins with the best possible cosmetic outcome [25, 26]. The procedures were carried out or directly supervised by fully trained surgeons specialized in breast surgery.

Results of preoperative diagnostic imaging were available in the operating theater. For non-palpable lesions, surgeons were typically guided by a gamma-ray detection probe, after preoperative intra-lesional injection of ^{99m}Tc -nanocolloid (Nanocoll; GE-Healthcare, Eindhoven, The Netherlands) administered under ultrasound guidance [27]. Wide local excisions in our hospital are performed according to the technique described by Aspegren et al. [28]: the incision is typically radial, skin is removed only for cosmetic reasons, tumor resection is performed with an intended macroscopic margin of at least 1 cm, generally down to the fascia and reconstruction of the breast parenchyma is done by mobilization of breast tissue in order to minimize the cavity.

Pathology

At pathology, the excision specimens were handled according to a fixed protocol based on radiographic and pathological assessment, described by Egan [29]. Specimens were inked to indicate their orientation in the breast, sectioned into 5 mm parallel slices and radiographs were obtained. Cross sections of the tumor, surrounding breast tissue and nearest margins, as well as additional grossly or radiologically suspicious areas, were sampled for microscopic examination. Pathologists, experienced in breast pathology, assessed the specimens to report the largest diameter of invasive cancer, in situ components, growth pattern, margins, histological grade and type.

Grade was determined according to the Bloom and Richardson method resulting in well (grade 1), moderately (grade 2), or poorly (grade 3) differentiated carcinoma [30, 31]. An incomplete excision was defined as an excision that resulted in extension of the tumor into the edge of specimen. Incomplete excisions were rated as focally incomplete (tumor present in the resection margin in less than two low power fields) or extensively positive (tumor present in the resection margin in two or more low power fields).

Statistical analysis

SPSS Version 15.0; SPSS Chicago, Ill, was used for all analyses. To explore the difference in patients and tumor characteristics between the MRI and the non-MRI group, Students *t*-tests were performed for normally distributed continuous variables, and Mann–Whitney–*U* and Fisher's exact test for the non-normally distributed variables.

Multivariate analysis using logistic regression (LR) was performed to determine which factors were significant explanatory variables for incomplete surgery. Backward LR based on step-wise feature selection (*f*-to-entry: 0.05, *f*-to-remove: 0.10) was applied.

The following patient and tumor characteristics were fitted into the model to explore the association with incompletely excised tumor: age, palpable (yes/no), lymph node metastases (present/not present), tumor size, tumor histological grade (1, 2, 3) and MRI (done/not done). Subset analysis, using similar procedures, was performed for presence of various tumor types on the excision boundary (IDC, ILC and DCIS).

Results

Patient characteristics

At baseline the MRI group consisted of 173 women with 175 tumors (2 contra-lateral tumors prior to MRI). The non-MRI group consisted of 176 women with 180 breast tumors (4 contra-lateral tumors). The mean age was 56.1 years, standard deviation (SD) 9.9 years (range: 28–82) and 59.6 years, SD 11.1 years (range: 31–89) in the MRI group and non-MRI group, respectively ($P = 0.02$).

No significant differences were found between the tumor characteristics in the two groups: lymph node stage, palpability, tumor size, histological tumor type, and grade. The tumor type was invasive ductal carcinoma (IDC) in 274 (77.2%) of the cases. Invasive lobular carcinoma (ILC) was found in 53 (14.9%) of all cases. Patient characteristics are listed in Table 1 and Fig. 1. The rate of patient inclusion in the MRI group and non-MRI group was comparable throughout the investigated study period.

Additional findings and patient management

In the MRI group, therapy was converted to mastectomy in 16/173 (9.2%) women after detection of additional pathology-proven disease (Table 1; Fig. 1). In 19 women (11.0%), tumor with a larger extent was found than anticipated using conventional imaging. Fifteen patients (8.7%) were advised a mastectomy because of larger tumor size ($n = 3$) and multi-focal disease spread, up to 9 cm ($n = 12$) (Table 2). In all cases, the spread of disease was confirmed by extensive histopathological examination of the specimens. In four cases (2.3%) a wider excision was performed than initially planned. Three women (1.7%) were found to have additional contra-lateral breast cancer, (not visible at conventional imaging). These MRI-detected contra-lateral tumors were not included in the current study. In one woman with a bilateral tumor the treatment was changed to bilateral mastectomy, according to the wish of the patient. The other two women underwent bilateral BCT. A total of 157 women with 159 tumors continued with wide-local excision.

Table 1 Patient and tumor characteristics

	MRI	Non-MRI	Total	
	173 women	176 women	349 women	
	175 tumors	180 tumors	355 tumors	
Mastectomy ^a	16 women	–	16 women	
	16 tumors		16 tumors	
WLE	157 women	176 women	333 women	
	159 tumors	180 tumors	339 tumors	
Variable				P-value
Age (years)	Mean: 56.8 years SD: 9.6 years	Mean: 59.2 years SD: 11.2 years		0.02
≤40	6 (3.8)	9 (5.1)	15 (4.5)	
41–50	39 (24.8)	27 (15.3)	66 (19.8)	
51–60	57 (36.3)	58 (33.0)	115 (34.5)	
>60	55 (35.0)	82 (46.6)	137 (41.1)	
Histological type				0.14
IDC	126 (79.2)	136 (75.6)	262 (77.3)	
ILC	26 (16.4)	26 (14.4)	52 (15.3)	
Other	7 (4.4)	18 (10.0)	25 (7.4)	
Laterality				0.88
Left	80 (50.3)	92 (51.1)	172 (50.7)	
Right	79 (49.7)	88 (48.9)	167 (49.3)	
Palpable				0.09
Yes	112 (70.4)	111 (61.7)	223 (65.8)	
No	47 (29.6)	69 (39.3)	116 (34.2)	
Pathology tumor size	Mean: 16.9 cm; SD: 6.5 cm	Mean: 15.7 cm; SD: 7.2 cm		0.12
<1 cm	23 (14.5)	32 (17.8)	55 (16.2)	
1–1.9 cm	86 (54.1)	98 (54.4)	184 (54.3)	
2–3 cm	45 (28.3)	39 (21.7)	84 (24.8)	
>3 cm	5 (3.1)	8 (4.4)	13 (3.8)	
Missing	0	3 (1.7)	3 (0.9)	
Histological grade				0.26
1	43 (27.0)	63 (35.0)	106 (31.3)	
2	77 (48.4)	81 (45.0)	158 (46.6)	
3	39 (24.5)	36 (20.0)	75 (22.1)	
Nodal status				0.38
N0	102 (64.2)	119 (66.1)	221 (65.2)	
N1	49 (30.8)	45 (25.0)	94 (27.7)	
N2	7 (4.4)	15 (8.3)	22 (6.5)	
N3	1 (0.6)	1 (0.6)	2 (0.6)	

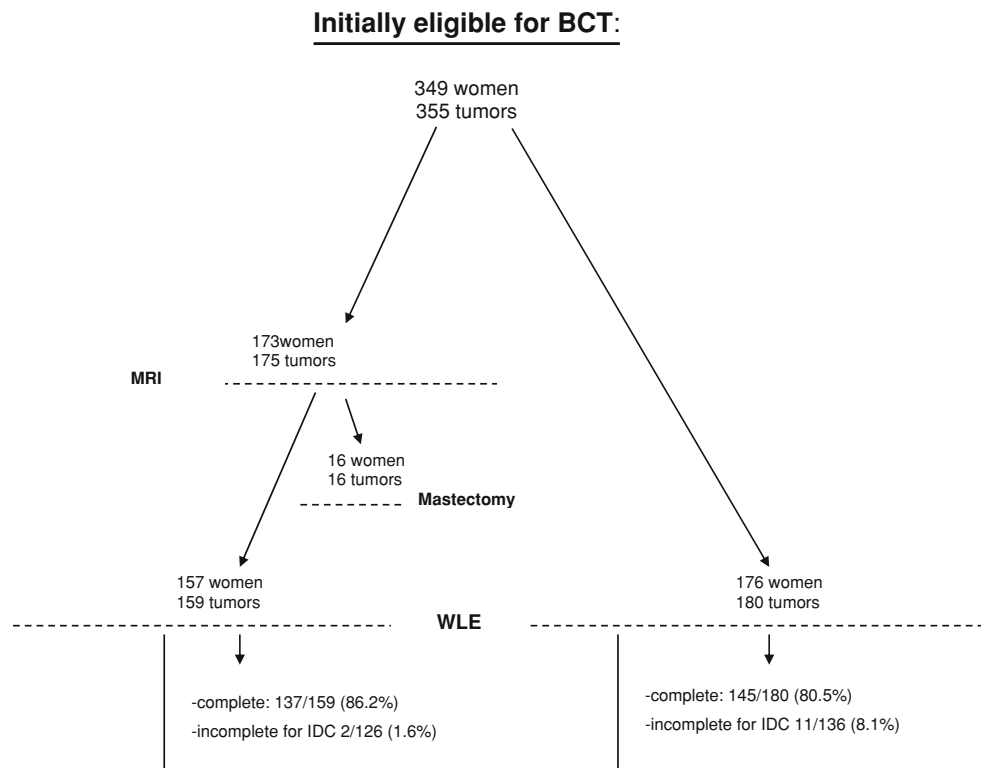
^a Mastectomies due to disease with larger extent ($n = 15$) and contra-lateral disease ($n = 1$) detected at MRI (see also Table 2). Values between parentheses are percentages

In addition to malignant findings, 21 benign lesions in 175 breasts (12.0%) were detected at preoperative MRI. Three lesions were considered benign on the basis of ultrasound characteristics, four were proved to be benign after target ultrasound with fine-needle aspiration (FNA). Thirteen lesions were occult at target ultrasonography and considered benign by follow-up. The median follow-up time was 54.1 months (range: 37.0–70.1 months). The only therapy change for a benign lesion was a wider local

excision than initially planned which included a fibroadenoma close to the index tumor.

Incomplete surgical excision

Surgical excision of the tumor was incomplete in 22 of the 159 procedures (13.8%) in the MRI group, and in 35 of the 180 procedures (19.4%) in the non-MRI group ($P = 0.17$). The types of disease at the margins of the incomplete

Fig. 1 Overview surgery in the MRI and the non-MRI group; main results**Table 2** Primary mastectomy due to disease with larger extent in the MRI group

Variable	15 Women 15 tumors
Age (years)	Mean: 47.7 years; SD 9.3 years
≤40	3 (20.0)
41–50	8 (53.3)
51–60	2 (13.3)
>60	2 (13.3)
Laterality	
Left	7 (46.7)
Right	8 (53.3)
Histological grade	
1	4 (26.7)
2	7 (46.7)
3	4 (26.7)
Nodal status	
N0	9 (60.0)
N1	5 (33.3)
N2	1 (6.7)
N3	0
Histological type	
IDC	11 (73.3)
ILC	1 (6.7)
Others	3 (20.0)

Values between parentheses are percentages

excisions are shown in Table 3. Incomplete excision of invasive disease was 8/159 (5%) and 19/180 (10.6%) in the MRI and in the non-MRI group, respectively, ($P = 0.06$). This difference was mainly caused by the lower rate of incompletely excised IDC in the MRI group: 2/126 (1.6%) versus 11/136 (8.1%), respectively, ($P = 0.02$). The mean weight of the excised specimens was 61.5 g (SD 35.0 g) in the MRI group and 65.0 g (SD 35.5 g) in the non-MRI group ($P = 0.38$).

Management after incomplete surgery

In the MRI group, 8/159 (5.0%) additional surgical procedures were performed after WLE. A re-excision was done in four patients and in another four a mastectomy. In the non-MRI group, 19/180 (10.6%) additional surgical procedures were performed after WLE ($P = 0.06$). Ten re-excisions were done and nine mastectomies. In 11 of the 22 women in the MRI group and in 13 of the 35 in the non-MRI group incomplete surgery was followed by a higher boost dose at radiotherapy to treat the incompletely excised component rather than additional surgery (Table 4).

Multivariate results

At multivariate analysis, no factors were associated with incomplete tumor excision in the overall patient cohort. At subset analysis, significant association was found only

Table 3 Incomplete surgery in the MRI versus the non-MRI group

Histological type primary tumor	Incompletely excised disease	MRI				Non-MRI				<i>P</i> -value
		<i>M</i>	%	<i>F</i>	<i>E</i>	<i>M</i>	%	<i>F</i>	<i>E</i>	
IDC	IDC	2	1.6	1	1	11	8.1	2	9	0.02
N = 126 vs. 136	in situ	12	9.8	6	6	12	8.6	4	8	n.s.
MRI vs. non-MRI										
ILC	ILC	6	23.1	4	2	5	19.2	2	3	n.s.
N = 26 vs. 26	in situ	1	3.8	0	1	3	11.5	1	2	n.s.
MRI vs. non-MRI										
Others	Others	0	–	–	–	1	5.6	0	1	n.s.
N = 7 vs. 18	IDC	0	–	–	–	1	5.6	1	0	n.s.
MRI vs. non-MRI										
	ILC	0	–	–	–	1	5.6	1	0	n.s.
	in situ	1	14.3	1	0	1	5.6	0	1	n.s.
	Total	22	13.8	12	10	35	19.4	11	24	0.17

M = Number of incompletely excised disease

F = Focally incomplete

E = Extensively incomplete

% = Percentage of incompletely excised disease

n.s. = Not significant

Table 4 Management after incomplete surgery

	MRI (<i>N</i> = 159)	Non-MRI (<i>N</i> = 180)
Re-excision	4 (2.5)	10 (5.6)
Mastectomy	4 (2.5)	9 (5.0)
Higher radiotherapy boost dose	11 (6.9)	13 (7.2)
No change in treatment	1 (0.6)	1 (0.6)
Unknown	2 (1.3)	1 (0.6)
Others		1 (0.6) ^a
Total	22 (13.8)	35 (19.4)

^a One woman with extensive incompletely excised IDC refused further treatment. Values between parentheses are percentages

between absence of MRI and incompletely excised IDC ($P = 0.02$) (Table 3). The hazard ratio was 0.18 (CI: 0.04–0.81), suggesting that these patients were at a relatively lower risk of incomplete excision of IDC when a preoperative MRI was performed. None of the other co-variables (age, palpability, lymph node status, tumor size, and grade) were significantly associated with incomplete surgical excision, and no factors were found to be associated with presence of ILC or a DCIS component on the excision boundary.

Discussion

We reported our experiences with a clinical guideline established to manage additional findings at preoperative

contrast-enhanced MRI of the breast. The impact of this guideline was assessed on the precision of BCT in a retrospective cohort of 349 women treated in the same time period. A total of 173 women underwent preoperative MRI.

In the entire cohort no significant difference in incomplete excision between the MRI and the non-MRI group was found ($P = 0.17$). Further stratification by subset analysis showed significant association between preoperative MRI and reduced rates of incompletely excised infiltrating ductal carcinoma (IDC) ($P = 0.02$). These findings may provide input to future studies investigating the potential benefit of preoperative MRI in subgroups of patients.

MRI led to treatment change in 11% of patients after pathology proof of malignancy. The rate of therapy changes due to benign findings were small (one change to larger wide local excision for a benign finding); no changes to mastectomy were caused by benign findings. MRI also detected contra-lateral cancer occult at conventional imaging in 1.7% of the patients.

The impact of preoperative MRI appeared twofold. Firstly women with more extensive pathology-proven disease were filtered away from the standard BCT eligibility and thus received a more extensive surgical treatment (mastectomy or a wider excision). The increased mastectomy rate in the MRI group raises the concern that MRI leads to over-treatment. Indeed, increased mastectomy rates were also reported in other studies [12, 13, 16]. It is likely that additional malignant disease also occurred in the non-MRI group. This assumption is supported by studies that reported more extensive disease in diverse groups of

breast tumors [7, 32–35]. Consequently, a considerable part of undetected multi-focal tumor may be controlled by adjuvant treatment such as radiotherapy. Nonetheless, it is also known that radiotherapy is ineffective to eradicate large residual tumor burden [2–4]. It remains to be proven whether conversion of therapy to mastectomy on the basis of additional MRI-detected disease has impact on the 15–20-year local recurrence rates after BCT [18–21, 22, 36–38]. This may be of particular concern in younger patients where the local recurrence rate is approximately twice as large as in older patients. In a retrospective analysis, Fisher and colleagues reported that preoperative MRI reduced the incidence of local recurrence [36]. Impact of preoperative MRI on surgical precision was not addressed. Solin and colleagues reported that the use of MRI in the staging of the patients was not associated with an improvement in local control after BCT [37]. One of the study limitations, indicated by the authors, was a significantly lower age of women in the MRI group, which makes differences in local recurrence difficult to interpret. In contrast to Fisher et al., Solin and colleagues took differences in age and adjuvant treatment into account in their analysis. Local recurrence was not an end-point of our current study.

A second impact of MRI appears to be the high accuracy at which the extent and location of IDC is visualized. This provided the surgeons with a better preoperative assessment resulting in reduced rates of incompletely excised IDC. Despite observations from other studies demonstrating superior sensitivity of MRI for ILC compared to that of conventional breast imaging [39–44], we were unable to translate these findings to reduced rates of incompletely excised ILC. Several explanations may exist. First, the number of patients with ILC was relatively small in our cohort. Secondly, all patients in our study were eligible for BCT on the basis of conventional imaging thus excluding tumors larger than 3 cm that were also included in other studies. Thirdly, evidence of multi-focal disease elsewhere in the breast may be difficult to extract from the cut margins of the WLE specimens at histopathology due to the finite tissue sampling and the typically diffuse multi-nodular pattern of growth of ILC [45, 46]. Some of these considerations also hold for DCIS. Moreover, variable sensitivity of MRI for the detection of pure DCIS has been observed in other studies [10, 47–50].

Study design

A randomized clinical trial (RCT) is the standard study design to provide level-I evidence for medical intervention studies. Level-II evidence is available showing that breast MRI visualizes disease extent more accurately than

conventional breast imaging [8–11]. This evidence has created much confidence in favor of MRI in patients as well as in practitioners, making it difficult to implement prospective comparative level-I studies. To our knowledge, there are currently only two RCTs that address aspects discussed in the present study. The first one is the COMICE (comparative effectiveness of magnetic resonance imaging in breast cancer) trial [38], investigating the role of the MRI in the preoperative staging of breast cancer. The second one is the MONET (MR mammography Of Non-palpable BrEAST Tumors) trial [51], evaluating whether MRI will improve breast cancer management for non-palpable tumors. Neither trials have been designed specifically to answer the question whether MRI will reduce local recurrence after long-term follow-up. Moreover, potential differences in how MRI findings are incorporated into clinical decision-making may lead to differences in outcome and cost-benefit between hospitals.

The design and results of the present study may be useful in follow-up studies to examine differences in local recurrence between “MRI-proven unifocal” breast tumors and tumors where only conventional imaging was performed. Studies concerning the cost effectiveness of MRI and the selection of patients for partial breast irradiation (PBI) may also benefit from these findings.

Study limitations

An obvious drawback of non-randomized studies is that they are prone to diverse bias and confounders. The women in the current study were not randomized, but consecutively recruited for a preoperative MRI scan. They were treated in the same time period as the patients in the non-MRI group, were included at similar rates during the investigated study period, under the same circumstances and had the same tumor characteristics. It allowed us to explore the potential impact of our preoperative guidelines on the management of additional MRI findings.

Although there was no selection on age in the current study we did observe a lower mean age in the MRI group, comparable to the observations of Solin et al. [37]. We analyzed the allocation procedure but could not find an explanation for this finding. It is likely that older women refused more often to undergo preoperative MRI. The multivariate analysis was performed taking the differences in age into account. Premenopausal women are at increased risk of local recurrence because of dense breast tissue (resulting in difficulty to visualize tumor extent) and increased tumor aggressiveness [3–5]. Nonetheless, despite the younger age of the women in the MRI group, this group still showed more complete excisions of IDC than the non-MRI group. This effect was not caused by larger excision volumes in the MRI group compared to the non-MRI group.

Conclusions

Preoperative MRI did not significantly affect the overall rate of incomplete tumor excision, but it yielded significantly lower rate of incompletely excised IDC. Preoperative MRI detected disease with larger extent in 11% of all patients eligible for BCT on the basis of conventional imaging and palpation, thus leading to a-prior changes in treatment.

Acknowledgments The authors thank Angelique Schlief, Anita Paape, Wil van Waardenberg, Eline Deurloo, Wilma Oughlane-Hemsbergen, and Robert Lindeboom for their contribution. This work was financially supported by The Dutch Cancer Foundation, grant number NKB 2004–3082

References

- van Dongen JA et al (2000) Long-term results of a randomized trial comparing breast-conserving therapy with mastectomy: European Organization for Research and Treatment of Cancer 10801 trial. *J Natl Cancer Inst* 92:1143–1150
- Clarke M et al (2005) Effects of radiotherapy and of differences in the extent of surgery for early breast cancer on local recurrence and 15-year survival: an overview of the randomised trials. *Lancet* 366:2087–2106
- Bartelink H et al (2001) Recurrence rates after treatment of breast cancer with standard radiotherapy with or without additional radiation. *N Engl J Med* 345:1378–1387
- Vrieling C et al (2003) Can patient-, treatment- and pathology-related characteristics explain the high local recurrence rate following breast-conserving therapy in young patients? *Eur J Cancer* 39:932–944
- Kreike B et al (2008) Continuing risk of ipsilateral breast relapse after breast-conserving therapy at long-term follow-up. *Int J Radiat Oncol Biol Phys* 71:1014–1021
- Smitt MC et al (1995) The importance of the lumpectomy surgical margin status in long-term results of breast conservation. *Cancer* 76:259–267
- Faverly DR, Hendriks JH, Holland R (2001) Breast carcinomas of limited extent: frequency, radiologic-pathologic characteristics, and surgical margin requirements. *Cancer* 91:647–659
- Boetes C et al (1995) Breast tumors: comparative accuracy of MR imaging relative to mammography and US for demonstrating extent. *Radiology* 197:743–747
- Hata T et al (2004) Magnetic resonance imaging for preoperative evaluation of breast cancer: a comparative study with mammography and ultrasonography. *J Am Coll Surg* 198:190–197
- Berg WA et al (2004) Diagnostic accuracy of mammography, clinical examination, US, and MR imaging in preoperative assessment of breast cancer. *Radiology* 233:830–849
- Deurloo EE et al (2006) Contrast-enhanced MRI in breast cancer patients eligible for breast-conserving therapy: complementary value for subgroups of patients. *Eur Radiol* 16:692–701
- Deurloo EE et al (2005) Additional breast lesions in patients eligible for breast-conserving therapy by MRI: impact on preoperative management and potential benefit of computerised analysis. *Eur J Cancer* 41:1393–1401
- Braun M et al (2008) Influence of preoperative MRI on the surgical management of patients with operable breast cancer. *Breast Cancer Res Treat* 111:179–187
- Bilimoria KY et al (2007) Evaluating the impact of preoperative breast magnetic resonance imaging on the surgical management of newly diagnosed breast cancers. *Arch Surg* 142:441–445
- Grobmyer SR et al (2008) Is there a role for routine use of MRI in selection of patients for breast-conserving cancer therapy? *J Am Coll Surg* 206:1045–1050
- Bedrosian I et al (2003) Changes in the surgical management of patients with breast carcinoma based on preoperative magnetic resonance imaging. *Cancer* 98:468–473
- Houssami N et al (2008) Accuracy and surgical impact of magnetic resonance imaging in breast cancer staging: systematic review and meta-analysis in detection of multifocal and multicentric cancer. *J Clin Oncol* 26:3248–3258
- Plevritis SK, Ikeda DM (2002) Ethical issues in contrast-enhanced magnetic resonance imaging screening for breast cancer. *Top Magn Reson Imaging* 13:79–84
- Morrow M (2004) Magnetic resonance imaging in the preoperative evaluation of breast cancer: primum non nocere. *J Am Coll Surg* 198:240–241
- Morrow M (2008) Magnetic resonance imaging in the breast cancer patient: curb your enthusiasm. *J Clin Oncol* 26:352–353
- Heywang-Kobrunner SH et al (1997) Contrast-enhanced MRI of the breast: accuracy, value, controversies, solutions. *Eur J Radiol* 24:94–108
- Bleicher RJ, Morrow M (2007) MRI and breast cancer: role in detection, diagnosis, and staging. *Oncology* 21:1521–1528, 1530
- Orel S (2008) Who should have breast magnetic resonance imaging evaluation? *J Clin Oncol* 26:703–711
- van Rijk MC et al (2006) Ultrasonography and fine-needle aspiration cytology can spare breast cancer patients unnecessary sentinel lymph node biopsy. *Ann Surg Oncol* 13:31–35
- Rutgers EJ (2001) Quality control in the locoregional treatment of breast cancer. *Eur J Cancer* 37:447–453
- Rutgers EJ (2004) Sentinel node procedure in breast carcinoma: a valid tool to omit unnecessary axillary treatment or even more? *Eur J Cancer* 40:182–186
- van Rijk MC et al (2007) Sentinel node biopsy and concomitant probe-guided tumor excision of nonpalpable breast cancer. *Ann Surg Oncol* 14:627–632
- Aspegren K, Holmberg L, Adami HO (1988) Standardization of the surgical technique in breast-conserving treatment of mammary cancer. *Br J Surg* 75:807–810
- Egan RL (1982) Multicentric breast carcinomas: clinical-radiographic-pathologic whole organ studies and 10-year survival. *Cancer* 49:1123–1130
- Bloom HJ, Richardson WW (1957) Histological grading and prognosis in breast cancer; a study of 1409 cases of which 359 have been followed for 15 years. *Br J Cancer* 11:359–377
- Elston CW, Ellis IO (1991) Pathological prognostic factors in breast cancer. I. The value of histological grade in breast cancer: experience from a large study with long-term follow-up. *Histopathology* 19:403–410
- Holland R et al (1985) Histologic multifocality of Tis, T1–2 breast carcinomas. Implications for clinical trials of breast-conserving surgery. *Cancer* 56:979–990
- Rosen PP et al (1975) “Residual” mammary carcinoma following simulated partial mastectomy. *Cancer* 35:739–747
- Anastassiades O et al (1993) Multicentricity in breast cancer. A study of 366 cases. *Am J Clin Pathol* 99:238–243
- Coombs NJ, Boyages J (2005) Multifocal and multicentric breast cancer: does each focus matter? *J Clin Oncol* 23:7497–7502
- Fischer U et al (2004) The influence of preoperative MRI of the breasts on recurrence rate in patients with breast cancer. *Eur Radiol* 14:1725–1731

37. Solin LJ et al (2008) Relationship of breast magnetic resonance imaging to outcome after breast-conservation treatment with radiation for women with early-stage invasive breast carcinoma or ductal carcinoma in situ. *J Clin Oncol* 26:386–391
38. Kneeshaw PJ, Turnbull LW, Drew PJ (2003) Current applications and future direction of MR mammography. *Br J Cancer* 88:4–10
39. Mann RM et al (2008) The value of MRI compared to mammography in the assessment of tumour extent in invasive lobular carcinoma of the breast. *Eur J Surg Oncol* 34:135–142
40. Boetes C et al (2004) The role of MRI in invasive lobular carcinoma. *Breast Cancer Res Treat* 86:31–37
41. Quan ML et al (2003) Magnetic resonance imaging detects unsuspected disease in patients with invasive lobular cancer. *Ann Surg Oncol* 10:1048–1053
42. Rodenko GN et al (1996) MR imaging in the management before surgery of lobular carcinoma of the breast: correlation with pathology. *AJR Am J Roentgenol* 167:1415–1419
43. Weinstein SP et al (2001) MR imaging of the breast in patients with invasive lobular carcinoma. *AJR Am J Roentgenol* 176:399–406
44. Mann RM et al (2008) MRI compared to conventional diagnostic work-up in the detection and evaluation of invasive lobular carcinoma of the breast: a review of existing literature. *Breast Cancer Res Treat* 107:1–14
45. Krecke KN, Gisvold JJ (1993) Invasive lobular carcinoma of the breast: mammographic findings and extent of disease at diagnosis in 184 patients. *AJR Am J Roentgenol* 161:957–960
46. Arpino G et al (2004) Infiltrating lobular carcinoma of the breast: tumor characteristics and clinical outcome. *Breast Cancer Res* 6:R149–R156
47. Bluemke DA et al (2004) Magnetic resonance imaging of the breast prior to biopsy. *JAMA* 292:2735–2742
48. Kuhl CK et al (2007) MRI for diagnosis of pure ductal carcinoma in situ: a prospective observational study. *Lancet* 370:485–492
49. Santamaria G et al (2008) Preoperative MRI of pure intraductal breast carcinoma—a valuable adjunct to mammography in assessing cancer extent. *Breast* 17:186–194
50. Rosen EL et al (2007) BI-RADS MRI enhancement characteristics of ductal carcinoma in situ. *Breast J* 13:545–550
51. Peters NH et al (2007) Breast MRI in nonpalpable breast lesions: a randomized trial with diagnostic and therapeutic outcome—MO. *Trials* 8:40