



HAL
open science

Detection of breast cancer metastasis in sentinel lymph nodes using intra-operative real time GeneSearch™ BLN Assay in the operating room: results of the Cardiff study

Robert E. Mansel, Amit Goyal, Anthony Douglas-Jones, Victoria Woods, Sumit Goyal, Ian Monypenny, Helen Sweetland, Robert G. Newcombe, Bharat Jasani

► **To cite this version:**

Robert E. Mansel, Amit Goyal, Anthony Douglas-Jones, Victoria Woods, Sumit Goyal, et al.. Detection of breast cancer metastasis in sentinel lymph nodes using intra-operative real time GeneSearch™ BLN Assay in the operating room: results of the Cardiff study. *Breast Cancer Research and Treatment*, 2008, 115 (3), pp.595-600. <10.1007/s10549-008-0155-6>. <hal-00478258>

HAL Id: hal-00478258

<https://hal.science/hal-00478258v1>

Submitted on 30 Apr 2010

HAL is a multi-disciplinary open access archive for the deposit and dissemination of scientific research documents, whether they are published or not. The documents may come from teaching and research institutions in France or abroad, or from public or private research centers.

L'archive ouverte pluridisciplinaire HAL, est destinée au dépôt et à la diffusion de documents scientifiques de niveau recherche, publiés ou non, émanant des établissements d'enseignement et de recherche français ou étrangers, des laboratoires publics ou privés.



HAL Authorization

Detection of breast cancer metastasis in sentinel lymph nodes using intra-operative real time GeneSearch™ BLN Assay in the operating room: results of the Cardiff study

Robert E. Mansel · Amit Goyal · Anthony Douglas-Jones ·
Victoria Woods · Sumit Goyal · Ian Monypenny ·
Helen Sweetland · Robert G. Newcombe · Bharat Jasani

Received: 8 May 2008 / Accepted: 6 August 2008 / Published online: 21 August 2008
© Springer Science+Business Media, LLC. 2008

Abstract *Background* Intra-operative assessment is not routinely performed in the UK due to poor sensitivity of available methods and overburdened pathology resources. We conducted a prospective clinical feasibility study of the GeneSearch™ Breast Lymph Node (BLN) Assay (Veridex, LLC, Warren, NJ) to confirm its potential usefulness within the UK healthcare system. *Methods* In the assay 50% of the lymph node was processed to detect the presence of cytokeratin-19 and mammaglobin mRNA. The assay was calibrated to detect metastases >0.2 mm. Assay results were compared to H&E performed on each face of ~2 mm alternating node slabs and 3 additional sections cut at ~150 µm interval from each face of the node slab. *Results* 124 sentinel lymph nodes were removed from 82 breast cancer patients. The assay correctly identified all 6 patients with sentinel node macrometastases (>2.0 mm), and 2 of 3 patients with sentinel node micrometastases

(0.2–2.0 mm). Sentinel lymph nodes in 4 patients were assay positive but histology negative. Two of these four patients had isolated tumor cells seen by histology. The overall concordance with histology was 93.9% (77/82), with sensitivity of 88.9% (8/9, 95% CI 56.5–98%), specificity of 94.6% (69/73, 95% CI 86.7–97.8%), positive predictive value of 66.7% (8/12, 95% CI 39.1–86.2%) and negative predictive value of 98.6% (69/70, 95% CI 92.3–99.7%). The assay was performed in a median time of 32 min (range 26–69 min). *Conclusion* Intra-operative assessment of sentinel lymph node can be performed rapidly and accurately using the GeneSearch™ BLN Assay.

Keywords Axillary lymph node dissection · Breast cancer · Intra-operative PCR · Sentinel lymph node biopsy

Introduction

Sentinel lymph node (SLN) biopsy is the current standard of care for nodal staging in early breast cancer. Approximately, 25% of women with early stage breast cancer undergoing SLN biopsy are node positive and therefore will need further therapy to the axilla as 50% of them will have further involved non-sentinel axillary nodes [1, 2]. Currently completion axillary lymph node dissection (ALND) is recommended but this involves a second procedure if routine H&E pathology is used for the SLN. Intra-operative assessment of SLN has the obvious advantage of enabling ALND to be performed immediately, thereby avoiding the morbidity, inconvenience and cost of a second, separate operation. A potential drawback of intra-operative assessment is that patients undergo an operation not knowing whether they

Presentation: This work was presented at the 30th Annual San Antonio Breast Cancer Symposium December 13-16, 2007.

R. E. Mansel (✉) · A. Goyal · H. Sweetland
Department of Surgery, School of Medicine, Cardiff University,
Cardiff CF14 4XN, UK
e-mail: manselre@cf.ac.uk

A. Douglas-Jones · V. Woods · B. Jasani
Department of Pathology, Cardiff University, Cardiff, UK

S. Goyal · I. Monypenny
Department of Surgery, University Hospital of Wales,
Cardiff, UK

R. G. Newcombe
Department of Epidemiology, Statistics and Public Health,
Cardiff University, Cardiff, UK

will wake up with an ALND. Another drawback is that patients may learn at a later date that an initial interpretation has been reversed after assessment by paraffin embedded delayed pathology. Frozen sectioning and imprint cytology have low and variable sensitivity and require a dedicated pathologist at the time of surgery to interpret the results. The false-negative rate can be reduced by serial sectioning to reduce sampling error and rapid IHC but this is too labour intensive to be adopted by overburdened UK pathologists.

Real time RT-PCR based assays can be used to detect sentinel lymph node metastasis by measuring the expression of tumor specific mRNA markers. Molecular analysis overcomes the sampling error of ‘gold standard’ histology by assessing the homogenate of the nodal tissue and can be used intra-operatively during SLN biopsy, thus enabling the surgeon to perform one-step ALND in patients with SLN metastasis. The GeneSearch™ BLN Assay is a real time RT-PCR based assay that accurately detects the presence or absence of metastasis in breast lymph nodes by quantitatively measuring the expression of mammaglobin (MG) and cytokeratin (CK) 19. MG and CK 19 are expressed at high levels in tissue of breast origin but not at all or only at low levels in normal lymph node tissue. The quantitative expression results are then applied against cut-offs for these genes that have been demonstrated to correlate with detection of metastasis with the current “gold standard” method of formalin-fixed, paraffin embedded (permanent section) H&E histology [3]. The assay is intended to detect metastasis to the same level as it is detected by permanent section H&E histology, but is intended to be used as an intra-operative test during SLN biopsy, thus providing the surgeon with immediate SLN status allowing the option of full ALND to be done at the time of the same operation.

The assay has been validated in previous studies [3, 4]. This study evaluates the feasibility of intra-operative assessment of SLN using the GeneSearch™ Breast Lymph Node (BLN) Assay (Veridex, LLC, Warren, NJ) within the UK NHS healthcare system. The sensitivity and specificity of the assay for intra-operative detection of SLN metastases were determined and compared with previously published results.

Methods

Participants

Patients of either sex who were at least 18 years of age and scheduled to undergo SLN biopsy for clinically node-negative invasive breast cancer irrespective of tumor size were eligible to participate in the trial.

Written informed consent was required from every participant according to a protocol approved by local ethics committee and in accordance with the Declaration of Helsinki. Patients participating in other research studies that would preclude their full study participation and those with previous ipsilateral axillary surgery were excluded from the trial.

Study design

We conducted a prospective clinical feasibility study of the BLN Assay to confirm its potential usefulness within the UK healthcare system. The sentinel nodes were tested intra-operatively with the GeneSearch™ BLN Assay and were also evaluated through permanent section H&E slides. Study data (BLN Assay and research slide results) was not used for patient management. The assay result was stored blinded in the computer until the diagnostic and research sections were evaluated.

Pathological examination of sentinel lymph nodes

Sentinel lymph node biopsy was performed using the combined technique according to a standardized protocol published previously [5]. In this study the BLN Assay equipment was located in an adjacent room to the operating room and the SLNs were received immediately by the technician (VW) for RNA preparation. All SLNs were bisected along the short axis into an even number of slabs (1.5–3.0 mm thick). Alternate slabs were prepared for histological evaluation or the BLN Assay (Fig. 1).

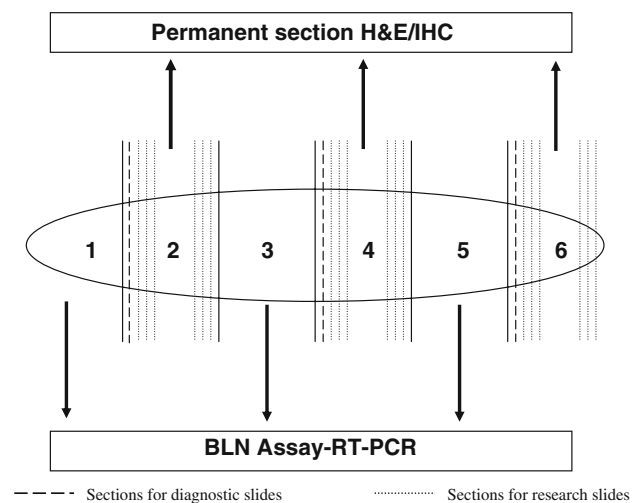


Fig. 1 Sentinel lymph node sectioning method

Real time RT-PCR assay

Training and quality assurance

Assay operators attended a 4 day training course which included hands on training. They passed a proficiency test with a panel of samples provided by Veridex before testing patient samples.

Alternating nodal tissue slabs from the same node were combined, processed and tested as per the manufacturer's instructions. The nodal tissue was homogenized to release mRNA molecules. If the combined weight of the tissue slabs from one node exceeded 550 mg, the tissue was divided into two parts prior to homogenization and each part was assayed as an individual specimen. The RNA was purified from the tissue homogenate and RT-PCR was performed on the RNA specimen using the GeneSearch™ BLN Test Kit and the Cepheid SmartCycler® (Cepheid, Sunnyvale, CA) system. Three gene markers (MG, CK19, and an internal control or housekeeping gene) were included in the real-time RT-PCR reaction, and each run included a positive and negative external control.

The BLN Assay has been calibrated to detect metastases >0.2 mm and cycle threshold (Ct) values ≤ 31 for MG and/or ≤ 30 for CK19 mRNA were considered positive. The technician performing the assay, treating surgeon and patients were blinded to the results of the assay. Assay and histological data with no patient identifying information were forwarded to Veridex for data analysis. A patient was considered to be Assay Node Positive if 1 or more SLNs were positive. A patient was considered to be Assay Node Negative if all the SLNs were negative.

Permanent section histology

The node slabs for permanent section H&E and immunohistochemistry (IHC) were processed using standard laboratory procedures. A single section (4–6 μm thick) was cut from one face of the fixed node slab for diagnostic slides. Patient management was based solely on the results of these diagnostic slides. At a later date, 3 additional sections (4–6 μm thick, $\sim 150 \mu\text{m}$ apart) were cut from each face of the fixed node slab for research slides and stained by both H&E and IHC for epithelial marker (AE1/AE3) (Fig. 1). The diagnostic slides for clinical management were reported by the on duty pathologist. The research slides (6 H&E and 6 IHC per lymph node) were reported by the expert pathologist (AGD-J) without knowledge of any patient information. The results of the diagnostic slides were compared with those of research slides to estimate the sampling error in conventional histology. Overall histology result was determined for each SLN by the combination of diagnostic and research data.

The patient was considered to be Conventional Histology Positive when the diagnostic slides and/or research slides showed metastatic disease (micrometastasis/macrometastasis) in 1 or more SLNs. The patient was designated as Conventional Histology Negative when the diagnostic slides and research slides were negative for all SLNs. Nodes showing isolated tumor cells (ITC) only were considered to be negative.

Statistical analysis

The primary endpoints were sensitivity, specificity, positive predictive value and negative predictive value of the BLN Assay. Secondary endpoints included time taken to perform the assay and a comparison of diagnostic slide results with those of research slides to estimate the sampling error of histological analysis. SLNs with invalid BLN Assay results were excluded from the analysis because excessive fat in the homogenate can lead to invalid results.

Results

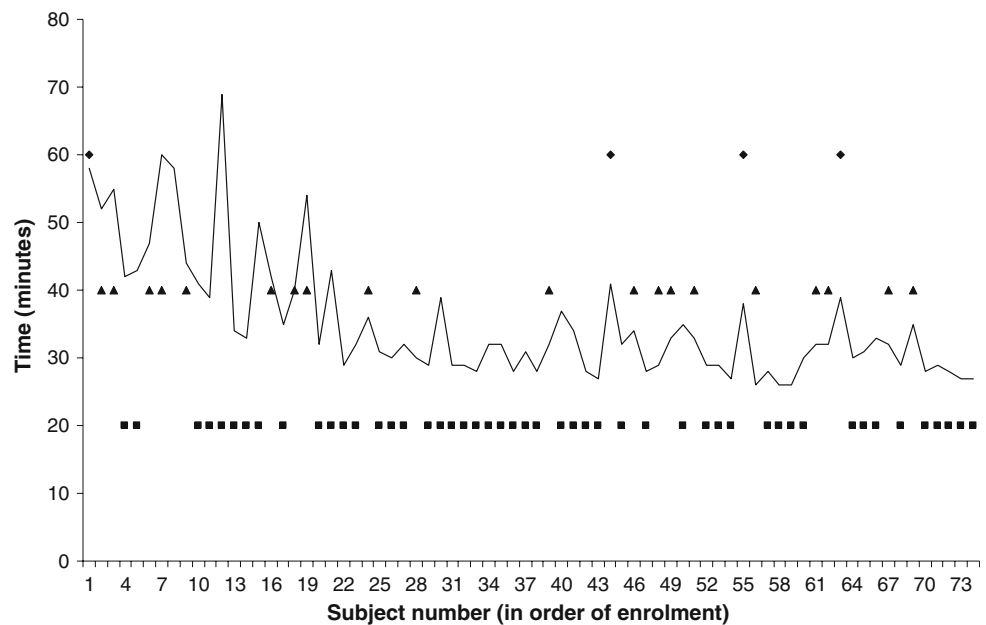
All patients were female. The median age of patients was 61 years (range 36–86 years). 124 SLNs were removed from 82 breast cancer patients. 9 of 82 patients (11%) had SLN metastases on Conventional Histology (Diagnostic and/or Research slides). Six of nine patients had macrometastases while three had micrometastases. Two of eighty two patients had isolated tumor cells and were considered as node negative for comparative analysis.

Time taken to perform the assay was recorded in 74 of 82 patients (Fig. 2). The assay was carried out in our pathology laboratory within the operating theatre complex in a median time of 32 min (range 26–69 min). There appeared to be a learning curve for performance of the assay. In the initial 20 cases, the assay was performed in a median time of 43.5 min (range 32–69 min) while the latter 54 cases were performed in a median time of 30 min (range 26–43 min). The assay took less time in patients who had one SLN removed compared with those who had multiple SLNs removed [one SLN: 30 min (range 26–69 min), two SLNs: 34.5 min (range 26–60 min), more than two SLNs: 41 min (range 38–58 min)].

Patient basis analysis (Table 1)

The assay correctly identified all six patients (100%; 95% CI 61% to 100%) with SLN macrometastases (>2.0 mm) in adjacent tissue slabs, and two of three patients (66.7%) with SLN micrometastases (0.2–2.0 mm). SLNs in four patients were assay positive but histology negative. Two of these four patients had only isolated tumor cells seen on

Fig. 2 Time taken for intra-operative assessment of sentinel lymph nodes using the GeneSearch™ BLN Assay. Number of sentinel lymph nodes removed: ■ 1 sentinel lymph node, ▲ 2 sentinel lymph nodes, ◆ >2 sentinel lymph nodes



histology. The overall concordance with histology was 93.9% (77/82), with sensitivity of 88.9% (8/9, 95% CI 56.5–98%), specificity of 94.6% (69/73, 95% CI 86.7–97.8%), positive predictive value of 66.7% (8/12, 95% CI 39.1–86.2%) and negative predictive value of 98.6% (69/70, 95% CI 92.3–99.7%).

Node basis analysis (Table 1)

Analyses performed on an individual node basis showed the overall concordance with histology was 95.2% (118/124), with sensitivity of 88.9% (8/9, 95% CI 56.5–98%),

specificity of 95.7% (110/115, 95% CI 90.2–98.1%), positive predictive value of 61.5% (8/13, 95% CI 35.5–82.3%) and negative predictive value of 99.1% (110/111, 95% CI 95.1–99.8%).

The diagnostic slide results were compared to the research slide results to quantify the inherent sampling error of conventional histology (Table 2). There was 100% (6/6, 95% CI 61–100%) agreement for macrometastases but this dropped to 33.3% (1/3) for micrometastases. The overall concordance between the diagnostic and research slide results was 98.4% (122/124) (ITC’s were considered node negative for these analyses).

Table 1 GeneSearch™ BLN assay versus conventional histology results

Histology	GeneSearch™ BLN Assay		Total
	Positive	Negative	
Patient level			
>2 mm	6	0	6
0.2–2 mm	2	1	3
ITC	2	0	2
Negative	2	69	71
Total	12	70	82
Node level			
>2 mm	6	0	6
0.2–2 mm	2	1	3
ITC	2	0	2
Negative	3	110	113
Total	13	111	124

Discussion

The sensitivity of frozen section is 76% (95% CI 65–84) and of imprint cytology is 62% (95% C.I. 53–70) [6]. False positives resulting in an unnecessary axillary

Table 2 Diagnostic slide versus research slide results (node level)

Diagnostic slides	Research slides				Total
	>2 mm	0.2–2 mm	ITC	Negative	
>2 mm	6	0	0	0	6
0.2–2 mm	0	1	0	1	2
ITC	0	0	1	0	1
Negative	0	1	1	113	115
Total	6	2	2	114	124

lymphadenectomy are uncommon with a pooled specificity of 99% [6]. Rapid immunohistochemistry and serial sectioning significantly increase the sensitivity compared to frozen section alone [7, 8]. However, these techniques have not gained popularity in the UK because of the volume of work involved, time required and the need for a technician and a pathologist to be available at the time of surgery. The GeneSearch BLN assay can be performed and the results interpreted by a trained technician without the need of a pathologist.

Sensitivity of any intra-operative technique is calculated as the percent of cases the intra-operative technique calls positive when conventional histology is positive (True positives/true positives + false negatives). However, conventional histology has inherent sampling error and therefore it should be noted that the sensitivity of the reference 'gold standard' is less than 100%. The false negative rate of conventional histology depends on the protocol followed for pathological examination of SLNs which varies considerably throughout Europe and can be reduced by serial sections and IHC [9].

GeneSearch BLN assay is performed on fresh homogenized tissue and can evaluate all cellular material within the 50% sample taken evenly from in the nodal tissue as depicted in Fig. 1, thus significantly minimizing the sampling error in the portions dedicated to the assay. In our series a second operation would have been avoided in all six patients with SLN macrometastases and in 66.7% (95% CI 20.8–93.9) patients with SLN micrometastases. The prognostic significance and management of patients with SLN micrometastases remains unclear. In our institution, we do not perform completion axillary lymph node dissection for SLN micrometastases and therefore adoption of GeneSearch™ BLN Assay would have enabled surgeons to perform one-step ALND in all the SLN positive patients in this series.

Five percent of patients (4/82) were assay positive but no metastases >0.2 mm were detected by conventional histology in adjacent tissue slabs. Two of these four patients had ITCs on histology. One percent of patients (1/82) were assay negative but found to have micrometastatic disease by histology. These results cannot be classified as true false positives or true false negatives as each test examined a different piece of tissue and may have given the correct result for the tissue slab each was testing. Complete concordance between GeneSearch BLN assay and conventional histology is not possible as the same tissue slab is not tested by both techniques. The discordance in the results is likely due to small metastases that were solely present in the tissue slab examined by the assay or conventional histology. Not surprisingly, a similar disagreement was seen between the diagnostic and research slide results.

The assay has been determined in in vitro studies to require approximately 2,000 cells to yield a positive result. Despite the apparent advantages of quantitation and sensitivity, the use of quantitative real time polymerase chain reaction does present some drawbacks. The technique is sensitive and enough contaminating cells (e.g., from breast tissue) will lead to readings that belong to non cancerous cells. To overcome this problem, assay operators should attend a validation training course and each run should include internal and external controls to ensure strict quality assurance.

Our study was a feasibility study and therefore underpowered to address sensitivity of the assay, although the results are generally consistent with the other larger trials [3]. The GeneSearch assay was compared with exhaustive serial frozen sectioning practiced by the European Institute of Oncology in Milan and was found to have an equivalent sensitivity to serial frozen sections taken every 1.5–2 mm [4]. A large, multicenter, prospective evaluation by several U.S. centers and a smaller feasibility study by Jules Bordet Institute, Belgium showed sensitivity of over 87% similar to that found in our study, suggesting the technique is reproducible across centers [3, 10].

The turnaround time of the assay is comparable to that of frozen section, and the excision of the primary tumor by wide local excision or mastectomy is conveniently performed during the running of the assay, allowing the surgeon to proceed to node dissection if the assay is positive. The assay can be performed in around 30 minutes once the learning curve is surpassed (Fig. 2).

In conclusion, our study shows that the GeneSearch™ BLN Assay is accurate and can be conducted close to the patient, and will allow intra-operative assessment of sentinel lymph node in hospitals where immediate pathology is not available due to manpower or resource constraints.

Acknowledgement This study was supported by a research grant from Veridex LLC, Warren, NJ.

References

1. Mansel RE, Fallowfield L, Kissin M, Goyal A, Newcombe RG, Dixon JM et al (2006) Randomized multicenter trial of sentinel node biopsy versus standard axillary treatment in operable breast cancer: the ALMANAC Trial. *J Natl Cancer Inst* 98:599–609
2. Goyal A, Douglas-Jones A, Newcombe RG, Mansel RE (2004) Predictors of non-sentinel lymph node metastasis in breast cancer patients. *Eur J Cancer* 40:1731–1737. doi:10.1016/j.ejca.2004.04.006
3. Blumencranz P, Whitworth PW, Deck K, Rosenberg A, Reintgen D, Beitsch P et al (2007) Scientific Impact Recognition Award. Sentinel node staging for breast cancer: intraoperative molecular pathology overcomes conventional histologic sampling errors. *Am J Surg* 194:426–432. doi:10.1016/j.amjsurg.2007.07.008

4. Viale G, Dell'Orto P, Biasi MO, Stufano V, Brito Lima LN, Paganelli G et al (2008) Comparative evaluation of an extensive histopathologic examination and a real-time reverse-transcription-polymerase chain reaction assay for mammaglobin and cytokeratin 19 on axillary sentinel lymph nodes of breast carcinoma patients. *Ann Surg* 247:136–142
5. Goyal A, MacNeill F, Keshtgar M, Horgan K, Kissin M, Layer G, Wishart G, Brown D, Purusotham A, Mansel RE, NEW START steering group (2008) Injection of radioactive colloid and blue dye at the peri-areolar edge in the tumor quadrant for sentinel lymph node biopsy in breast cancer: Results of the UK NEW START training program. *J Clin Oncol* 26:2008 (May 20 suppl; abstr 538)
6. Tew K, Irwig L, Matthews A, Crowe P, Macaskill P (2005) Meta-analysis of sentinel node imprint cytology in breast cancer. *Br J Surg* 92:1068–1080. doi:[10.1002/bjs.5139](https://doi.org/10.1002/bjs.5139)
7. Johnston EI, Beach RA, Waldrop SM, Lawson D, Cohen C (2006) Rapid intraoperative immunohistochemical evaluation of sentinel lymph nodes for metastatic breast carcinoma. *Appl Immunohistochem Mol Morphol* 14:57–62. doi:[10.1097/01.pai.0000153722.21155.5f](https://doi.org/10.1097/01.pai.0000153722.21155.5f)
8. Viale G, Bosari S, Mazzarol G, Galimberti V, Luini A, Veronesi P et al (1999) Intraoperative examination of axillary sentinel lymph nodes in breast carcinoma patients. *Cancer* 85:2433–2438. doi:[10.1002/\(SICI\)1097-0142\(19990601\)85:11<2433::AID-CNCR18>3.0.CO;2-3](https://doi.org/10.1002/(SICI)1097-0142(19990601)85:11<2433::AID-CNCR18>3.0.CO;2-3)
9. Cserni G, Amendoeira I, Apostolikas N, Bellocq JP, Bianchi S, Boecker W et al (2004) Discrepancies in current practice of pathological evaluation of sentinel lymph nodes in breast cancer Results of a questionnaire based survey by the European Working Group for Breast Screening Pathology. *J Clin Pathol* 57:695–701. doi:[10.1136/jcp.2003.013599](https://doi.org/10.1136/jcp.2003.013599)
10. Martin Martinez MD, Veys I, Majjaj S, Lespagnard L, Schobbens JC, Rouas G et al (2008) Clinical validation of a molecular assay for intra-operative detection of metastases in breast sentinel lymph nodes. *Eur J Surg Oncol*. doi:[10.1016/j.ejso.2008.05.008](https://doi.org/10.1016/j.ejso.2008.05.008)